ANTICANCER RESEARCH *40*: 6437-6441 (2020)
doi:10.21873/anticanres.14665

# Effect of Computer-aided Detection System Use on the Duration of MRI-guided Biopsy of the Breast

MASAFUMI SHIMODA[1], SEUNG JIN KIM[1], YUKIKO TOKUDA[2], YOSHIAKI SOTA[1], TOMOHIRO MIYAKE[1], TOMONORI TANEI[1], NAOFUMI KAGARA[1], YASUTO NAOI[1], SHINZABURO NOGUCHI[1] and KENZO SHIMAZU[1]

[1]*Department of Breast and Endocrine Surgery, Osaka University Graduate School of Medicine, Osaka, Japan;*
[2]*Department of Radiology, Osaka University Graduate School of Medicine, Osaka, Japan*

**Abstract.** *Background/Aim: Magnetic resonance imaging (MRI)-guided breast biopsy is a complex and time-consuming procedure. This study aimed to clarify the factors that affect the duration of the procedure. Patients and Methods: Twenty-eight examinations performed at our institute for 27 lesions detected solely on MRI were analyzed. The correlations between the clinicopathological factors and duration of the procedure were estimated. Results: The needle guidance method was the only factor that significantly affected the duration of the MRI-guided vacuum-assisted breast biopsy (VAB) (p=0.012). The use of a computer-aided detection (CAD) system with grid breast compression plates had significantly shorter durations (62±12 min) than the manual calculation of coordinates with pillar-type compression plates (76±13 min). Conclusion: This preliminary study showed that the use of a CAD system might shorten the duration of MRI-guided VAB.*

Contrast-enhanced magnetic resonance imaging (CE-MRI) is a modality that can detect breast cancer with high sensitivity and can be displayed in a three-dimensional manner. Reportedly, the sensitivity of CE-MRI in detecting breast cancer is 88%-92% (1), which is generally greater than that of mammography and ultrasonography (US), especially for younger women (2, 3). Due to its high sensitivity, CE-MRI has become essential for the evaluation of the extent of cancer spread in the affected breast when breast-conserving surgery is planned. Moreover, CE-MRI is frequently performed to diagnose impalpable lesions such as microcalcifications and bloody nipple discharge. On the contrary, the high sensitivity of CE-MRI sometimes results in the detection of lesions that can only be identified using CE-MRI. The incidental detection rate of such lesions found only on CE-MRI is 16% in ipsilateral breasts when CE-MRI is used to evaluate the extent of breast cancer spread (4). Although a second-look US is commonly performed in patients whose lesions were detected only on CE-MRI, the identification rate of this modality is approximately 58% (range=22.6-82.1%), leaving nearly half of those lesions unidentified (5).

MRI-guided vacuum-assisted breast biopsy (VAB) is the only method used for the pathological diagnosis of such lesions. Among the lesions that were pathologically diagnosed with MRI-guided VAB, the prevalence of high-risk or malignant lesions, in which surgical intervention is necessary, is 30%-55% (6-15). In addition, 6%-21% of the lesions evaluated with MRI-guided VAB are diagnosed as invasive carcinomas (6-11, 13-15). Thus, those lesions that were detected only using breast MRI and showed a risk of malignancy should be pathologically diagnosed with MRI-guided VAB when available.

Nevertheless, MRI-guided VAB has some disadvantages: it requires a biopsy system available under CE-MRI, and the cost of conducting such a procedure is relatively high. The non-negligible drawback of this examination is that it takes a considerable time to complete. The long duration of this examination may exert a substantial burden on patients and healthcare providers and decrease the cost effectiveness of an MRI system. Thus, it is important to mitigate the factor(s) that may affect the duration of MRI-guided VAB. Here, we aim to evaluate the relationships between the duration of MRI-guided VAB and various clinicopathological factors using the data of all patients who underwent MRI-guided VAB in our institution.

## Patients and methods

*Patients*. This study was approved by the institutional review board of Osaka University Hospital (study no. 14416, 16020, and 19098), and a written informed consent was obtained from each patient. MRI-guided VAB has been performed at our institution since October 2013. Data on 28 examinations for 27 lesions in 26 patients performed between October 2013 and February 2020 were

*Correspondence to:* Seung Jin Kim, MD, Ph.D., Department of Breast and Endocrine Surgery, Osaka University Graduate School of Medicine, 2-2-E10 Yamadaoka, Suita, Osaka 565-0871, Japan. Tel: +81 668793772, e-mail: kimsj@onsurg.med.osaka-u.ac.jp

*Key Words:* Magnetic resonance imaging, computer-aided detection, vacuum-assisted biopsy.

retrospectively analyzed; a lesion was examined twice with an interval of 13 months. The clinical presentation of the patients is summarized in Table I. Prior to MRI-guided VAB, CE-MR imaging was performed in all patients using a 1.5-tesla (T) or 3.0-T MRI system and a breast coil with general sequences for breast imaging.

*MRI-guided VAB*. The indication for MRI-guided VAB was determined by the attending physicians and a radiologist specializing in breast imaging. Briefly, all cases of BI-RADS 4 and 5 and some cases of BI-RADS 3, the score of which was determined according to recommendations (16), were subjected to MRI-guided VAB when the second-look US could not identify the lesions detected in the preceding MRI. Biopsy for BI-RADS 3 lesions was indicated when these lesions were detected using MRI performed for preoperative evaluation and the patients or referring physicians requested to confirm the histological diagnosis. MR images were acquired using an Achieva 3.0-T MRI system with a 7-channel breast biopsy coil (Phillips, Tokyo, Japan). The patient was placed in a prone position. The suspected breast was compressed with two pillar immobilization plates for the manual method or with a grid and a pillar immobilization plate for the computer-aided detection (CAD) grid method using DynaCAD® (version 2.1.8. between April 2014 and March 2018, and version 3.3, between October 2019 and present) (Philips, Amsterdam, the Netherlands). A fiducial marker was attached to the immobilization plate before the MRI was performed. The target lesion was identified by performing plain and CE MRI using gadoterate meglumine (6 or 7 ml per injection; Magnescope; Guerbet Japan, Tokyo, Japan). For the manual method, the x, y, and z coordinates of the target from the fiducial marker were measured on the console. For the CAD grid method, the MRI data were transferred to the DynaCAD workstation, on which the coordinates of the target were automatically calculated. According to the calculated coordinates of the target, the skin was disinfected, a local anesthetic agent was injected, and an introducer with a trocar (EnCor Biopsy Probe®; C.R. Bard, Murray Hill, NJ, USA) was inserted into the area of the suspected lesion. After the trocar was replaced with an obturator, a CE-MRI was performed to confirm if the introducer was correctly inserted. Then, the obturator was replaced with a biopsy probe, and the samples were obtained using a 10-gauge vacuum-assisted biopsy device (EnCor EnSpire; C. R. Bard). After inserting the obturator back to the introducer, CE or plain MRI was performed to confirm whether the suspected lesion was properly biopsied. The device was removed, and the breast was released from the immobilization plates. Using hands, pressure was applied to the breast wound for 5 min to stop the bleeding. Procedural duration was defined as the time between the first and last image acquisition.

*Histological evaluation*. The biopsied samples were fixed with 10% phosphate-buffered formalin and embedded in paraffin. Hematoxylin-eosin stain was applied to the thin sections; histological evaluation was performed by the pathologists from the Department of Pathology of our institute in accordance with the World Health Organization classification fourth or fifth edition (17).

*Statistics*. Statistical evaluation was performed using GraphPad Prism 6® (GraphPad Software; San Diego, CA, USA). A two-tailed unpaired Student's *t*-test with Welch's correction was applied to compare the two groups. Alternatively, one-way analysis of variance (ANOVA) was applied to compare the three groups. A *p*-value of less than 0.05 was considered significant.

Table I. *Relationship between the clinicopathological and radiological features and the duration of MRI-guided VAB*.

| Parameters | N | Duration (mean±SD, min) | *p*-Value |
|---|---|---|---|
| Age | | | |
| ≤50 y | 12 | 70±14 | |
| >50 y | 16 | 64±14 | 0.252*[1] |
| MRI finding | | | |
| Non-mass | 10 | 64±12 | |
| Mass | 18 | 68±15 | 0.424*[1] |
| Breast density | | | |
| Fatty/scattered | 10 | 72±14 | |
| Dense | 18 | 64±13 | 0.155*[1] |
| Target site | | | |
| Inner | 11 | 70±12 | |
| Center | 3 | 60±6 | |
| Outer | 14 | 66±16 | 0.519*[2] |
| Depth*[3] | | | |
| ≤26 mm | 14 | 68±13 | |
| >26 mm | 14 | 66±15 | 0.711*[1] |
| Thickness*[4] | | | |
| ≤46 mm | 15 | 63±10 | |
| >46 mm | 13 | 71±17 | 0.128*[1] |
| Known breast disease | | | |
| None | 17 | 66±11 | |
| Ipsilateral tumor | 3 | 68±31 | |
| Contralateral tumor | 8 | 67±15 | 0.977*[2] |
| Pathology | | | |
| Benign | 18 | 64±12 | |
| High risk/malignant | 10*[5] | 72±15 | 0.120*[1] |
| Surgery | | | |
| No | 18 | 64±12 | |
| Yes | 10 | 72±15 | 0.154*[1] |
| Guidance method | | | |
| Manual | 9 | 76±13 | |
| CAD | 19 | 62±12 | 0.012*[1] |
| Complication | | | |
| None | 25 | 66±15 | |
| Hematoma | 3 | 72±6 | 0.263*[1] |

*[1]Student's *t*-test; *[2]one-way ANOVA; *[3]distance between the skin and the biopsied site (median, 26 mm); *[4]breast thickness at the site of probe insertion (median, 46 mm); *[5]one high-risk lesion was upgraded to ductal carcinoma *in situ*. VAB, Vacuum-assisted biopsy; CAD, computer-aided detection.

## Results

The clinicopathological and radiological features of all study participants are summarized in Table I. The median age was 51 years (range=34-73 years), suggesting that relatively younger participants were examined by MRI-guided VAB. The reasons for performing breast MRI prior to MRI-guided VAB were as follows: preoperative evaluation of existing breast tumor (n=11), presence of bloody nipple discharge (n=7), abnormal mammogram findings (n=7), abnormal positron-emission tomography-CT findings (n=2) and an abnormal finding in the follow-up MRI for the preceding MRI-guided VAB (n=1). The

detailed pathological diagnoses of VAB samples showed no evidence of malignancy (n=9; two of them were from the same lesion), fibroadenomatous lesion (n=4), mastopathy (n=2), ductal adenoma (n=1), pseudoangiomatous stromal hyperplasia (n=2), atypical ductal hyperplasia (ADH; n=3), ductal carcinoma in situ (DCIS; n=5), invasive ductal carcinoma (n=1), and invasive lobular carcinoma (n=1). All seven malignant lesions, two ADH lesions, and a benign lesion were surgically removed. A lesion diagnosed with ADH was upgraded to DCIS in the surgical specimen (even though DCIS was highly suspected in the biopsy specimen, the number of affected ducts in the biopsy specimen was insufficient to be diagnosed as DCIS). Among the 17 lesions that did not require surgical intervention, 5 were followed up with MRI; the results of the follow-up MRI performed in one lesion with no evidence of malignancy indicated that the suspected lesion was not properly excised in the previous MRI-guided VAB. Therefore, a repeat MRI-guided VBA was performed 13 months later, and the lesion was diagnosed with no evidence of malignancy. In this case, CAD was not used in the first MRI-guided VAB but in the second examination. The MR images of the lesion and the procedural images of the first and second examinations are shown in Figure 1. The procedural duration was 15 minutes shorter in the second examination.

To identify the clinicopathological features that affected the duration of MRI-guided VAB, univariate analyses were performed (Table I). The needle guidance method was the only factor that affected the duration of the examination; MRI-guided VAB using the manual method required significantly longer time than MRI-guided VAB using CAD (76±13 *vs*. 62±12 min, respectively; $p$=0.012). Other factors including age, MRI findings, breast density, target site, depth from the skin, breast thickness, known breast disease, pathology of VAB samples, surgery, and complications were not significantly associated with the procedural duration.

## Discussion

MRI-guided breast biopsy is the sole method used for the pathological evaluation of lesions detected only on MRI (MRI-only lesions). The pathological types of MRI-only lesions reported in the present study were malignant (25%), high risk (11%), and benign (64%); the percentage of each diagnosis was comparable to that of previous studies (6-15). Thus, as previously pointed out, MRI-only lesions should be properly diagnosed and treated if necessary. Historically, MRI-guided hookwire localization followed by surgical excision for pathological evaluation of MRI-only lesions was usually performed. With the development of devices for needle biopsy systems that can be used near MRI scanners, MRI-guided breast biopsy using a handheld biopsy system was established. However, MRI-guided breast biopsy is time consuming as it involves the performance of complex procedures compared with US-guided breast biopsy. On the other hand, CAD systems have been used to accurately interpret MR images, especially in unfamiliar breast MRI readers (18, 19). Taking advantage of the accurate reading using a CAD system, MRI-guided VAB in combination with a CAD system, which was initiated by Dr. Heywang-Köbrunner in 1999 (20), has become widespread. In this preliminary study, we found that the utilization of CAD systems might help shorten the duration of this complicated examination.

In a series of 475 lesions sampled through MRI-guided breast biopsy, Schrading *et al*. reported that the use of VAB with CAD console significantly took lesser time than the use of handheld biopsy device (21). Therefore, the longer duration of MRI-guided biopsy using a handheld device might be because of the differences in the method of sampling and the requirement for the handheld device to be inserted and withdrawn for every single sampling. In contrast, the VAB system can obtain multiple samples without removing the device. In this study, we used the same biopsy device (EnCor EnSpire® biopsy system), which can obtain samples repeatedly without removing it. Thus, the difference in the procedural duration seems to be attributable to the use of a CAD system, which helps in quickly determining the x, y, and z coordinates of a target lesion as well as guiding the needle to the lesion more precisely.

Biopsy is the most reliable examination in terms of avoiding false-positive results. Thus, one of the important purposes of building a better biopsy system is to reduce the sampling error, which leads to an increase in false-negative results. The use of a CAD system may contribute to the certainty of sampling of a target lesion. Schrading *et al*. reported that the examiners' confidence in sampling the lesion of interest was stronger in MRI-guided VAB when CAD systems were used, compared with MRI-guided biopsy using handheld devices (21). This case series is not adequate to indicate if this assumption is correct because all benign cases, whether CAD was used or not, did not develop malignant lesions after performing MRI-guided VAB. Nevertheless, it was speculated that the use of a CAD system can reduce the sampling error because the x, y, and z coordinates of the target can be objectively determined. A recent study reported the additional potential of a CAD system in MRI-guided VAB, which may enable the construction of a robotic biopsy system, leading to reduction of the sampling error and workload of the healthcare providers (22).

## Conclusion

Utilization of a CAD system might help shorten the duration of MRI-guided VAB. The limitation of this study was the small number of cases undergoing MRI-guided VAB, making the findings of this study preliminary. To verify this, an investigation of a large number of cases undergoing MRI-guided VAB is necessary.

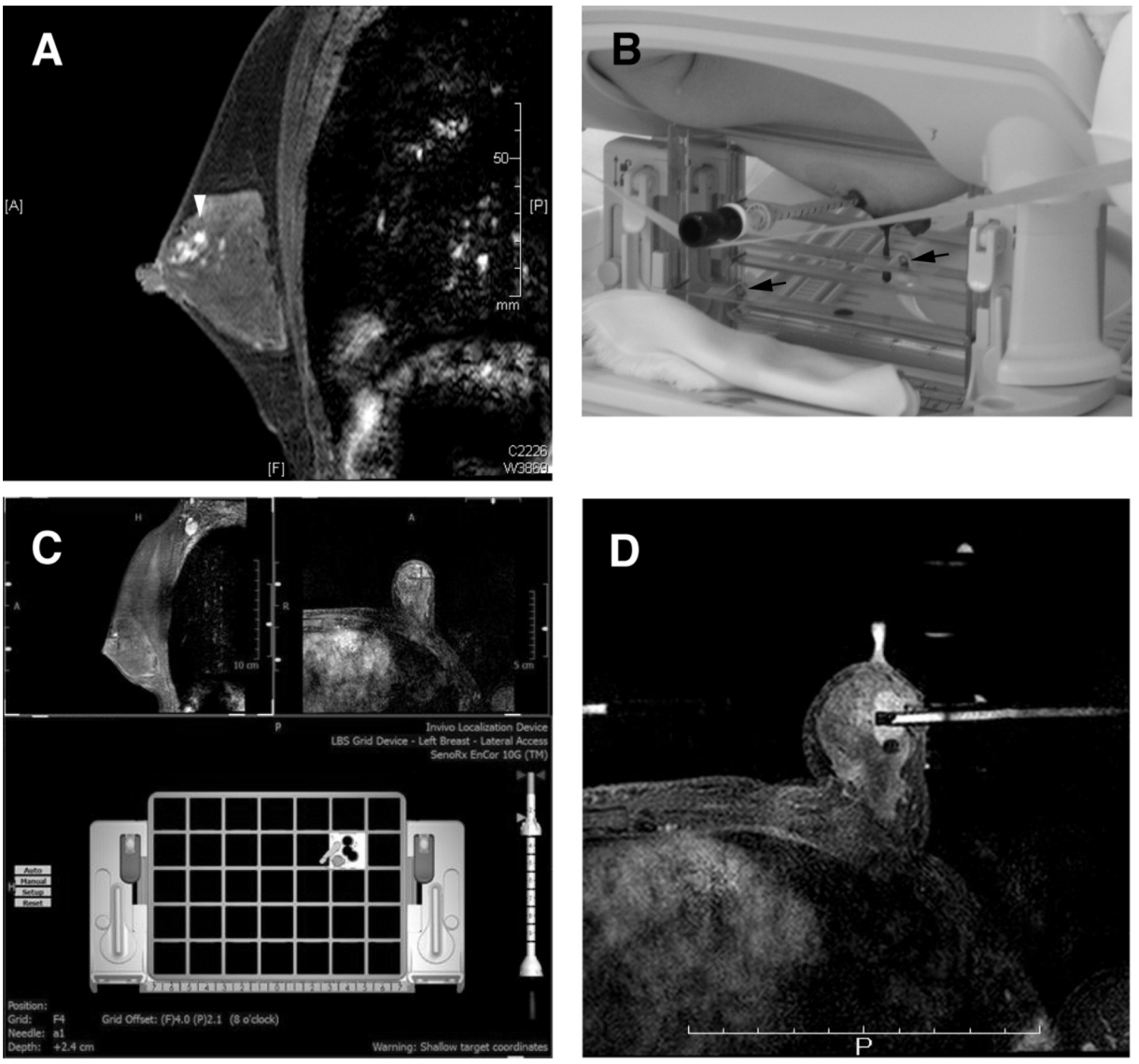


Figure 1. *A case of a breast lesion examined by MRI-guided VAB twice. (A, B) In the first examination a biopsy needle was inserted manually. The procedural duration was 75 min. (A) An MR image showing the location of the target lesion (arrowhead). (B) A photograph showing an obturator after inserting a biopsy needle into the target, based on the 3-dimensional distance manually calculated from two fiducial markers (arrows). (C, D) In the second examination a biopsy needle was guided using a CAD system. The procedural duration was 60 min. (C) An image indicating the location in the grid and depth of the target lesion automatically calculated on a CAD system. (D) An MR image showing an obturator after inserting a biopsy needle in accordance with the calculation result.*

## Conflicts of Interest

Osaka University Hospital received a free rental service of the DynaCAD system from Philips Japan, Ltd. All Authors declare that they have no conflicts of interests.

## Authors' Contributions

MS performed the MRI-guided biopsy, collected data, and wrote the first draft of the manuscript. SJK conceived the study, participated in the MRI-guided biopsy, collected the data, and revised the manuscript. YT diagnosed the MRI findings and participated in the MRI-guided biopsy. YS, TM, TT, NK, YN, and KS treated patients who underwent breast biopsy. SN supervised the study.

## Acknowledgements

The Authors thank Dr. Mitsuhiro Tozaki (Sagara Hospital) for providing technical assistance with the MRI-guided breast biopsy and Drs. Keiichiro Honma and Eiichi Morii (Department of Pathology, Osaka University Hospital) for providing assistance with the pathological evaluation.

## References


1 Peters NH, Borel Rinkes IH, Zuithoff NP, Mali WP, Moons KG and Peeters PH: Meta-analysis of MR imaging in the diagnosis of breast lesions. Radiology *246(1)*: 116-124, 2008. PMID: 18024435. DOI: 10.1148/radiol.2461061298

2 Kuhl CK, Schrading S, Leutner CC, Morakkabati-Spitz N, Wardelmann E, Fimmers R, Kuhn W and Schild HH: Mammography, breast ultrasound, and magnetic resonance imaging for surveillance of women at high familial risk for breast cancer. J Clin Oncol *23(33)*: 8469-8476, 2005. PMID: 16293877. DOI:10.1200/JCO.2004.00.4960

3 Elsamaloty H, Elzawawi MS, Mohammad S and Herial N: Increasing accuracy of detection of breast cancer with 3-T MRI. AJR Am J Roentgenol *192(4)*: 1142-1148, 2009. PMID: 19304726. DOI: 10.2214/AJR.08.1226

4 Houssami N, Ciatto S, Macaskill P, Lord SJ, Warren RM, Dixon JM and Irwig L: Accuracy and surgical impact of magnetic resonance imaging in breast cancer staging: systematic review and meta-analysis in detection of multifocal and multicentric cancer. J Clin Oncol *26(19)*: 3248-3258, 2008. PMID: 18474876. DOI: 10.1200/JCO.2007.15.2108

5 Spick C and Baltzer PA: Diagnostic utility of second-look US for breast lesions identified at MR imaging: systematic review and meta-analysis. Radiology *273(2)*: 401-409, 2014. PMID: 25119022. DOI: 10.1148/radiol.14140474

6 Perlet C, Heywang-Kobrunner SH, Heinig A, Sittek H, Casselman J, Anderson I and Taourel P: Magnetic resonance-guided, vacuum-assisted breast biopsy: results from a European multicenter study of 538 lesions. Cancer *106(5)*: 982-990, 2006. PMID: 16456807. DOI: 10.1002/cncr.21720

7 Liberman L, Holland AE, Marjan D, Murray MP, Bartella L, Morris EA, Dershaw DD and Wynn RT: Underestimation of atypical ductal hyperplasia at MRI-guided 9-gauge vacuum-assisted breast biopsy. AJR Am J Roentgenol *188(3)*: 684-690, 2007. PMID: 17312054. DOI: 10.2214/AJR.06.0809

8 Han BK, Schnall MD, Orel SG and Rosen M: Outcome of MRI-guided breast biopsy. AJR Am J Roentgenol *191(6)*: 1798-1804, 2008. PMID: 19020252. DOI: 10.2214/AJR.07.2827

9 Tozaki M, Yamashiro N, Sakamoto M, Sakamoto N, Mizuuchi N and Fukuma E: Magnetic resonance-guided vacuum-assisted breast biopsy: results in 100 Japanese women. Jpn J Radiol *28(7)*: 527-533, 2010. PMID: 20799018. DOI: 10.1007/s11604-010-0464-7

10 Rauch GM, Dogan BE, Smith TB, Liu P and Yang WT: Outcome analysis of 9-gauge MRI-guided vacuum-assisted core needle breast biopsies. AJR Am J Roentgenol *198(2)*: 292-299, 2012. PMID: 22268171. DOI: 10.2214/AJR.11.7594

11 Oxner CR, Vora L, Yim J, Kruper L and Ellenhorn JD: Magnetic resonance imaging-guided breast biopsy in lesions not visualized by mammogram or ultrasound. Am Surg *78(10)*: 1087-1090, 2012. PMID: 23025947.

12 Heller SL, Elias K, Gupta A, Greenwood HI, Mercado CL and Moy L: Outcome of high-risk lesions at MRI-guided 9-gauge vacuum- assisted breast biopsy. AJR Am J Roentgenol *202(1)*: 237-245, 2014. PMID: 24370150. DOI: 10.2214/AJR.13.10600

13 Imschweiler T, Haueisen H, Kampmann G, Rageth L, Seifert B, Rageth C, Freiwald B and Kubik-Huch RA: MRI-guided vacuum-assisted breast biopsy: comparison with stereotactically guided and ultrasound-guided techniques. Eur Radiol *24(1)*: 128-135, 2014. PMID: 23979106. DOI: 10.1007/s00330-013-2989-5

14 Ferré R, Ianculescu V, Ciolovan L, Mathieu MC, Uzan C, Canale S, Delaloge S, Dromain C and Balleyguier C: Diagnostic performance of MR-guided vacuum-assisted breast biopsy: 8 years of experience. Breast J *22(1)*: 83-89, 2016. PMID: 26511082. DOI: 10.1111/tbj.12519

15 Spick C, Schernthaner M, Pinker K, Kapetas P, Bernathova M, Polanec SH, Bickel H, Wengert GJ, Rudas M, Helbich TH and Baltzer PA: MR-guided vacuum-assisted breast biopsy of MRI-only lesions: a single center experience. Eur Radiol *26(11)*: 3908-3916, 2016. PMID: 26984430. DOI: 10.1007/s00330-016-4267-9

16 Mann RM, Balleyguier C, Baltzer PA, Bick U, Colin C, Cornford E, Evans A, Fallenberg E, Forrai G, Fuchsjäger MH, Gilbert FJ, Helbich TH, Heywang-Köbrunner SH, Camps-Herrero J, Kuhl CK, Martincich L, Pediconi F, Panizza P, Pina LJ, Pijnappel RM, Pinker-Domenig K, Skaane P and Sardanelli F; European Society of Breast Imaging (EUSOBI), with language review by Europa Donna–The European Breast Cancer Coalition: Breast MRI: EUSOBI recommendations for women's information. Eur Radiol *25(12)*: 3669-3678, 2015. PMID: 26002130. DOI: 10.1007/s00330-015-3807-z

17 Lakhani SR, Ellis IO, Schnitt SJ, Tan PH and van de Vijver MJ: WHO Classification of Tumours of the Breast, Volume 4, IARC WHO Classification of Tumours, No 4, 2012.

18 Dorrius MD, Jansen-van der Weide MC, van Ooijen PM, Pijnappel RM and Oudkerk M: Computer-aided detection in breast MRI: a systematic review and meta-analysis. Eur Radiol *21(8)*: 1600-1608, 2011. PMID: 21404134. DOI: 10.1007/s00330-011-2091-9

19 Lehman CD, Blume JD, DeMartini WB, Hylton NM, Herman B and Schnall MD: Accuracy and interpretation time of computer-aided detection among novice and experienced breast MRI readers. AJR Am J Roentgenol *200(6)*: W683-W689, 2013. PMID: 23701102. DOI: 10.2214/AJR.11.8394

20 Heywang-Köbrunner SH, Heinig A, Schaumlöffel U, Viehweg P, Buchmann J, Lampe D and Spielmann R: MR-guided percutaneous excisional and incisional biopsy of breast lesions. Eur Radiol *9(8)*: 1656-1665, 1999. PMID: 10525886. DOI: 10.1007/s003300050905

21 Schrading S, Simon B, Braun M, Wardelmann E, Schild HH and Kuhl CK: MRI-guided breast biopsy: influence of choice of vacuum biopsy system on the mode of biopsy of MRI-only suspicious breast lesions. AJR Am J Roentgenol *194(6)*: 1650-1657, 2010. PMID: 20489109. DOI: 10.2214/AJR.09.2550

22 Liu W, Yang Z, Jiang S, Feng D and Zhang D: Design and implementation of a new cable-driven robot for MRI-guided breast biopsy. Int J Med Robot *16(2)*: e2063, 2020. PMID: 31830358. DOI: 10.1002/rcs.2063


*Received August 19, 2020*
*Revised September 2, 2020*
*Accepted September 8, 2020*