

Male Malignant Phyllodes Breast Tumor After Prophylactic Breast Radiotherapy and Bicalutamide Treatment: A Case Report

PEETER KARIHTALA¹, TARJA RISSANEN² and HANNU TUOMINEN³

¹*Department of Oncology and Radiotherapy, Medical Research Center Oulu, Oulu University Hospital and University of Oulu, Oulu, Finland;*

Departments of ²Radiology and ³Pathology, Oulu University Hospital, Oulu, Finland

Abstract. *Phyllodes tumor in male breast is an exceptionally rare neoplasm with only few published case reports. Herein, we present a case of malignant phyllodes tumor in male breast nine years after prophylactic breast 10 Gy radiotherapy and after nine year bicalutamide treatment. The imaging findings of the tumor and pathological correlation are also presented.*

Phyllodes tumors are rare neoplasms with an incidence in women that has been estimated to be <1% of all breast primary tumors. Phyllodes tumors contain both epithelial and stromal components and are classified as benign, borderline and malignant subtypes, although this classification does not necessarily optimally reflect tumor's clinical behavior (1, 2). Clinically, phyllodes tumors are usually rapidly growing and painless masses. In mammography or ultrasound, women's phyllodes tumors may appear as fibroadenomas (1). The median age of the patients is 40-50 years in women (3, 4). The main treatment modality is local surgical excision with tumor-free margins of at least 1 cm. Since metastases are rare, also in axillary lymph nodes (ALNs), there is no need for routine surgical axillary staging or ALN dissection (1).

The current localized prostate cancer guidelines recommend adjuvant androgen-deprivation therapy with either luteinizing hormone-releasing hormone (LHRH) analogues or bicalutamide after radiotherapy or surgery to the patients with high-risk for prostate cancer mortality (5, 6). Based on small randomized trials, breast bud radiotherapy 10 to 12 Gray (Gy) reduces

gynecomastia and mastalgia rates and it is, therefore, routinely administrated in the beginning of bicalutamide treatment (7, 8).

There are very few reports describing breast phyllodes tumor in men with few cases reported in the English literature. Usually, these tumors are associated with gynecomastia, with various etiological factors reported (9-18). To the best of our knowledge, the present study reports the first case of male malignant phyllodes tumor occurring after bicalutamide treatment or radiotherapy.

Case Report

A sixty-eight-year-old man was diagnosed with cT3NxM0, Gleason score 8 (4+4) prostate adenocarcinoma in December 2004. There were no known cancers in family history. Bone scan did not show any suspect lesions and prostate-specific antigen (PSA) level was 22 ng/ml at the time of diagnosis. The patient was managed with single androgen suppression therapy (LHRH analogue leuporelin) and external beam radiotherapy to a total dose of 72 Gy in April-June 2005. Due to side-effects of adjuvant leuporelin, the attending urologist changed adjuvant treatment to 150 mg of bicalutamide once daily in August 2006, which was administrated since then. To prevent gynecomastia, prophylactic 10 Gy bilateral breast irradiation with a single fraction was delivered in October 2006.

Soon after breast radiotherapy, the patient noticed his left breast enlarged and during the summer of 2014 he felt a separate lump in his left breast, which began to enlarge. In a routine control in October 2014, physical examination revealed a mobile tumor in the left breast with intact skin. Subsequent breast ultrasound revealed a 36×23 mm solid, rather hyperemic, uncalcified tumor with no clear invasive growth pattern. Core needle biopsy demonstrated features of malignant, sarcomatotic adenosarcoma.

Preoperative magnetic resonance imaging (MRI) showed bilateral gynecomastia with a heterogeneously enhancing tumor in the upper lateral part of left breast. Tumor's dimensions were

This article is freely accessible online.

Correspondence to: Peeter Karihtala, Department of Oncology and Radiotherapy, Oulu University Hospital, PO Box 22, 90029 Oulu, Finland. Tel: +358 83152011, Fax: +358 83156449, e-mail: peeter.karihtala@oulu.fi

Key Words: Male breast tumor, phyllodes tumors, case report.

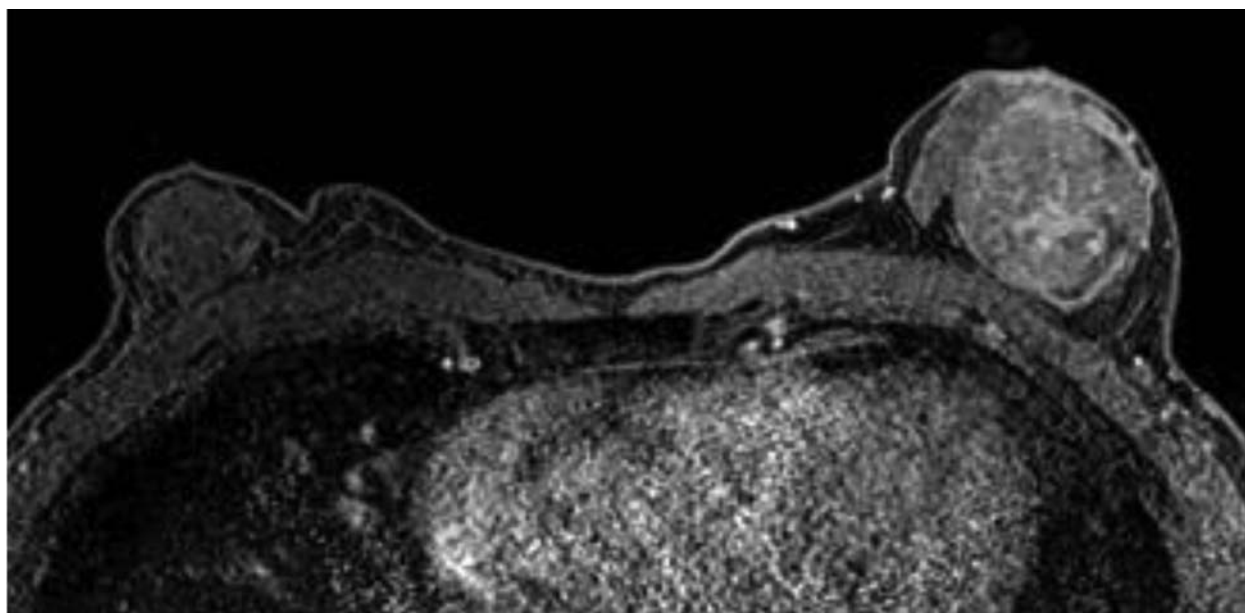


Figure 1. Axial T1-weighted magnetic resonance image, taken 300 sec after intravenous contrast injection, shows bilateral gynecomastia and a 45-mm well-circumscribed heterogeneously enhancing mass in the left breast.

40×45×45 mm and, although it was in contact with the pectoralis major muscle, it did not infiltrate into it (Figure 1). There were no suspicious ALNs observed in MRI. Breast ultrasound demonstrated similar dimensions in solid tumor with prominent vasculature and definite borders. No metastatic lesions were found in whole body computed tomography and no thoracic invasion of the tumor was observed.

Mastectomy without axillary procedures was performed in February 2015; also, approximately 60% of the caudal part of the pectoralis major was removed. Large, compressive retrosternal struma was removed during the same operation with total thyroidectomy. There were no problems in postoperative recovery. No local recurrence or distant metastases were noted during the 14-month follow-up after surgery.

Postoperative radiotherapy to thoracic wall was administered (2 Gy × 25 fractions up to total of 50 Gy) starting six weeks after surgery. No early complications of surgery or radiotherapy were observed with the exception of local radiation dermatitis (grade 1-2a) according to the Radiation Therapy Oncology Group (RTOG).

Pathological Findings

The preoperative core needle biopsy revealed tumor tissue of two components: a cellular stroma with atypical spindle and pleomorphic cells and tubular and papillary structures of proliferating epithelial cells without atypia. The mastectomy material contained a totally excised roundish tumor of 51 mm in diameter. It was mostly well-circumscribed but focally with

an infiltrative border. No heterologous elements were detected. Mitoses were abundant in the stromal cells, more than 10 mitoses per high power field. Immunohistochemically, pancytokeratin, CD34, desmin, alfa-SMA and S100 protein were negative in stromal cells, whereas CK5/6 and estrogen receptor were strongly and variably positive in epithelial cells, respectively. Histopathological findings were consistent with a biphasic tumor containing a malignant stromal component, a malignant phyllodes tumor of the male breast (Figure 2).

Discussion

Phyllodes breast tumors comprise <1% of breast tumors in women. In the largest retrospective cohort study including 172 phyllodes tumors of breast, only one (0.58%) tumor was reported in male (4). Male phyllodes tumors have been reported most commonly in prostate (19-22) but also in urethra and seminal vesicles (23, 24).

Based on single case reports in the literature (9-18), gynecomastia seems to associate with the development of male phyllodes tumors, which suggests hormonal etiology in the pathogenesis of male phyllodes tumor. Gynecomastia is the most common male breast abnormality with various etiological factors, which are potent to affect the estrogen / androgen imbalance (Johnson *et al.*). There is a single published case report where phyllodes tumor appearing in male breast following prolonged estrogen therapy (18). In the present case report, our patient received antiandrogen bicalutamide for nine years as an adjuvant therapy of localized prostate

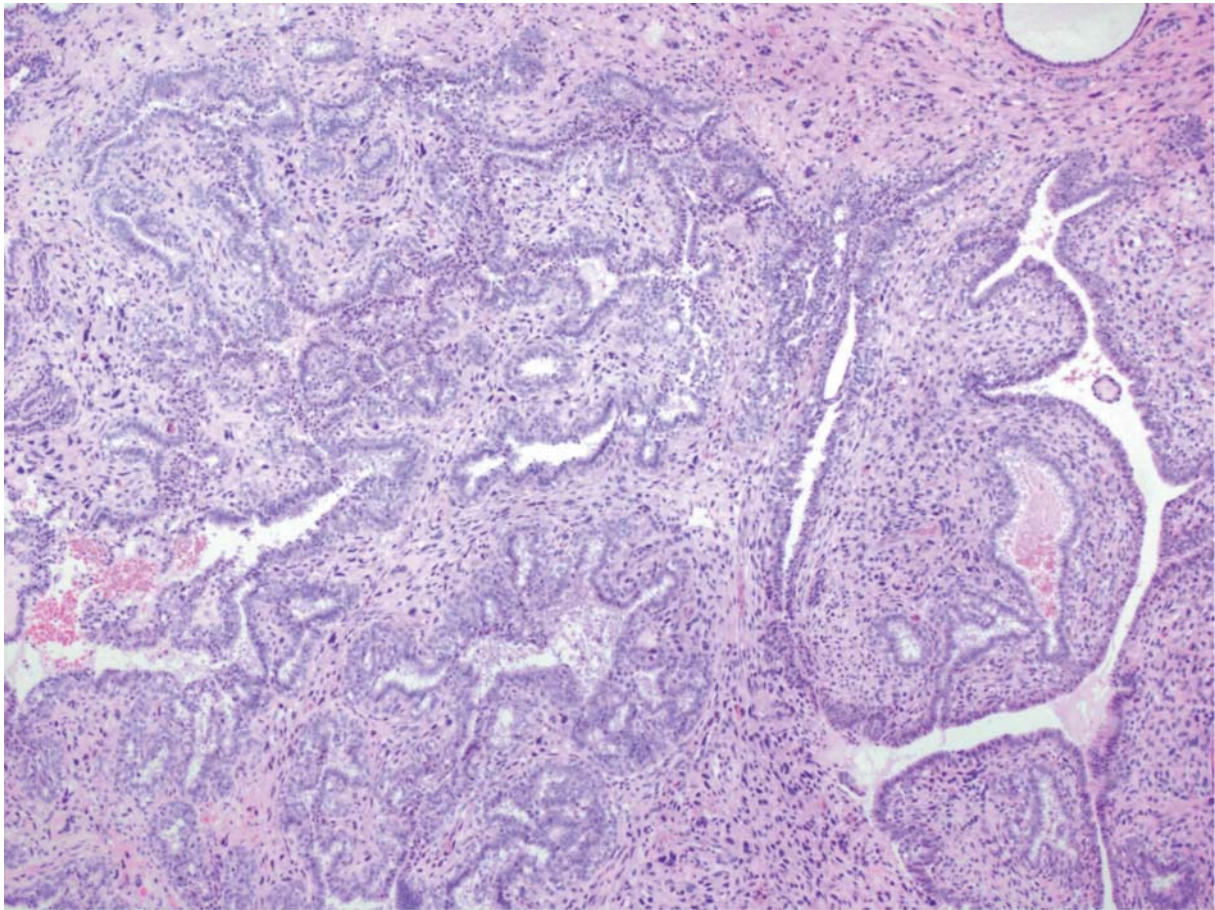


Figure 2. Malignant phyllodes tumor showing atypical, cellular stromal component covered with proliferative, non-atypical epithelium as assessed by hematoxylin & eosin staining.

adenocarcinoma. Originally, the duration of bicalutamide treatment was planned to be five years; however, there was a small rise in PSA after three months of bicalutamide discontinuation at five years and the treatment was, therefore, re-initiated. As an androgen receptor antagonist, bicalutamide induces estrogen in relation to androgen imbalance, with gynecomastia being a very common side-effect (25).

Our patient had phyllodes tumor occurring nine years after 10 Gy breast radiotherapy. Prophylactic breast irradiation is still the standard practice at the start of bicalutamide administration, although in a randomized study only 52% of patients developed gynecomastia even without breast irradiation (7). On the other hand, despite breast bud irradiation, 15% of patients still develop gynecomastia (7), like our patient did. In addition to bicalutamide-induced gynecomastia and subsequent tumorigenesis, there is -in theory- a possibility that phyllodes tumor was a secondary tumor nine years after radiotherapy. There is no data on the risk of developing a secondary malignancy after prophylactic breast radiotherapy, although after breast cancer adjuvant radiotherapy

there is a slightly elevated risk of second malignancy (26, 27). Nevertheless, adjuvant breast radiotherapy has been traditionally administered to a dose of 50 Gy, significantly greater than that used in prophylactic breast bud irradiation. There is also a case report of high-grade pleomorphic spindle cell sarcoma of breast after prophylactic breast bud irradiation (28). Also in this case, the tumor was curatively operated. We decided to administer an additional postoperative 50 Gy radiotherapy after phyllodes surgery, although this practice is still controversial and not assessed in randomized studies (1).

Women with germline *TP53* mutation (Li-Fraumeni) showed an increased risk for phyllodes tumor (29). Although our patient was diagnosed with a second cancer, he had no family history of any carcinomas and, thus, likely, no germline *TP53* mutation. The clinical course of the patient was fairly ordinary to phyllodes tumor with painless rapidly growing mass in breast. Like in our case, it is rare that a definite diagnosis can be made based on imaging findings or percutaneous needle biopsies (30). On MRI, phyllodes tumors in female patients have many similarities with common fibroadenomas: both appear as a well-

circumscribed mass with variable enhancement after intravenous contrast administration. In a recent study, phyllodes tumors tended to be more heterogeneous and showed cystic components and strong lobulation, significantly more frequently than fibroadenomas (31). MRI findings of male phyllodes tumor have not, to our knowledge, been described previously.

In conclusion, we presented a case report of a patient who had an extremely rare malignant phyllodes tumor after prophylactic breast irradiation and a 10-year treatment of bicalutamide. Although it cannot be conclusively stated, phyllodes tumor may be linked with either gynecomastia or 10-year bicalutamide treatment or prophylactic breast irradiation. Typical to malignant phyllodes tumors, the tumor was still operable at the time of diagnosis and, thus, carried an excellent prognosis.

References

- NCCN Clinical Practice Guidelines in Oncology. Version 1.2016. www.nccn.org.
- Anderson BO, Lawton TJ, Lehman CD and Moe RE: Phyllodes tumors. *In: Harris JR, Lippman ME, Morrow M, Osborne CK, eds. Diseases of the Breast* (ed 3rd). Philadelphia, Lippincott Williams & Wilkins, 2004.
- Macdonald OK, Lee CM, Tward JD, Chappel CD and Gaffney DK: Malignant phyllodes tumor of the female breast: association of primary therapy with cause-specific survival from the Surveillance, Epidemiology, and End Results (SEER) program. *Cancer* 107: 2127-2133, 2006.
- Spitaleri G, Toesca A, Botteri E, Bottiglieri L, Rotmensz N, Boselli S, Sangalli C, Catania C, Toffalorio F, Noberasco C, Delmonte A, Luini A, Veronesi P, Colleoni M, Viale G, Zurrida S, Goldhirsch A, Veronesi U and De Pas T: Breast phyllodes tumor: a review of literature and a single center retrospective series analysis. *Crit Rev Oncol Hematol* 88: 427-436, 2013.
- Parker C, Gillissen S, Heidenreich A and Horwich A: Cancer of the Prostate: ESMO Clinical Practice Guidelines. *Ann Oncol* 26(suppl 5): v69-v77, 2015.
- Mottet N, Bellmunt J and Briers E: European Urology Association. Guidelines on Prostate Cancer. http://uroweb.org/wp-content/uploads/09-Prostate-Cancer_LR.pdf
- Ozen H, Akyol F, Toktas G, Eskicorapci S, Unluer E, Kuyumcuoglu U, Abay E, Cureklibatur I, Sengoz M, Yalcin V, Akpınar H, Zorlu F, Sengor F and Karaman I: Is prophylactic breast radiotherapy necessary in all patients with prostate cancer and gynecomastia and/or breast pain? *J Urol* 184: 519-524, 2010.
- Van Poppel H, Tyrrell CJ, Haustermans K, Cangh PV, Keuppens F, Colombeau P, Morris T and Garside L: Efficacy and tolerability of radiotherapy as treatment for bicalutamide-induced gynecomastia and breast pain in prostate cancer. *Eur Urol* 47: 587-592, 2005.
- Reingold IM and Ascher GS: Cystosarcoma phyllodes in a man with gynecomastia. *Am J Clin Pathol* 53: 852-856, 1970.
- Bapat K, Oropeza R and Sahoo S: Benign phyllodes tumor of the male breast. *Breast J* 8: 115-116, 2002.
- Nielsen VT and Andreasen C: Phyllodes tumour of the male breast. *Histopathology* 11: 761-762, 1987.
- Hilton DA, Jameson JS and Furness PN: A cellular fibroadenoma resembling a benign phyllodes tumour in a young male with gynecomastia. *Histopathology* 18: 476-477, 1991.
- Ansah-Boateng Y and Tavassoli FA: Fibroadenoma and cystosarcoma phyllodes of the male breast. *Mod Pathol* 5: 114-116, 1992.
- Kahan Z, Toszegi AM, Szarvas F, Gaizer G, Baradnay G and Ormos J: Recurrent phyllodes tumor in a man. *Pathol Res Pract* 193: 653-658, 1997.
- Konstantakos AK and Graham DJ: Cystosarcoma phyllodes tumors in men. *Am Surg* 69: 808-811, 2003.
- Kim JG, Kim SY, Jung HY, Lee DY and Lee JE: Extremely rare borderline phyllodes tumor in the male breast: a case report. *Clin Imaging* 39: 1108-1011, 2015.
- Chouqule A, Bal A, Rastoqi P and Das A: Recurrent phyllodes tumor in the male breast in a background of gynecomastia. *Breast Dis* 35: 139-142, 2015.
- Bartoli C, Zurrida SM and Clemente C: Phyllodes tumor in a male patient with bilateral gynecomastia induced by oestrogen therapy for prostatic carcinoma. *Eur J Surg Oncol* 17: 215-217, 1991.
- Maudlin L, Ball RY, Irving S, Preston P and Chitale S: Phyllodes tumour of the prostate posing diagnostic and therapeutic dilemmas. *BMJ Case Rep* 2010, 2010.
- Fujii T, Shimada K, Tanaka N, Fujimoto K and Konishi N: Phyllodes tumor of the prostate. *Pathol Int* 62: 204-208, 2012.
- Parada D, Ugas G, Peña K, Caricote L and Mujica N: Lung metastases of low grade phyllodes tumor of the prostate: histopathologic confirmation. *Arch Esp Urol* 61: 658-662, 2008.
- Shabaik A: Nonepithelial tumors and tumor-like lesions of the prostate gland. *Crit Rev Clin Lab Sci* 40: 429-472, 2003.
- Tang J, He L, Long Z and Wei J: Phyllodes tumor of the verumontanum: a case report. *Diagn Pathol* 10: 69, 2015.
- Safar B, Kanmaniraja D and Herts BR: Phyllodes tumor of the seminal vesicle. *J Urol* 192: 554-555, 2014.
- Sieber PR: Treatment of bicalutamide-induced breast events. *Expert Rev Anticancer Ther* 7: 1773-1779, 2007.
- Berrington de Gonzalez A, Curtis RE, Gilbert E, Berg CD, Smith SA, Stovall M and Ron E: Second solid cancers after radiotherapy for breast cancer in SEER cancer registries. *Br J Cancer* 102: 220-226, 2010.
- Zhang W, Becciolini A, Biggeri A, Pacini P and Muirhead CR: Second malignancies in breast cancer patients following radiotherapy: a study in Florence, Italy. *Breast Cancer Res* 13: R38, 2011.
- Lewis R, Cassoni A and Payne H: Prophylactic breast bud radiotherapy for patients taking bicalutamide: should this still be practised for patients with prostate cancer? *Case Rep Oncol Med* 2012; 2012:239269.
- Birch JM, Alston RD, McNally RJ, Evans DG, Kelsey AM, Harris M, Eden OB and Varley JM: Relative frequency and morphology of cancers in carriers of germline TP53 mutations. *Oncogene* 20: 4621-4628, 2001.
- Plaza MJ, Swintelski C, Yaziji H, Torres-Salichs M and Esserman LE: Phyllodes tumor: review of key imaging characteristics. *Breast Dis* 35: 79-86, 2015.
- Kamitani T, Matsuo Y, Yabuuchi H, Fujita N, Nagao M, Kawanami S, Yonezawa M, Yamasaki Y, Tokunaga E, Kubo M, Yamamoto H and Honda H: Differentiation between benign phyllodes tumors and fibroadenomas of the breast on MR imaging. *Eur J Radiol* 83: 1344-1349, 2014.

Received April 20, 2016

Revised May 25, 2016

Accepted May 26, 2016