Sentinel Node Navigation Surgery for Lower Rectal Cancer

HIDEJIRO KAWAHARA[1], KAZUHIRO WATANABE[1], HIROYA ENOMOTO[1], MITSUHIRO TOMODA[1], TADASHI AKIBA[1] and KATSUHIKO YANAGA[2]

[1]*Department of Surgery, Kashiwa Hospital, Jikei University School of Medicine, Chiba, Japan;*
[2]*Department of Surgery, Jikei University School of Medicine, Tokyo, Japan;*

Abstract. *Background: Lateral pelvic lymph node metastasis is generally present in 17% of patients with T3 lower rectal cancer. However, such lymph node metastases cannot be accurately detected before surgery. Since 2001, we have performed sentinel node navigation surgery for patients with T3 lower rectal cancer considering the lymph nodes located between the vesicohypogastric fascia and the pelvic nerve plexus as the lateral sentinel lymph node (LSN). Patients and Methods: Between 2001 and 2010, 101 patients with T3 lower rectal cancer without distant metastasis or peritoneal dissemination were prospectively enrolled in the study. Patients with negative lymph nodes in the mesorectum underwent only LSN dissection in the lateral pelvic space. Patients with metastatic lymph nodes detected in the mesorectum underwent lateral pelvic lymph node dissection (LPLD). Results: Fifty-three out of the 101 patients with pathologically-negative lymph nodes in the mesorectum and a negative LSN were clinically judged as having stage II disease because no recurrence was detected in the lateral pelvic space during the three years following surgery. The other 48 patients underwent LPLD because of a positive lymph node in the mesorectum, and were further divided into two sub-groups, 40 with a negative and 8 with a positive LSN. Only the eight patients with a positive LSN also had positive lymph nodes in the lateral pelvic space. Conclusion: Patients with T3 lower rectal cancer in stage III may not require LPLD. LSN may be very useful to determine stage II disease during surgery.*

Lateral pelvic lymph node metastasis is generally present in 17% of patients with T3 lower rectal cancer (1-3). As such, lymph node metastases cannot be detected accurately before surgery, nerve-sparing surgery with lateral pelvic lymph node dissection (LPLD) has been regarded as part of the standard operation for advanced lower rectal cancer in many Japanese Institutions (4, 5). Recently, neoadjuvant chemoradiation therapy has also been performed to avoid sexual or urinary dysfunction by LPLD (6,7). If all patients with T3 lower rectal cancer underwent LPLD or neoadjuvant chemoradiation therapy, more than 80% of patients with no lateral pelvic lymph node metastasis would receive unnecessary treatments. Since 2001, we have performed sentinel node navigation surgery in patients with T3 lower rectal cancer, considering lymph nodes located between the vesicohypogastric fascia and the pelvic nerve plexus as the lateral sentinel lymph node (LSN). The aim of our study was to evaluate the validity of the LSN for the indication of LPLD for patients with T3 lower rectal cancer.

Correspondence to: Hidejiro Kawahara, M.D., Ph.D., Department of Surgery, Kashiwa Hospital, Jikei University School of Medicine, 163-1 Kashiwashita, Kashiwashi, Chiba 277-8567, Japan. Tel: +81 471641111 Ext. 3428, Fax: +81 471633488, e-mail: kawahide@jikei.ac.jp

Key Words: Lower rectal cancer, lateral pelvic dissection, laparoscopic surgery, sentinel lymph node.

Patients and Methods

Patients' eligibility. The Ethics Committee for Biomedical Research of the Jikei Institutional Review Board approved the protocol [26-035 (7540)] and all patients provided their written informed consent. All patients in this prospective study met the following eligibility criteria: Patients with colorectal cancer without distant metastasis or peritoneal dissemination who were able to undergo curative resection, an operation termed R0, as defined by the guidelines of the Japanese Classification of Colorectal Carcinoma (8); sufficient preoperative oral intake; and were between 30 and 80 years old. Patients with a history of serious surgical or non-surgical complications were excluded. Pregnant or lactating women were also excluded. Pathological examination was performed according to the Japanese guideline (8).

All patients were evaluated by chest x-ray, ultrasonography, computed tomographic (CT) scan, magnetic resonance imaging (MRI), and colonoscopy to determine the clinical diagnosis and staging. No patient had received chemoradiation therapy before surgery. The patients with stage II disease received no adjuvant chemotherapy. The patients with stage III disease were given oral anticancer drugs after surgery, such as S-1 (Taiho Pharmaceuticals Co. Ltd., Tokyo, Japan) or capecitabine (Xeloda; Hoffmann-La Roche, Basel, Switzerland) for six months or longer.

A total of 101 patients with T3 lower rectal cancer were enrolled in this study between January 2001 and December 2010 at the Department of Surgery, Kashiwa Hospital, Jikei University School of Medicine. They consisted of 65 males and 36 females, with a

Table I. *Clinicopathological features of the patients.*

Characteristic	No. of patients
Gender, n (%)	
Male	65 (64)
Female	36 (36)
Median age (range), years	65 (29-80)
Median tumor diameter (range), mm	54 (20-120)
Surgical procedure, n (%)	
Low anterior resection	47 (47)
Intersphincteric resection	5 (5)
Abdominoperineal resection	49 (48)
Open or laparoscopic sugery, n (%)	
Open	84 (83)
Laparoscopic	17 (17)
Pathological tumor staging, n (%)	
II	53 (52)
III	48 (48)
Histological differentiationn (%)	
Well	40 (40)
Moderately	57 (56)
Poorly	4 (4)

Well: Well-differentiated adenocarcinoma; moderately: moderately defferentiated adenocarcinama; poorly: poorly defferentiated adenocarcinoma.

Table II. *Comparison clinicopathological features by metastasis to lateral pelvic node (LPLN).*

	LPLN		
	Positive	Negative	
Variable	n=8	n=93	*p*-Value
Gender, n (%)			0.787
Male	5 (63)	60 (65)	
Female	3 (37)	33 (35)	
Median age (range), years	52 (33-74)	65 (29-80)	0.057
Median tumor diameter (range), mm	50 (30-80)	55 (14-120)	0.748
Histological differentiation, n (%)			0.787
Well	1 (13)	39 (42)	
Modelately	7 (87)	50 (54)	
Poorly	0 (0)	4 (4)	
Lymph nodes in the mesorectum, n (%)			0.006
Positive	8 (100)	40 (43)	
Negative	0 (0)	53 (57)	
Lateral sentienl lymph node		<	<0.001
Positive	8 (100)	0 (0)	
Negative	0 (0)	93 (100)	

Well: Well-differentiated adenocarcinoma; moderately: moderately defferentiated adenocarcinama; poorly: poorly defferentiated adenocarcinoma.

median age of 65 (range=29-80) years. Fifty-three patients had stage II disease, and the remaining 48 stage III.

Intraoperative analysis for lymph nodes. After total mesorectal excision (TME), the patients without mesorectum lymph node metastasis underwent only LSN dissection in the lateral pelvic space (Figure 1). Patients with a metastatic LSN underwent LPLD, whereas patients with a metastasis-free LSN did not undergo further dissection. Patients with metastatic lymph nodes detected in their mesorectum underwent LPLD including the LSN. With regard to the intraoperative diagnosis of lymph node involvement in the mesorectum, lymph nodes of more than 5-mm in diameter with a hard consistency were judged as metastases. If lymph nodes of less than 5-mm in diameter were suspected to be metastatic, they were evaluated by frozen section examination. All LSNs were evaluated by frozen section examination for metastasis during operation.

Surgical techniques for dissection of the LSN. After TME with preservation of the left colic artery and dissection around the inferior mesenteric artery, the root of the superior vesical artery originating from the internal iliac artery was identified. The areolar tissue between the vesicohypogastric fascia and the pelvic nerve plexus were defined as the lateral sentinel lymphatic basin (LSLB), which was mobilized from the medial side of the internal iliac artery between the root of superior vesical artery and the Alcock orifice. They were subsequently detached from the pelvic nerve plexus. With this procedure, mobilization of the ureters is not required.

Surgical technique of LPD. After TME with preservation of the left colic artery and dissection around the inferior mesenteric artery, lymph nodes along the common iliac vessels, internal iliac vessels and middle rectal vessels, and between the external and internal iliac vessels were removed by sharp dissection using scissors or diathermy. If necessary, an aspiration procedure was added for complete removal of the areolar tissue surrounding vessels (9). Essentially, the hypogastric nerve and the pelvic nerve plexus are preserved.

Analysis of recurrence and survival. Follow-up consisted of regular evaluations that included monitoring of serum carcinoembryonic antigen (CEA) levels every three months, a CT every six months, and a colonoscopy every 12 months to look for local recurrence and distant metastasis.

Statistical analysis. All data were analyzed using the Statistical Package for Social Sciences, SPSS 22.0, (IBM SPSS, Tokyo, Japan). Statistical significance was determined using the Mann-Whitney *U*-test and the Chi-square test. A *p*-value of less than 0.05 indicates significance.

Results

Clinicopathological features of the patients. Clinicopathological features are shown in Table I). Intraoperative diagnosis of lymph node metastasis in the mesorectum by our criteria completely accorded with the diagnosis by postoperative pathological examination using hematoxylin-eosin (HE) staining. Additionally, in all patients, intraoperative diagnosis of LSN

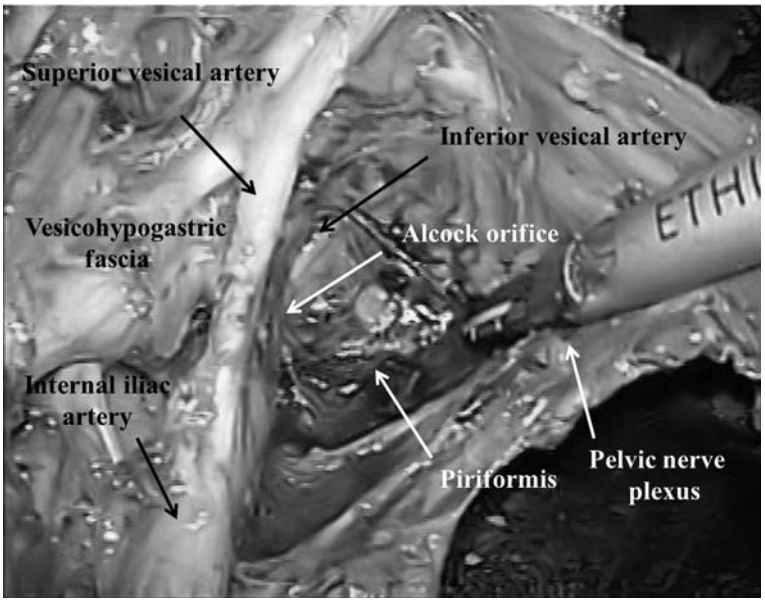

Figure 1. *Intraoperative view of the left side of the lateral pelvic space after lateral sentinel node dissection.*

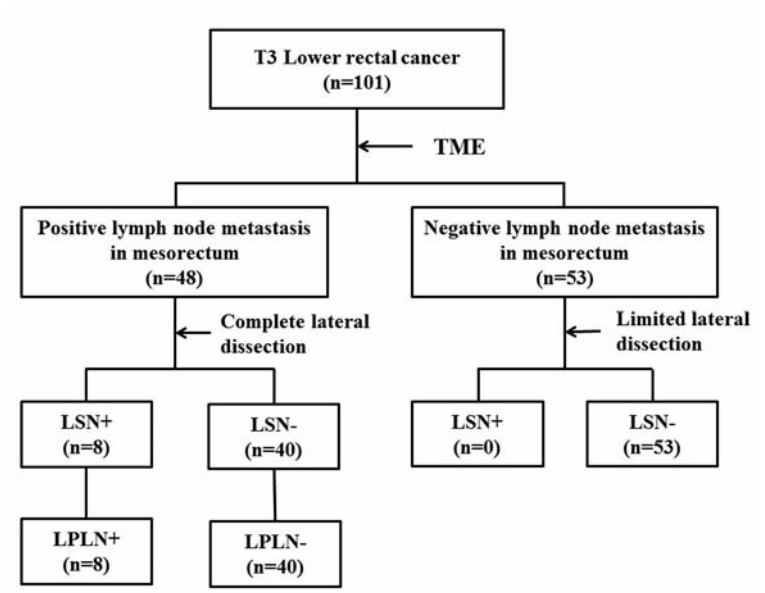

Figure 2. *Flowchart of this study. Only the eight patients with positive lateral sentinel lymph nodes had positive lymph nodes in the lateral pelvic space, with a sensitivity and specificity of 100% each.*

metastasis using frozen section examination was confirmed by postoperative pathological diagnosis using HE staining.

The status of lymph node metastasis. After TME, fifty-three out of the 101 patients were judged to have negative lymph nodes in the mesorectum and negative LSN (Figure 2), which were confirmed by postoperative permanent pathological diagnosis. The other 48 patients with positive lymph nodes in the mesorectum who underwent LPLD were further divided into two subgroups, 40 with a negative and eight with a positive LSN. Lymph nodes in the lateral pelvic space were positive in only the eight patients with a positive LSN.

Comparison of clinicopathological features by lateral lymph node metastasis. Only eight patients (7.9%) had lateral lymph nodes metastasis in the present study (Table II). A significant

Table III. *Characteristics of patents with lateral pelvic lymph node metastasis.*

	Case no.							
Characteristic	1	2	3	4	5	6	7	8
Gender	Male	Female	Male	Male	Male	Female	Male	Female
Age, years	74	53	51	46	61	33	43	70
Tumor diameter, mm	80	70	50	45	50	30	70	42
Surgical procedure	APR	APR	APR	APR	ISR	APR	ISR	APR
Histological differentiation	mod	mod	mod	wel	mod	mod	mod	mod
Positive lymph node numbers								
In mesorectum	2	1	3	1	3	3	2	6
In lateral pelvic space	2	2	1	1	1	1	1	2
Site of recurence								
Distant metastasis	Negative	Negative	Negative	Negative	Negative	Negative	Positive	Positive
Local recurrence	Negative	Negative	Negative	Negative	Negative	Negative	Negative	Negative

APR: Abdominoperineal resection; ISR: internalsphincteric resection; well: well-differentiated adnocarcinoma; mode: moderately differentiated adenocarcinoma.

differences was found in the status of lymph nodes in the mesorectum and LSN. Forty out of the 48 patients (83%) with lymph node metastasis in the mesorectum had no lymph node metastasis in the LPLN. In contrast, complete accordance was observed between metastasis in the LSN and LPLN in this small sample size study.

Characteristics of patients with lateral pelvic lymph node metastasis. The characteristics of the eight patients with lateral pelvic lymph node metastasis are shown in Table III. All patients had up to two lymph node metastases in the lateral pelvic space. Two of these patients developed liver metastasis. None of the patients in this study developed local recurrence.

Discussion

TME, which was developed and popularized by Heald (10-12) is currently the standard treatment for patients with rectal cancer. The lymphatic drainage of the upper and middle rectum is predominantly associated with spread along the perirectal vessels originating from the inferior mesenteric artery to perirectal nodes and is opportunely contained within the mesorectal fascia (13). TME-alone is associated with a good prognosis in patients with upper and middle rectal cancer. In contrast, the lower rectum has been shown to drain both upwards along the superior rectal vessels and laterally along the middle rectal vessels and then to the internal iliac vessels (14, 15). The incidence of lateral nodal involvement has been reported to be approximately 20% in patients with T3 or 4 lower rectal cancer at or below the peritoneal reflection, not only in Japan but also in other countries (16, 17). TME cannot remove lymph nodes located in the lateral pelvic space outside the mesorectal envelope. Many Japanese surgeons have persisted in performing LPLD in order to reduce local recurrence and improve the outcome of lower rectal cancer (1-5). There is a long-standing controversy as to whether involved pelvic nodes represent systemic disease, M1 as suggested by the TNM classification (18), or localized disease, N3, as outlined in the Japanese guideline (8). Recently, some reports suggested that patients with fewer than three positive lateral lymph node metastases, as detected by LPLD, may have good outcomes (9, 19). Even if these patients have lateral nodal involvement, they might not develop systemic disease. Therefore, we have found limited benefit from using LPLD because of the poor outcome and high morbidity associated with the procedure. The time has come to reconsider the indications for LPLD seriously to avoid unnecessary LPLD or neoadjuvant chemoradiation therapy.

Which mesorectal lymph nodes are involved can be accurately diagnosed during surgery and has been reported as one of the factors that predict lateral nodal involvement (3, 20). In the present study, forty out of the 48 patients (83%) with lymph node metastasis in the mesorectum had no lymph node metastasis in the lateral pelvic space. If all patients with positive lymph node in the mesorectum had to undergo LPLD, more than 80% of patients would have been subjected to unnecessary dissection. In contrast, the sensitivity and specificity of lateral lymph node metastasis prediction by LSN in this study was 100%. In 2007, we reported that the first lateral lymph node that receives lymphatic drainage from lower rectal cancer is located between the vesicohypogastric fascia and the pelvic nerve plexus by infrared ray electronic endoscopy with indocyanine green as a tracer (15). Such lymph nodes may be considered for the LSN. Patients with T3 lower rectal cancer with negative LSNs may not require LPLD because the LSN is highly likely to be the sentinel lymph node, which needs to be proven by a prospective study with a large number of patients.

Conflicts of Interest

The Authors have no conflicts of interest.

References

1 Moriya Y, Hojo K, Sawada T and Koyama Y: Significance of lateral node dissection for advanced rectal carcinoma at or below the peritoneal reflection. Dis Colon Rectum 32: 307-315, 1989.

2 Takahashi T, Ueno M, Azekura K and Ohta H: Lateral node dissection and total mesorectal excision for rectal cancer. Dis Colon Rectum *43(suppl)*; S59-S68, 2000.

3 Ueno M, Oya M, Azekura K, Yamaguchi T and Muto T: Incidence and prognostic significance of lateral lymph node metastasis in patients with advanced low rectal cancer. Br J Surg *92*: 756-763, 2005.

4 Moriya Y, Sugihara K, Akasu T and Fujita S: Nerve-sparing surgery with lateral node dissection for advanced lower rectal cancer. Eur J Cancer *31A*: 1229-1232, 1995.

5 Surgihara K, Moriya Y, Akasu T and Fujita S. Pelvic autonomic nerve preservation for patients with rectal carcinoma: oncologic and functional outcome. Cancer *78*: 1871-1880, 1996.

6 Cedermark B, Johansson H, Rutqvist LE and Wilking N: The Stockholm I trial of preoperative short term radiotherapy in operable rectal carcinoma: a prospective randomized trial. Stockholm Colorectal Cancer Study Group. Cancer *75*: 2269-2275, 1995.

7 Martling A, Holm T, Johansson H, Rutqvist LE, Cedermark B and Stockholm Colorectal Study Group: The Stockholm II trial on preoperative radiotherapy in rectal carcinoma: long-term follow-up of a population-based study. Cancer *92*: 896-902, 2001.

8 Japanese Society for Cancer of the Colon and Rectum: Japanese Classification of Colorectal Carcinoma. Second English Edition. Kanehara Co Ltd, Tokyo, 2009.

9 Kawahara H, Watanabe K, Ushigome T, Yanagisawa S, Kabayashi S and Yanaga K: Lateral pelvic lymph node dissection using latero-vesical approach with aspiration procedure for advanced lower rectal cancer. Hepatogastroenterology *59*: 116-9.1136-1138, 2012.

10 Heald RJ, Husband EM and Ryall RD: The mesorectum in rectal cancer surgery: the clue to pelvic recurrence? Br J Surg *69*: 613-616, 1982.

11 Heald RJ: The 'Holy Plane' of rectal surgery. J Royal Soc Med *81*: 503-508, 1988.

12 MacFarlane JK, Ryall RD and Heald RJ: Mesorectal excision for rectal cancer. Lancet *341*: 457-460, 1993.

13 Heald RJ and Moran BJ. Embryology and anatomy of the rectum. Semin Surg Oncol *15*: 66-71, 1998.

14 Funahashi K, Koike J, Shimada M, Okamoto K, Goto T and Teramoto T: A preliminary study of the draining lymph node basin in advanced lower rectal cancer using a radioactive tracer. Dis Colon Rectum *49(suppl)*: S53-S58, 2006.

15 Kawahara H, Nimura H, Watanabe K, Kobayashi T, Kashiwagi H and Yanaga K: Where does the first lateral pelvic lymph node receive drainage from? Dig Surg *24*: 413-417, 2007.

16 Japanese Society for Cancer of the Colon and Rectum: General Rules for Clinical and Pathological Studies on Cancer of the Colon, Rectum and Anus (Seventh Edition). Kaenhara: Tokyo, 2006.

17 Quadros CA, Lopes A, Araujo I, Fahel F, Bacellar MS and Dias CS: Retroperitoneal and lateral pelvic lymphadenectomy mapped by lymphoscintigraphy and blue dye for rectal adenocarcinoma staging: preliminary results. Ann Surg Oncol *13*: 1617-1621, 2006.

18 Sobin LH and Wittekind C (eds.): International Union Against Cancer: TNM Classification of Malignant Tumours (Six Edition). Wiley-Liss: New York, 2002.

19 Homma Y, Hamano T, Otsuki Y, Shimizu S and Kobayashi Y: The total number of lymph node metastases is a more significant risk factor for poor prognosis than positive lateral lymph node metastasis. Surg Today *44*: 1084-1089, 2015.

20 Sugihara K, Kobayashi H, Kato T, Mori T, Mochizuki H, Kameoka S, Shirouzu K and Muto T: Indication and benefit of pelvic sidewall dissection for rectal cancer. Dis Colon Rectum *49*: 1663-1672, 2006.

Received February 11, 2015
Revised February 24, 2015
Accepted February 26, 2015