

Assessment of Planning Target Volume Margin for a Small Number of Vertebral Metastatic Lesions Using Image-guided Intensity-modulated Radiation Therapy by Helical Tomotherapy

TAKUYA NISHIMURA¹, HIDEYA YAMAZAKI^{1,2}, KAZUKI IWAMA¹, TOMOYA KOTANI³,
YOSHITAKA OOTA², HIRONORI AIBE^{1,2}, SATOAKI NAKAMURA^{1,2},
HIROYASU IKENO², KEN YOSHIDA⁴, FUMIAKI ISOHASHI⁵ and HARUUMI OKABE¹

¹Department of Radiology, Ujitakeda Hospital, Uji-city, Kyoto, Japan;

²Department of Radiology, Graduate School of Medical Science,
Kyoto Prefectural University of Medicine, Kamigyo-ku, Kyoto, Japan;

³Department of Radiology, Matsushita Memorial Hospital, Moriguchi-city, Osaka, Japan;

⁴Department of Radiology, Osaka Medical College, Takatsuki-City, Osaka, Japan;

⁵Department of Radiation Oncology, Osaka University Graduate School of Medicine, Suita, Osaka, Japan

Abstract. *Aim:* To evaluate an appropriate planning target volume (PTV) margin in for one to three vertebral metastases using megavolt computed tomography (MVCT) images during the course of image-guided and stereotactic intensity-modulated radiotherapy (IGRT-IMRT) by use of helical tomotherapy. *Patients and Methods:* A total of 25 lesions in 24 patients with vertebral metastases who received IGRT-IMRT were analyzed. MVCT images were acquired before and after radiation therapy. Intra-fractional movement and PTV margin were calculated by comparing treatment planning images and these 310 MVCT images for right-left (RL), superior-inferior (SI), and anteroposterior (AP) dimensions. Five patients were treated by 35 Gy/5 fractions, 17 by 30 Gy/5 fractions, one by 25 Gy/5 fractions, and one by 60 Gy/30 fractions. A margin to compensate for these variations was calculated with the formula of vanHerck's equation. *Results:* The intra-fractional motion was 0.02 (−1.3 to 1.4) ± 0.34 mm in the RL direction, −0.09 (−1.8 to 0.28) ± 0.44 mm in the SI direction, and 0.20 (−1.8 to 1.8) ± 0.36 mm in the AP direction. The required PTV margin was 0.98 mm in the RL direction, 0.69 mm in the SI direction, and 1.26 mm in the AP direction. No patient showed a deviation greater than 2 mm. *Conclusion:* The PTV margin

in hypofractionated IGRT-IMRT, using helical tomotherapy for a few vertebral metastases, was 2 mm or less and our tentative PTV margin of 5 mm was sufficient and reducible.

Radiation therapy is a common and effective treatment modality for managing skeletal metastases. The possible irradiated dose to vertebral metastases is limited for tumors located near the spinal cord when conventional external beam techniques are used. Recent advances in technology have improved the therapeutic threshold, permitting delivery of an ablative radiation dose using an image-guided stereotactic approach (1). In addition, in the era of modern radiotherapy techniques, the planned target volume (PTV) to vertebral metastases can be reduced by precise positioning, *i.e.* by image-guided and stereotactic intensity-modulated radiotherapy (IGRT-IMRT) (2). Because helical tomotherapy has the ability to acquire megavoltage computed tomographic (MVCT) images of a patient in the treatment position before each treatment, daily imaging can minimize daily positional uncertainties (2). This precise positioning allows the PTV to be reduced, directly improving conformal avoidance of nearby critical structures. Therefore, we initiated an assessment of the required PTV margin in IGRT-IMRT for a few vertebral metastases using helical tomotherapy.

Patients and Methods

We evaluated 25 lesions in 24 patients with one to three vertebral metastases who received IGRT-IMRT using helical tomotherapy (HI-ART TomoTherapy Inc., Madison, WI, USA) between December 2007 and February 2009. Patient characteristic are shown in Table I. One patient was treated for cervical and lumber spine twice. Vacuum cushions (Blue Bag, Medical Intelligence, Schwabmünchen, Germany) were used to immobilize the patients

Correspondence to: Hideya Yamazaki, MD, Department of Radiology, Kyoto Prefectural University of Medicine, 465 Kajicho Kawaramachi Hirokoji, Kamigyo-ku, Kyoto, Kyoto 602-8566 Japan. Tel: +81 752515618, Fax: +81 752515840, e-mail: hideya10@hotmail.com

Key Words: Tomotherapy, vertebral body metastases, stereotactic body radiotherapy, PTV margin, image-guided IMRT.

in a supine position. Custom Aquaplast masks (WFR Aquaplast, Inc., Avondale, PA, USA) were also used to immobilize the patients with cervical spine targets.

Kilovoltage CT images were acquired for each patient (2-mm slice thickness) at least 5 cm above and below the level of PTV. The spinal cord was defined as an organ at risk. The gross tumor volume was contoured; the vertebral body was contoured as a clinical target volume (CTV), which was expanded into the PTV by adding a uniform 5-mm margin around the CTV and subtracting the cord volume at risk. The dose was set as D95: 95% of the PTV was to receive the prescribed dose. Five patients were treated by 35 Gy/5 fractions, 17 by 30 Gy/5 fractions, one by 25 Gy/5 fractions, and one by 60 Gy/30 fractions. The maximum dose to the spinal cord was set with the highest inverse priority so that the total cord dose did not exceed 50 Gy ($BED_{2Gy} = n \times d \times (\alpha/\beta + d)/(\alpha/\beta + 2)$, where BED =biological equivalent dose, n =number of fractions, d =fraction dose, and $\alpha/\beta=2$). The patients were then positioned for each delivery fraction on the HI-ART table and aligned using wall-mounted lasers.

MVCT using 3.5-MV energy images were acquired through PTV before treatment delivery with the minimum slice thickness (4 mm) and field of view (35 cm). The first MVCT images were taken and autofused with the kV CT treatment planning images, and the superior–inferior (SI), anterior–posterior (AP), and right–left (RL) shifts were calculated by automatic image fusion and then manually verified and corrected by two of the authors (rotational corrections were not implemented at the time of this study). The patients were then shifted along calculated couch translations. For the initial 12 lesions of 11 patients, MVCT (second MVCT) images were acquired to verify that the shifts were correctly applied. The images were manually inspected by two of the authors, and the patients were then re-adjusted (if necessary) and treated. The third MVCT image was taken to assess intrafractional organ motion after radiation therapy. The total time between image acquisition and treatment delivery was typically less than 10 min. Intrafractional movement was calculated by comparing the second and third MVCT images. The second MVCT images were omitted because little displacement (<1 mm) was found between the second MVCT image and the expected location by the shifts applied. Thereafter, the first and third MVCT images were used to calculate intrafractional organ motion in the subsequent 13 lesions in 13 patients. Intrafractional movement was calculated by comparing the expected location by the shifts applied to the first and third MVCT image locations. vanHerck’s formula ($2.5\Sigma + 0.7\sigma$, where Σ and σ were systematic and random positioning errors, respectively) was used to calculate the PTV margin to compensate for these variations (3).

Results

Five patients were treated with 35 Gy/5 fractions, 17 by 30 Gy/5 fractions, one by 25 Gy/5 fractions, and one by 60 Gy/30 fractions. In each patient, five fractions were examined by repeated MVCT, and the 310 MVCT images were analyzed for deviations. Intrafractional motion was 0.02 mm (–1.3 to 1.4 mm) ± 0.34 mm in the RL direction (right direction regarded as positive), –0.09 mm (–1.8 mm to 0.28 mm) ± 0.44 mm in the SI direction (superior direction regarded as positive), 0.20 mm (–1.8 mm to 1.8 mm) ± 0.36 mm in the AP direction (anterior direction regarded as positive). In

Table I. Patients’ characteristics.

		Range
Age	Median: 67	51-88
Gender	M:F	19:5
Disease	Lung cancer	7
	Bile duct cancer	1
	Prostate cancer	2
	Pancreatic cancer	1
	Renal cell cancer	2
	Esophageal cancer	2
	Thyroid cancer	1
	Chondrosarcoma	1
	Stomach cancer	1
	Colon cancer	2
	Breast cancer	3
	Hepatocellular cancer	1
No. of lesions	1	13
	2	6
	3	6
Location	Cervical spine	3
	Thoracic spine	12
	Lumber spine	10
Dose	30 Gy/5 fr	17
	35 Gy/5 fr	5
	25 Gy/5 fr	1
	60 Gy/30 fr	1

detail, the intrafractional motions in the RL, SI, and AP directions for the cervical spine were 0.3 mm ± 0.38 mm, –0.05 mm ± 0.37 mm, and –0.44 mm ± 0.56 mm, respectively; for the thoracic spine, 0.02 mm ± 0.30 mm, –0.17 mm ± 0.47 mm, and 0.24 mm ± 0.40 mm, respectively; and for the lumber spine, –0.17 mm ± 0.23 mm, 0.14 mm ± 0.34 mm, and 0.25 mm ± 0.23 mm, respectively. No patient showed a deviation greater than 2 mm (Figure 1). Therefore, the required PTV margin was 0.98 mm in the RL direction, 0.69 mm in the SI direction, and 1.26 mm in the AP direction. All patients were treated without any adverse effects.

Discussion

In contrast to the relatively disappointing outcomes reported with conventional fractionation or low-dose single-fraction radiotherapy, high-dose single or fractionated radiation therapy was shown to be highly effective in the palliation of metastatic spinal cord tumors (4). Gerszten and Welch reported on 500 patients with paraspinal lesions treated with 12-25 Gy (maximal intratumoral dose) single-fraction radiation therapy (5). Stereotactic radiosurgery was the primary treatment modality for the spinal lesions in 65 patients. The control of symptoms was excellent; 86% of the patients reported decrease in pain and 90% were reported to

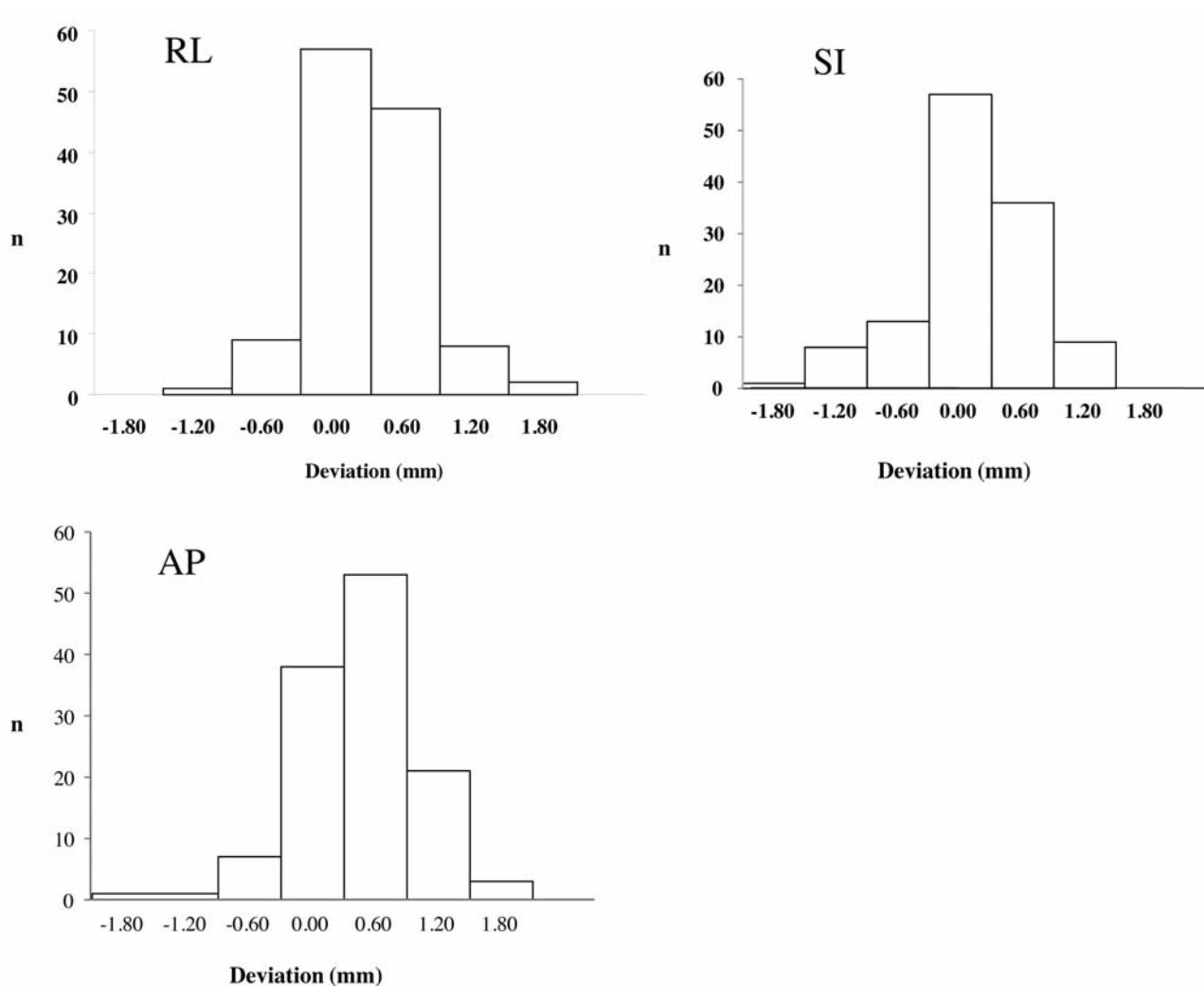


Figure 1. Distribution of intra-fractional motion. No patient showed deviation larger than 2 mm. AP: Anterior–posterior; RL: right–left; SL: superior–inferior.

have local control. Toxicity was minimal, including no treatment-related myelopathy. Similar favorable results have also been reported by several others (6-9). Following those results, we initiated IGRT–IMRT in patients with a few vertebral metastases.

Hyde *et al.* reported that the absolute intra-fractional motion averaged over all directions along the x, y, and z axes (SD) were 0.7 ± 0.5 mm and 0.5 ± 0.4 mm for the 1.5- and 1-mm tolerances, respectively. On the basis of a 1-mm and 1 correction threshold, the target was localized to within 1.2 mm and 0.9 mm, respectively, with 95% confidence using Cyberknife (10). These values are consistent with our results. Mahan *et al.* reported that anthropomorphic phantom studies indicated that MVCT images in tomotherapy were capable of imaging the spine with sufficient accuracy to place the

isocenter within 1 mm of the desired position (2). Our results showed that the required maximal PTV margin was 1.26 mm in the AP direction. Therefore 2.26 mm margin ($1.26 + 1$ mm) for the PTV is enough to compensate for image ambiguity.

One of the limitations of this study was that we applied vanHerk's equation because it is a widely known formula for conventional multifractionation radiotherapy, although here it was used for hypofractionated stereotactic radiation therapy. Even so, no patient showed a deviation greater than 2 mm; thus, our tentative 5-mm PTV margin was sufficient for IGRT–IMRT for cases with few vertebral metastases.

In conclusion, the PTV margin in hypofractionated IGRT–IMRT using helical tomotherapy for a few vertebral metastases could be 2 mm or less. Our tentative PTV margin of 5 mm was sufficient and reducible, if required.

References

- 1 Hall WA, Stapleford LJ, Hadjipanayis CG, Curran WJ, Crocker I and Shu HK: Stereotactic body radiosurgery for spinal metastatic disease: an evidence-based review. *Int J Surg Oncol* 2011; 979214, 2011.
- 2 Mahan SL, Ramsey CR, Scaperoth DD, Chase DJ and Byrne TE: Evaluation of image-guided helical tomotherapy for the retreatment of spinal metastasis. *Int J Radiat Oncol Biol Phys* 63: 1576-1583, 2005.
- 3 Yamada Y, Bilsky MH, Lovelock DM, Venkatraman ES, Toner S, Johnson J, Zatzky J, Zelefsky MJ and Fuks Z: High-dose, single-fraction image-guided intensity-modulated radiotherapy for metastatic spinal lesions. *Int J Radiat Oncol Biol Phys* 71: 484-490, 2008.
- 4 van Herk M: Errors and margins in radiotherapy. *Semin Radiat Oncol* 14: 52-64, 2004.
- 5 Gerszten PC, Burton SA, Belani CP, Ramalingam S, Friedland DM, Ozhasoglu C, Quinn AE, McCue KJ, Welch WC: Radiosurgery for spinal metastases: Clinical experience in 500 cases from a single institution. *Spine* 32: 193-199, 2007.
- 6 Gibbs IC, Kammerdsupaphon P, Ryu MR, Dodd R, Kiernan M, Chang SD and Adler JR Jr.: Image-guided robotic radiosurgery for spinal metastases. *Radiother Oncol* 82: 185-190, 2007.
- 7 Chang EL, Shiu AS, Mendel E, Mathews LA, Mahajan A, Allen PK, Weinberg JS, Brown BW, Wang XS, Woo SY, Cleeland C, Maor MH and Rhines LD: Phase I/II study of stereotactic body radiotherapy for spinal metastasis and its pattern of failure. *J Neurosurg Spine* 7: 151-160, 2007.
- 8 Nieder C, Grosu AL, Andratschke NH and Molls M: Update of human spinal cord reirradiation tolerance based on additional data from 38 patients. *Int J Radiat Oncol Biol Phys* 66: 1446-1449, 2006.
- 9 Rades D, Stalpers LJ, Veninga T and Hoskin PJ: Spinal reirradiation after short-course RT for metastatic spinal cord compression. *Int J Radiat Oncol Biol Phys* 63: 872-875, 2005.
- 10 Hyde D, Lochray F, Korol R, Davidson M, Wong CS, Ma L and Sahgal A: Spine stereotactic body radiotherapy utilizing cone-beam CT image-guidance with a robotic couch: Intrafraction motion analysis accounting for all six degrees of freedom. *Int J Radiat Oncol Biol Phys* 82: e555-562, 2012.

Received March 12, 2013

Revised May 2, 2013

Accepted May 8, 2013