HE4 Tissue Expression in Borderline Ovarian Tumors: A Pilot Study by the Tumorbank Ovarian Cancer Network

MANI NASSIR[1], SILVIA DARB-ESFAHANI[2], ROLF RICHTER[1], RADOSLAV CHEKEROV[1], CHRISTINA HALL[3], MUSTAFA ZELAL MUALLEM[1], CARSTEN DENKERT[2], FLORIN STAMATIAN[4], CHRISTINA FOTOPOULOU[1], JALID SEHOULI[1] and ELENA IOANA BRAICU[1]

[1]*Department of Gynecology, Virchow Campus Clinic and* [2]*Institute of Pathology, Mitte Campus, Charité Medical University Berlin, Berlin, Germany;*
[3]*Fujirebio Diagnostics AB, Goteborg, Sweden;*
[4]*Department for Obstetrics and Gynecology, Iuliu Hatieganu Medical University, Cluj-Napoca, Romania*

Abstract. *Aim: Our purpose was to analyze the tissue expression of human epididymis protein-4 (HE4) in borderline tumors of the ovary (BOT) and to correlate it with histological subtypes and clinical features. Patients and Methods: Tumor tissue samples from 25 patients with BOT were stained on tissue microarrays. The percentage of stained tumor cells was represented by grouped immunoreactivity scores (IRS) 0 to 4. Results: The median patient age was 47 (range=22-73) years. Tumors in most patients (19/25) were staged-FIGO I and presented serous (52%) or mucinous (40%) histology. HE4 immunoreactivity occurred exclusively within the tumor cells. No association between grouped IRS and histological type, age, CA125 and FIGO stage was found. Correlation between HE4 positivity cells and HE4 IRS was significant (p<0.001). Conclusion: The role of HE4 in BOT remains unclear. Multicenter surveys are needed to more profoundly help in the understanding of the biological and clinical features of BOT.*

Borderline tumors (BOT) account for 8-10% of all ovarian neoplasms (1). They constitute an entirely separate tumor entity, requiring expert treatment and long-term follow-up. They usually present in early FIGO I stages and are generally associated with an excellent overall prognosis. Hence, they are also considered to be tumors of low malignant potential (2). The only negative prognostic impact identified was, however, the presence of invasive peritoneal implants, which reduces the survival rate to 30-50% (1, 3). Due to the rarity of the disease, the clinicopathological characteristics and pathological features are not well-described and many factors remain to constitute a therapeutic dilemma in terms of accurate diagnosis, surgical management and follow-up. In particular, the preoperative discrimination between borderline and malignant tumors is very often a challenge.

The measurement of cancer antigen 125 (CA125) is an important and widely-used component in the clinical management of patients with an ovarian mass. Nevertheless, its utility remains restricted due to its low specificity, especially in pre-menopausal women, in whom it is also elevated in common benign lesions such as endometriosis, follicular cysts, cystadenoma, tuboovarian abscess and pregnancy (4-6). In addition, raised CA125 concentrations, are also found in various gastrointestinal malignancies, especially in cases of metastatic disease (7).

Human epididymis protein-4 (HE4) is a glycoprotein that is expressed in normal tissues of the reproductive and respiratory tract. It is overexpressed in serous and endometrioid ovarian carcinomas and can easily be measured in the bloodstream (8). HE4 has greater sensitivity and specificity for the detection of ovarian cancer and has a better potential for the differentiation of benign from malignant ovarian tumors than CA125 (9, 10). The recently established Risk of Ovarian Malignancy Algorithm (*ROMA*) using the combination of CA125 and HE4 plus information concerning the patient's hormonal state (pre-menopausal *vs*. post-menopausal) has greater sensitivity for the prediction of ovarian cancer in patients with a pelvic tumour (11-13). Furthermore, the combination of HE4 and CA125 expression in plasma might contribute to the prediction of surgical outcome in patients with ovarian cancer (14). The use of HE4 in ovarian cancer is analyzed and discussed in several publications but its role in BOT has not been entirely clarified.

Holcomb *et al*. failed to identify any significant differences between serum HE4 levels in 195 patients with benign conditions and 16 patients suffering from BOT (37.9 pmol/l

Correspondence to: Mani Nassir, MD, Department of Gynecology, Campus Virchow Clinic, Charité Medical University Berlin, Augustenburger Platz 1, 13353 Berlin, Germany. Tel: +49 30450564047, Fax: +49 30450564939, e-mail: mani.nassir@ charite.de

Key Words: HE4, borderline ovarian tumors, ovarian cancer.

vs. 57.3 pmol/l, respectively) (9). Using a cut-off value of 70 pmol/l for HE4 and 35 U/ml for CA125, the authors showed there to be higher incidence of elevated CA125 levels in patients with BOT compared to HE4 levels (88% *vs*. 38%) (9). HE4 has been described to be elevated almost exclusively in patients with ovarian cancer and in benign conditions, including endometriosis (15). Like CA125, expression of HE4 is commonly found in serous and endometrioid subtypes but less often in the mucinous and clear cell-type (8, 10).

The aim of our study was to analyze the expression of HE4 in BOT tissue in the absence of any invasive implants. Furthermore, we sought to evaluate any possible correlation with histological subtypes, CA125 levels (cut-off value: 35 U/ml) and clinicopathological characteristics.

Patients and Methods

Patients. We identified 25 patients who underwent surgery due to BOT between 1996 and 2008 in the Charité Virchow Clinic of Berlin. Since BOT with invasive implants behave more like epithelial ovarian cancer and could therefore present inhomogeneous results, we assessed only patients without invasive implants.

Written informed consent was obtained from all participating patients before the operation and approval from the local Ethics Commission was gained (EK207/2003). Tissue samples were preserved during each operation and have been sent to the Institute of Pathology at Virchow Campus Clinic of the Charité Medical University Berlin for histopathological evaluation by an experienced gynecological pathologist.

HE4 immunohistochemical analysis. Immunohistochemical staining was performed on tissue microarrays (TMAs). For this purpose, representative tumor areas of primary BOT tissue samples were marked on the H&E-stained section. Two tissue cores of 1.5 mm diameter were punched from different areas of each sample using a tissue microarrayer (Beecher Instruments, Woodland, CA, USA) and were embedded in two new paraffin blocks.

Tissue slides were de-paraffinized and microwaved in 10 mM citrate buffer (pH 6.0) for 10 min. For antigen retrieval endogenous peroxidases were quenched by incubation in 3% H_2O_2 for 5 min. Slides were then incubated for 1 h at room temperature with monoclonal antibody 12A2 diluted to 5 μg/ml in phosphate buffered saline (PBS) (Gibco Life Technologies, Carlsbad, CA), 1% bovine serum albumin (BSA) (Fujirebio Diagnostics AB, Goteborg, Sweden). For visualization EnVision+ System-Horseradish Peroxidase (HRP) (Dako Cytomation, Glostrup, Denmark) was used according to the manufacturer's instructions. Slides were counterstained in hematoxylin (Dako Cytomation, Glostrup, Denmark), mounted and analyzed.

The TMAs were evaluated by an experienced gynecological pathologist. The percentage of stained tumor cells was scored as follows: 0%=0; 1-10%=1; 11-50%=2; 51-80%=3; 81-100%=4) and was multiplied by the scoring of the staining intensity (negative=0; weak=1; moderate=2; strong=3), resulting in a semi-quantitative immunoreactivity score (IRS) that ranged from 0 to 12.

Statistical analysis. All analyses were performed in a descriptive fashion. All results are presented in raw numbers, medians and ranges.

Table I. *Patients' characteristics*.

Parameter	N	%
Age		
median, range (years)		47 (22-73)
Histological type		
Serous	13	52
Mucinous	10	40
Seromucinous (endocervical-like)	1	4
Clear cell	1	4
FIGO stage		
IA	14	56
IC	5	21
IIA	1	4
IIIA	2	8
IIB	1	4
CA125		
median, range (U/ml)		30 (13-259)
Percentage of HE4-positive cells		
0% (score 0)	8	32
1-10% (score 1)	4	16
11-50% (score 2)	6	24
51-80% (score 3)	5	20
81-100% (score 4)	2	8
HE4 staining intensity		
Negative (score 0)	8	32,0
Weak (score 1)	4	16,0
Moderate (score 2)	13	52
Strong (score 3)	0	0
Immunoreactivity score (IRS)		
0	8	32
1	2	8
2	4	16
4	4	16
6	5	20
8	2	8
12	0	0
Grouped IRS		
0 (IRS 0)	8	32
1 (IRS 1-3)	6	24
2 (IRS 4-6)	9	36
3 (IRS 7-9)	2	8
4 (IRS 10-12)	0	0

In order to perform further analyses, the IRS were grouped as 0 (IRS 0), 1 (IRS 1-3), 2 (IRS 4-6), 3 (IRS 7-9) and 4 (IRS 10-12). The grouped IRS was correlated with age at initial diagnosis, CA125 levels in blood, histological type of BOT [serous, mucinous, seromucinous (endocervical-like), clear cell] and tumor stage according to the FIGO classification (16).

For the correlation of grouped IRS with age at initial diagnosis, CA125 levels in blood and FIGO stage, Kendall's *tau b* was applied.

The difference between histological types of BOT for grouped IRS was analyzed by using the Pearson's chi-squared test.

All tests were two-sided with $p<0.05$ considered to be statistically significant. All analyses were performed with IBM SPSS Statistics 19 (SPSS In., Chicago, IL).

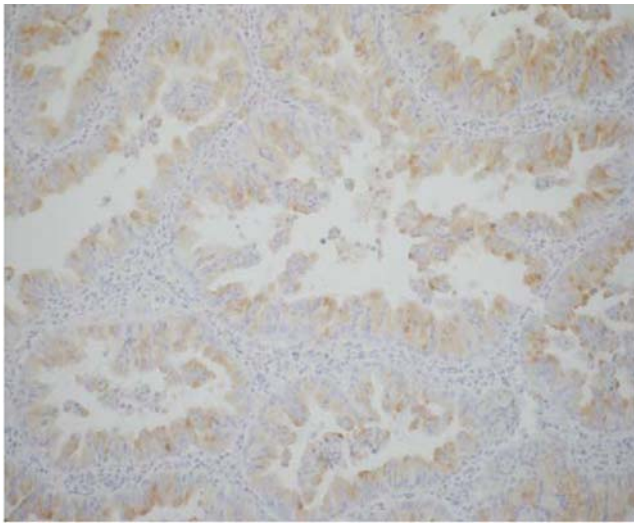

Figure 1. *A serous borderline ovarian tumor with moderate cytoplasmic expression of human epididymis protein-4 in the majority of the tumor cells.*

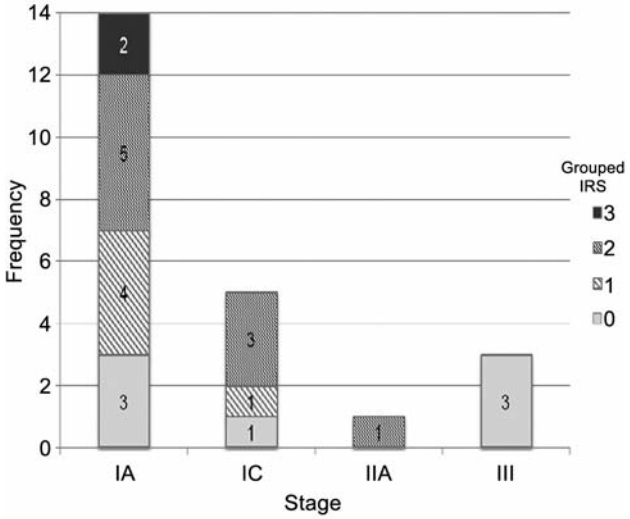

Figure 2. *Distribution of grouped IRS within different FIGO stages.*

Results

For the 25 patients included in this study, the median age at the date of first diagnosis was 47 (range=22-73) years. Thirteen patients (52%) had serous and 10 patients (40%) had mucinous borderline tumors, while only one (4%) patient presented with seromucinous (endocervical-like) and another (4%) with a clear cell histological type.

In 23 patients, the majority of tumors were stage I (19/25); in two (8%) cases, FIGO stage was unclear. The patients' characteristics are summarized in Table I.

If present, HE4 immunoreactivity was seen exclusively in tumor cells, not in stromal or inflammatory cells. Signals were localized to the cytoplasm and accentuated on the apical portion of the cells. In HE4-expressing tumors, intracystic secretions were also frequently positive (Figure 1).

The extent and distribution of HE4-positive stained cells, staining intensity scores and IRS of our cohort are also shown in Table I.

There was no association between the age at first diagnosis and grouped IRS (p=0.639).

No significant correlation between grouped IRS and histological type of BOT (p=0.701) was found. The frequency of the other two histological types – seromucinous (endocervical-like) and clear cell-type – was too low to draw conclusions. We also analyzed the association between grouped IRS and FIGO stage. The latter was known for 23 cases: 14 (60.87%) patients were grouped as IRS 1 and 2. Two patients (8.7%) were grouped as IRS 3 (Figure 2).

The correlation coefficient *tau b*=-0.25 (p=0.19) indicates a non-significant weak linear correlation between lower FIGO stage (I and II) and higher grouped IRS (2 and 3). Eleven cases (47.8%) out of 19 cases in FIGO stage I had higher grouped IRS (2 and 3), while there was no case of higher FIGO stage (III) associated with higher grouped IRS (2 and 3).

The correlation between grouped IRS (0 to 3) with CA125 concentration in blood was only weak and not significant (in both cases *tau b*=±0.347; p=0.14).

The correlation between HE4 rate positivity and HE4 IRS was significant (*tau b*=0.967; p<0.001).

Discussion

The primary purpose of this study was to analyze the pattern of HE4 tissue expression in different histological types of BOT. We further evaluated the association of HE4 expression with clinical factors that are known to be prognostic in ovarian cancer, notably age at date of initial diagnosis, FIGO tumor stage and CA125 levels in blood.

In the present study, we identified a relatively weak expression of HE4 in BOT patients with no invasive implants, with one third of them not expressing the marker at all, thus bringing into question the value of HE4 in the diagnosis and management of BOT.

Moore *et al*. noticed a significant increase in serum HE4 levels above the age of forty years in a cohort of 1,168 healthy women; they also found a significant difference in the serum HE4 levels in pre-menopausal compared to post-menopausal women (46.6 pmol/l *vs*. 57.6 pmol/l, respectively) (17).

In our survey, we did not find any significant correlation between HE4 tissue expression (which might also result in

higher serum concentrations) and patient age at the date of first diagnosis. In our study, HE4 expression and histological type of BOT were also not associated. There was almost no difference between serous and mucinous types concerning the rate of HE4 positivity, which is in concordance with findings in ovarian cancer. Among others, Drapkin and Van Gorp revealed high plasma levels of HE4 in ovarian cancer of the serous histological type (8, 18).

Our cohort demonstrated a weak linear correlation between a lower FIGO tumor stage and a higher expression of HE4 represented by higher grouped IRS 2 and 3, but this finding was non-significant and should be interpreted carefully due to the low number of cases. Furthermore, it is controversial considering the findings in OC patients: a study by Escudero *et al*. showed that both serum HE4 and CA125 levels are associated with the histological type and FIGO tumor stage in ovarian cancer, with lower concentrations in FIGO stage I and II, compared to FIGO stages III and IV (10). In contrast, Köbel *et al*. studied the expression of 21 tumor markers (including HE4) in different histological types of ovarian cancer, but no statistical significance difference in their expression in different FIGO stages was found (19).

Our study indicates that previous findings in invasive ovarian cancer research are not assignable to BOT *per se*. The main limitation of our study was the small number of cases. Due to the low incidence of BOT of only 1.8-4.8 out of 100,000 women per year (1), multicenter surveys are certainly needed. In order to increase the number of cohorts for both prospective and retrospective studies, university and tertiary clinics should be involved since they carry-out significantly higher rates of operations on BOT than smaller hospitals (1).

Among others, it was Steven G. Silverberg who critized the lack of information about the biology and clinical behaviour of BOT as early as 2004 (20). The number of publications in the field of BOT is not in general low, but there is still a scant amount of knowledge on adjuvant treatment and aftercare standards (21). To our knowledge, there is a lack of pre-existing detailed literature dealing with the role of HE4 tissue expression in BOT and its association with clinicopathological factors. The present study is one of the first steps to elucidate the role of HE4 tissue expression in BOT and should encourage a more profound and interdisciplinary view of this entity.

Since some recent studies suggest that BOT might be a pre-cancerous condition and might evolve to low-grade serous ovarian cancer (22), further investigations into the biology of BOT are crucial. Furthermore, regarding the importance of HE4 as a tumor marker in the management of patients with ovarian cancer and its upcoming broad use in clinical settings, this should encourage further investigations into HE4 in the field of BOT.

The present study has without any some limitations doubt, but provides an insight into the obstacles to be faced when dealing with BOT. It also raises the question whether HE4 tissue expression might be found in patients with BOT that present invasive implants. Due to the small number of such cases and hence the lack of a comparison group, this problem merits further studies and further investigations might contribute to the better understanding of the etiology of BOT itself.

Conflicts of Interest

The Authors stated that there are no conflicts of interest regarding the publication of this article.

The immunohistochemical analysis was partly performed by Fujirebio Diagnostics AB, Sweden. Christina Hall is an employee of Fujirebio Diagnostics AB in Sweden.

References

1 Coumbos A, Sehouli J, Chekerov R, Schaedel D, Oskay-Oezcelik G, Lichtenegger W, Kuehn W, North-Eastern German Society of Gynecological Oncology (NOGGO). Clinical management of borderline tumours of the ovary: results of a multicentre survey of 323 clinics in Germany, Br J Cancer *100(11)*: 1731-1738, 2009.

2 Serov SF, Scully RE and Sobin LH: Histologic typing of ovarian tumours. *In*: World Health Organization, International Histological Classification and Staging of Tumours. First edition, Geneva, Switzerland, WHO, 1973.

3 Sehouli J, Oskay-Oezcelik G, Pietzner K, Chen F, Coumbos A, Darb-Esfahani S, Schuback B, Heinrich G, Kronenberger C, Lorsbach M, Lichtenegger W and Chekerov R: Clinical management of borderline tumours of the ovary – experience from the Berlin Online Tumour Conference for Gynaecological Malignancies". Anticancer Res *30(5)*: 1701-1706, 2010.

4 Buamah P: Benign conditions associated with raised serum CA-125 concentration. J Surg Oncol *75*: 264-265, 2000.

5 Halila H, Stenman UH and Seppälä M: Ovarian cancer antigen CA-125 levels in pelvic inflammatory disease and pregnancy. Cancer *57*: 1327-1329, 1986.

6 Meden H and Fattahi-Meibodi A: CA-125 in benign gynecological conditions. Int J Biol Markers *13*: 231-237, 1998.

7 Haga Y, Sakamoto K, Egami H, Yoshimura R and Akagi M: Clinical significance of serum CA-125 values in patients with cancers of the digestive system. Am J Med Sci *229*: 30-34, 1986.

8 Drapkin R, von Horsten HH, Lin Y, Mok SC, Crum CP, Welch WR and Hecht JL: Human epididymis protein 4 (HE4) is a secreted glycoprotein that is overexpressed by serous endometrioid ovarian carcinomas. Cancer Res *65(6)*: 2162-2169, 2005.

9 Holcomb K, Vucetic Z, Miller MC and Knapp RC: Human epididymis protein 4 offers a superior specificity in the differentiation of benign and malignant adnexal masses in premenopausal women. Am J Obstet Gynecol *205*: 358.e1-6, 2011.

10 Escudero JM, Auge JM, Filella X, Torne A, Pahisa J and Molina R: Comparison of serum human epididymis protein 4 with cancer antigen 125 as a tumor marker in patients with malignant and nonmalignant diseases. Clin Chem *57(11)*: 1534-1544, 2011.

11 Montagnana M, Danese E, Giudici S, Franchi M, Guidi GC, Plebani M and Lippi G: HE4 in ovarian cancer: From discovery to clinical application. Adv Clin Chem *55*: 1-20, 2011.

12 Langmár Z, Németh M, Vleskó G, Király M, Hornyák L, Bösze P. HE4 – a novel promising serum marker in the diagnosis of ovarian carcinoma. Eur J Gynaecol Oncol *32(6)*: 605-610, 2011.
13 Moore RG, Miller MC, Disilvestro P, Landrum LM, Gajewski W, Ball JJ and Skates SJ: Evaluation of the diagnostic accuracy of the risk of ovarian malignancy algorithm in women with a pelvic mass. Obstet Gynecol *118*: 280-288, 2011.
14 Braicu EI, Fotopoulou C, Van Gorp T, Richter R, Chekerov R, Hall C, Butz H, Castillo-Tong D Cacsire, Mahner S, Zeilinger R, Concin N, Vergote I and Sehouli J: Preoperative HE4 expression in plasma predicts surgical outcome in primary ovarian cancer patients, Gynecologic Oncology *128(2)*: 245-251, 2013.
15 Huhtinen K, Suvitie P, Hiissa J, Junnila J, Huvila J, Kujari H, Setälä M, Härkki P, Jalkanen J, Fraser J, Mäkinen J, Auranen A, Poutanen M and Perheentupa A: Serum HE4 concentration differentiates malignant ovarian tumours from ovarian endometriotic cysts. Br J Cancer *100(8)*: 1315-1319, 2009.
16 Fédération Internationale de Gynécologie et d'Obstétrique (FIGO), Geneva, Switzerland, 1954.
17 Moore RG, Miller MC, Eklund EE, Lu KH, Bast RC Jr. and Lambert-Messerlian G: Am J Serum levels of the ovarian cancer biomarker HE4 are decreased in pregnancy and increase with age. Obstet Gynecol *206(4)*: 349.e1-7, 2012.
18 Van Gorp, Cadron I, Despierre E, Daemen A, Leunen K, Amant F, Timmermann D, De Moor B and Vergote I: HE4 and CA125 as a diagnostic test in ovarian cancer: A questionnaire-based survey. Int. J Gynecol Cancer *18(3)*: 439-445, 2008.
19 Köbel M, Kalloger SE, Boyd N, McKinney S, Mehl E, Palmer C, Leung S, Bowen NJ, Ionescu DN, Rajput A, Prentice LM, Miller D, Santos J, Swenerton K, Gilks CB and Huntsman D: Ovarian carcinoma subtypes are different diseases: implications for biomarker studies. PLoS Med *5(12)*: e232, 2008.
20 Silverberg SG, Bell DA, Kurman RJ, Seidman JD, Prat J, Ronnett BM, Copeland L, Silva E, Gorstein F and Young RH: Borderline ovarian tumors: key points and workshop summary. Hum Pathol *35(8)*: 910-917, 2004.
21 Fotopoulou C, Bugariu M, Braicu EI, Lichtenegger W and Sehouli J: What are the individual perceptions of patients with borderline tumours of the ovary in regard to pathogenesis and prognosis? A structured survey on 60 women. J Psychosom Obstet Gynaecol *31(4)*: 265-272, 2010.
22 Romero I and Bast RC Jr.: Minireview: Human ovarian cancer: Biology, current management, and paths to personalizing therapy. Endocrinology *153(4)*: 1593-1602, 2012.

Received January 28, 2013
Revised March 6, 2013
Accepted March 7, 2013