

Satisfactory Sampling in Cytological Cervical Diagnosis: Comparison Between a Conventional and a New Sampling Device

ANKICA LUKIC¹, STEFANIA IANNAFFIO¹, ROSEMARIE HEYN²,
SANDRA VILLANI³, FLAVIA NOBILI¹, ENRICO GIARNIERI³,
RITA MANCINI³, MASSIMO MOSCARINI¹ and MARIA ROSARIA GIOVAGNOLI³

¹Department of Gynecology-Obstetrics & Urology;

²Department of Anatomic, Histologic, Forensic and Orthopaedic Sciences;

³Department of Clinical and Molecular Medicine, Sapienza University of Rome, Rome, Italy

Abstract. Aim: Inadequate cervical sampling is the most frequent cause of misdiagnosis in cervical cancer screening. The aim of this study was to test the ability of PapCone[®] versus the conventional sampling method (Ayre's spatula plus cytobrush) to collect ectocervical and glandular cells. Materials and Methods: In 18 healthy women, two ecto-endocervical samples, obtained by two different methods, were obtained at a three-month interval. Qualitative and quantitative parameters were evaluated. Ultrastructure features of sampling devices were analyzed by scanning electron microscopy (SEM) before and after sampling. Results: The χ^2 test revealed a statistically significant difference between the two methods: PapCone[®] caused less cell overlap and sampled less white blood cells ($p < 0.05$) and more metaplastic cells ($p < 0.01$). SEM evaluation highlighted the porous and spongy structure of PapCone[®] that was responsible for the large number of glandular cells on its surface. Conclusion: Cervical smears performed by PapCone[®] were adequate and generally easier to screen than conventionally performed ones.

Cervical cancer is a very important gynecological cancer, ranking as the second female cancer worldwide. The incidence and mortality of cervical cancer can be controlled by well-organized screening programs and, according to the international guidelines, the Pap smear represents the gold standard for this screening (1-4).

A Pap smear consists of a sample of cells from the ecto-endocervix smeared and fixed on to a glass slide or immersed

in a liquid fixative and then stained for evaluation by light microscopy. Whatever the method, it is very important that cells are sampled primarily from the transformation zone (TZ) between the ectocervical squamous epithelium and the endocervical columnar epithelium, since cervical cancer arises mostly in this area (2, 5). The correct sampling of the cervix with appropriate equipment contributes significantly to the diagnostic value of the Pap test (2).

Several sampling devices can be used to obtain endocervical and ectocervical cells. The European Guidelines for Quality Assurance in cervical cancer screening recommend three sampling methods: cervical brush (Cervex-Brush, Rovers), a combination of a spatula for the ectocervical sample and an endocervical brush for the endocervical sample, or an extended-tip spatula-alone. Furthermore, the use of cotton tip applicators is not recommended (2). The most commonly used methods are Ayre's spatula and cytobrush. A new sampling device was recently proposed for clinical use: PapCone[®] (Otto Bock, Duderstadt, Germany). Therefore, the aim of this study was to test the ability of this new device to collect squamous and glandular cells-compared with the conventional sampling method (Ayre's spatula and cytobrush).

Materials and Methods

A prospective, comparative and randomized study was performed on 18 healthy women aged between 21 and 46 years. They were enrolled, after informed consent, at the "Colposcopy and low genital tract diseases" outpatients room of the Sant'Andrea Hospital in Rome. Sampling was performed between the 5th and the 10th day of the menstrual cycle and after at least five days of sexual abstinence. At enrolling time, 13 patients were nulliparous and five pluriparous. The study was approved by the local Ethics Committee. Exclusion criteria were: clinical history of genital warts or destructive or excisional therapies of the lower genital tract, Pap test

Correspondence to: Prof. Ankica Lukic, Via Michele Amari 47, 00179 Roma, Italy. Tel: +39 3355487643, e-mail: luki.anki@tin.it

Key Words: Pap test, cervical sampling device, Ayre's spatula, cytobrush.

positive for Human Papillomavirus (HPV) or intraepithelial neoplasia, pregnancy and use of hormonal contraceptive methods.

For all the patients, two ecto-endocervical samples were taken at an interval of three months. The first sampling was randomly performed using conventional devices: Ayre's spatula and cytobrush (Ayre's spatula, Farmac Zabban S.P.A., Caldera di Reno, Bologna, Italy; cytobrush, Clini Lab S.R.L., Conselve, Padua, Italy) in 11 patients (Group A), and PapCone[®] alone in seven patients (Group B). PapCone[®] is a cone-shaped polyurethane (foam) sampling device designed by the University Hospital, Göttingen (Germany) to obtain cells from the ecto- and the endocervix simultaneously (Figure 1 A). On the second round, sampling techniques were reversed, using conventional devices for Group B and PapCone[®] for Group A. Cervical samples were collected and processed according to the European Guidelines for Quality Assurance in cervical cancer screening (2).

Both sides of the spatula were longitudinally smeared onto a glass slide, while cytobrush and PapCone[®] were gently wrapped on the glass slide and immediately fixed with a spray fixative (Fixa, Biotekne S.R.L. Bologna, Italy). All Pap smears were reported according to the Bethesda system 2001 (6).

Several parameters were analyzed during the evaluation of Pap smears by light microscopy giving the relative proportion of squamous, glandular and metaplastic cells. We also evaluated the presence of columnar cells mimicking glandular structures (7), separation between ectocervical and glandular cells, presence of blood cells, cells overlapping, presence of mucus and presence of white blood cells (WBCs).

A non-parametric scale of 0 to 3 was used to score the more significant parameters effectively contributing to the quality of the specimen (quantity of squamous, glandular and metaplastic cells): 0=absence, and 3=presence of the parameter in the largest quantity.

A reverse non-parametric scale was used to score the parameters that could have a more significant negative effect on the correct evaluation of samples (blood cell presence, overlapping cells and presence of WBCs): 0=presence in the largest quantity, to 3=absence of the negative parameter.

Two highly experienced senior cytologists were given the task of evaluating the smears; each evaluated the samples separately and, in the case of discrepancy between their reports, the case was fully-reviewed under a dual microscope until agreement was reached.

Presence or absence of mucus was evaluated, as well as the presence of glandular cells mimicking glandular structures and separation between glandular and squamous cells. Means, medians and standard deviations were calculated for the other parameters (Table I). The χ^2 test was used to compare the qualitative variables (Stata 9.1; StataCorp, College Station, Texas, USA).

The more significant parameters (presence of squamous, glandular, metaplastic and blood cells, overlapping cells, and presence of WBCs) were also scored in order to obtain a numerical global evaluation of the technical quality of the specimens.

In order to characterize the sampling methods, as well as the sampled cells, more precisely, ultrastructural features of the three devices (Ayre's spatula, cytobrush and PapCone[®]) were analyzed by scanning electron microscopy (SEM) before and after sampling: the apical extremity of each device was fractured and fixed *in toto* by immersion in vials containing a solution of 2.5% glutaraldehyde in 0.1 M PBS. Samples were stored at 4°C, post-fixed in 1% osmium tetroxide in 0.1 M PBS (pH 7.4), and then dehydrated in increasing ethanol concentrations. Specimens were critical-point dried with carbon dioxide (EMITECH K850 Critical Point Dryer; Emitech

Ashford, Kent, UK), mounted on aluminum stubs and metal-coated with 3 nm of platinum (EMITECH K550 Sputter Coater; Emitech). Samples were ultimately observed and photographed with a Hitachi S-4000 field emission SEM operating at accelerating voltages of 10-15 kV. Devices were observed by SEM at a magnification of $\times 250$. Glandular, squamous and blood cells were counted in 10 microscopic fields for each sample. The presence of mucus on the device's surface was evaluated on a non-parametric scale ranging from 0 to 2: 0=absence of mucus; 2=maximum presence of mucus. Means, medians and standard deviations were calculated for each device.

The statistical analysis was performed using MedCalc Software bvba (version 11.5.1; Mariakerke, Belgium). The χ^2 test was used to compare the qualitative variables and Student's *t*-test for the quantitative variables evaluated by SEM.

Results

All samples were deemed adequate for their number of cells, fixation and staining. The results of the more significant parameters evaluated by light microscopy are summarized in Table I.

In five cases, no glandular cells were present on the glass slides with either method; in particular, three women had no glandular cells on samples obtained using both sampling devices (three cases corresponded to the same women). There were differences in the number of glandular cells depending on the sampling device. More glandular cells were present in conventional smears than in PapCone[®] smears (mean=1.83 vs. 1.44), although the χ^2 test showed that this difference was not statistically significant. Moreover, in only two cases were groups of cells mimicking glandular structures present on glass slides sampled with PapCone[®], while such structures were evident in five conventional smears.

The score of metaplastic cells in PapCone[®] samples was higher than the conventional device samples score (mean=0.28 vs. 0.06) and this difference was statistically significant ($p < 0.01$).

Glandular cells, metaplastic cells and mucus were clearly separated from the squamous cells in half of the conventional, and in none of the PapCone[®] smears.

Differences in blood presence were observed in relation to sampling tools: no blood was found in 78% of PapCone[®] cases. In contrast, blood was present in 50% of traditional methods and in 22% of the cases, it partially interfered with the evaluation of the smear, without attaining statistical significance.

PapCone[®] obtained the best score when considering overlapping cells (mean=2.17 vs. 1.61 of conventional devices). Cell overlapping was maximum in four conventional smears and in none of the PapCone[®] smears.

WBCs on glass slides were present in the largest quantity in four conventional smears and in none of the PapCone[®] smears. Thus, smears obtained with PapCone[®] gave better results for this parameter than conventional devices did (mean=2.22 vs. 1.83).

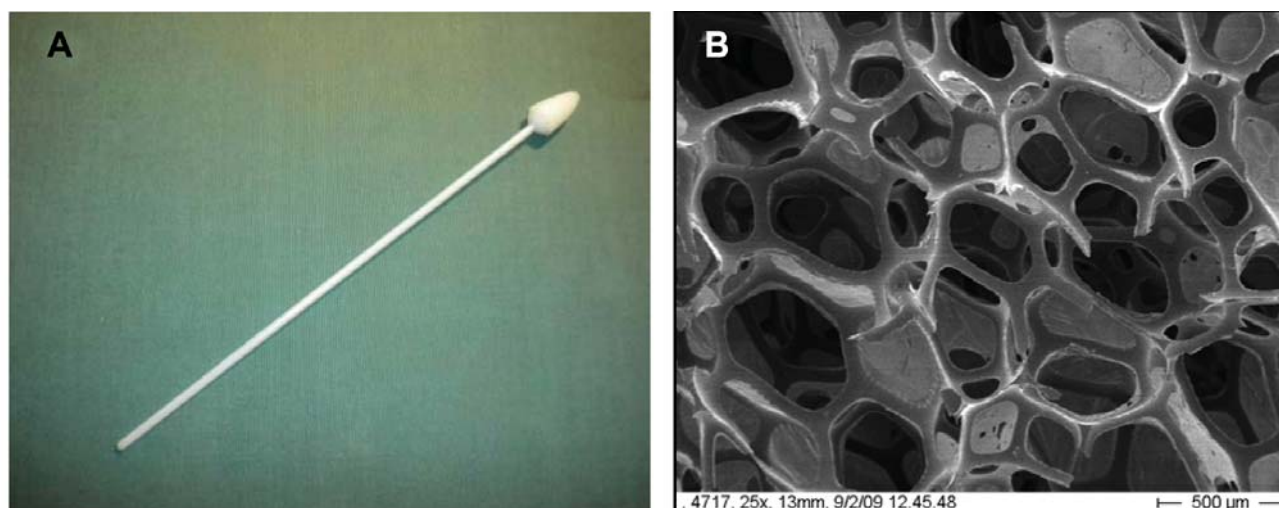


Figure 1. PapCone® actual dimensions (A); porous and spongy structure of PapCone® (B).

Table I. Results of light microscopy evaluation.

Index value	Squamous cells		Glandular cells		Blood presence		Cells overlapping		WBCs		Metaplastic cells		Total score	
	pt	pc	pt	pc	pt	pc	pt	pc	pt	pc	pt	pc	pt	pc
0	0	0	5	5	4	2	4	0	4	0	17	13		
1	1	1	2	4	1	0	4	3	3	4	1	5		
2	2	2	2	5	4	2	5	9	3	6	0	0		
3	15	15	9	4	9	14	5	6	8	8	0	0		
Total patients	18	18	18	18	18	18	18	18	18	18	18	18		
Score	50	50	33	26	36	46	29	39	33	40	1	5	182	206
Mean	2.78	2.78	1.83	1.44	2	2.56	1.61	2.17	1.83	2.22	0.06	0.28		
Median	3	3	2.5	1.5	2.5	3	2	2	2	2	0	0		
Deviation	0.55	0.55	1.34	1.15	1.24	0.98	1.14	0.71	1.25	0.81	0.24	0.46		
Differences	-	-	-	-	-	-	$p < 0.05$	$p < 0.05$	$p < 0.05$	$p < 0.05$	$p < 0.01$	$p < 0.01$		

Pt, Conventional Pap test; pc, PapCone®; WBCs, white blood cells.

Mucus was generally present on glass slides obtained with both sampling methods: it was absent from only one PapCone® smear and four conventional smears. In no cases did the mucus interfere with smear evaluation; it was far less present on glass slides obtained with PapCone®.

The χ^2 test showed that differences in overlapping cells, presence of WBCs and quantity of metaplastic cells between PapCone® and conventional devices were statistically significant ($p < 0.05$ for overlapping cells and WBC and $p < 0.01$ for amount of metaplastic cells).

The evaluation of the most important parameters: quantity of squamous, glandular, metaplastic, and blood cells, as well as overlapping cells and the presence of WBCs, showed that

PapCone® obtained a higher total score than conventional devices (206 vs. 182).

In the second phase of the study, the cells remaining on the devices after performing the smear were evaluated. The most interesting feature was the porous and spongy structure of PapCone® (Figure 1 B). Cells lay on the meshes, in between the pores in such a way that there was generally less cell overlap with respect to the three-dimensional microarchitecture of the spatula and the cytobrush. Observing the cell distribution on the devices, the cytobrush usually displayed fewer cells, which were generally distributed either over the proximal part of the instrument or at its tip. The cell number increased when the mucus was

more abundant. Mucus usually lay like a tent, particularly on the surface of the cytobrush. It tended to concentrate between the base and the bristles, thus covering and masking most of the cells sampled. This effect was less evident in samples obtained with the wooden spatula and with the PapCone[®].

No difference was observed under the SEM regarding the number of squamous cells present on the surface of the three sampling devices. Nor was any difference observed in the number of glandular cells between spatula and cytobrush. Instead, glandular cells were always more numerous on the PapCone[®] than on the spatula or brush ($p=0.072$ and $p=0.055$, respectively). Likewise, the mean number of red blood cells was higher (55.86 ± 58.40) on the PapCone[®] than on the cytobrush (31.59 ± 40.66) or spatula (23.00 ± 29.37), but the difference was statistically significant only for the latter ($p=0.0011$).

Discussion

This is the first study comparing different sampling devices from the point of view of both of the cytological performance and ultrastructural features. The results show that both sampling devices were able to obtain adequate smears with a sufficient number of cervical cells.

No statistically significant differences were found between PapCone[®] and conventional devices as far as the number of squamous ectocervical cells is concerned. Furthermore, PapCone[®] displayed fewer glandular cells on glass slides, even though this difference was not statistically significant. Only two PapCone[®] samples showed glandular groups mimicking glandular structures versus five cases obtained by conventional devices. One possible explanation is that glandular cells, which are much smaller than the squamous ones, could be trapped by the spongy and porous structure of PapCone[®]. This hypothesis could also explain why the number of glandular cells on glass slides was lower than that observed on the device's surface. Indeed, SEM analysis of the device's surface showed that glandular cells were always more numerous on PapCone[®] than on spatula or cytobrush, the difference being statistically significant for the spatula. Unexpectedly, PapCone[®] showed a better and statistically significant sampling performance regarding metaplastic cells, which may be explained, once again, by the peculiar structure of PapCone[®] which grips the transformation zone (TZ) more effectively.

Inflammatory cell contamination (WBCs) was less present on glass slides performed by PapCone[®] and these data are statistically significant ($p<0.05$). Like glandular and red blood cells, it was possible for WBCs to be trapped by the PapCone[®] structure.

The importance of glandular cell presence in Pap smears has been discussed in literature since 1972 (8). The idea that these cells reflect the correct sampling of the TZ is

anatomically plausible. According to the guidelines reported in literature, the cervical smear report should include a comment on the presence of glandular and/or metaplastic cells (9, 10) as, together with mucus, this is a sign of TZ sampling (6).

The European Guidelines for Quality Assurance in cervical cancer screening (2) recommend three sampling methods: cervical brush, combination of spatula and cytobrush, or extended-tip spatula alone. According to the literature, the cytobrush plus extended-tip spatula is the best combination for obtaining cervical samples and the collection devices that more effectively collect glandular cells are also more likely to produce adequate smears with no blood or inflammatory cell contamination (5, 11-13).

Other authors evaluated the glandular, squamous and metaplastic cells in cervical smears performed with the wooden, plastic and modified Ayre's spatula, extended tip spatula, cytobrush, cotton swab and loop (14-17). Use of spatula with cytobrush was more effective than the spatula alone at collecting endocervical cells and the most effective combination appeared to be the cytobrush with an extended tip spatula (16). They concluded that cytobrush was better than cotton swab for collecting glandular cells, whereas a plastic Ayre's spatula was better than a wooden one, even if more bleeding was caused by the combination of plastic spatula plus cytobrush (15).

The same results were reported by other authors using Accellon Combi which increased the possibility of introducing blood during the ectocervical sweep (18).

In the present study, a wooden Ayre's spatula and cytobrush were used as conventional devices and more blood was present on the glass slides, particularly on the brush-smear part of the glass slide, with respect to the PapCone[®]-produced glass slides. However, statistical analysis shows that the difference is not statistically significant. The mean number of red blood cells was higher on PapCone[®] than on cytobrush or spatula analyzed by SEM and the difference was statistically significant for the spatula ($p=0.0011$). As already suggested, this difference may be due to the typical spongy structure of the PapCone[®].

Another device used to obtain cervical samples is the Cervex brush. In several studies, this tool was compared with other sampling methods (19-25). Results show that spatula plus cytobrush or cytopick constituted the best sampling method, and that when the Cervex brush was used, it was mandatory to remove the mucus from the cervix in that the mucus interfered with smear evaluation (19). In the present study, we did not remove the cervical mucus before sampling, and the glass slides were easily screened regardless of the sampling method. SEM showed that the mucus remained trapped within the spongy structure of the PapCone[®]. In the same way mucus lay like a tent in between the bristles present on the surface of the cytobrush.

According to Jarvi *et al.* no statistical differences were found in the quantity of glandular cells when Cervex brush was compared with other sampling tools although more metaplastic cells were found in the Cervex brush (20). Whitaker *et al.* deemed this device better than the extended-tip spatula alone (25).

Our data showed that there was a statistically significant difference in the number of metaplastic cells. The PapCone[®] gripped the TZ more effectively and collected a larger number of metaplastic cells.

No significant data were found in literature regarding cervical smears and cell overlap. In our cases, cell overlap was less present on PapCone[®]-prepared glass slides than on conventional ones. The PapCone[®] sample is easy to smear on the glass slides by uniform rotation, allowing an even distribution of the sampled material.

At present, at least in the European Countries, cytobrush plus wooden or plastic Ayre's spatula remain the standard devices for conventional cervical smears. Of course, only random controlled prospective testing could allow the present recommendations to be modified.

Conclusion

This study was performed on cytological samples from 18 healthy women, without any clinical history of genital warts, positive Pap test, destructive or excisional therapies of the uterine cervix. The main aim was to analyze the ability of PapCone[®] to obtain adequate smears. The ability of this device to sample cervical intraepithelial neoplasia lesions was not evaluated and could be the subject of future studies.

Cervical smears performed with the aid of PapCone[®] are generally easy to screen because they have few WBCs and less cell overlap, thus preserving satisfactory representation of glandular, squamous and metaplastic cells.

SEM showed the typical porous and spongy structure of the PapCone[®] surface; these features may absorb mucus and blood, and may also trap part of the glandular and blood cells. From a clinical point of view, PapCone[®] is comfortable in nulliparous and pluriparous women, in that its spongy structure is very soft and adaptable. Therefore, according to our preliminary results, PapCone[®] could be considered or even recommended as a sampling device in cervical modifications after destructive or excisional therapies, or in the case of anatomical variations, and when the phlogistic or hormonal milieu could cause bleeding during sampling. The results of the present study open up a further interesting perspective on a new sampling tool that could be used side by side with conventional ones, especially in specific clinical situations, or when Pap smear is repeatedly found to be inadequate in the presence of negative satisfactory colposcopy.

Correct cervical sampling plays a fundamental role in cervical cancer screening; correct cervical sampling depends, in part, on the device we use in clinical practice.

Conflicts of Interest

None declared.

Acknowledgements

The Authors are grateful to Dr. Lucio Morettini for his help in the processing and statistical analysis of clinical data.

References

- 1 Ferley J, Shin HR, Bray F, Forman D, Mathers C and Parkin DM: Estimates of worldwide burden of cancer in 2008: GLOBOCAN 2008 Int J Cancer 127: 2893-2917, 2010.
- 2 European Guidelines for Quality Assurance in Cervical Cancer Screening. Second edition. Available at http://screening.iarc.fr/doc/ND7007117ENC_002.pdf.
- 3 Arbyn M, Autier P and Ferlay J: Burden of cervical cancer in the 27 member states of the European Union: Estimates for 2004. Ann Oncol 18(10): 1425-1427, 2007.
- 4 Recommendations on cancer screening in the European Union. Advisory Committee on Cancer Prevention. Eur J Cancer 36: 1473-1478, 2000.
- 5 Martin-Hirsch P, Lilford R, Jarvis G and Kitchener HC: Efficacy of cervical-smear collection devices: a systematic review and meta-analysis. Lancet 354: 1763-1770, 1999.
- 6 Solomon D, Davey D, Kurman R, Moriarty A, O'Connor D, Prey M, Raab S, Sherman M, Wilbur D, Wright T Jr and Young N; Forum Group Members; Bethesda 2001 Workshop. The 2001 Bethesda System: Terminology for reporting results of cervical cytology. JAMA 287: 2114-2119, 2002.
- 7 Selvaggi SM: Cytologic features of squamous cell carcinoma in situ involving endocervical glands in endocervical cytobrush specimens. Acta Cytol 38: 687-692, 1994.
- 8 Gondos B, Marshall D and Ostergard DR: Endocervical cells in cervical smears. Am J Obstet Gynecol 114: 833-834, 1972.
- 9 Herbert A, Johnson J and Patrick J: Achievable standards, benchmarks for reporting and criteria for evaluating cervical cytopathology. Cytopathology 6: 301-303, 1995.
- 10 Quality Assurance Guidelines for the Cervical Screening Programme. NHS cervical screening programme. NHSCSP Publication no 3. Sheffield UK, 1996.
- 11 Hjersing M, Hom E and Larson G: Comparison between cytobrush and papaplast in sampling vaginal smear. Acta Obstet. Gynecol. Scand 70: 595-99, 1991.
- 12 Waddell CA, Rollason TP, Amarilli JM, Cullimore J and McConkey CC: The cervix: An ectocervical sampler. Cytopathology 1: 1171-1181, 1990.
- 13 Noel M, Kazal LA and Glenday MC: Papanicolaou smear adequacy: The effect of the sampling sequence. J Am Board Fam Pract 6: 103-107, 1993.
- 14 Valenzuela P, Hernandez MJ, Remacha P, Nieto A and Ruiz A: Analysis of sampling methods for cervical cytology. J Obstet. Gynecol 15: 53-56, 1995.

- 15 Rammou-Kinia R, Anagnostopoulou I and Gomousa M: Comparison of spatula and nonspatula methods for cervical sampling. *Acta Cytol* 35 69-75, 1991.
- 16 Martin-Hirsch P, Jarvis G, Kitchener H and Lilford R: Collection devices for obtaining cervical cytology samples. *Cochrane Database Syst Rev* 3: CD001036, 2000.
- 17 Kohlberger PD, Stani J, Gitsch G, Kieback DG and Breitenecker G: Comparative evaluation of seven cell collection devices for cervical smears. *ActaCytol* 43;6: 1023-1026, 1999.
- 18 Valenzuela P, Martinez P, Santana A, Garrido N, Cano A and Arnanz F: Comparison of cervical smears secured with different instruments. *Acta Obstet Gynecol Scand* 80: 262-266, 2001.
- 19 Boon ME, de Graaff Guillound JC and Rietveld WJ: Analysis of five sampling methods for the preparation of cervical smears. *Acta Cytol* 33: 843-848, 1989.
- 20 Jarvi K: Cervex brush versus vaginal-cervical-endocervical (VCE) triple smear techniques in cervical cancer. *Cytopathology* 8: 282-288, 1997.
- 21 Fokke HE, Salvatore CM, Schipper ME and Bleker OP: The quality of Pap smear. *Eur J Gynaecol Oncol* 13: 445-448, 1992.
- 22 Germain M, Heaton R, Erickson D, Henry M, Nash J and O'Connor D: A comparison of the three most common Papanicolaou smear collection techniques. *Obstet Gynecol* 84: 168-173, 1994.
- 23 Sparrow MJ, Fauck R and Gupta RK: A trial of two methods of taking cervical smears: The Aylesbury spatula plus cytology brush compared to Cervex broom. *N Z Med J* 110(1052): 356-358, 1997.
- 24 Marchand L, Mundt M, Klein G and Agarwal SC: Optimal collection technique and devices for a quality Pap smear. *WMJ*. 104: 51-55, 2005.
- 25 Whitaker CJ, Stamp EC, Young W and Greenwood LA: Comparison of efficacy of the cervix brush and the extended-tip wooden spatula with conventional cytology: A longitudinal study. *Cytojournal* 19;6: 2, 2009.

Received December 20, 2012

Revised February 8, 2013

Accepted February 8, 2013