

Therapeutic Response of Untreatable Hepatocellular Carcinoma After Application of the Immune Modulators IL-2, BCG and Melatonin

BOJIDAR TOMOV¹, DIMITAR POPOV¹, RADOSVETA TOMOVA¹,
NICOLA VLADOV², WILLEM DEN OTTER³ and ZACHARY KRASTEV¹

¹Medical University Sofia, Clinic of Gastroenterology, Sofia, Bulgaria;

²Military Medical Academy Sofia, Clinic of Liver-Pancreatic and Transplant Surgery, Sofia, Bulgaria;

³VUmc, Department of Urology, Amsterdam, the Netherlands

Abstract. *Aim: Application of immunotherapy to a patient with untreatable hepatocellular carcinoma. Case Report: The patient had a tumor of 60 mm in the liver. The pathological anatomic diagnosis was adenoma. However, after surgery of the tumor seven new lesions arose, showing that the original tumor had been a hepatocellular carcinoma. In addition, when hepatocellular adenomas grow to a size of more than 6-8 cm, they are considered cancerous and thus become a risk for hepatocellular carcinoma. The patient was treated with interleukin-2, Bacillus Calmette Guerin, and melatonin. Results: During treatment, the alpha-fetoprotein levels in blood fell from 5,000 IU/ml to zero, at which level it remained during the follow-up period of two years. No tumor was detectable on MRI and CT. Six years after the diagnosis of untreatable hepatocellular carcinoma, the patient remains in a good condition. Conclusion: In this case, combined immunomodulating therapy was effective. For patients with metastasized tumors of the liver who are not suitable for conventional therapy, immunomodulation may delay tumor progression, induce tumor regression, or even be curative in some patients. Immunotherapeutic approaches combined with conventional methods for hepatocellular carcinoma treatment may be able to improve therapeutic efficacy.*

Hepatocellular carcinoma (HCC) is amongst the leading causes of cancer-related death (1). Alpha-fetoprotein (AFP) is a serum marker used for HCC diagnosis. High serum

levels strongly suggest the presence of the disease (2). The sensitivity of this parameter is 25-65%, with a specificity of 79-95% (3). At diagnosis, the majority of patients with HCC have an advanced stage of cancer and/or impaired liver function. Therefore they are not suitable for surgery, ablation (percutaneous ethanol injection or radiofrequency ablation), or transarterial chemo-embolisation. Chemotherapy is hardly effective and is associated with significant toxicity and loss of quality of life. Sorafenib is a treatment option for advanced-stage HCC; this therapy can prolong the median survival and time-to-progression in patients with advanced HCC (4). New immunotherapy approaches might also be useful for patients with advanced liver tumors. Cancer immunotherapy can be defined as a set of techniques aimed at eliminating malignant tumors through mechanisms involving immune responses (5). Interleukin-2 (IL-2) plays a major role in immunoregulation and leads to activation of different cells of the immune system and secondary production of multiple cytokines *in vivo*. It has been administered alone, and in combination with other treatments of liver tumors. Systemic administration of high IL-2 doses is associated with significant toxicity and many side-effects (6-8). On the other hand, prolonged subcutaneous administration of low doses is well-tolerated by patients and was given on outpatient basis in clinical trials (9, 10). Systemic low dose IL-2 induced objective responses against HCC in some studies, when given alone or in combination with melatonin (11, 12). Instillation of IL-2 in patients with carcinoma of the bladder led to good therapeutic effects after incomplete transurethral resection (13). The precise anti-tumor mechanism of IL-2 is not completely understood, but it is supposed that IL-2 can trigger natural killer cell (NK), T-cell and lymphokine activated killer cell (LAK) antitumor immune responses (14-16). According to another hypothesis, local IL-2 administration can cause severe vascular leakage in the tumor, acute massive tumor necrosis, followed by

This article is freely accessible online.

Correspondence to: Willem Den Otter, Department of Urology, VUmc, Amsterdam, the Netherlands. E-mail: W.denotter@VUmc.nl; W.den.otter@live.nl

Key Words: Hepatocellular carcinoma, HCC, immunotherapy, interleukin-2, IL-2, BCG, melatonin.

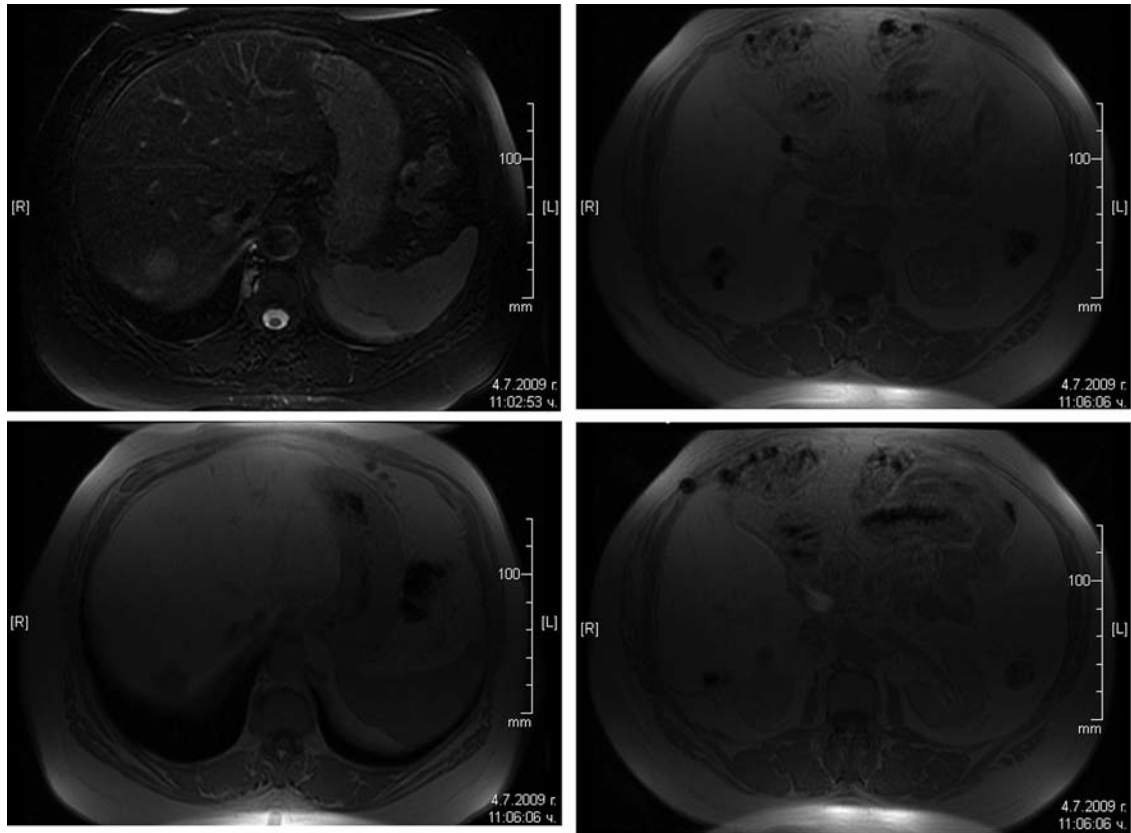


Figure 1. MRI scan of July 2009 revealing new liver lesions after surgery.

clearance of necrotic tumor material, with subsequent liberation of antigenic tumor material, resulting in a secondary immune reaction (17). Melatonin has immunomodulating effects and has shown anti-tumor properties against, HCC among others (12, 18, 19). Vaccination with Bacillus Calmette Guerin (BCG) provokes a non-specific immune response and has led to good results in some cancer treatment regimes (20).

Case Report

We report the case of a 67-year-old female. She was first admitted in 2007 with a single liver tumor of 60 mm. When hepatocellular adenomas grow to a size of more than 6-8 cm, they are considered cancerous and thus become a risk for hepatocellular carcinoma. The patient had normal AFP levels (normal range <5.5 IU/ml). Viral tests revealed that the patient was Hepatitis C Virus (HCV) negative, Hepatitis B surface antigen (HBsAg) negative, anti-HBcore-total (+), Hepatitis B Virus (HBV)-DNA was not detected, and anti-HBsAg was >1000 U/l. In 2008, the tumor marker AFP started to rise; there was no change in tumor size. In

November 2008, when AFP reached 200 IU/ml, liver resection was performed. Histology showed hepatic adenoma and chronic hepatitis. After surgery, follow-up continued and ultrasound investigation did not show any tumor. A high level of AFP was registered in March and April 2009 (913 and 1000 IU/ml, respectively), but CT scan and ultrasound investigation did not reveal any liver tumor. In June 2009 we measured a striking rise of AFP to 5,000 IU/ml and in July 2009, magnetic Resonance imaging (MRI) revealed 7 new liver lesions (Figure 1). The patient was considered inoperable and no standard therapeutic option was available for this patient. Transarterial chemoembolization and sorafenib were not available in Bulgaria at that time.

The patient agreed to start immunotherapy with intermittent subcutaneous low-dose IL-2, BCG and melatonin. The treatment scheme was as follows: IL-2 (Proleukin) - 1.5 MU s.c. on five consecutive days monthly; BCG (Calgevax), 11.25 mg/0.5ml, applied monthly by skin scarification two weeks after IL-2 administration; melatonin pills, 20 mg daily for the period of treatment. The patient tolerated the immunotherapy very well and was

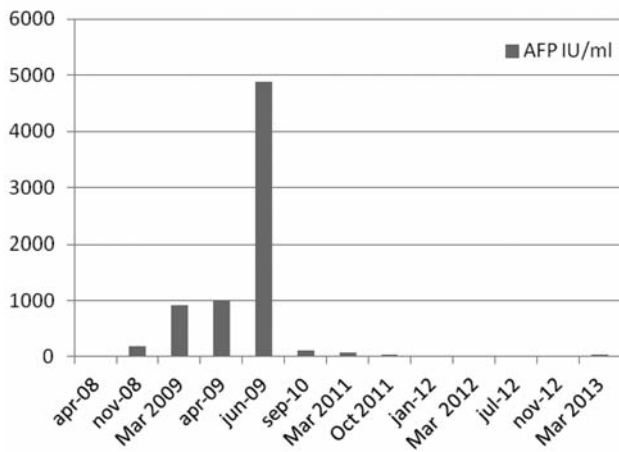


Figure 2. Levels of alpha-fetoprotein (AFP) (IU/ml) during immunomodulation in the patient with HCC. Immunotherapy started in June 2009.

in an excellent clinical condition with no signs of HCC or side-effects due to the application of the immune modulators. During follow-up AFP levels decreased to an undetectable level (Figure 2). CT scan performed in October 2011 showed only one liver lesion (15 mm) in the VIIth liver segment with diminished size compared with the CT of July 2009 (26 mm). In March and November 2012, MRI scan (Figure 3) and CT scan did not show any liver lesions or enlarged lymph nodes, but ultrasound investigation showed two hypoechogenic zones of 24 and 34 mm in the IVth and VIIth liver segments. The contrast-enhanced ultrasound (CEUS) investigation conducted in March 2013 revealed that these lesions were slightly increased in intensity during the arterial phase of enhancement and had decreased intensity in the late phase. An additional zone of 25 mm, not well-defined, was found perihilary and showed the same.

Discussion

After initial surgery, seven new lesions were detected in our patient, thus making a standard curative therapeutic approach impossible. It is important to understand the origin of these new lesions. Some studies reveal that micrometastases are present in 50% of HCC cases after surgical treatment. The recurrence rate in patients with anatomical resection and those with non-anatomical resection does not differ. The frequency of relapse in patients with resection means that factors other than blood supply may contribute to cancer recurrence (21, 22). Such factors might be dormancy of locoregional lesions, dormancy of disseminated tumor cells, or dormancy of

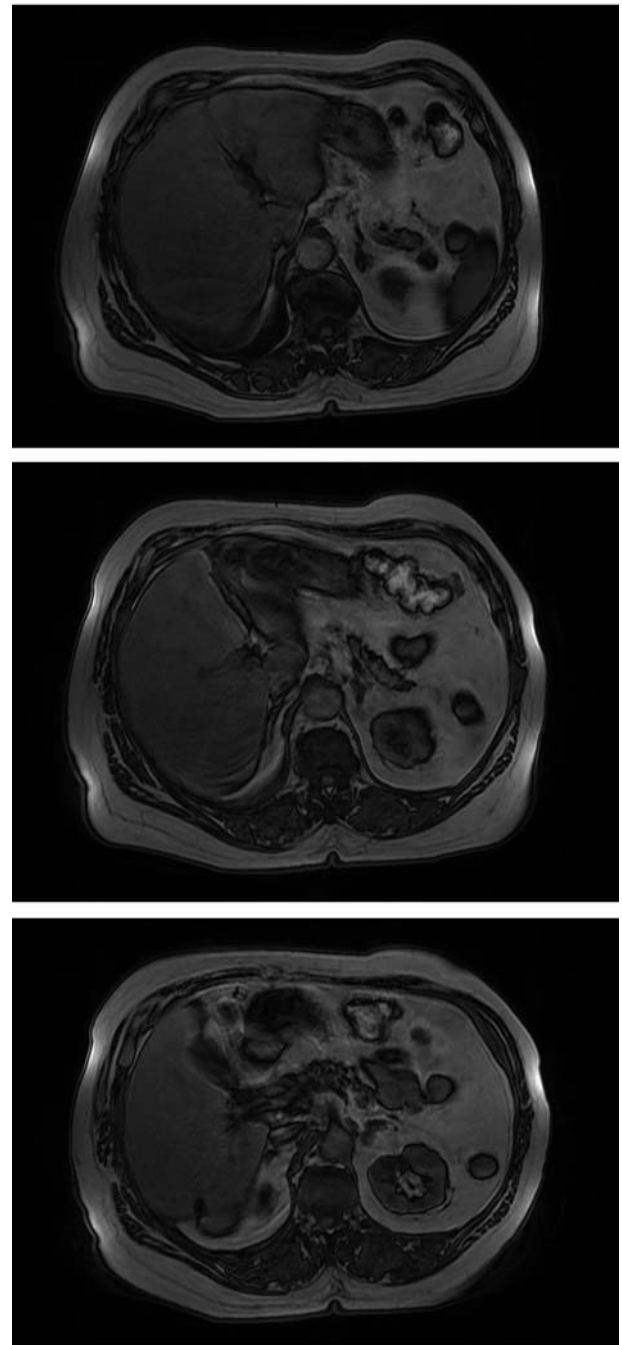


Figure 3. MRI scan of March 2012 revealing no liver tumor.

micrometastases. Tumor dormancy ensues when cancer cell proliferation is counteracted by mechanisms such as apoptosis, impaired vascularization or immunosurveillance. Cellular dormancy ensues when cancer cells enter growth arrest. Several mechanisms can explain cellular dormancy:

the disrupted crosstalk between growth factors and adhesion signaling, which prevents tumor cells interpreting their microenvironment and leads to G₀-G₁ arrest; the inability of tumor cells to recruit blood vessels despite active proliferation; immunosurveillance, which can prevent residual tumor cell expansion; expression of genes that selectively suppress metastases (23).

The impact of surgery on these events is not clear, but there are data from clinical and animal studies suggesting that partial hepatectomy can stimulate remnant tumor growth and growth of metastases by modulating tumor angiogenesis through specific factors involved in liver regeneration such as hepatocyte growth factor (HGF), epidermal growth factor (EGF), transforming growth factors (TGF)- α , TGF- β , hypoxia-inducible factor-1 (HIF-1), vascular endothelial growth factor (VEGF), and matrix metalloproteinases (MMPs) (24, 25). During the late phase of liver regeneration after partial hepatectomy, acceleration of tumor growth and metastasis has been observed (24). After surgery growth of dormant cells may be stimulated just as the growth of the liver is stimulated after partial hepatectomy. If this view is correct, then application of immunotherapy with its systemic effects in addition to surgery could be of major importance in the treatment of HCC.

Currently only a limited number of patients have been enrolled in immunotherapeutic clinical trials. Although the results of these trials are inconclusive, due to the small number of patients, it is evident that this strategy can lead to therapeutic benefit in some patients, especially when no other treatment option is available. Our patient is a good example. She is still alive and in good general condition six years after the diagnosis of untreatable disease.

Conclusion

In this patient, combined immunomodulating therapy of HCC was successful. For patients with dormant tumor cells that are not removed during surgery, immunomodulation may achieve tumor dormancy, delay of tumor progression, induce tumor regression, or even be curative in some patients. Combined immunotherapy with other conventional methods for HCC treatment may be able to improve therapy of HCC.

References

- 1 Ferlay J, Parkin DM and Steliarova-Foucher E: Estimates of cancer incidence and mortality in Europe in 2008. *Eur J Cancer* 46: 765-781, 2010.
- 2 Kew MC: Tumour markers of hepatocellular carcinoma. *J Gastroenterol Hepatol* 4: 373-384, 1989.
- 3 Soresi M, Magliarisi C, Campagna P, Leto G, Bonfissuto G, Riili A, Carroccio A, Sesti R, Tripi S and Montalto G: Usefulness of alpha-fetoprotein in the diagnosis of hepatocellular carcinoma. *Anticancer Res* 23: 1747-1753, 2003.
- 4 Sacco R, Bargellini I, Ginanni B, Bertini M, Faggioni L, Federici G, Romano A, Bertonni M, Metrangola S, Altomare E, Parisi G, Tumino E, Scaramuzzino A, Bresci G and Bartolozzi C: Long-term results of sorafenib in advanced-stage hepatocellular carcinoma: What can we learn from routine clinical practice? *Expert Rev Anticancer Ther* 12: 869-875, 2012.
- 5 Berzofsky JA, Terabe M, Oh S, Belyakov IM, Ahlers JD, Janik JE and Morris JC: Progress on new vaccine strategies for the immunotherapy and prevention of cancer. *J Clin Invest* 113: 1515-1525, 2004.
- 6 Baluna R and Vitetta E: Vascular leak syndrome: A side-effect of immunotherapy. *Immunopharmacology* 37: 117-132, 1997.
- 7 Fyfe G, Fisher RI, Rosenberg SA, Sznol M, Parkinson DR and Louie AC: Results of treatment of 255 patients with metastatic renal cell carcinoma who received high-dose recombinant interleukin 2 therapy. *J Clin Oncol* 13: 688-696, 1995.
- 8 Lotze MT, Chang AE, Seipp CA, Simpson C, Vetto JT and Rosenberg SA: High-dose recombinant interleukin 2 in the treatment of patients with disseminated cancer: Responses, treatment-related morbidity, and histologic findings. *JAMA* 256: 3117-3124, 1986.
- 9 Stein RC, Malkovska V, Morgan S, Galazka A, Aniszewski C, Roy SE, Shearer RJ, Marsden RA, Bevan D and Gordon-Smith EC: The clinical effects of prolonged treatment of patients with advanced cancer with low-dose subcutaneous interleukin 2. *Br J Cancer* 63: 275-278, 1991.
- 10 Meloni G, Trisolini SM, Capria S, Torelli GF, Baldacci E, Torromeo C, Valesini G and Mandelli F: How long can we give interleukin-2? Clinical and immunological evaluation of AML patients after 10 or more years of IL2 administration. *Leukemia* 16: 2016-2018, 2002.
- 11 Palmieri G, Montella L, Milo M, Fiore R, Biondi E, Bianco AR, and Martignetti A: Ultra-low-dose interleukin-2 in unresectable hepatocellular carcinoma. *Am J Clin Oncol* 25: 224-226, 2002.
- 12 Aldeghi R, Lissoni P, Barni S, Ardizzoia A, Tancini G, Piperno A, Pozzi M, Ricci G, Conti A and Maestroni GJ: Low-dose interleukin-2 subcutaneous immunotherapy in association with the pineal hormone melatonin as a first-line therapy in locally advanced or metastatic hepatocellular carcinoma. *Eur J Cancer* 30A: 167-170, 1994.
- 13 Den Otter W, Van Moorselaar RJE, Jacobs JJJ, Ter Haar R, Korten JW, Dobrowolski Z, Lipczynski W, Pasukoniene V, Characiejus D, Jankevicius F, Eidukevicius R and De Reijke TM: Role of marker lesion when applying intravesical instillations of IL-2 for non-muscle-invasive bladder carcinoma. Comparison of the therapeutic affect in two pilot studies. *Anticancer Res* 33: 2099-2106, 2013.
- 14 Ishiyama K, Ohdan H, Ohira M, Mitsuta H, Arihiro K and Asahara T: Difference in cytotoxicity against hepatocellular carcinoma between liver and periphery natural killer cells in humans. *Hepatology* 43: 362-372, 2006.
- 15 Cohen PJ, Lotze MT, Roberts JR, Rosenberg SA and Jaffe ES: The immunopathology of sequential tumor biopsies in patients treated with interleukin 2: Correlation of response with T-cell infiltration and HLA-DR expression. *Am J Pathol* 129: 208-216, 1987.
- 16 Domskov F and Von der Maase HV: Impact of immune parameters on long-term survival in metastatic renal cell carcinoma. *J Clin Oncol* 24: 1997-2005, 2006.

- 17 Den Otter W, Jacobs JJ, Battermann JJ, Hordijk GJ, Krastev Z, Moiseeva EV, Stewart RJ, Ziekman PGPM and Koten JW: Local therapy of cancer with free IL-2. *Cancer Immunol Immunother* 57: 931-950, 2008.
- 18 Srinivasan V, Spence DW, Pandi-Perumal SR, Trakht I and Cardinali DP: Therapeutic actions of melatonin in cancer: possible mechanisms. *Integr Cancer Ther* 7: 189-203, 2008.
- 19 Jung B and Ahmad N: Melatonin in cancer management: progress and promise. *Cancer Res* 66: 9789-9793, 2006.
- 20 Wu X, Patterson S and Hawk E: Chemoprevention-history and general principles. *Best Pract Res Clin Gastroenterol* 25:445-459,2011.
- 21 Shi M, Zhang CQ, Zhang YQ, Liang XM and Li JQ: Micrometastases of solitary hepatocellular carcinoma and appropriate resection margin. *World J Surg* 28: 376-381, 2004.
- 22 Tanaka K, Zhang CQ, Zhang YQ, Liang XM and Li JQ: Anatomic *versus* limited nonanatomic resection for solitary hepatocellular carcinoma. *Surgery* 143: 607-615, 2008.
- 23 Aguirre-Ghiso JA: Models, mechanisms and clinical evidence for cancer dormancy. *Nat Rev Cancer* 7: 834-846, 2007.
- 24 Christophi C, Harun N and Fifiis T: Liver regeneration and tumor stimulation: A review of cytokine and angiogenic factors. *J Gastrointest Surg* 12: 966-980, 2008.
- 25 Chen JA, Shi M, Li JQ and Qian CN: Angiogenesis: Multiple masks in hepatocellular carcinoma and liver regeneration. *Hepatol Int* 4: 537-547, 2010.

Received July 26, 2013

Revised September 18, 2013

Accepted September 20, 2013