

Review

Epidermal Growth Factor Receptor (EGFR)-targeted Therapies in Esophagogastric Cancer

SABARISH AYYAPPAN¹, DHIVYA PRABHAKAR² and NEELESH SHARMA¹

¹*Division of Hematology/Oncology, University Hospitals Case Medical Center and Case Western Reserve University, Cleveland, OH, U.S.A.;*

²*Department of Medicine, University Hospitals Case Medical Center, Cleveland, OH, U.S.A.*

Abstract. *Esophageal and gastric cancer incidence has been increasing worldwide. Most cases are diagnosed in advanced stages, and current therapy has not been able to improve the modest survival rates after diagnosis. Epidermal growth factor receptor expression has been found to correlate with poor prognosis and aggressive disease in esophagogastric cancers. Targeting these receptors through monoclonal antibody or downstream inhibition of tyrosine kinase has produced some encouraging results. The Trastuzumab for Gastric Cancer (ToGA) trial demonstrated that trastuzumab, a monoclonal antibody directed against the Her-2 receptor improves survival in Her-2 positive advanced gastric and gastro-esophageal cancers. Encouraging results have been reported in the ongoing clinical trials of EGFR- directed therapies in combination with concurrent chemoradiation for the locally advanced esophagogastric cancers. Identification of pertinent biomarkers of efficacy will likely lead to further optimization of EGFR-directed treatment. In the current article, we will be discussing the mechanisms of action, completed phase II/III trials and future of epidermal growth factor targeted-therapy in gastric and esophageal cancers.*

Esophageal and gastric cancer incidence all over the world has been rising, and mortality from these cancers combined, is second only to lung cancer. These two cancers combined as per the GLOBOCAN series published by the International

agency for Research on cancer in 2008, was estimated to have a cumulative incidence of 1.47 million and a mortality of about 1.14 million (1). Applying the same prediction model, by 2020, the mortality could rise up to 1.56 million. The incidence and mortality rates from these two cancers combined vary widely throughout the world, and current mortality estimates are highest in Eastern Asia, 56% of deaths were estimated from here (1). Incidence in squamous cell cancer of esophagus in USA has been steady or declining in last 3 decades (2). The recent increase in incidence of gastric cardia, gastro-esophageal junction and distal esophagus adenocarcinoma has brought interest in elucidating common etio-pathology for this cancer and they are thought to have different etiologic factors compared to distal gastric and proximal esophageal cancers (3, 4). Changes in lifestyle including obesity, chronic gastro-esophageal reflux disease, and Barrett's esophagus has been implicated in the resurgence of adenocarcinoma as leading esophageal cancer (5-8).

There have been recent advances in surgical techniques, chemotherapy and radiotherapy, both in the adjuvant and neoadjuvant setting but outcome for patients with esophagogastric cancers remains poor (9). In advanced malignancies, median survival beyond one year has not been achievable with any combination chemotherapy (10, 11). Advances in molecular biology have helped us formulate tumor-specific therapies by utilizing the biological differences between normal and cancer cells. Epidermal growth factor receptors (EGFR) are overexpressed in esophagogastric cancers and their inhibition as a potential therapeutic strategy is being explored. Recently, trastuzumab, a monoclonal antibody against human EGFR-2 (Her-2) increased survival of the Her-2-positive advanced gastric or gastro-esophageal junction cancer in combination with first-line systemic chemotherapy. In this review, an overview of EGFR signaling pathway in esophagogastric cancer will be provided, supported by available data from clinical trials.

This article is freely accessible online.

Correspondence to: Neelesh Sharma, MD, Ph.D, Assistant Professor Thoracic Oncology. University Hospitals/ Case Comprehensive cancer Center, Case Western Reserve University, 11100 Euclid Avenue, Cleveland, OH 44106-1716, U.S.A. Tel: +1 2168440363, Fax: +1 2168445234, e-mail: neeleesh.sharma@uhhospitals.org

Key Words: Esophageal cancer, gastric cancer, EGFR, trastuzumab, cetuximab, review.

EGFR Receptor and Signaling

The epidermal growth factor receptor (EGFR) family of receptors, also called HER family of tyrosine kinases, include ERBB1 or EGFR, ERBB2 or Her-2, ERBB3 and ERBB4, are encoded by *erb* oncogenes (12) and have been implicated in tumor cell growth and differentiation. EGFR is a receptor with an extracellular ligand binding domain (domains I-IV), a transmembrane region, an intracellular domain with tyrosine kinase activity (except in ErbB3), and a tail containing tyrosine residues, required for downstream signaling. Multiple ligands including epidermal growth factor (EGF), transforming growth factor- α , amphiregulin, heparin binding-EGF, epiregulin and betacellulin bind and activate the EGFR receptors (13). Ligand-binding induces interaction with a second receptor of same class (homodimerization) or with a different class receptor (heterodimerization). Dimerization is followed by internalization of receptors, which is followed by autophosphorylation of the intracellular tyrosine kinase domain resulting in a cascade of signaling pathways (12).

The signaling pathway (Figure 1) is a busy roadmap, has multiple channels and includes the Ras/Raf/mitogen-activated protein kinase (MAPK)/cyclin-D1, PI3K/AKT pathway and signal transducers and activators of transcription (STAT) signaling pathways, which are involved in cell proliferation and differentiation (14). The EGFR nuclear signaling independently of the pathways described above, has been implicated in tumor progression (15). After activation by ligand binding and internalization, EGFR receptor binds to importin- β in the cytoplasm which facilitates its nuclear transport, where it stimulates various gene promoters including *cyclin-D1*, *iNOS*, *B-myb*, *Aurora kinase A* and *COX2* (16-20).

Despite having no soluble ligand, ERBB2 is important because it is the preferred heterodimerization partner of the other ligand-bound family members (21). Overexpression of ERBB2 can lead to spontaneous dimerization and auto-activation of the downstream signaling. It can also amplify the signaling by other ERBB heterodimers by strengthening the ligand binding, receptor cycling and stability (21-23).

Role of EGFR Receptor Family in Esophageal and Gastric Cancer

Esophageal squamous cell carcinomas have been known to have higher frequency of EGFR overexpression in the range of 60-70 % (Table I), particularly, with gene amplification noted to be 28% in a series of resected tumours (24, 25). They have been associated with poor response to chemoradiotherapy and poor survival (26). The EGFR overexpression has been seen in high-grade dysplasia in Barrett's oesophagus and a progressive increase in

percentage could represent a marker for progression to malignancy (27). Genetic mutations in the tyrosine residue of the cytoplasmic domain are uncommon. EGF and TGF- α overexpression has been seen in Barrett's esophagus, esophageal adenocarcinoma and esophageal squamous cell carcinoma (13). It is associated with poor survival in squamous cell carcinoma and in particular those with recurrent disease and those undergoing esophagectomy (15).

In gastric cancers, although EGFR amplification has been low, EGFR expression has been comparable to esophageal cancers and it correlates with a poor prognosis (28). In a recently published series, 69 gastric cancer specimens were evaluated for EGFR and HER-2 expression and clinicopathological correlation (29). Her-2 protein was expressed in 42 % of samples and gene amplification or mutation noted in 52 % samples. EGFR expression was seen in 52% of samples with gene alteration in 59%. Gene amplifications were associated with lymph node metastasis and depth of invasion of tumor, with no correlation to other variables evaluated.

In the Trastuzumab for Gastric cancer trial (TOGA) 3,280 patients were screened prior to therapy, 22.1% were found to be positive for Her-2 expression by Fluorescence *in situ* hybridization (FISH) or Immunohistochemistry (IHC) (30). The intestinal type sub-group of gastric cancers are found to have higher positivity compared to the diffuse type (32 vs. 20.4%). There appears to be discordance in the degree of positivity when evaluated by the IHC method. A number of explanations have been provided including discrepancies in laboratory procedures and heterogeneity of gastric cancers, compared to breast cancer where Her-2 testing is routinely performed. False-negatives observed were up to 50% if same principles as used in latter testing were applied (31, 32). It is now advised that screening for Her-2 in gastric cancers and scoring should be performed as per guidelines, based on the TOGA trial (31).

HER-2 overexpression has been identified in 9-60% of esophageal cancers (33-35). In a recent single-institution retrospective analysis, 15% of esophageal cancers and 28% of GEJ cancers were found to be Her-2 positive (36). HER-2 over expression did not correlate with age, race, gender, tumor location, tumor length, stage, or presence of Barrett's esophagus and treatment outcomes including response, patterns of recurrence, and survival were also not statistically different between the groups. There was an increase in poorly differentiated tumors in the Her-2-negative group.

Targeting the Epidermal Growth Factor Receptor (EGFR)

Targeting the EGFR in cancer therapy was initially proposed more than 20 years ago. Out of the various EGFR-targeted agents, the most promising and well-researched are the monoclonal antibodies and the small-molecule EGFR tyrosine kinase inhibitors (TKIs).

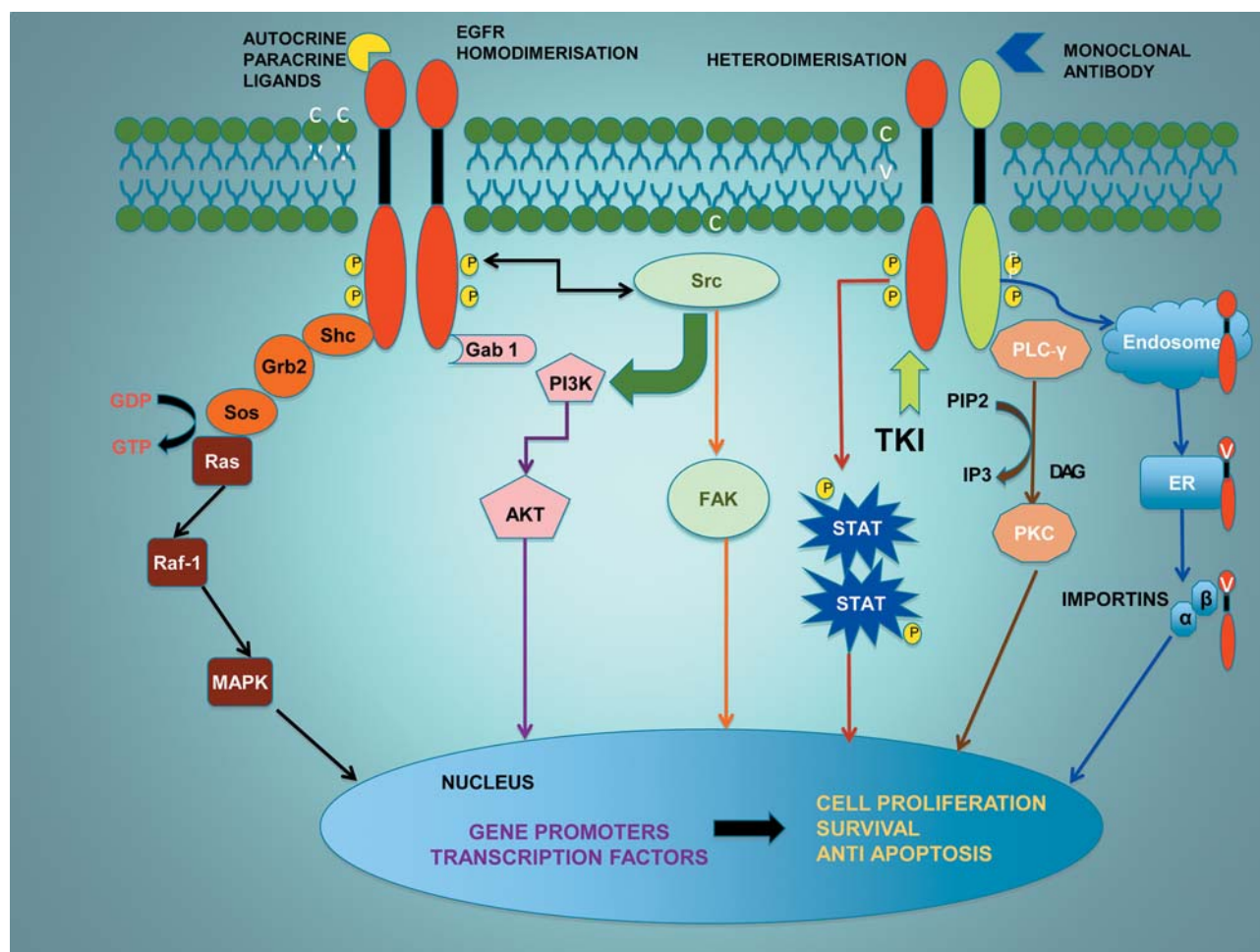


Figure 1. *EGFR* signaling: *EGFR* is activated by ligand binding and subsequent receptor heterodimerization or homodimerization which results in auto-phosphorylation of tyrosine residues and binding of adaptor molecules like *shc*, *gab-1* to the cytoplasmic domain. Intracellular signaling pathways include *RAS*/ *Raf-1*/ *MAPK*, *PI3K*/*AKT*, *PLC-γ*/*PKC* pathways which require the adaptor molecules for signaling. *Src* and *STAT* pathways are directly activated by phosphorylated receptors. Alternately, the activated receptors can undergo endocytosis followed by importin-mediated translocation to the nucleus, and co-transcriptional activation of key genes like *Cox-2*, *iNOS*, *aurora kinase-A* and *cyclin-D1*. All pathways lead to changes in gene expression and stimulation of cell proliferation, survival, invasion and metastasis. *EGFR* manipulation can be approached extracellularly by monoclonal antibodies through inhibition of ligand binding and intracellularly, by tyrosine kinase inhibitor (*TKI*), which compete with *ATP* binding to receptor kinase for activation. *Shc*, *Src* homology-2 domain containing transforming protein-1; *Grb2*, growth factor receptor bound protein-2; *Sos* son of sevenless; *Ras*, rat sarcoma; *Raf-1*, rapidly accelerated fibrosarcoma; *MAPK*, mitogen activated protein kinase; *Gab-1*, *Grb2* associated binding protein-1; *PI3K*, phosphoinositide 3 kinase; *AKT*, protein kinase B; *Src*, sarcoma gene; *FAK*, focal adhesion kinase; *STAT*, signal transducer and activator of transcription; *TKI*, tyrosine kinase inhibitor; *PLC-γ*, phospholipase C-γ; *phosphatidylinositol 4,5-bisphosphate* (*PIP2*); *IP3*, inositol 1,3,5-triphosphate; *DAG*, 1,2-diacylglycerol; *PKC*, protein kinase C; *ER*, endoplasmic reticulum.

Anti-EGFR monoclonal antibodies

Trastuzumab. Trastuzumab is a humanized monoclonal antibody that binds to the extracellular domain IV of the Her-2/neu receptor and prevents the activation of its intracellular tyrosine kinase (37). Several mechanisms of action have been proposed including antibody-dependent cell cytotoxicity (ADCC) activity, activation of natural killer cells and destruction of cancer cells bound to Fc domain of trastuzumab

(38, 39). Inhibition of Her-2 shedding in overexpressing breast cancer cells (40), inhibition of *PI3K* pathway (41), inhibition of angiogenesis (42) and *G₁* phase cell-cycle arrest (43) are other the postulated mechanisms. Trastuzumab is approved for use in combination chemotherapy as adjuvant for Her-2/neu and node positive breast cancer (44, 45).

The ToGA trial evaluated the role of trastuzumab in combination with chemotherapy in metastatic gastric or gastro-esophageal junction cancers. It was an open-label,

Table I. EGFR receptor expression and gene amplification in esophagogastric cancer.

| EGFR receptor | Cancer | Protein expression | Gene amplification | References |
|---------------|--|--------------------|--------------------|----------------------|
| ERBB1 | ESCC | 60-70 % | 28% | 24, 25 |
| | EAC | 32- 80% | 21% | 26, 27, 59, 118, 141 |
| | Gastric | 44-52% | 29% | 28, 29 |
| | Barrett's esophagus (High grade dysplasia) | 35 % | NA | 27 |
| Her-2 | ESCC | 26-64% | 5% | 34, 142-144 |
| | EAC | 10-70% | 15% | 142, 145 |
| | Gastric | 7-42% | 20.30% | 29, 30, 146-149 |
| ERBB3 | EAC | 40-50% | NA | 150 |

ESCC, Esophageal squamous cell cancer; EAC, esophageal adenocarcinoma; EGFR, epidermal growth factor receptor; NA, not available.

international, phase3, randomized trial conducted in 122 centers in 24 countries (46). Out of 3,807 patients initially enrolled with gastric or gastro-esophageal junction cancers, twenty two percent (n=810) were found to be positive for Her-2 if they scored 3+ on IHC or if they were FISH-positive (Her-2:CEP17 ratio ≥ 2). A total of 290 and 294 patients were randomized to receive either 5-FU or capecitabine with cisplatin with or without trastuzumab respectively. Trastuzumab-exposed patients showed and improved overall response rate (47.3% vs. 34.5%) and median progression-free survival (PFS) (6.7 vs. 5.5 months) as well as median overall survival (OS) (13.8 vs. 11.1 months). Rates of overall grade 3 or 4 adverse events (except for diarrhea in the trastuzumab arm) and cardiac adverse events did not differ between groups. Patients assigned to the trastuzumab-plus-chemotherapy arm had slightly higher rates of diarrhea, stomatitis, anemia, thrombocytopenia and weight loss than did patients assigned to the chemotherapy arm alone. There was also a mild increase in incidence of asymptomatic left ventricular ejection fraction decrease in trastuzumab arm (4.6 vs. 1.1%). With these results, FDA and European medicines agency (EMA) have approved trastuzumab for advanced gastric or gastro-esophageal cancer therapy in previously untreated Her-2-positive patients in combination with chemotherapy.

In the only phase I/II study so far conducted in locally advanced esophageal carcinoma, escalating doses of trastuzumab were added to a regimen of weekly cisplatin/paclitaxel in combination with radiation therapy (47). Fourteen out of nineteen patients (74%) were positive for 3+ HER-2 by IHC or gene amplification by FISH. There was 50% survival at 2 years and OS was similar to previous studies without trastuzumab with no increase in toxicity. There is an on going randomized phase III trial investigating efficacy of radiation therapy, paclitaxel, and carboplatin together with or without trastuzumab in treating patients with locally advanced esophageal cancer.

T-DM1, is an antibody-drug conjugate of trastuzumab with microtubule polymerization inhibitor, derivative of

maytansine(48). It binds to Her-2, undergoes receptor mediated internalization and DM-1 is released into cytoplasm. It can induce apoptosis and ADCC mediated tumour cytotoxicity. It has been shown to inhibit gastric cancer cells *in vitro* and *in vivo* in mouse xenograft models (49). There is an ongoing phase II study of T-DM 1, the trastuzumab-emtansine conjugate, in advanced gastric cancer.

Cetuximab. Cetuximab is a chimeric (mouse/human) EGFR-blocking monoclonal antibody, originally derived from a mouse myeloma cell line (50). It blocks the binding of EGF and TGF- α to EGFR and inhibits ligand-induced activation of tyrosine kinase receptor. It also stimulates EGFR internalization and effectively removes the receptor from ligand interaction (51). Cetuximab is approved for clinical use in metastatic colorectal cancers with wild-type KRAS status and in locally advanced as well as recurrent/metastatic squamous cell carcinoma of head and neck (52-54). Cetuximab's antitumour activity has been studied extensively in pre-clinical models of esophagogastric cancer. In the gastric carcinoma cell line, NCI-N87, cetuximab down-regulates EGF-induced EGFR and Her-2 phosphorylation, inhibits homodimerization of EGFR, heterodimerisation between EGFR and Her-2 and downstream signaling *via* the MAPK and AKT pathway (55). In a mouse xenograft model of gastric cancer, cetuximab inhibited the growth of cancer cells and induced apoptosis (56).

Cetuximab in combination with three standard chemotherapy regimens (ECF-C, IC-C, FOLFOX-C) was investigated in a randomized phase-II study performed by the Eastern Cooperative Oncology Group (ECOG1206) in metastatic esophageal and gastro-esophageal junction (GEJ) cancer (57). A total of 245 patients were randomized to receive either one of the regimens, and response rates with the ECF-C, IC-C and FOLFOX-C were 58%, 38% and 51% respectively. FOLFOX-C was found to be least toxic and IC-C least effective. In the only trial with squamous cell cancer of esophagus, combination of cetuximab with cisplatin/5-FU produced 19% overall response in comparison to 13% in the

chemotherapy-alone arm with median survival of 9.5 months vs. 5.5 months (58). Cetuximab did not exacerbate grade 3/4 toxicity, except for rash and diarrhea.

Several phase II/III studies have investigated the role of cetuximab in combination with various chemotherapeutic regimens as first-line therapy in advanced gastric and GEJ cancers (Table II). Three of these trials showed better response with cetuximab combination compared to available triple-agent chemotherapy regimens. Cetuximab combined with FUFOX (5-FU, D-folinic acid, oxaliplatin), showed 65% response rate with OS of 9.5 months (59). In another trial, 35 patients received cetuximab with cisplatin, 5-fluoruracil combination, in which OS had improved to 14.5 months with 69% overall response rate (ORR) (60). Oxaliplatin and irinotecan bi-weekly was combined with weekly cetuximab therapy as first line therapy in advanced gastric cancer (61). Although, response rate and OS were comparable to aforementioned trials, toxicities related to therapy were of lower grade. Multiple phase II studies have examined the role of cetuximab in combination with either cisplatin or irinotecan for the second-line treatment of esophagogastric cancers (62-64). Cetuximab increased survival only modestly in this patient population and was well-tolerated in combination with irinotecan (65). Grade 1-2 skin rash was noted in 73% of patients and portended a prolonged OS of 7.1 months (62). In a recently completed study, cetuximab was combined with a modified FOLFIRI regimen (66), as second-line therapy in advanced gastric cancer subjects, ORR of 35 % was noted and median OS was 8.1 months.

Cetuximab as second line, single-agent therapy in metastatic esophagogastric cancers has good tolerability, but minimal clinical activity (67, 68). Chan *et al.* reported a partial response in 3%, stable disease in 6% of patients treated with single-agent cetuximab with median PFS and OS of 1.6 and 3.1 months, respectively (68). In a phase-II southwest oncology group study, 55 patients were treated with single-agent cetuximab after failure of first-line chemotherapy, the median OS was 4 months (95% CI= 3.2-5.9), and the median PFS was 1.8 months (95% CI= 1.7-1.9). Two patients experienced Grade 4 fatigue, and there was one treatment related death due to pneumonitis (59). In locally advanced esophagogastric cancers, cetuximab has been used in the neo-adjuvant setting along with different chemotherapy backbones such as cisplatin/irinotecan (69), carboplatin/ paclitaxel (70), docetaxel/cisplatin (71) and FOLFOX-4 (bi-weekly 5-fluorouracil/leucovorin/oxaliplatin) (69-73). Complete pathological response rate (pCR) in these studies ranged from 60-70%, with no significant increase in toxicities. Cetuximab combination with cisplatin/irinotecan had a lower complete response rate and higher overall toxicity (54). Results from the first North American cooperative group trial (SWOG 0414) evaluating cetuximab-

plus-cisplatin, irinotecan, and thoracic radiotherapy as definitive treatment for locally advanced, unresectable esophageal cancer has been disappointing (74). The study was closed early due to slow accrual, with 21 eligible patients (11 squamous, 10 adenocarcinoma). Concurrent radiation was administered at 1.8 Gy in 28 daily fractions to a total dose of 50.4 Gy, to begin with on day 1 of cycle 3. Chemotherapy regimen consisted of four 21-day cycles of cetuximab on days 1, 8, and 15, cisplatin 30 mg/m² (days 1 and 8) and irinotecan 65 mg/m² (days 1 and 8). ORR was 17.6%, with two year OS of 33.3% and PFS of 23.8%. Two deaths occurred from the treatment with an overall ten percent treatment-related mortality and 76% of patients developing grade 3/4 toxicities.

Cetuximab combination with definitive chemoradiation for locally advanced esophageal squamous cell cancer in chinese patients, showed good clinical response with an acceptable safety profile. In a single-arm phase II study, 31 patients were enrolled and treated with weekly cetuximab, paclitaxel and cisplatin for 8 weeks in combination with 59.4 Gy radiotherapy (75). Among the 29 response-evaluable patients, 20 (69.0%) had a complete response (CR) with the one and two year PFS rates of 85.5% and 75.1%, respectively.

Matuzumab. This is a humanized IgG1 anti-EGFR monoclonal antibody that has effective ADCC activity. In a randomized phase 2 trial (MATRIX), patients with advanced esophagogastric cancer were randomly assigned to either matuzumab-plus-epirubicin, cisplatin and capecitabine (ECX) or the same ECX regimen alone (76). The ORR was inferior (31vs. 58%) in the matuzumab combination group and median OS was worse (9.4 vs. 12.2 months). The maximum tolerated dose (MTD) for combination of matuzumab and ECX from a phase 1 study was 800 mg weekly which was significantly less compared to single agent MTD of 1,600 mg weekly. Optimal biological dose to achieve efficacy may not have been reached in the combination matuzumab and ECX study.

Panitumumab. This fully-humanized IgG2 monoclonal antibody has already been approved along with cetuximab for metastatic colorectal cancer as single agent therapy or in combination (77). It differs from cetuximab, by inducing minimal immunogenic response and inability to stimulate ADCC. Panitumumab is currently being evaluated in a randomized phase 3 trial (REAL-3), in combination with epirubicin, oxaliplatin and capecitabine (78). Patients with untreated advanced esophagogastric adenocarcinoma were randomly allocated to receive up to eight 21-day cycles of open-label EOC (epirubicin 50 mg/m² and oxaliplatin 130 mg/m² on day 1 and capecitabine 1,250 mg/m² per day on days 1-21) or modified-dose EOC plus panitumumab (mEOC+P; epirubicin 50 mg/m² and oxaliplatin 100 mg/m²

Table II. Monoclonal antibodies in phase 2/3 trials for esophagogastric cancer.

| Agent | Site | Histology | No | ORR | PFS Months | OS Months | Ref |
|--|--------------------|-----------|-----|-----|---------------|--------------|--------|
| Locally advanced | | | | | | | |
| Cet/FOLFOX-4/RT- Preop | Eso | Adeno/SCC | 41 | 50% | N/A | 16 | 73 |
| Cet /RT- Preop | Eso/GEJ | Adeno/SCC | 40 | 36% | N/A | N/A | 151 |
| Cet/carboplatin/ paclitaxel/RT | Eso/Gastric | Adeno/SCC | 60 | 70% | N/A | N/A | 70 |
| Cet/cis/CPT/thoracic RT | Eso | Adeno/SCC | 21 | 18% | 6.4 | 11.2 | 74 |
| Cet/docetaxel/cis+Chemoimmunoradiotherapy(cis/Cet/RT)- Preop | Eso/GEJ | Adeno/SCC | 28 | 68% | N/A | N/A | 71 |
| Cet+cis+CPT+concurrent RT- (Preop) + Cet (post op) | Eso/GEJ | Adeno | 17 | 13% | 10 | 31 | 69 |
| Neoadjuvant-cis/CPT,Cet,surgery+ Adjuvant-cet/leucovorin/5-FU/RT | GEJ/Gastric | Adeno | 20 | N/A | N/A | 11.6 | 152 |
| Cet/Docetaxel:ATTAX2 | Eso/GEJ | Adeno | 38 | 6% | 2.1 | 5.4 | 153 |
| Cet | Eso/Gastric | Adeno | 35 | 3% | 1.6 | 3.1 | 68 |
| Metastatic | | | | | | | |
| Cet | Eso/GEJ | Adeno | 55 | 2% | 1.8 | 4 | 67 |
| Cet+ECF(epirubicin/Cisplatin/5-FU) | Eso/GEJ | Adeno/SCC | 59 | 58% | 5.6 | 10 | 57 |
| Vs Cet+cis+CPT | Eso/GEJ | Adeno/SCC | 66 | 38% | 5 | 8.6 | 57 |
| Vs Cet+FOLFOX | Eso/GEJ | Adeno/SCC | 67 | 51% | 5.7 | 10 | 57 |
| Cet + cis/5-FU | Eso | SCC | 62 | 19% | 5.9 | 9.5 | 58 |
| Vs cis/5-FU | Eso | SCC | | 13% | 3.6 | 5.5 | 58 |
| Cet+Docetaxel+cisplatin(Docetux) | Gastric/GEJ | Adeno | 72 | 41% | 5 | 9 | 117 |
| Cet+FOLFIRI (Folcetux) | Gastric/GEJ | Adeno | 38 | 44% | 8 | 16 | 130 |
| Cet+CPT+folinic acid+ 5-FU | Gastric/GEJ | Adeno | 49 | 46% | 9 | 16 | 118 |
| Cet+5FU/oxaliplatin/folinic acid (FUFOX) | Gastric/GEJ | Adeno | 52 | 65% | 7.6 | 9.5 | 59 |
| Cet+FOLFOX-4 | Gastric | Adeno | 25 | 36% | 6.5 | 10.6 | 154 |
| Cet+FOLFOX-6 | Gastric | Adeno | 38 | 50% | 5.5 | 9.9 | 119 |
| Cet+CPT (PD-platinum) | Eso/Gastric | Adeno | 63 | 11% | 2.8 | 6.1 | 62, 65 |
| Cet+cis+RT | Eso | SCC | 31 | 69% | N/A | N/A | 75 |
| Cet+oxaliplatin/CAPE | Gastric | Adeno | 44 | 52% | 6.5 | 11.8 | 61 |
| Cet+mFOLFIRI (EFFI) | Gastric | Adeno | 61 | 35% | 4.9 | 8.1 | 66 |
| Cet+oxaliplatin/CPT | Gastric | Adeno | 51 | 63% | 6.5 | 9.5 | 155 |
| Cet+cis/5-FU | Gastric | Adeno | 35 | 69% | 11 | 14.5 | 60 |
| Cet+cis/CAPE | Gastric | Adeno | 49 | 48% | 5.2 | N/A | 156 |
| Matuzumab+Epirubicin/cis/CAPE | Distal gastric/GEJ | Adeno | 72 | 31% | 4.8 | 9.4 | 76 |
| Nimotuzumab+cis/paclitaxel | Eso | ESCC | 55 | 55% | 10.5 | N/A | 86 |
| Panitumumab+Epirubicin/oxaliplatin/CAPE (REAL-3) | | Adeno | 553 | 46% | 6 | 8.8 | 79,80 |
| Trastuzumab+cis/paclitaxel/RT | Eso/GEJ | Adeno | 19 | 43% | N/A | 24 | 47 |
| Trastuzumab + 5-FU or CAPE + cis (TOGA) | Gastric/GEJ | Adeno | 294 | 47% | 6.7 | 13.8 | 157 |
| Vs 5-FU or CAPE + cis | | | 290 | 35% | 5.5 | 11.1 | |
| Trastuzumab+cis/s-1 (HERBIS) | Gastric | Adeno | 56 | 68% | 7.1 | N/A | 158 |
| Trastuzumab+paclitaxel | Gastric | Adeno | 46 | 37% | 5.2 | N/A | 159 |

No, Number; ORR, overall response rate; OS, overall survival; Cis, cisplatin; RT, radiotherapy; N/A,unavailable; PFS, progression-free survival; Eso, esophageal; GEJ, gastro-esophageal junction; PD, prior chemotherapy; Adeno, adenocarcinoma; SCC, squamous cell carcinoma; CPT, irinotecan; Cis, cisplatin; Cet, cetuximab; Preop, preoperative; Post op, post operative; CAPE, capecitabine; 5-FU, 5-fluorouracil.

on day 1, capecitabine 1000 mg/m² per day on days 1-21, and panitumumab 9 mg/kg on day 1) (79). A total of 553 patients were enrolled, and the experimental arm (mEOC+P) had a poorer OS of 8.8 months compared to the EOC arm 11.3 months, [Hazard ratio (HR)=1.37, 95% CI=1.07-1.76; $p=0.013$]. Median PFS was 7.4 and 6.0 months respectively (HR=1.22: 95% CI=0.98-1.52, $p=0.068$), and ORR of 42% compared to 46% (odds ratio=1.16, 95% CI=0.81-1.57, $p=0.467$) was observed (80). The panitumumab-arm patients

also had higher incidence of grade 3-4 toxicities, diarrhea (17 vs. 11%), rash (11 vs. 1%), mucositis (5% vs. none), and hypomagnesaemia (5% vs. none) but reduced incidence of neutropenia (13 vs. 28%). Interestingly, a subgroup of patients with grade 1-3 rash (77%) showed an improved OS of 10.2 months vs. 4.3 months ($p<0.001$) with similar improvements in RR and PFS. As per the authors of the study, poorer outcomes in the panitumumab group was thought to be related to the lower dose of oxaliplatin and

epirubicin in the mEOC+P group. KRAS, BRAF and PIK3CA mutations and PTEN expression were assessed in 175 pre-treatment biopsies and correlated with response to mEOC+P (81). Mutations in KRAS (5.7%), BRAF (0%), PIK3CA (2.5%) and loss of PTEN expression (15.0%) were noted, however, were found to be too low to have any prognostic or predictive effect.

Nimotuzumab. It is a humanized monoclonal antibody with weak ADCC activity, has a comparatively better adverse effect profile compared to cetuximab and panitumumab, with absence of skin, renal and gastrointestinal toxicities (82). A recent dose-escalation study of nimotuzumab in advanced esophageal squamous cell carcinoma in combination with cisplatin and 5-fluorouracil showed an excellent tolerability profile and good treatment effect with ORR of 42% (83). A randomized phase II trial of nimotuzumab in combination with cisplatin and s-1 in metastatic gastric cancer, showed comparable response rates and superior time-to-progression (5.5 vs. 3 months) (84). In a phase 2 trial with 63 advanced (locally advanced and metastatic) esophageal cancer patients, cisplatin, 5-FU and radiotherapy was given alone or in combination with six weekly infusions of nimotuzumab (85). An ORR of 47.8% in the nimotuzumab group in comparison to 15.4% in the control group was noted. EGFR-expressing tumors had an objective response rate of 60% and disease control rate of 80%. As first-line therapy in esophageal squamous cell cancers, 55 patients received cisplatin with paclitaxel and nimotuzumab (86). The ORR was 54.7% with median PFS of 10.5 months. In a single-center study, 62 metastatic gastric cancer patients were enrolled to receive s-1 (twice daily on days 1-14 every 3 weeks) and cisplatin on days 1 and 2 alone or in combination with nimotuzumab (days 1, 8, 15) as first-line therapy. The ORR achieved was 50% in the latter group (NCS) in comparison to 63% in the first group (CS) with PFS of 5 months and 3 months respectively (87). Incidence of adverse events was similar in both groups.

Pertuzumab. Pertuzumab is a new humanized monoclonal antibody that binds to domain II dimerization arm of HER-2 in contrast to trastuzumab which binds to domain IV. It inhibits the HER-2 dimerization with other EGFR family members and also exhibits antibody-dependent cell-mediated cytotoxicity (ADCC) related antitumor activity (88, 89). In NCI-N87, an Her-2-positive human gastric cancer xenograft model, combination of trastuzumab and pertuzumab achieved higher efficacy in causing tumor regression, compared to maximum effective dose with single agent alone (90). This combination inhibited EGFR-Her-2 heterodimerization and down-regulated phosphorylation of HER-1/Her-2 receptors as well as downstream effectors. Potentiation of the ADCC activity by the combination, and anti-angiogenetic activity was also observed. Clinical trials to investigate the activity

of this combination in advanced esophagogastric cancers are being designed.

Tyrosine kinase inhibitors

Tyrosine kinase inhibitors repress the phosphorylation step that follows the EGFR receptor dimerization, inhibiting further downstream signaling proteins (91). Gefitinib and erlotinib, both EGFR tyrosine kinase inhibitors are approved for treatment of advanced NSCLC after failure of first line platinum-based chemotherapy (92). Erlotinib is also approved with gemcitabine as first-line treatment of pancreatic cancer (93). The various trials and clinical outcomes for TKIs in esophagogastric cancer are summarized in Table III .

Gefitinib. Gefitinib in esophagogastric cancers has been disappointing, but careful patient selection for future trials might improve its efficacy for these cancers. As first line therapy, gefitinib along with perioperative 5-FU/cisplatin and radiation was evaluated in 80 locally advanced esophageal cancer patients, including both adenocarcinoma and squamous cell carcinoma histology (94). The patients did not develop any significant toxicity compared to a cohort of patients similarly treated without gefitinib. In this single-arm phase II study, addition of gefitinib to chemotherapy resulted in OS of 40%, compared to 28% in the historical cohort suggesting a survival benefit.

Gefitinib has a modest activity in advanced esophageal cancer patients after failure of first line chemotherapy treatment. In a phase II study of 36 esophageal cancer patients treated with daily gefitinib, one patient had partial response and 10 patients had stable disease with OS of 5.5 months (95). Higher response rate was associated with female sex, squamous cell histology and higher EGFR expression.

Another phase II study of gefitinib in 58 recurrent and metastatic esophageal and gastro-esophageal cancers demonstrated partial response in 7% and stable disease in 17% patients with median survival of 5.5 month (96). Treatment with gefitinib has been well tolerated, but efficacy is limited. Further patient selection and combination with other chemotherapy agents in future trials may improve outcome in trials with gefitinib.

Erlotinib. Erlotinib was evaluated in a phase 2 study concurrently with chemotherapy and radiation for locally advanced esophageal carcinoma patients (97). Erlotinib at 150 mg daily dosing was given for the entire duration of chemo-radiotherapy, and chemotherapy (paclitaxel and cisplatin) was administered on Day 1 and Day 29 of the radiotherapy. Two-year OS, loco-regional control, and relapse-free survival were 70.1, 87.5 and 57.4% respectively with low incidence of grade 3 or greater toxicities. In previously-untreated metastatic and locally advanced

Table III. Tyrosine kinase inhibitors in esophagogastric cancer.

| Agent | Site | Histology | No | ORR | PFS Months | OS Months | Ref |
|--------------------------|---------|-----------|----|------|---------------|--------------|-----|
| Erlotinib | Eso | Adeno/SCC | 20 | 15 | N/A | N/A | 160 |
| Erlotinib | Gastric | Adeno | 25 | 0 | 1.6 | 3.5 | 99 |
| | GEJ | Adeno | 43 | 12 | 2 | 6.7 | 99 |
| Erlotinib | Eso | N/A | 24 | N/A | N/A | 70 | 9 |
| Gefitinib | Eso/GEJ | Adeno/SCC | 58 | 24 | 6.1 | 5.5 | 96 |
| Gefitinib/oxaliplatin/RT | Eso/GEJ | Adeno | 6 | 33 | 8.4 | 10.8 | 161 |
| Gefitinib+5-FU/cis+RT | Eso | Adeno/SCC | 34 | 50 | N/A | N/A | 162 |
| Gefitinib | Gastric | Adeno | 75 | 16 | N/A | N/A | 163 |
| Gefitinib | Eso | Adeno | 27 | 26 | 1.9 | 4.5 | 164 |
| Gefitinib | Eso/GEJ | Adeno/SCC | 36 | 28 | 2 | 5.5 | 95 |
| Erlotinib + RT | Eso | SCC | 18 | 72 | 12 | 21.2 | 165 |
| Erlotinib + mFOLFOX | Eso/GEJ | Adeno | 33 | 51.5 | 11 | 5.5 | 98 |
| Lapatinib | Gastric | Adeno | 47 | 7 | 2 | 5 | 104 |
| Lapatinib | Eso/GEJ | Adeno | 25 | 0 | N/A | N/A | 166 |
| Lapatinib | Gastric | Adeno | 16 | 6.25 | N/A | N/A | 105 |
| Dacotinib | Gastric | Adeno | 27 | 7.4 | 2.1 | 7.1 | 107 |

No, Number; ORR, overall response rate; OS, overall survival; Cis, cisplatin; RT, radiotherapy; N/A, unavailable; PFS, progression-free survival; Eso, esophageal; GEJ, gastro-esophageal junction; PD, prior chemotherapy; Adeno, adenocarcinoma; SCC, squamous cell carcinoma.

esophageal and GEJ cancer, daily erlotinib in combination with a modified FOLFOX chemotherapy regimen every 14 days was evaluated with a primary objective of overall response rate and secondary objective including other clinical outcomes (98). Thirty three patients were included and 51% ORR with 5.5 months PFS and eleven months median OS was noted. Diarrhea nausea and vomiting were the commonest grade 3 toxicities. The Southwest Oncology Group (SWOG 0127) conducted a phase II trial of erlotinib in unresectable or metastatic adenocarcinoma of the gastroesophageal junction (GEJ) or stomach as a first line of treatment (99). ORR was 9%, all occurring in patients with GEJ. The median survival was 6.7 months in GEJ and 3.5 months in patients with stomach cancer. Molecular correlates (EGFR, phosphorylated AKT, TGF- α expression) were not predictive of response and no somatic mutation or amplification of EGFR was observed.

Lapatinib. Lapatinib is an oral, reversible dual tyrosine kinase inhibitor of EFGR and Her-2. Compared to erlotinib and gefitinib, it binds to inactive conformation of EGFR and has slower receptor dissociation rates. In comparison to trastuzumab, it produces anti-tumor effects through survivins (100), an apoptosis inhibitor protein. Other than causing the accumulation of inactive Her-2 receptors on the cell surface, it potentiates along with trastuzumab the ADCC activity (101). Currently, it has FDA approval for Her-2-positive breast cancer patients with prior progression on trastuzumab, a taxane and anthracycline. Lapatinib has been shown to induce growth inhibition in Her-2 amplified gastric cancer cell lines *in vivo*,

SNU-216 and NCI-N87 (102). It also induces apoptosis in the NCI-N87 line which has a high Her-2 amplification ratio and in combination with 5-FU, cisplatin, oxaliplatin and paclitaxel showed a synergistic effect. *In vivo* and *in vitro* studies on esophageal and gastric cell lines, with trastuzumab in combination with lapatinib synergistically showed tumor regression in Her-2 amplified cell lines (103).

Lapatinib as a single, first-line agent was evaluated in a southwest oncology group (SWOG) trial in 47 patients with gastric adenocarcinoma. Partial response rate was seven percent with a median OS of 5 months (104). A random discontinuation study of lapatinib was conducted in patients with solid tumors, refractory to chemotherapy and with Her-2 amplification. The trial closed early secondary to slow accrual and poor response (105). Lapatinib is currently being evaluated as first line therapy along with capecitabine or oxaliplatin in LOGIC trial (106). Initial results reported have been disappointing, as the primary end-point was not reached with a hazard ratio of 0.91 (95% CI=0.73, 1.12, $p=0.35$) and median survival of 12.2 vs. 10.5 months, respectively.

Dacomitinib. Dacomitinib is a pan-HER tyrosine kinase inhibitor, currently being evaluated in advanced gastric cancer (107). Twenty seven patients with advanced Her-2-positive gastric cancer were treated with single-agent dacomitinib after failure of at least one prior chemotherapy regimen. The ORR was 7.4% and OS was 7.1 months. This modest clinical activity in heavily pre-treated patients is encouraging and merits further evaluation. Adverse effect profiles included rash, diarrhea and fatigue.

Targeting ERBB3 and ERBB4 Receptor

Her-2 which is the favored hetero-dimerization partner among the EGFR receptors, prefers to dimerize with Her-3 when signaling through the PI3K pathway. Her-3 can directly activate the PI3K-Akt pathway, mediating the proliferative effects of the Her-2/Her-3 dimer (108). Her-3 loss of function has been found to inhibit the growth of HER-2 overexpressing cells (109) and these cells were sensitive to PI3K inhibitors (110). HER-3 overexpression is an independent poor prognostic indicator in patients with gastric cancer who underwent gastrectomy (111). Anti-Her-3 monoclonal antibodies are currently under development. In comparison to other members of the EGFR family, EGFR-4 receptor's role in oncogenesis remains less well-defined and it is suggested that it might actually be involved in signaling towards cell growth inhibition (112). At present, there are no drugs in clinical development targeting the Her-4 receptor specifically and its expression did not correlate with prognosis in gastric cancer specimens (111).

Predictors of Response

Despite development of new molecular-level therapies for managing gastric and esophageal cancers, reliable markers of response are yet to be validated in large prospective studies. These would not only help advance our understanding of these complex interactions at the molecular level but also help select patient populations through clinical trials in a more meaningful way.

EGFR Expression

EGFR overexpression was initially studied as a possible marker for response to EGFR-directed therapy. In metastatic colorectal cancer, EGFR overexpression (detected by IHC staining) has not been predictive of response to monoclonal antibodies (113). Similar lack of correlation between EGFR expression and therapeutic benefit of EGFR inhibitors was seen in head and neck cancer and lung cancer studies (54, 114). EGFR status determined by IHC is not considered reliable as it does have multiple technical difficulties for reliable result reproduction. EGFR amplification (detected by FISH) might be a better alternative (115). Out of the four trials, comparing EGFR expression by IHC and cetuximab response in esophagogastric cancers, all but one showed no correlation (116-118). Han *et al.* reported, that EGFR expression in advanced gastric cancers can be an independent predictor of time-to-progression and also low levels of ligands (EGF and TGF- α) at baseline correlated with response to treatment (119). The role of IHC to assist response prediction to anti-EGF monoclonal antibodies remains unclear.

Oncogene Mutations

Oncogenic mutations in the *KRAS*, *BRAF* or *PIK3CA* genes lead to production of constitutively active signaling proteins downstream of EGFR pathway, which are not affected by inhibition of EGFR through monoclonal antibody or tyrosine kinase inhibitors (120). Mutation status of *KRAS* gene, which is about 30-40 % in colorectal cancers, helps to identify a distinct subtype of metastatic colorectal cancer which does not respond to cetuximab or panitumumab (120, 121). It is being widely used in clinical practice as a validated marker in treatment selection. Among tumors carrying wild-type *KRAS*, mutations of *BRAF* or *PIK3CA* or loss of *PTEN* expression may be associated with resistance to the anti-EGFR monoclonal antibody treatment (122). Incidence of *KRAS* and *BRAF* mutations in gastric cancer studies has been low (2-20%) (123-126), and sporadic simultaneous presence has been noted with aggressive behavior (123). Data regarding the role of these mutations and relation to anti-EGFR therapy have been obtained in a number of phase-2 studies with cetuximab. In the FUFOX study (59), *KRAS* mutation in exon 1 was found only in 1 of 32 samples (3%) and no correlation to EGFR therapy could be identified. In a retrospective study *KRAS* mutation was found in 13.3 % of metastatic gastric cancer patients treated with cetuximab and irinotecan, and response to cetuximab or OS did not correlate with *KRAS* mutation status (63). Forty-four patients with advanced gastric cancer, were evaluated from 2 consecutive phase 2 studies; FOLCETUX and DOCETUX. *KRAS* and *BRAF* mutations were detected in 11.4 and 2.3 % patients respectively (127). The *KRAS* and *BRAF* mutations were mutually-exclusive and the latter was the classic V600E substitution. There was no correlation to oncogene mutations and treatment response and OS. Current evidence for *KRAS* and *BRAF* mutations as potential predictors of outcome for gastric cancer is lacking.

Other Predictors of Response

Cetuximab-induced rash can be a potential predictor of response. In a phase-2 trial of esophageal squamous cell cancer, cetuximab induced rash (grade ≥ 2) had a better CR rate and PFS than those with no or grade 1 rash ($p < 0.05$) (75). Potential biomarkers to predict response to Her-2-targeted treatment include loss of *PTEN*, *PI3KCA* gene mutation and increase in signaling through EGFR and IGF receptor (128). In HER-2-positive breast cancer, loss of *PTEN* (examined by IHC) correlated with poor response rates to trastuzumab and chemotherapy treatment (129). Similar correlation in esophagogastric cancers needs further evaluation. Increased levels of EGFR ligands, epiregulin and amphiregulin promote tumor growth *via* an autocrine loop. In colorectal cancer patients with wild-type *KRAS*, expression

of epiregulin and amphiregulin mRNA in primary tumors correlates with response to cetuximab. In esophagogastric cancers, expression of EGFR ligands has not been evaluated. PET scanning was evaluated in the FOLCETUX study, in advanced gastric cancer patients treated with cetuximab in combination with irinotecan, folinic acid with 5-fluorouracil (130). Metabolic responders on the scan had significantly longer time-to-progression compared to non-responders. Further evaluation in bigger studies might prove this to be a useful resource in predicting response to cetuximab-based treatment.

Resistance to EGFR Therapy

After an initial response to EGFR-targeted therapy, progression or recurrence develops secondary to intrinsic or acquired resistance. Our understanding of the resistance to these monoclonal antibodies and tyrosine kinase inhibitors comes from breast and colorectal cancer data where they have been used extensively. The etiology for EGFR receptor antibody resistance appears to vary. Increased angiogenesis in response to treatment with cetuximab has been proposed as a mechanism of resistance to cetuximab (131). Higher levels of VEGFR-1, VEGF and placental growth factor were found in EGFR-resistant cell lines and VEGFR inhibition restored sensitivity to anti-EGFR drugs (132). An *in vitro* study on five gastric cancer cell lines showed correlation between positivity for *MET* amplification and *KRAS* mutations, and cetuximab resistance (133). Dysregulation of EGFR internalization and degradation (134) along with subcellular compartmentalization to nucleus could contribute to resistance (135). The nuclear EGFR could constitutively activate gene promoters including cyclin-D1, iNOS, B-myc leading to EGFR antibody resistance. Genetic mutations in signaling proteins downstream to EGFR pathway such as RAS, RAF, AKT and PI3K could lead to constitutive activation of growth promoting signaling and resistance to EGFR antibody. Mutant *KRAS* and *BRAF* are well-established biomarkers which predict resistance to cetuximab in colorectal cancers, however such mutations are rare in esophagogastric cancers and have not correlated with response to anti-EGFR treatment in the published studies so far (136).

Multiple mechanisms have been postulated for resistance to Her-2 receptor inhibition and targeting of these mechanisms along with Her-2 receptor inhibition would help to improve Her-2-targeted therapy. IGF-1 receptor overexpression and cross-talk with Her-2 receptor, leading to its activation was seen in only trastuzumab-resistant breast cancer cell lines and not in the parental trastuzumab-sensitive cells (137). Genetic alterations in the PI3K/AKT pathway such as gain of function mutation in *PIK3CA*, loss of *PTEN* and *AKT* mutations have been correlated with resistance to trastuzumab (138-140).

Another mechanism of resistance described in breast cancer but not known in esophagogastric cancers in expression of p95HER2, a truncated Her-2 receptor at the amino terminal, which cannot bind to trastuzumab but has kinase activity. Metastatic breast cancer patients expressing p95HER2 showed limited clinical response to trastuzumab compared to patients with tumors expressing full-length Her-2 receptor (154).

Conclusion and Future Directions

Treatment of esophagogastric cancers with traditional chemotherapeutic agents had reached a plateau and recent demonstration of increased survival with the addition of trastuzumab to the chemotherapy has generated much excitement and there has been a surge of clinical trials involving EGFR-targeted agents. Although, EGFR-targeted agents have produced only modest success in esophagogastric cancers compared to breast, colorectal or head and neck cancers, clinical studies evaluating newer more potent drugs in combination with different treatment modalities are in the anvil. Success of these trials depends on identifying the predictive biomarkers and to select the right patient population that is likely to benefit. On-going clinical trials will establish the role of EGFR inhibitors in neoadjuvant, adjuvant therapy and in combination with radiation treatment. In the metastatic setting, the role of EGFR-targeted agents as maintenance therapy after achieving response with first-line therapy and their use beyond first-line of treatment will need to be further explored.

Further studies are needed to better-understand the role of EGFR receptor signaling in esophagogastric cancers in relation to other signal transduction pathways. There is plenty of cross-talk between multiple signaling pathways and targeting one of the molecules alone, allows for cancer cells to find an escape route utilizing alternate pathways. Increased understanding of the involved pathways will help to develop rational strategies to combine agents targeted against different pathways to achieve maximal therapeutic benefit. Identification of mechanism for acquired resistance will lead to design of clinical trials with newer approaches to delay or reverse the same.

References

- 1 Ferlay J, Shin HR, Bray F, Forman D, Mathers C and Parkin DM: Estimates of worldwide burden of cancer in 2008: GLOBOCAN 2008. International journal of cancer Journal international du cancer 2010.
- 2 Blot WJ and McLaughlin JK: The changing epidemiology of esophageal cancer. Semin Oncol 26: 2-8, 1999.
- 3 Keeney S BT: Epidemiology of adenocarcinoma of the esophagogastric junction. Surg Oncol Clin N Am 15: 687, 2006.
- 4 Wilkinson N, Howe J, Gay G, Patel-Parekh L, Scott-Conner C and Donohue J: Differences in the Pattern of Presentation and Treatment of Proximal and Distal Gastric Cancer: Results of the 2001 Gastric Patient Care Evaluation. Annals of Surgical Oncology 15: 1644-1650, 2008.

- 5 Chow WH, Finkle WD, McLaughlin JK, Frankl H, Ziel HK and Fraumeni JF Jr.: The relation of gastroesophageal reflux disease and its treatment to adenocarcinomas of the esophagus and gastric cardia. *JAMA* 274: 474-477, 1995.
- 6 Heath EI, Limburg PJ, Hawk ET and Forastiere AA: Adenocarcinoma of the esophagus: risk factors and prevention. *Oncology (Williston Park, NY)* 14: 507-514; discussion 518-520, 522-503, 2000.
- 7 Lagergren J, Bergstrom R and Nyren O: Association between body mass and adenocarcinoma of the esophagus and gastric cardia. *Annals of internal medicine* 130: 883-890, 1999.
- 8 Hvid-Jensen F, Pedersen L, Drewes AM, Sorensen HT and Funch-Jensen P: Incidence of adenocarcinoma among patients with Barrett's esophagus. *N Engl J Med* 365: 1375-1383, 2011.
- 9 Enzinger PC and Mayer RJ: Esophageal Cancer. *N Engl J Med* 349: 2241-2252, 2003.
- 10 Cunningham D, Okines AF and Ashley S: Capecitabine and oxaliplatin for advanced esophagogastric cancer. *N Engl J Med* 362: 858-859, 2010.
- 11 Van Cutsem E, Moiseyenko VM, Tjulandin S, Majlis A, Constenla M, Boni C, Rodrigues A, Fodor M, Chao Y, Voznyi E, Risse M-L and Ajani JA: Phase III study of docetaxel and cisplatin plus fluorouracil compared with cisplatin and fluorouracil as first-line therapy for advanced gastric cancer: A report of the V325 study group. *J Clin Oncol* 24: 4991-4997, 2006.
- 12 Franklin WA, Veve R, Hirsch FR, Helfrich BA and Bunn PA Jr.: Epidermal growth factor receptor family in lung cancer and premalignancy. *Seminars in Oncology* 29: 3-14, 2002.
- 13 Salomon DS, Brandt R, Ciardiello F and Normanno N: Epidermal growth factor-related peptides and their receptors in human malignancies. *Critical Reviews in Oncology/ Hematology* 19: 183-232, 1995.
- 14 Marshall J: Clinical implications of the mechanism of epidermal growth factor receptor inhibitors. *Cancer* 107: 1207-1218, 2006.
- 15 Brand TM, Iida M and Wheeler DL: Molecular mechanisms of resistance to the EGFR monoclonal antibody cetuximab. *Cancer Biology & Therapy* 11: 777-792, 2011.
- 16 Lin SY, Makino K, Xia W, Martin A, Wen Y, Kwong KY, Bourguignon L and Hung MC: Nuclear localization of EGF receptor and its potential new role as a transcription factor. *Nat Cell Biol* 3: 802-808, 2001.
- 17 Lo HW, Hsu SC, Ali-Seyed M, Gunduz M, Xia W, Wei Y, Bartholomeusz G, Shih JY and Hung MC: Nuclear interaction of EGFR and STAT3 in the activation of the iNOS/NO pathway. *Cancer Cell* 7: 575-589, 2005.
- 18 Lo HW, Cao X, Zhu H and Ali-Osman F: Cyclooxygenase-2 is a novel transcriptional target of the nuclear EGFR-STAT3 and EGFRvIII-STAT3 signaling axes. *Mol Cancer Res* 8: 232-245, 2010.
- 19 Hung LY, Tseng JT, Lee YC, Xia W, Wang YN, Wu ML, Chuang YH, Lai CH and Chang WC: Nuclear epidermal growth factor receptor (EGFR) interacts with signal transducer and activator of transcription 5 (STAT5) in activating Aurora-A gene expression. *Nucleic Acids Res* 36: 4337-4351, 2008.
- 20 Hanada N, Lo HW, Day CP, Pan Y, Nakajima Y and Hung MC: Co-regulation of B-Myb expression by E2F1 and EGF receptor. *Mol Carcinog* 45: 10-17, 2006.
- 21 Gaus-Porta D, Beerli RR, Daly JM and Hynes NE: ErbB-2, the preferred heterodimerization partner of all ErbB receptors, is a mediator of lateral signaling. *EMBO J* 16: 1647-1655, 1997.
- 22 Wang LM, Kuo A, Alimandi M, Veri MC, Lee CC, Kapoor V, Ellmore N, Chen XH and Pierce JH: ErbB2 expression increases the spectrum and potency of ligand-mediated signal transduction through ErbB4. *Proceedings of the National Academy of Sciences of the United States of America* 95: 6809-6814, 1998.
- 23 Pinkas-Kramarski R, Soussan L, Waterman H, Levkowitz G, Alroy I, Klapper L, Lavi S, Seger R, Ratzkin BJ, Sela M and Yarden Y: Diversification of Neu differentiation factor and epidermal growth factor signaling by combinatorial receptor interactions. *EMBO J* 15: 2452-2467, 1996.
- 24 Hanawa M, Suzuki S, Dobashi Y, Yamane T, Kono K, Enomoto N and Ooi A: EGFR protein overexpression and gene amplification in squamous cell carcinomas of the esophagus. *International journal of cancer Journal international du cancer* 118: 1173-1180, 2006.
- 25 Gibault L, Metges JP, Conan-Charlet V, Lozac'h P, Robaszkiewicz M, Bessaguet C, Lagarde N and Volant A: Diffuse EGFR staining is associated with reduced overall survival in locally advanced oesophageal squamous cell cancer. *Br J Cancer* 93: 107-115, 2005.
- 26 Wang KL, Wu TT, Choi IS, Wang H, Resetkova E, Correa AM, Hofstetter WL, Swisher SG, Ajani JA, Rashid A and Albarracin CT: Expression of epidermal growth factor receptor in esophageal and esophagogastric junction adenocarcinomas: association with poor outcome. *Cancer* 109: 658-667, 2007.
- 27 Cronin J, McAdam E, Danikas A, Tselepis C, Griffiths P, Baxter J, Thomas L, Manson J and Jenkins G: Epidermal growth factor receptor (EGFR) is overexpressed in high-grade dysplasia and adenocarcinoma of the esophagus and may represent a biomarker of histological progression in Barrett's esophagus (BE). *The American journal of gastroenterology* 106: 46-56, 2011.
- 28 Galizia G, Lieto E, Oditura M, Castellano P, Mura AL, Imperatore V, Pinto M, Zamboli A, De Vita F and Ferraraccio F: Epidermal growth factor receptor (EGFR) expression is associated with a worse prognosis in gastric cancer patients undergoing curative surgery. *World journal of surgery* 31: 1458-1468, 2007.
- 29 Wang YK, Gao CF, Yun T, Chen Z, Zhang XW, Lv XX, Meng NL and Zhao WZ: Assessment of ERBB2 and EGFR gene amplification and protein expression in gastric carcinoma by immunohistochemistry and fluorescence *in situ* hybridization. *Molecular cytogenetics* 4: 14, 2011.
- 30 Bang Y, Chung H, Xu J, Lordick F, Sawaki A, Al-Sakaff N, Lipatov O, See C, Rueschoff J and Van Cutsem E: Pathological features of advanced gastric cancer (GC): Relationship to human epidermal growth factor receptor 2 (HER2) positivity in the global screening programme of the ToGA trial. *ASCO Meeting Abstracts* 27: 4556, 2009.
- 31 Ruschoff J, Hanna W, Bilous M, Hofmann M, Osamura RY, Penault-Llorca F, van de Vijver M and Viale G: HER2 testing in gastric cancer: a practical approach. *Mod Pathol* 2012.
- 32 Ruschoff J, Dietel M, Baretton G, Arbogast S, Walch A, Monges G, Chenard MP, Penault-Llorca F, Nagelmeier I, Schlake W, Hofler H and Kreipe HH: HER2 diagnostics in gastric cancer-guideline validation and development of standardized immunohistochemical testing. *Virchows Archiv: an international journal of pathology* 457: 299-307, 2010.
- 33 Dahlberg PS, Jacobson BA, Dahal G, Fink JM, Kratzke RA, Maddaus MA and Ferrin LJ: ERBB2 amplifications in esophageal adenocarcinoma. *The Annals of thoracic surgery* 78: 1790-1800, 2004.

- 34 Friess H, Fukuda A, Tang WH, Eichenberger A, Furlan N, Zimmermann A, Korc M and Buchler MW: Concomitant analysis of the epidermal growth factor receptor family in esophageal cancer: overexpression of epidermal growth factor receptor mRNA but not of c-erbB-2 and c-erbB-3. *World journal of surgery* 23: 1010-1018, 1999.
- 35 Yoshida K, Kuniyasu H, Yasui W, Kitadai Y, Toge T and Tahara E: Expression of growth factors and their receptors in human esophageal carcinomas: regulation of expression by epidermal growth factor and transforming growth factor alpha. *Journal of cancer research and clinical oncology* 119: 401-407, 1993.
- 36 Phillips BE, Tubbs RR, Rice TW, Rybicki LA, Plesec T, Rodriguez CP, Videtic GM, Saxton JP, Ives DI and Adelstein DJ: Clinicopathologic features and treatment outcomes of patients with human epidermal growth factor receptor 2-positive adenocarcinoma of the esophagus and gastroesophageal junction. *Diseases of the esophagus: official journal of the International Society for Diseases of the Esophagus/ISDE* 2012.
- 37 Cho H-S, Mason K, Ramyar KX, Stanley AM, Gabelli SB, Denney DW and Leahy DJ: Structure of the extracellular region of HER2 alone and in complex with the Herceptin Fab. *Nature* 421: 756-760, 2003.
- 38 Clynes RA, Towers TL, Presta LG and Ravetch JV: Inhibitory Fc receptors modulate *in vivo* cytotoxicity against tumor targets. *Nature Medicine* 6: 443-446, 2000.
- 39 Gennari R, Menard S, Fagnoni F, Ponchio L, Scelsi M, Tagliabue E, Castiglioni F, Villani L, Magalotti C, Gibelli N, Oliviero B, Ballardini B, Prada GD, Zambelli A and Costa A: Pilot Study of the Mechanism of Action of Preoperative Trastuzumab in Patients with Primary Operable Breast Tumors Overexpressing HER2. *Clinical Cancer Research* 10: 5650-5655, 2004.
- 40 Molina MA, Codony-Servat J, Albanell J, Rojo F, Arribas J and Baselga J: Trastuzumab (Herceptin), a Humanized Anti-HER2 Receptor Monoclonal Antibody, Inhibits Basal and Activated HER2 Ectodomain Cleavage in Breast Cancer Cells. *Cancer Res* 61: 4744-4749, 2001.
- 41 Nagata Y, Lan KH, Zhou XY, Tan M, Esteva FJ, Sahin AA, Klos KS, Li P, Monia BP, Nguyen NT, Hortobagyi GN, Hung MC and Yu DH: PTEN activation contributes to tumor inhibition by trastuzumab and loss of PTEN predicts trastuzumab resistance in patients. *Cancer Cell* 6: 117-127, 2004.
- 42 Kos KS, Zhou XY, Lee S, Zhang LL, Yang WT, Nagata Y and Yu DH: Combined trastuzumab and paclitaxel treatment better inhibits ErbB-2-mediated angiogenesis in breast carcinoma through a more effective inhibition of Akt than either treatment alone. *Cancer* 98: 1377-1385, 2003.
- 43 Lane HA, Motoyama AB, Beuvink I and Hynes NE: Modulation of p27/Cdk2 complex formation through 4D5-mediated inhibition of HER2 receptor signaling. *Annals of Oncology* 12: S21-S22, 2001.
- 44 Piccart-Gebhart MJ, Procter M, Leyland-Jones B, Goldhirsch A, Untch M, Smith I, Gianni L, Baselga J, Bell R, Jackisch C, Cameron D, Dowsett M, Barrios CH, Steger G, Huang CS, Andersson M, Inbar M, Lichinitser M, Lang I, Nitz U, Iwata H, Thomssen C, Lohrisch C, Suter TM, Ruschoff J, Suto T, Grotzer V, Ward C, Straehle C, McFadden E, Dolci MS, Gelber RD and Herceptin Adjuvant Trial Study T: Trastuzumab after adjuvant chemotherapy in HER2-positive breast cancer. *The New England journal of medicine* 353: 1659-1672, 2005.
- 45 Smith I, Procter M, Gelber RD, Guillaume S, Feyereislova A, Dowsett M, Goldhirsch A, Untch M, Mariani G, Baselga J, Kaufmann M, Cameron D, Bell R, Bergh J, Coleman R, Wardley A, Harbeck N, Lopez RI, Mallmann P, Gelmon K, Wilcken N, Wist E, Sanchez Rovira P, Piccart-Gebhart MJ and team Hs: 2-year follow-up of trastuzumab after adjuvant chemotherapy in HER2-positive breast cancer: a randomised controlled trial. *Lancet* 369: 29-36, 2007.
- 46 Bang Y-J, Van Cutsem E, Feyereislova A, Chung HC, Shen L, Sawaki A, Lordick F, Ohtsu A, Omuro Y, Satoh T, Aprile G, Kulikov E, Hill J, Lehle M, Rüschoff J and Kang Y-K: Trastuzumab in combination with chemotherapy *versus* chemotherapy alone for treatment of HER2-positive advanced gastric or gastro-oesophageal junction cancer (ToGA): a phase 3, open-label, randomised controlled trial. *The Lancet* 376: 687-697.
- 47 Safran H, Dipetrillo T, Akerman P, Ng T, Evans D, Steinhoff M, Benton D, Purviance J, Goldstein L, Tantravahi U and Kennedy T: Phase I/II study of trastuzumab, paclitaxel, cisplatin and radiation for locally advanced, HER2 overexpressing, esophageal adenocarcinoma. *Int J Radiat Oncol Biol Phys* 67: 405-409, 2007.
- 48 Lewis Phillips GD, Li G, Dugger DL, Crocker LM, Parsons KL, Mai E, Blättler WA, Lambert JM, Chari RVJ, Lutz RJ, Wong WLT, Jacobson FS, Koeppen H, Schwall RH, Kenkare-Mitra SR, Spencer SD and Sliwkowski MX: Targeting HER2-Positive Breast Cancer with Trastuzumab-DM1, an Antibody-Cytotoxic Drug Conjugate. *Cancer research* 68: 9280-9290, 2008.
- 49 Barok M, Tanner M, Koninki K and Isola J: Trastuzumab-DM1 is highly effective in preclinical models of HER2-positive gastric cancer. *Cancer letters* 306: 171-179, 2011.
- 50 Goldstein NI, Prewett M, Zuklys K, Rockwell P and Mendelsohn J: Biological efficacy of a chimeric antibody to the epidermal growth factor receptor in a human tumor xenograft model. *Clinical cancer research: an official journal of the American Association for Cancer Research* 1: 1311-1318, 1995.
- 51 Waksal HW: Role of an anti-epidermal growth factor receptor in treating cancer. *Cancer metastasis reviews* 18: 427-436, 1999.
- 52 Karapetis CS, Khambata-Ford S, Jonker DJ, O'Callaghan CJ, Tu D, Tebbutt NC, Simes RJ, Chalchal H, Shapiro JD, Robitaille S, Price TJ, Shepherd L, Au HJ, Langer C, Moore MJ and Zalcberg JR: K-ras mutations and benefit from cetuximab in advanced colorectal cancer. *The New England journal of medicine* 359: 1757-1765, 2008.
- 53 Bonner JA, Harari PM, Giralt J, Cohen RB, Jones CU, Sur RK, Raben D, Baselga J, Spencer SA, Zhu J, Youssoufian H, Rowinsky EK and Ang KK: Radiotherapy plus cetuximab for locoregionally advanced head and neck cancer: 5-year survival data from a phase 3 randomised trial, and relation between cetuximab-induced rash and survival. *The lancet oncology* 11: 21-28, 2010.
- 54 Vermorken JB, Trigo J, Hitt R, Koralewski P, Diaz-Rubio E, Rolland F, Knecht R, Amellal N, Schueler A and Baselga J: Open-label, uncontrolled, multicenter phase II study to evaluate the efficacy and toxicity of cetuximab as a single agent in patients with recurrent and/or metastatic squamous cell carcinoma of the head and neck who failed to respond to platinum-based therapy. *Journal of clinical oncology: official journal of the American Society of Clinical Oncology* 25: 2171-2177, 2007.
- 55 Patel D, Bassi R, Prewett M, Hicklin DJ and Kang X: Anti-epidermal growth factor receptor monoclonal antibody cetuximab inhibits EGFR/HER-2 heterodimerization and activation. *International journal of oncology* 34: 25-32, 2009.

- 56 Zhang J, Ji J, Yuan F, Ma T, Ye ZB, Yu YY, Liu BY and Zhu ZG: EGFR-blockade by antibody Cetuximab inhibits the growth of human gastric cancer xenograft in nude mice and its possible mechanism. *Zhonghua zhong liu za zhi [Chinese journal of oncology]* 31: 85-89, 2009.
- 57 Enzinger PC, Burtress B, Hollis D, Niedzwiecki D, Ilson D, Benson AB, Mayer RJ and Goldberg RM: CALGB 80403/ECOG 1206: A randomized phase II study of three standard chemotherapy regimens (ECF, IC, FOLFOX) plus cetuximab in metastatic esophageal and GE junction cancer. *ASCO Meeting Abstracts* 28: 4006, 2010.
- 58 Lorenzen S, Schuster T, Porschen R, Al-Batran S-E, Hofheinz R, Thuss-Patience P, Moehler M, Grabowski P, Arnold D, Greten T, Müller L, Röthling N, Peschel C, Langer R and Lordick F: Cetuximab plus cisplatin–5-fluorouracil *versus* cisplatin–5-fluorouracil alone in first-line metastatic squamous cell carcinoma of the esophagus: a randomized phase II study of the Arbeitsgemeinschaft Internistische Onkologie. *Annals of Oncology* 20: 1667-1673, 2009.
- 59 Lordick F, Luber B, Lorenzen S, Hegewisch-Becker S, Folprecht G, Woll E, Decker T, Endlicher E, Rothling N, Schuster T, Keller G, Fend F and Peschel C: Cetuximab plus oxaliplatin/leucovorin/5-fluorouracil in first-line metastatic gastric cancer: a phase II study of the Arbeitsgemeinschaft Internistische Onkologie (AIO). *Br J Cancer* 102: 500-505, 2010.
- 60 Yeh K, Hsu C, Hsu C, Lin C, Shen Y, Wu S, Chiou T, Chao Y and Cheng A: Phase II study of cetuximab plus weekly cisplatin and 24-hour infusion of high-dose 5-fluorouracil and leucovorin for the first-line treatment of advanced gastric cancer. *ASCO Meeting Abstracts* 27: 4567, 2009.
- 61 Kim C, Lee JL, Ryu MH, Chang HM, Kim TW, Lim HY, Kang HJ, Park YS, Ryoo BY and Kang YK: A prospective phase II study of cetuximab in combination with XELOX (capecitabine and oxaliplatin) in patients with metastatic and/or recurrent advanced gastric cancer. *Investigational new drugs* 29: 366-373, 2011.
- 62 Schönnemann KR, Yilmaz M, Bjerregaard JK, Nielsen KM and Pfeiffer P: Phase II study of biweekly cetuximab in combination with irinotecan as second-line treatment in patients with platinum-resistant gastro-oesophageal cancer. *Eur J Cancer* 48: 510-517, 2012.
- 63 Park SR, Kook MC, Choi IJ, Kim CG, Lee JY, Cho SJ, Kim YW, Ryu KW, Lee JH, Lee JS, Park YI and Kim NK: Predictive factors for the efficacy of cetuximab plus chemotherapy as salvage therapy in metastatic gastric cancer patients. *Cancer chemotherapy and pharmacology* 65: 579-587, 2010.
- 64 Ku GY, Shah MA, Tang LH, Miron B, Kelsen DP and Ilson DH: Cetuximab (C225) plus irinotecan/cisplatin (CPT/Cis) for CPT/Cis-refractory esophageal cancer. *ASCO Meeting Abstracts* 26: 15580, 2008.
- 65 Schönnemann KR, Yilmaz M, Bjerregaard JK, Nielsen KM and Pfeiffer P: Phase II study of biweekly cetuximab in combination with irinotecan as second-line treatment in patients with platinum-resistant gastro-oesophageal cancer. *Eur J Cancer* 2012.
- 66 Li J, Liu X, Wang BY, Guo WJ, Yin JL, Zhu XD, Zhang J and Liu T: Phase II study of cetuximab in combination with modified FOLFIRI in patients with advanced gastric cancer who failed first-line chemotherapy (EFFI study). *ASCO Meeting Abstracts* 28: 4107, 2010.
- 67 Gold PJ, Goldman B, Iqbal S, Leichman LP, Lenz HJ and Blanke CD: Cetuximab as second-line therapy in patients with metastatic esophageal cancer: A phase II Southwest Oncology Group Study. *ASCO Meeting Abstracts* 26: 4536, 2008.
- 68 Chan JA, Blaszkowsky LS, Enzinger PC, Ryan DP, Abrams TA, Zhu AX, Temel JS, Schrag D, Bhargava P, Meyerhardt JA, Wolpin BM, Fidias P, Zheng H, Florio S, Regan E and Fuchs CS: A multicenter phase II trial of single-agent cetuximab in advanced esophageal and gastric adenocarcinoma. *Annals of oncology: official journal of the European Society for Medical Oncology/ESMO* 22: 1367-1373, 2011.
- 69 Lee MS, Mamon HJ, Hong TS, Choi NC, Fidias PM, Kwak EL, Meyerhardt JA, Ryan DP, Bueno R, Donahue DM, Jaklitsch MT, Lanuti M, Rattner DW, Fuchs CS and Enzinger PC: Preoperative cetuximab, irinotecan, cisplatin, and radiation therapy for patients with locally advanced esophageal cancer. *The oncologist* 18: 281-287, 2013.
- 70 Safran H, Suntharalingam M, Dipetrillo T, Ng T, Doyle LA, Krasna M, Plette A, Evans D, Wanebo H, Akerman P, Spector J, Kennedy N and Kennedy T: Cetuximab With Concurrent Chemoradiation for Esophagogastric Cancer: Assessment of Toxicity. *International Journal of Radiation Oncology* Biology*Physics* 70: 391-395, 2008.
- 71 Ruhstaller T, Pless M, Dietrich D, Kranzbuehler H, von Moos R, Moosmann P, Montemurro M, Schneider PM, Rauch D, Gautschi O, Mingrone W, Widmer L, Inauen R, Brauchli P and Hess V: Cetuximab in Combination With Chemoradiotherapy Before Surgery in Patients With Resectable, Locally Advanced Esophageal Carcinoma: A Prospective, Multicenter Phase IB/II Trial (SAKK 75/06). *Journal of Clinical Oncology* 29: 626-631, 2011.
- 72 De Vita F, Orditura M, Innocente R, Vecchione L, Pinto C, Chiarion Sileni V, Martinelli E, Ruol A, Catalano G and Ciardiello F: A multicenter phase II study of induction CT with FOLFOX-4 and cetuximab followed by RT and cetuximab in locally advanced esophageal cancer (LAEC). *ASCO Meeting Abstracts* 27: 4546, 2009.
- 73 De Vita F, Orditura M, Martinelli E, Vecchione L, Innocenti R, Sileni VC, Pinto C, Di Maio M, Farella A, Troiani T, Morgillo F, Napolitano V, Ancona E, Di Martino N, Ruol A, Galizia G, Del Genio A and Ciardiello F: A multicenter phase II study of induction chemotherapy with FOLFOX-4 and cetuximab followed by radiation and cetuximab in locally advanced oesophageal cancer. *Br J Cancer* 104: 427-432, 2011.
- 74 Tomblyn MB, Goldman BH, Thomas CR Jr., Benedetti JK, Lenz HJ, Mehta V, Beeker T, Gold PJ, Abbruzzese JL and Blanke CD: Cetuximab plus cisplatin, irinotecan, and thoracic radiotherapy as definitive treatment for locally advanced, unresectable esophageal cancer: a phase-II study of the SWOG (S0414). *Journal of thoracic oncology: official publication of the International Association for the Study of Lung Cancer* 7: 906-912, 2012.
- 75 Chen Y, Wu X, Bu S, He C, Wang W, Liu J, Guo W, Tan B, Wang Y and Wang J: Promising outcomes of definitive chemoradiation and cetuximab for patients with esophageal squamous cell carcinoma. *Cancer Sci* 103: 1979-1984, 2012.
- 76 Rao S, Starling N, Cunningham D, Sumpter K, Gilligan D, Ruhstaller T, Valladares-Ayerbes M, Wilke H, Archer C, Kurek R, Beadman C and Oates J: Matuzumab plus epirubicin, cisplatin and capecitabine (ECX) compared with epirubicin, cisplatin and capecitabine alone as first-line treatment in patients with advanced oesophago-gastric cancer: a randomised, multicentre open-label phase II study. *Annals of Oncology* 21: 2213-2219, 2010.

- 77 Grothey A: EGFR Antibodies in Colorectal Cancer: Where Do They Belong? *Journal of Clinical Oncology* 28: 4668-4670, 2010.
- 78 Okines AF, Ashley SE, Cunningham D, Oates J, Turner A, Webb J, Saffery C, Chua YJ and Chau I: Epirubicin, oxaliplatin and capecitabine with or without panitumumab for advanced esophagogastric cancer: dose-finding study for the prospective multicenter, randomized, phase II/III REAL-3 trial. *Journal of clinical oncology: official journal of the American Society of Clinical Oncology* 28: 3945-3950, 2010.
- 79 Waddell T, Chau I, Cunningham D, Gonzalez D, Frances A, Okines C, Wotherspoon A, Saffery C, Middleton G, Wadsley J, Ferry D, Mansoor W, Crosby T, Coxon F, Smith D, Waters J, Iveson T, Falk S, Slater S, Peckitt C and Barbachano Y: Epirubicin, oxaliplatin, and capecitabine with or without panitumumab for patients with previously untreated advanced oesophagogastric cancer (REAL3): a randomised, open-label phase 3 trial. *The lancet oncology* 14: 481-489, 2013.
- 80 Waddell TS, Chau I, Barbachano Y, Gonzalez de Castro D, Wotherspoon A, Saffery C, Middleton GW, Wadsley J, Ferry DR, Mansoor W, Crosby TDL, Coxon FY, Smith D, Waters JS, Iveson T, Falk S, Slater S, Okines AFC and Cunningham D: A randomized, multicenter trial of epirubicin, oxaliplatin, and capecitabine (EOC) plus panitumumab in advanced esophagogastric cancer (REAL3). *ASCO Meeting Abstracts* 30: LBA4000, 2012.
- 81 Okines AF, Gonzalez de Castro D, Cunningham D, Chau I, Langley RE, Thompson LC, Stenning SP, Saffery C, Barbachano Y, Coxon F, Middleton G, Ferry D, Crosby T, Madhusudan S, Wadsley J, Waters J, Hall M, Swinson D, Robinson A, Smith D, Reis-Filho JS, Waddell TS, Puckey L, Hulkki Wilson S, Eltahir Z, Band M and Wotherspoon A: Biomarker analysis in oesophagogastric cancer: Results from the REAL3 and TransMAGIC trials. *Eur J Cancer* 2013.
- 82 Allan DG: Nimotuzumab: evidence of clinical benefit without rash. *The oncologist* 10: 760-761, 2005.
- 83 Ling Y, Chen J, Tao M, Chu X and Zhang X: A pilot study of nimotuzumab combined with cisplatin and 5-FU in patients with advanced esophageal squamous cell carcinoma. *Journal of thoracic disease* 4: 58-62, 2012.
- 84 Chi Y, Zheng Z, Zhou A, Yang L, Qu T, Jiang W, Shi S, Sun Y, Song Y, Kang S and Wang J: Randomized, single-centered, phase II clinical trial of nimotuzumab plus cisplatin and S-1 as first-line therapy in patients with advanced gastric cancer. *ASCO Meeting Abstracts* 29: e21021, 2011.
- 85 Ramos-Suzarte M, Lorenzo-Luaces P, Lazo NG, Perez ML, Soriano JL, Gonzalez CE, Hernandez IM, Albuena YA, Moreno BP, Alvarez ES, Callejo IP, Alert J, Martell JA, Gonzalez YS, Gonzalez YS, Astudillo de la Vega H, Ruiz-Garcia EB and Ramos TC: Treatment of malignant, non-resectable, epithelial origin esophageal tumours with the humanized anti-epidermal growth factor antibody nimotuzumab combined with radiation therapy and chemotherapy. *Cancer biology & therapy* 13: 600-605, 2012.
- 86 Zhang X, Lu M, Wang X, Li J, Li Y, Li J, Zhang X, Gao J, Zhou J, Lu Z, Gong J, Jia J, Cui Y, Yu J and Shen L: Nimotuzumab plus paclitaxel and cisplatin as first-line treatment for esophageal squamous cell cancer: A single center prospective clinical trial. *ASCO Meeting Abstracts* 31: 4097, 2013.
- 87 Wang J-W, Chi Y, Zheng Z-x, Qu T, Zhou A-P, Yang L, Jiang W-c, Shi S-z, Sun Y-k, Song Y and Kang S-y: Randomized, single-centered, phase II clinical trial of nimotuzumab plus cisplatin and S-1 as first-line therapy in patients with advanced gastric cancer. *ASCO Meeting Abstracts* 30: e14668, 2012.
- 88 Franklin MC, Carey KD, Vajdos FF, Leahy DJ, de Vos AM and Sliwkowski MX: Insights into ErbB signaling from the structure of the ErbB2-pertuzumab complex. *Cancer cell* 5(4): 317-328, 2004.
- 89 Scheuer W, Friess T, Burtscher H, Bossenmaier B, Endl J and Hasmann M: Strongly Enhanced Antitumor Activity of Trastuzumab and Pertuzumab Combination Treatment on HER2-Positive Human Xenograft Tumor Models. *Cancer research* 69: 9330-9336, 2009.
- 90 Yamashita-Kashima Y, Iijima S, Yoroze K, Furugaki K, Kurasawa M, Ohta M and Fujimoto-Ouchi K: Pertuzumab in Combination with Trastuzumab Shows Significantly Enhanced Antitumor Activity in HER2-Positive Human Gastric Cancer Xenograft Models. *Clinical Cancer Research* 17: 5060-5070, 2011.
- 91 Mendelsohn J: Epidermal growth factor receptor inhibition by a monoclonal antibody as anticancer therapy. *Clinical Cancer Research* 3: 2703-2707, 1997.
- 92 Shepherd FA, Rodrigues Pereira J, Ciuleanu T, Tan EH, Hirsh V, Thongprasert S, Campos D, Maoleekoonpiroj S, Smylie M, Martins R, van Kooten M, Dediu M, Findlay B, Tu D, Johnston D, Bezjak A, Clark G, Santabarbara P, Seymour L and National Cancer Institute of Canada Clinical Trials G: Erlotinib in previously treated non-small-cell lung cancer. *The New England journal of medicine* 353: 123-132, 2005.
- 93 Moore MJ, Goldstein D, Hamm J, Figer A, Hecht JR, Gallinger S, Au HJ, Murawa P, Walde D, Wolff RA, Campos D, Lim R, Ding K, Clark G, Voskoglou-Nomikos T, Ptasynski M, Parulekar W and National Cancer Institute of Canada Clinical Trials G: Erlotinib plus gemcitabine compared with gemcitabine alone in patients with advanced pancreatic cancer: a phase III trial of the National Cancer Institute of Canada Clinical Trials Group. *Journal of clinical oncology: official journal of the American Society of Clinical Oncology* 25: 1960-1966, 2007.
- 94 Rodriguez CP, Adelstein DJ, Rybicki LA, Rice TW, Videtic GM, Saxton JP, Murthy SC, Mason DP and Ives DI: A phase II trial of perioperative concurrent chemoradiotherapy (CCRT) and gefitinib (G) in locally advanced esophagus (E) and gastroesophageal junction (GEJ) cancer. *ASCO Meeting Abstracts* 26: 4547, 2008.
- 95 Janmaat ML, Gallegos-Ruiz MI, Rodriguez JA, Meijer GA, Vervenne WL, Richel DJ, Van Groeningen C and Giaccone G: Predictive Factors for Outcome in a Phase II Study of Gefitinib in Second-Line Treatment of Advanced Esophageal Cancer Patients. *Journal of Clinical Oncology* 24: 1612-1619, 2006.
- 96 Adelstein DJ, Rodriguez CP, Rybicki LA, Ives DI and Rice TW: A phase II trial of gefitinib for recurrent or metastatic cancer of the esophagus or gastroesophageal junction. *Investigational new drugs* 2011.
- 97 Li G, Hu W, Wang J, Deng X, Zhang P, Zhang X, Xie C and Wu S: Phase II study of concurrent chemoradiation in combination with erlotinib for locally advanced esophageal carcinoma. *Int J Radiat Oncol Biol Phys* 78: 1407-1412, 2010.
- 98 Wainberg ZA, Lin LS, DiCarlo B, Dao KM, Patel R, Park DJ, Wang HJ, Elashoff R, Ryba N and Hecht JR: Phase II trial of modified FOLFOX6 and erlotinib in patients with metastatic or advanced adenocarcinoma of the oesophagus and gastro-oesophageal junction. *British journal of cancer* 105: 760-765, 2011.

- 99 Dragovich T, McCoy S, Fenoglio-Preiser CM, Wang J, Benedetti JK, Baker AF, Hackett CB, Urba SG, Zaner KS, Blanke CD and Abbruzzese JL: Phase II Trial of Erlotinib in Gastroesophageal Junction and Gastric Adenocarcinomas: SWOG 0127. *Journal of Clinical Oncology* 24: 4922-4927, 2006.
- 100 Xia W, Bisi J, Strum J, Liu L, Carrick K, Graham KM, Treece AL, Hardwicke MA, Dush M, Liao Q, Westlund RE, Zhao S, Bacus S and Spector NL: Regulation of survivin by ErbB2 signaling: therapeutic implications for ErbB2-overexpressing breast cancers. *Cancer research* 66: 1640-1647, 2006.
- 101 Xia W, Gerard CM, Liu L, Baudson NM, Ory TL and Spector NL: Combining lapatinib (GW572016), a small molecule inhibitor of ErbB1 and ErbB2 tyrosine kinases, with therapeutic anti-ErbB2 antibodies enhances apoptosis of ErbB2-overexpressing breast cancer cells. *Oncogene* 24: 6213-6221, 2005.
- 102 Kim JW, Kim HP, Im SA, Kang S, Hur HS, Yoon YK, Oh DY, Kim JH, Lee DS, Kim TY and Bang YJ: The growth inhibitory effect of lapatinib, a dual inhibitor of EGFR and HER2 tyrosine kinase, in gastric cancer cell lines. *Cancer letters* 272: 296-306, 2008.
- 103 Wainberg ZA: Lapatinib, a dual EGFR and HER2 kinase inhibitor, selectively inhibits HER2-amplified human gastric cancer cells and is synergistic with trastuzumab *in vitro* and *in vivo*. *Clin Cancer Res* 16: 1509-1519, 2010.
- 104 Iqbal S, Goldman B, Lenz HJ, Fenoglio-Preiser CM and Blanke CD: S0413: A phase II SWOG study of GW572016 (lapatinib) as first line therapy in patients (pts) with advanced or metastatic gastric cancer. *ASCO Meeting Abstracts* 25: 4621, 2007.
- 105 Galsky MD, Von Hoff DD, Neubauer M, Anderson T, Fleming M, Sweetman RW, Mahoney J, Midwinter D, Vocila L and Zaks TZ: Target-specific, histology-independent, randomized discontinuation study of lapatinib in patients with HER2-amplified solid tumors. *ASCO Meeting Abstracts* 27: 3541, 2009.
- 106 Hecht JR, Bang Y-J, Qin S, Chung H-C, Xu J-M, Park JO, Jeziorski K, Shparyk Y, Hoff PM, Sobrero AF, Salman P, Li J, Protsenko S, Buyse ME, Afenjar K, Kaneko T, Kemner A, Santillana S, Press MF and Slamon DJ: Lapatinib in combination with capecitabine plus oxaliplatin (CapeOx) in HER2-positive advanced or metastatic gastric, esophageal, or gastroesophageal adenocarcinoma (AC): The TRIO-013/LOGiC Trial. *ASCO Meeting Abstracts* 31: LBA4001, 2013.
- 107 Oh D-Y, Lee K-W, Cho JY, Kang WK, Rha SY and Bang Y-J: A phase II open-label trial of dacomitinib monotherapy in patients with HER2-positive advanced gastric cancer after failure of at least one prior chemotherapy regimen. *ASCO Meeting Abstracts* 30: 54, 2012.
- 108 Hsieh AC and Moasser MM: Targeting HER proteins in cancer therapy and the role of the non-target HER3. *Br J Cancer* 97: 453-457, 2007.
- 109 Holbro T, Beerli RR, Maurer F, Koziczak M, Barbas CF, 3rd and Hynes NE: The ErbB2/ErbB3 heterodimer functions as an oncogenic unit: ErbB2 requires ErbB3 to drive breast tumor cell proliferation. *Proceedings of the National Academy of Sciences of the United States of America* 100: 8933-8938, 2003.
- 110 Brachmann SM, Hofmann I, Schnell C, Fritsch C, Wee S, Lane H, Wang S, Garcia-Echeverria C and Maira SM: Specific apoptosis induction by the dual PI3K/mTor inhibitor NVP-BEZ235 in HER2 amplified and PIK3CA mutant breast cancer cells. *Proceedings of the National Academy of Sciences of the United States of America* 106: 22299-22304, 2009.
- 111 Hayashi M, Inokuchi M, Takagi Y, Yamada H, Kojima K, Kumagai J, Kawano T and Sugihara K: High Expression of HER3 Is Associated with a Decreased Survival in Gastric Cancer. *Clinical Cancer Research* 14: 7843-7849, 2008.
- 112 Feng SM, Sartor CI, Hunter D, Zhou H, Yang X, Caskey LS, Dy R, Muraoka-Cook RS and Earp HS, 3rd: The HER4 cytoplasmic domain, but not its C terminus, inhibits mammary cell proliferation. *Molecular endocrinology (Baltimore, Md)* 21: 1861-1876, 2007.
- 113 Cunningham D, Humblet Y, Siena S, Khayat D, Bleiberg H, Santoro A, Bets D, Mueser M, Harstrick A, Verslype C, Chau I and Van Cutsem E: Cetuximab monotherapy and cetuximab plus irinotecan in irinotecan-refractory metastatic colorectal cancer. *The New England journal of medicine* 351: 337-345, 2004.
- 114 Khambata-Ford S, Harbison CT, Hart LL, Awad M, Xu LA, Horak CE, Dakhil S, Hermann RC, Lynch TJ and Weber MR: Analysis of potential predictive markers of cetuximab benefit in BMS099, a phase III study of cetuximab and first-line taxane/carboplatin in advanced non-small-cell lung cancer. *Journal of clinical oncology: official journal of the American Society of Clinical Oncology* 28: 918-927, 2010.
- 115 Sartore-Bianchi A, Bencardino K, Cassingena A, Venturini F, Funaioli C, Cipani T, Amatu A, Pietrogiovanna L, Schiavo R, Di Nicolantonio F, Artale S, Bardelli A and Siena S: Therapeutic implications of resistance to molecular therapies in metastatic colorectal cancer. *Cancer Treatment Reviews* 36(Suppl 3): S1-S5, 2010.
- 116 Lordick F, Lorenzen S, Hegewisch-Becker S, Folprecht G, Woll E, Decker T, Endlicher E, Rothling N, Fend F and Peschel C: Cetuximab plus weekly oxaliplatin/5FU/FA (FUFOX) in 1st line metastatic gastric cancer. Final results from a multicenter phase II study of the AIO upper GI study group. *ASCO Meeting Abstracts* 25: 4526, 2007.
- 117 Pinto C, Di Fabio F, Barone C, Siena S, Falcone A, Cascinu S, Rojas Llimpe FL, Stella G, Schinzari G, Artale S, Mutri V, Giaquinta S, Giannetta L, Bardelli A and Martoni AA: Phase II study of cetuximab in combination with cisplatin and docetaxel in patients with untreated advanced gastric or gastro-oesophageal junction adenocarcinoma (DOCETUX study). *Br J Cancer* 101: 1261-1268, 2009.
- 118 Moehler M, Mueller A, Trarbach T, Lordick F, Seufferlein T, Kubicka S, Geissler M, Schwarz S, Galle PR, Kanzler S and German Arbeitsgemeinschaft Internistische O: Cetuximab with irinotecan, folinic acid and 5-fluorouracil as first-line treatment in advanced gastroesophageal cancer: a prospective multi-center biomarker-oriented phase II study. *Annals of oncology: official journal of the European Society for Medical Oncology/ESMO* 22: 1358-1366, 2011.
- 119 Han SW, Oh DY, Im SA, Park SR, Lee KW, Song HS, Lee NS, Lee KH, Choi IS, Lee MH, Kim MA, Kim WH, Bang YJ and Kim TY: Phase II study and biomarker analysis of cetuximab combined with modified FOLFOX6 in advanced gastric cancer. *Br J Cancer* 100: 298-304, 2009.
- 120 De Roock W, Claes B, Bernasconi D, De Schutter J, Biesmans B, Fountzilas G, Kalogeras KT, Kotoula V, Papamichael D, Laurent-Puig P, Penault-Llorca F, Rougier P, Vincenzi B, Santini D, Tonini G, Cappuzzo F, Frattini M, Molinari F, Saletti P, De Dosso S, Martini M, Bardelli A, Siena S, Sartore-Bianchi A, Tabernero J, Macarulla T, Di Fiore F, Gangloff AO, Ciardiello F, Pfeiffer P, Qvortrup C, Hansen TP, Van Cutsem E, Piessevaux H, Lambrechts

- D, Delorenzi M and Tejpar S: Effects of KRAS, BRAF, NRAS, and PIK3CA mutations on the efficacy of cetuximab plus chemotherapy in chemotherapy-refractory metastatic colorectal cancer: a retrospective consortium analysis. *The lancet oncology* 11: 753-762, 2010.
- 121 Allegra CJ, Jessup JM, Somerfield MR, Hamilton SR, Hammond EH, Hayes DF, McAllister PK, Morton RF and Schilsky RL: American Society of Clinical Oncology provisional clinical opinion: testing for KRAS gene mutations in patients with metastatic colorectal carcinoma to predict response to anti-epidermal growth factor receptor monoclonal antibody therapy. *Journal of clinical oncology: official journal of the American Society of Clinical Oncology* 27: 2091-2096, 2009.
- 122 Bardelli A and Siena S: Molecular mechanisms of resistance to cetuximab and panitumumab in colorectal cancer. *Journal of clinical oncology: official journal of the American Society of Clinical Oncology* 28: 1254-1261, 2010.
- 123 Lee SH, Lee JW, Soung YH, Kim HS, Park WS, Kim SY, Lee JH, Park JY, Cho YG, Kim CJ, Nam SW, Kim SH, Lee JY and Yoo NJ: BRAF and KRAS mutations in stomach cancer. *Oncogene* 22: 6942-6945, 2003.
- 124 Kim JJ, Park JH, Kang HC, Shin Y, Park HW, Park HR, Ku JL, Lim SB and Park JG: Mutational analysis of BRAF and K-ras in gastric cancers: absence of BRAF mutations in gastric cancers. *Human genetics* 114: 118-120, 2003.
- 125 Nanus DM, Kelsen DP, Mentle IR, Altorki N and Albino AP: Infrequent point mutations of ras oncogenes in gastric cancers. *Gastroenterology* 98: 955-960, 1990.
- 126 Oliveira C, Pinto M, Duval A, Brennetot C, Domingo E, Espin E, Armengol M, Yamamoto H, Hamelin R, Seruca R and Schwartz S Jr.: BRAF mutations characterize colon but not gastric cancer with mismatch repair deficiency. *Oncogene* 22: 9192-9196, 2003.
- 127 Stella G: KRAS and BRAF mutational status as response biomarkers to cetuximab combination therapy in advanced gastric cancer patients [abstract]. *J Clin Oncol* 27: a15503, 2009.
- 128 Esteva FJ, Yu D, Hung MC and Hortobagyi GN: Molecular predictors of response to trastuzumab and lapatinib in breast cancer. *Nature reviews Clinical oncology* 7: 98-107, 2010.
- 129 Nagata Y, Lan KH, Zhou X, Tan M, Esteva FJ, Sahin AA, Klos KS, Li P, Monia BP, Nguyen NT, Hortobagyi GN, Hung MC and Yu D: PTEN activation contributes to tumor inhibition by trastuzumab, and loss of PTEN predicts trastuzumab resistance in patients. *Cancer cell* 6: 117-127, 2004.
- 130 Pinto C, Di Fabio F, Siena S, Cascinu S, Rojas Llimpe F, Ceccarelli C, Mutri V, Giannetta L, Giaquinta S, Funaioli C, Berardi R, Longobardi C, Piana E and Martoni A: Phase II study of cetuximab in combination with FOLFIRI in patients with untreated advanced gastric or gastroesophageal junction adenocarcinoma (FOLCETUX study). *Annals of Oncology* 18: 510-517, 2007.
- 131 Ciardiello F, Bianco R, Caputo R, Caputo R, Damiano V, Troiani T, Melisi D, De Vita F, De Placido S, Bianco AR and Tortora G: Antitumor Activity of ZD6474, a Vascular Endothelial Growth Factor Receptor Tyrosine Kinase Inhibitor, in Human Cancer Cells with Acquired Resistance to Anti-epidermal Growth Factor Receptor Therapy. *Clinical Cancer Research* 10: 784-793, 2004.
- 132 Bianco R, Rosa R, Damiano V, Daniele G, Gelardi T, Garofalo S, Tarallo V, De Falco S, Melisi D, Benelli R, Albini A, Ryan A, Ciardiello F and Tortora G: Vascular Endothelial Growth Factor Receptor-1 Contributes to Resistance to Anti-Epidermal Growth Factor Receptor Drugs in Human Cancer Cells. *Clinical Cancer Research* 14: 5069-5080, 2008.
- 133 Heindl S, Eggenstein E, Keller S, Kneissl J, Keller G, Mutze K, Rauser S, Gasteiger G, Drexler I, Hapfelmeier A, Hofler H and Lubert B: Relevance of MET activation and genetic alterations of KRAS and E-cadherin for cetuximab sensitivity of gastric cancer cell lines. *Journal of cancer research and clinical oncology* 2012.
- 134 Wheeler DL, Huang S, Kruser TJ, Nechrebecki MM, Armstrong EA, Benavente S, Gondi V, Hsu KT and Harari PM: Mechanisms of acquired resistance to cetuximab: role of HER (ErbB) family members. *Oncogene* 27: 3944-3956, 2008.
- 135 Li C, Iida M, Dunn EF, Ghia AJ and Wheeler DL: Nuclear EGFR contributes to acquired resistance to cetuximab. *Oncogene* 28: 3801-3813, 2009.
- 136 Normanno N, Tejpar S, Morgillo F, De Luca A, Van Cutsem E and Ciardiello F: Implications for KRAS status and EGFR-targeted therapies in metastatic CRC. *Nature reviews Clinical oncology* 6: 519-527, 2009.
- 137 Nahta R, Yuan LXH, Zhang B, Kobayashi R and Esteva FJ: Insulin-like Growth Factor-I Receptor/Human Epidermal Growth Factor Receptor 2 Heterodimerization Contributes to Trastuzumab Resistance of Breast Cancer Cells. *Cancer research* 65: 11118-11128, 2005.
- 138 Bachman KE, Argani P, Samuels Y, Silliman N, Ptak J, Szabo S, Konishi H, Karakas B, Blair BG, Lin C, Peters BA, Velculescu VE and Park BH: The PIK3CA gene is mutated with high frequency in human breast cancers. *Cancer Biology & Therapy* 3: 772-775, 2004.
- 139 Carpten JD, Faber AL, Horn C, Donoho GP, Briggs SL, Robbins CM, Hostetter G, Boguslawski S, Moses TY, Savage S, Uhlik M, Lin A, Du J, Qian Y-W, Zeckner DJ, Tucker-Kellogg G, Touchman J, Patel K, Mousses S, Bittner M, Schevitz R, Lai M-HT, Blanchard KL and Thomas JE: A transforming mutation in the pleckstrin homology domain of AKT1 in cancer. *Nature* 448: 439-444, 2007.
- 140 Saal LH, Johansson P, Holm K, Gruvberger-Saal SK, She Q-B, Maurer M, Koujak S, Ferrando AA, Malmström P, Memeo L, Isola J, Bendahl P-O, Rosen N, Hübshoos H, Ringnér M, Borg Å and Parsons R: Poor prognosis in carcinoma is associated with a gene expression signature of aberrant PTEN tumor suppressor pathway activity. *Proceedings of the National Academy of Sciences* 104: 7564-7569, 2007.
- 141 Itakura Y, Sasano H, Shiga C, Furukawa Y, Shiga K, Mori S and Nagura H: Epidermal growth factor receptor overexpression in esophageal carcinoma. An immunohistochemical study correlated with clinicopathologic findings and DNA amplification. *Cancer* 74: 795-804, 1994.
- 142 Reichelt U, Duesedau P, Tsourlakis M, Quaas A, Link BC, Schurr PG, Kaifi JT, Gros SJ, Yekebas EF, Marx A, Simon R, Izbicki JR and Sauter G: Frequent homogeneous HER-2 amplification in primary and metastatic adenocarcinoma of the esophagus. *Mod Pathol* 20: 120-129, 2007.
- 143 Hardwick RH, Barham CP, Ozua P, Newcomb PV, Savage P, Powell R, Rahamin J and Alderson D: Immunohistochemical detection of p53 and c-erbB-2 in oesophageal carcinoma; no correlation with prognosis. *European journal of surgical oncology: the journal of the European Society of Surgical Oncology and the British Association of Surgical Oncology* 23: 30-35, 1997.
- 144 Mimura K, Kono K, Hanawa M, Mitsui F, Sugai H, Miyagawa N, Ooi A and Fujii H: Frequencies of HER-2/neu expression and

- gene amplification in patients with oesophageal squamous cell carcinoma. *Br J Cancer* 92: 1253-1260, 2005.
- 145 Rossi E, Villanacci V, Bassotti G, Casa DD, Missale G, Minelli L and Cestari R: Her-2/neu in barrett esophagus: a comparative study between histology, immunohistochemistry, and fluorescence *in situ* hybridization. *Diagnostic molecular pathology: the American journal of surgical pathology, part B* 15: 125-130, 2006.
- 146 Takehana T, Kunitomo K, Kono K, Kitahara F, Iizuka H, Matsumoto Y, Fujino MA and Ooi A: Status of c-erbB-2 in gastric adenocarcinoma: a comparative study of immunohistochemistry, fluorescence *in situ* hybridization and enzyme-linked immunosorbent assay. *International journal of cancer Journal international du cancer* 98: 833-837, 2002.
- 147 Tanner M, Hollmen M, Junttila TT, Kapanen AI, Tammola S, Soini Y, Helin H, Salo J, Joensuu H, Sihvo E, Elenius K and Isola J: Amplification of HER-2 in gastric carcinoma: association with Topoisomerase IIalpha gene amplification, intestinal type, poor prognosis and sensitivity to trastuzumab. *Annals of oncology: official journal of the European Society for Medical Oncology/ESMO* 16: 273-278, 2005.
- 148 Park DI, Yun JW, Park JH, Oh SJ, Kim HJ, Cho YK, Sohn CI, Jeon WK, Kim BI, Yoo CH, Son BH, Cho EY, Chae SW, Kim EJ, Sohn JH, Ryu SH and Sepulveda AR: HER-2/neu amplification is an independent prognostic factor in gastric cancer. *Digestive diseases and sciences* 51: 1371-1379, 2006.
- 149 Hofmann M, Stoss O, Shi D, Buttner R, van de Vijver M, Kim W, Ochiai A, Ruschoff J and Henkel T: Assessment of a HER2 scoring system for gastric cancer: results from a validation study. *Histopathology* 52: 797-805, 2008.
- 150 Peng D, Sheta EA, Powell SM, Moskaluk CA, Washington K, Goldknopf IL and El-Rifai W: Alterations in Barrett's-related adenocarcinomas: a proteomic approach. *International journal of cancer Journal international du cancer* 122: 1303-1310, 2008.
- 151 Agarwala AK, Hanna N, McCollum A, Bechar N, DiMaio M, Yu M, Tong Y, Becerra CR and Choy H: Preoperative cetuximab and radiation (XRT) for patients (pts) with surgically resectable esophageal and gastroesophageal junction (GEJ) carcinomas: A pilot study from the Hoosier Oncology Group and the University of Texas Southwestern. *ASCO Meeting Abstracts* 27: 4557, 2009.
- 152 Ma HY, Newman E, Ryan T, Miller G, Sarpel U, Pachter HL, Cohen DJ, Choi H, Goldberg JD and Hochster HS: Neoadjuvant therapy of gastric cancer with cetuximab added to both irinotecan and cisplatin, followed by surgical resection and adjuvant chemoradiation. *ASCO Meeting Abstracts* 27: e15552, 2009.
- 153 Tebbutt NC, Parry MM, Zannino D, Strickland AH, Van Hazel GA, Pavlakis N, Ganju V, Mellor D, Dobrovic A and Gebbski VJ: Docetaxel plus cetuximab as second-line treatment for docetaxel-refractory oesophagogastric cancer: the AGITG ATTAX2 trial. *British journal of cancer* 108: 771-774, 2013.
- 154 Shi M, Ji J, Wu J, Ma T, Liu Y, Zhou CF, Su Y, Ye ZB, Zhang J and Zhu ZG: Cetuximab Combined With FOLFOX4 as the First-Line Treatment for Advanced Gastric Cancer: Report of 25 Cases from a Single Institution. *Hepato-gastroenterology* 59:2012.
- 155 Wöhl E, Greil R, Eisterer W, Bechter O, Fridrik MA, Grünberger B, Zabernigg A, Mayrbäurl B, Russ G, Dlska M, Obrist P and Thaler J: Oxaliplatin, Irinotecan and Cetuximab in Advanced Gastric Cancer. A Multicenter Phase II Trial (Gastric-2) of the Arbeitsgemeinschaft Medikamentöse Tumortherapie (AGMT). *Anticancer Research* 31: 4439-4443, 2011.
- 156 Zhang X, Xu J, Shen L, Wang J, Liang J, Xu N, Bai Y and Wang J: A phase II study of cetuximab (Cetuximab) with cisplatin and capecitabine (Xeloda) as 1st line treatment in advanced gastric cancer. *ASCO Meeting Abstracts* 26: 15663, 2008.
- 157 Bang YJ, Van Cutsem E, Feyereislova A, Chung HC, Shen L, Sawaki A, Lordick F, Ohtsu A, Omuro Y, Satoh T, Aprile G, Kulikov E, Hill J, Lehle M, Ruschoff J and Kang YK: Trastuzumab in combination with chemotherapy *versus* chemotherapy alone for treatment of HER2-positive advanced gastric or gastro-oesophageal junction cancer (ToGA): a phase 3, open-label, randomised controlled trial. *Lancet* 376: 687-697, 2010.
- 158 Koeda K, Sugimoto N, Tanaka J, Tsuda M, Okamoto W, Okuda H, Imamura H, Matsuyama J, Shimokawa T, Sakai D, Fukushima N, Kurokawa Y, Komatsu Y, Tsujinaka T and Furukawa H: A phase II study of new combination regimen with trastuzumab, S-1, and CDDP in HER2-positive advanced gastric cancer (HERBIS-1). *ASCO Meeting Abstracts* 31: 4072, 2013.
- 159 Iwasa S, Nishikawa K, Miki A, Noshiro H, Tsuburaya A, Nishida Y, Miwa H, Masuishi T, Yoshida K, Koda Y, Boku N, Yamada Y, Morita S, Sakamoto J, Saji S and Kitagawa Y: Multicenter, phase II study of trastuzumab and paclitaxel to treat HER2-positive, metastatic gastric cancer patients naive to trastuzumab (JFMC45-1102). *ASCO Meeting Abstracts* 31: 4096, 2013.
- 160 Tew W SM, Schwartz G *et al*: Phase II trial of erlotinib for second-line treatment in advanced esophageal cancer. *Proc Am Soc Clin Oncol GI Cancers Symposium* 23: 25a., 2005.
- 161 Javle M, Pande A, Iyer R, Yang G, LeVea C, Wilding G, Black J, Nava H and Nwogu C: Pilot study of gefitinib, oxaliplatin, and radiotherapy for esophageal adenocarcinoma: tissue effect predicts clinical response. *American journal of clinical oncology* 31: 329-334, 2008.
- 162 Sunpaweravong P, Sunpaweravong S, Sangthawan D, Puttawibul P and Mitamun W: Combination of gefitinib, cisplatin and 5-FU chemotherapy, and radiation therapy (RT) in newly-diagnosed patients with esophageal carcinoma. *ASCO Meeting Abstracts* 25: 4605, 2007.
- 163 Doi T KS, Siena S *et al*: Efficacy, tolerability and pharmacokinetics of gefitinib (ZD1839) in pretreated patients with metastatic gastric cancer. *Proc Am Soc Clin Oncol* 22: (abstr 1036), 2003.
- 164 Ferry DR, Anderson M, Beddard K, Tomlinson S, Atherfold P, Obszynska J, Harrison R and Jankowski J: A Phase II Study of Gefitinib Monotherapy in Advanced Esophageal Adenocarcinoma: Evidence of Gene Expression, Cellular, and Clinical Response. *Clinical Cancer Research* 13: 5869-5875, 2007.
- 165 Zhai Y, Hui Z, Wang J, Zou S, Liang J, Wang X, Lv J, Chen B, Zhu H and Wang L: Concurrent erlotinib and radiotherapy for chemoradiotherapy-intolerant esophageal squamous cell carcinoma patients: results of a pilot study. *Diseases of the esophagus: official journal of the International Society for Diseases of the Esophagus/ISDE* 2012.
- 166 Hecht J: Lapatinib monotherapy in recurrent upper gastrointestinal malignancy: phase II efficacy and biomarker analyses [abstract]. *Proceedings ASCO 2008 Gastrointestinal Cancers Symposium*: a43, 2008.

Received August 23, 2013
Revised September 17, 2013
Accepted September 18, 2013