

Hepatic Arterial Thrombosis: A Critical Complication During Combination Therapy of Arterial Chemoinfusion and Sorafenib

HIDEYUKI NISHIOFUKU, TOSHIHIRO TANAKA, HIROSHI ANAI, SATORU SUEYOSHI,
SHINSAKU MAEDA, TETSUYA MASADA and KIMIHIKO KICHIKAWA

Department of Radiology, Nara Medical University, Nara, Japan

Abstract. *Hepatic arterial infusion chemotherapy (HAIC) combined with sorafenib is considered to be a promising therapeutic strategy for patients with advanced hepatocellular carcinoma. However, this combination therapy carries the risk of hepatic arterial thrombosis (HAT), which interrupts the continuation of HAIC, due to the side-effects of sorafenib. This case demonstrates a complication of HAT which occurred during HAIC combined with sorafenib. HAT was detected early by angiography via an implantable port-catheter system and was successfully treated with catheter-directed thrombolysis.*

Recently, sorafenib (Nexavar®; Bayer Pharmaceuticals Corporation), an oral multikinase inhibitor that targets RAF serine/threonine kinases, vascular endothelial growth factor receptors (VEGFR) 1-3, platelet-derived growth factor receptor, FLT-3, c-KIT, and p38 tyrosine kinases (1), has become a standard treatment for advanced hepatocellular carcinoma (HCC). However, the outcome of patients treated with sorafenib-alone is limited. Response rates of 2% and median overall survival (OS) of 10.7 months have been reported (2). Hepatic arterial infusion chemotherapy (HAIC) using an implantable port-catheter system is a promising regional treatment, with response rates of 20-48% for advanced HCC (3). Therefore, HAIC combined with sorafenib could be expected to have therapeutic advantages compared with sorafenib monotherapy.

The patency of the hepatic artery is vital in order to allow for repeated HAIC. However, arterial thrombosis is a complication associated with the use of VEGF inhibitor and

the combination of the VEGF inhibitor with other systemic chemotherapies increases the complication rate of thrombosis (4). Implantation of a catheter in the hepatic artery and continuous arterial chemoinfusion would increase the risk of hepatic arterial thrombosis (HAT). Therefore, it is important to be fully aware of the possibility of this critical side-effect occurrence and to know how to manage this complication, when combination therapies with continuous HAIC and sorafenib are administered.

To date, there have been only two case reports regarding the use of continuous HAIC via an implantable port-catheter system combined with sorafenib (5, 6). To our knowledge, our report is the first describing the complication of HAT due to this combination therapy.

Case Report

A 65-year-old male with multiple HCCs, which had been uncontrollable with transcatheter arterial chemoembolization, underwent HAIC. An anticoagulant-coated tapered 5-F side-holed catheter (W-Spiral catheter; Piolax Medical Devices, Tokyo, Japan) was inserted into the left hepatic artery and the side hole was positioned in the proper hepatic artery (Figure 1a). The proximal end of the catheter was connected to an implantable port (Celsite Port; Toray Medical, Tokyo, Japan) that was embedded subcutaneously. The administration schedule of anticancer drugs was the following low-dose 5-fluorouracil (5-FU)-cisplatin (LFP): continuous 5-FU at 1250 mg for 5 days every week combined with low-dose cisplatin at 5-10 mg on days 1 to 5 for 30 min. Two months after the initiation of LFP therapy, the tumors had completely disappeared.

Even though LFP therapy was continued with the bi-weekly administration schedule as maintenance therapy, HCCs developed again after 1.5 years (Figure 1b). At the time, the patient had a high performance status and good liver function (Child-Pugh A). Therefore, we decided to change the LFP therapy to sorafenib monotherapy (400 mg twice daily). However, the sorafenib monotherapy was not effective and the tumors increased in size (Figure 1c). Thus,

Correspondence to: Hideyuki Nishiofuku, MD, Ph.D., Department of Radiology, Nara Medical University 840 Shijo-cho, Kashihara, 634-8522, Nara, Japan. Tel: +81 744298900, Fax: +81 744241988, e-mail: hmn@naramed-u.ac.jp

Key Words: Hepatic arterial infusion chemotherapy, sorafenib, arterial thrombosis, catheter-directed thrombolysis, implantable port-catheter system.

we started combination chemotherapy of sorafenib (200 mg twice daily) and bi-weekly LFP therapy. The patency of the hepatic artery was confirmed at the initiation of the combination therapy.

Computed-tomography for the evaluation in the first month after the combination therapy demonstrated tumor reduction. However, hepatic arterial occlusion, due to a thrombus, was found on the digital subtraction arteriography (DSA) *via* the implantable port-catheter system (Figure 1d). HAIC was consequently stopped and sorafenib monotherapy (400 mg twice daily) was continued. However, after four weeks, the tumors remarkably increased in size again.

We considered that HAIC was necessary to suppress the tumor growth. Therefore, two days after the termination of administration of sorafenib, catheter-directed thrombolysis (CDT) was attempted in order to recanalize the hepatic artery. Urokinase (10,000 U/h) was continuously infused through the implantable port-catheter system. Simultaneously, heparin was given intravenously at a dosage of 500 U/h. The activated partial thromboplastin time was monitored to maintain the value between 1.25 and 1.5 times in order to adjust the heparin doses. Four days after the initiation of the thrombolysis, DSA demonstrated that the HAT had almost disappeared (Figure 1e). HAIC alone was successfully re-started, and currently the tumors have been controlled for 6 months without the recurrence of HAT.

Discussion

Recent reports have suggested the combination therapy of sorafenib with other anticancer treatments to enhance therapeutic efficacy. Yang *et al.* reported a case in which the combination therapy of sorafenib and continuous HAIC successfully treated advanced HCC with portal vein tumor thrombosis (6). In our case, it is of interest that the combination therapy was effective even after the failure of each monotherapy using HAIC and sorafenib. Several previous pre-clinical and clinical studies showed the synergistic antitumor activity of 5-FU combined with sorafenib (7). Qun *et al.* reported a case similar to ours in which HAIC of 5-FU combined with sorafenib demonstrated effectiveness for cholangiocarcinoma which had been resistant to HAIC monotherapy (5).

Previous phase II studies showed that the LFP regimen using an implantable port-catheter system achieved high tumor response rates in patients with HCC. Recently, in Japan, a randomized controlled trial (SILIUS trial: LFP therapy alone *versus* LFP combined with sorafenib) was started (8). In the future, greater worldwide attention will be drawn to the effective use of the combination of HAIC with sorafenib in the treatment of patients with HCC.

Caution must be taken in regards to HAT, when continuous HAIC using an implantable port-catheter system

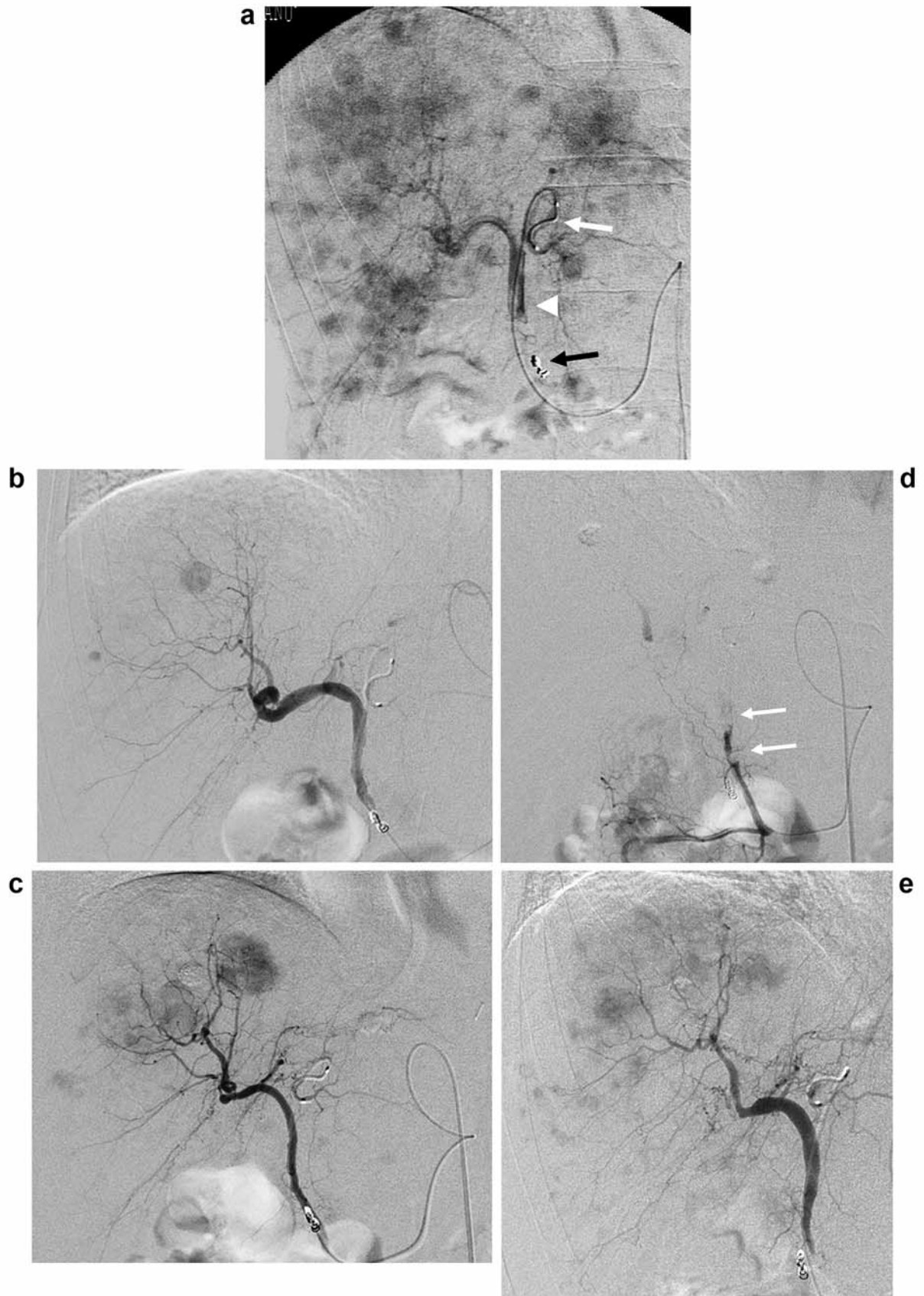
is combined with sorafenib. Arterial thrombus is a critical complication related to sorafenib use. The mechanism of thrombosis due to VEGF inhibitor is the result of the multiplicity of actions of VEGF on vascular walls and components of the coagulation system. Inhibition of VEGF reduces the regenerative capacity of endothelial cells and increases hematocrit and blood viscosity *via* overproduction of erythropoietin (9).

It has been reported that hepatic arterial occlusion during HAIC *via* an implantable port system is usually caused by the following: firstly, mechanical stimulation of the catheter tip against the arterial intima, and secondly, vascular endothelial injury by anticancer agents. The hepatic arterial patency rate has been reported to be 91% at 6 months (10). We considered that, in our case, the hepatic arterial occlusion was mainly related to the combination of HAIC and sorafenib, because hepatic arterial occlusion had not appeared during previous monotherapies using either HAIC- or sorafenib-alone, and the thrombus appeared early after the initiation of the combination therapy. In addition, the angiography showed unusual floating clots in the hepatic artery, which was a different finding from the usual hepatic arterial occlusion. HAIC monotherapy after the recanalization of the hepatic artery was conducted without further hepatic arterial occlusion. It is highly possible that HAIC escalated the thrombogenicity due to sorafenib.

HAIC monotherapy management requires angiography *via* an implantable port-catheter system to check the hepatic arterial flow, which is usually conducted every three months (10). Due to the high possibility of HAT, examinations at shorter intervals are required in combination therapy of HAIC and sorafenib. In our case, the first DSA was performed four weeks after the initiation of the combination therapy, and consequently, asymptomatic hepatic arterial occlusion was detected earlier.

→

Figure 1. *a*: Digital subtraction angiography (DSA) *via* an implantable port-catheter system, before hepatic arterial infusion chemotherapy, demonstrated multiple tumor stains of hepatocellular carcinoma (HCC). The catheter tip (white arrow) was introduced deeply into the left hepatic artery and the side hole (white arrow head) was positioned in the proper hepatic artery. The right gastric artery was embolized with the metallic coils (black arrow). *b*: DSA obtained 1.5 years after the initiation of the combination therapy demonstrated the recurrence of HCC. *c*: DSA obtained three months after sorafenib monotherapy demonstrated that HCC had increased in size and the hepatic artery was patent. *d*: DSA obtained one month after the initiation of the combination therapy of hepatic arterial infusion chemotherapy and sorafenib, demonstrated arterial occlusion and floating clots (arrows) in the proper hepatic artery. *e*: DSA after catheter-directed thrombolysis with urokinase demonstrated the recanalization of the hepatic artery.



It is well-known that sorafenib has another critical side-effect, that of hemorrhage (2). Severe gastric and brain hemorrhages due to sorafenib monotherapy have been reported (11, 12). Therefore, in our case, urokinase and heparin were not used as an initial treatment of the HAT. However, after the tumors re-increased in size, we determined that we had to administer urokinase and heparin in order to be able to continue HAIC. Two days before the start of urokinase and heparin administration, sorafenib was stopped, because sorafenib has a half-life of 25 to 48 h. In addition, we infused urokinase through the implantable port-catheter system. Several articles reported that CDT had a higher recanalization rate and a lower hemorrhagic rate compared with intravenous thrombolysis (13). The advantages of continuous infusion of urokinase compared with bolus injections were also reported.

As a preventive strategy with the combination of HAIC and sorafenib, concurrent anti-coagulation therapy during this combination therapy may be useful. However, caution must be taken regarding the side effect of hemorrhage.

In conclusion, this case report is the first regarding the critical complication of acute HAT, occurring during the combination therapy of HAIC and sorafenib. Two important points should be noted. Firstly, the short-interval angiography *via* the implantable port-catheter system was useful in detecting HAT early. Secondly, CDT *via* the implantable port-catheter system was successful at recanalizing the hepatic artery and enabling HAIC to continue.

Conflicts of interest

All Authors declare that they have no conflicts of interest.

Acknowledgments

The Authors acknowledge the excellent advice of Ms. Marian Pahud (Valkenburg, the Netherlands) in submitting this article.

References

- 1 Wilhelm SM, Carter C, Tang L, Wilkie D, McNabola A, Rong H, Chen C, Zhang X, Vincent P, McHugh M, Cao Y, Shujath J, Gawlak S, Eveleigh D, Rowley B, Liu L, Adnane L, Lynch M, Auclair D, Taylor I, Gedrich R, Voznesensky A, Riedl B, Post LE, Bollag G and Trail PA: BAY 43-9006 exhibits broad spectrum oral antitumor activity and targets the RAF/MEK/ERK pathway and receptor tyrosine kinases involved in tumor progression and angiogenesis. *Cancer Res* 64: 7099-7109, 2004.
- 2 Llovet JM, Ricci S, Mazzaferro V, Hilgard P, Gane E, Blanc JF, de Oliveira AC, Santoro A, Raoul JL, Forner A, Schwartz M, Porta C, Zeuzem S, Bolondi L, Greten TF, Galle PR, Seitz JF, Borbath I, Häussinger D, Giannaris T, Shan M, Moscovici M, Voliotis D and Bruix J; SHARP Investigators Study Group: Sorafenib in advanced hepatocellular carcinoma. *N Engl J Med* 359: 378-390, 2008.
- 3 Shao YY, Huang CC, Liang PC and Lin ZZ: Hepatic arterial infusion of chemotherapy for advanced hepatocellular carcinoma. *Asia Pac J Clin Oncol* 6: 80-88, 2010.
- 4 Zangari M, Fink LM, Elice F, Zhan F, Adcock DM and Tricot GJ: Thrombotic events in patients with cancer receiving antiangiogenesis agents. *J Clin Oncol* 27: 4865-4873, 2009.
- 5 Qun W and Tao Y: Effective treatment of advanced cholangiocarcinoma by hepatic arterial infusion chemotherapy combination with sorafenib: One case report from China. *Hepatogastroenterology* 57: 426-429, 2010.
- 6 Yang MY, Jeong SW, Kim DK, Kim SG, Jang JY, Kim YS, Lee JS, Kim BS, Kim JH and Kim YJ: Treatment of hepatocellular carcinoma with portal vein thrombosis by sorafenib combined with hepatic arterial infusion chemotherapy. *Gut Liver* 4: 423-427, 2010.
- 7 Heim M, Sharifi M, Hilger RA, Scheulen ME, Seeber S and Strumberg D: Antitumor effect and potentiation or reduction in cytotoxic drug activity in human colon carcinoma cells by the RAF kinase inhibitor (RKI) BAY 43-9006. *Int J Clin Pharmacol Ther* 41: 616-617, 2003.
- 8 UMIN Clinical Trials Registry (ID: 000004315) Available at: <http://www.umin.ac.jp/ctr/index/htm/>. Last accessed December 24, 2011.
- 9 Kamba T and McDonald DM: Mechanisms of adverse effects of anti-VEGF therapy for cancer. *Br J Cancer* 96: 1788-1795, 2007.
- 10 Tanaka T, Arai Y, Inaba Y, Matsueda K, Aramaki T, Takeuchi Y and Kichikawa K: Radiologic placement of side-hole catheter with tip fixation for hepatic arterial infusion chemotherapy. *J Vasc Interv Radiol* 14: 63-68, 2003.
- 11 Mancuso A, Airoidi A, Vigano R and Pinzello G: Fatal gastric bleeding during sorafenib treatment for hepatocellular carcinoma recurrence after liver transplantation. *Dig Liver Dis* 43: 754, 2011.
- 12 Pouessel D and Culine S: High frequency of intracerebral hemorrhage in metastatic renal carcinoma patients with brain metastases treated with tyrosine kinase inhibitors targeting the vascular endothelial growth factor receptor. *Eur Urol* 53: 376-381, 2008.
- 13 Singhal A, Stokes K, Sebastian A, Wright HI and Kohli V: Endovascular treatment of hepatic artery thrombosis following liver transplantation. *Transpl Int* 23: 245-256, 2010.

Received May 4, 2012

Revised July 13, 2012

Accepted August 8, 2012