

Interstitial Lung Disease Associated with Docetaxel in Patients with Advanced Non-small Cell Lung Cancer

AKIHIRO TAMIYA¹, TATEAKI NAITO¹, SATORU MIURA¹, SAKAE MORII¹,
ASUKA TSUYA¹, YUKIKO NAKAMURA¹, KYOICHI KAIRA¹, HARUYASU MURAKAMI¹,
TOSHIKAKI TAKAHASHI¹, NOBUYUKI YAMAMOTO¹ and MASAHIRO ENDO²

Divisions of ¹Thoracic Oncology and ²Diagnostic Radiology, Shizuoka Cancer Center, Shizuoka, Japan

Abstract. *Background: Docetaxel is a well tolerated chemotherapy for non-small cell lung cancer (NSCLC). However, few studies have investigated interstitial lung disease (ILD) associated with docetaxel. The purpose is to describe the incidence of this complication by using NSCLC patients. Patients and Methods: Between September 2002 and March 2008, 392 patients with advanced NSCLC were treated with docetaxel and we retrospectively reviewed the radiography. In total, 18 patients subsequently developed ILD associated with docetaxel. Results: The incidence of ILD associated with docetaxel was 4.6%. In treated patients who showed an interstitial change on chest computed tomography (CT), the incidence was very high (25.9%). Chest radiograph showed diffuse and bilateral ground-glass appearance patterns. Conclusion: Pre-existing interstitial change on CT was associated with a higher incidence of ILD (25.9%) among NSCLC patients treated with docetaxel. We don't recommend administering docetaxel for the patients with pre-existing interstitial change.*

Docetaxel has a chemical structure and mechanism of action, which account for its broad antitumor activity. The taxane rings of docetaxel are linked to an ester side chain that is attached to the C13 position of the ring, which is essential for the antimicrotubule and antitumor activity of docetaxel. Docetaxel binds to the interior luminal surface of the microtubule at binding sites completely distinct from those of exchangeable guanosine 5'-triphosphate (GTP), colchicines, podophyllotoxin, and the vinca alkaloids. Moreover, the water solubility of docetaxel is slightly more than that of paclitaxel (1, 2).

Correspondence to: Tateaki Naito, MD, Department of Thoracic Oncology, Shizuoka Cancer Center, 1007, Shimonagakubo, Nagaizumi, Shizuoka 411-8777, Japan. Tel: +81 559895222, Fax: +81 559895783, e-mail: t.naito@scchr.jp

Key Words: Non-small cell lung cancer, docetaxel, interstitial lung disease, pulmonary emphysema, interstitial change.

In chemotherapy treatment, drug-induced pulmonary toxicity is an important adverse event. However, little is known regarding the incidence rates and characteristic imaging findings. Additionally, interstitial lung disease (ILD) associated with docetaxel is also understudied. No report has described the features of ILD associated with docetaxel treatment, and only a few cases of ILD associated with docetaxel have been reported since 2000, either with docetaxel monotherapy or with combination therapy with other agents and/or irradiation, for a wide range of malignancies, including non-small cell lung cancer (NSCLC), breast cancer (3, 4), prostate cancer (5), bladder cancer (6).

The purpose of this retrospective study was to describe the features of ILD associated with docetaxel treatment in patients with advanced NSCLC treated tri-weekly with docetaxel monotherapy.

Patients and Methods

Patient selection. Between September 2002 and March 2008, 392 patients with advanced NSCLC (stage IIIB/IV) were treated with docetaxel at our Institution (Shizuoka Cancer Center, 600-bed hospital) and were subsequently reviewed in this study. All of the patients were treated with docetaxel alone. A docetaxel dose of 60 mg/m², the recommended dose in Japan, was administered once every three weeks. Of the 392 patients, 18 subsequently developed ILD associated with docetaxel treatment.

Collection of data. Data was collected from the electronic medical records of the institution, and ethical approval was obtained from a local research Ethics Board of our Institution. We recorded demographic data (date of birth, age at docetaxel treatment, sex, and history of smoking). Additional data, such as previous chemotherapy history and imaging data, including emphysematous and interstitial changes, were also collected at baseline from chest radiographs and computed tomography (CT) scans. Furthermore, during docetaxel treatment, chest radiography was performed at least once for two weeks, and chest CT was performed at least once between one month and three months of therapy.

Diagnosis of ILD associated with docetaxel. In our retrospective study, ILD associated with docetaxel treatment was defined: (i) based on clinical symptoms, including fever and cough and

Table I. Patient's characteristics.

Factor		Non-ILD cases	ILD cases
Age (year)	Median (range)	64 (23-86)	65 (44-77)
	≤70	269	14
	>70	105	4
Gender	Male	275	16
	Female	99	2
PS	0, 1	328	14
	2-	46	4
Smoking history (pack year)	No	84	3
	Yes	290	15
Previous chemotherapy	No	25	0
	Yes	349	18
Chest-imaging pre-medication	Normal	303	6
	Emphysema	51	5
	Interstitial change	20	7

PS: Performance status.

dyspnea, and elevation of laboratory data, such as a serum lactate dehydrogenase (LDH) and/or KL-6, which is a mucin-like high-molecular-weight glycoprotein and shown to correlate well with the activities of several different kinds of interstitial pneumonia; (ii) chest radiography and CT scans showing newly developed shadows with a linear, diffuse ground-glass appearance (GGA) or a reticular shadow, and not segmental infiltrative shadows; and (iii) no indication of cardiac failure, inferior respiratory inflammation or pneumonia. In addition, these diagnoses were evaluated by a radiologist and a thoracic oncologist and a respiratory physician, who had no knowledge of the patients' outcomes.

Statistical analysis. Fisher's exact test or χ^2 test was performed to identify the risk factors for the ILD associated with docetaxel treatment according to potential predictors. We also calculated the odds ratio (OR) and its 95% confidential interval. *P*-values less than 0.05 were considered statistically significant. Two-sided statistical tests were used in all analyses.

Results

Patient characteristics and ILD incidence. Between September 2002 and March 2008, 18 out of 392 patients treated with docetaxel subsequently developed ILD associated with docetaxel treatment. The characteristics of the patients treated with docetaxel and those who developed docetaxel associated ILD with docetaxel are shown in Table I. Among the 392 patients treated with docetaxel, median age, 64 years. The majorities of those patients were male and good performance status (PS), and had smoking history and previous chemotherapy. On chest CT scans showed an obvious emphysematous change in 56 patients, an obvious interstitial change in 27. Among the 18 patients who developed ILD associated with docetaxel treatment, the

Table II. Incidence and risk rate of pulmonary toxicity related to docetaxel therapy (univariate analysis).

Factors		Incidence (%)	Odds ratio (95% CI)	P-value
All		4.6		
Age (year)	≤70	4.9	0.73 (0.23-2.27)	0.614
	≥71	3.7		
Gender	Male	5.5	0.35 (0.08-1.54)	0.177
	Female	2.0		
PS	0, 1	4.1	2.04 (0.64-6.46)	0.266
	2-	8.0		
Smoking history (pack year)	No	3.4	1.45 (0.41-5.12)	0.774
	Yes	4.9		
Previous chemotherapy	No	0	-	0.396
	Yes	4.9		
	Normal	1.9		
pre-medication	Emphysema	8.9	4.95 (1.46-16.83)	0.016
	Interstitial change	25.9		
			17.68 (5.43-57.56)	0.000012

PS: performance status.

median age, 65 years; range, 44-77 years, 16 men and 2 women, 15 had a history of smoking, 14 were PS 0 or 1, and all the 18 patients had a history of previous chemotherapy. The chest CT images revealed 5 patients had obvious emphysematous change and 7 had obvious interstitial changes.

The incidence of ILD associated with docetaxel was 4.6%. The results of the univariate analysis of risk factors for ILD associated with docetaxel therapy are shown in Table II. The incidences and OR of this toxicity were statistically elevated when the patients had the emphysematous change (8.9%, $p=0.016$, OR=4.95 (1.46-16.83)), and interstitial change (25.7%, $p=0.000012$, OR=17.68 (5.43-57.56)). And the incidences and OR of this toxicity were not statistically different between the other factors.

Onset of this complication. The median cycle from the first docetaxel administration to the appearance of toxicity findings on a chest radiograph was cycle 2 (range: 1-4 cycles) (Figure 1). The median time from the last docetaxel administration to the onset of toxicity findings on the chest radiograph was 18 days (3 patients in 10 days, 9 in 10-20 days).

Imaging findings. The most common chest radiography finding was diffuse and bilateral shadows with GGA, which was observed in 17 patients, while non-segmental infiltrative shadows were observed in one patient.

Chest CT findings were available for 17 out of the 18 patients; the main CT features of ILD associated with docetaxel were new diffuse and bilateral GGA, thickened septal lines, reticular opacity, non-segmental predominance of lung opacity, and no predilection or evidence of vascular engorgement. Typical CT imaging is shown in Figure 2.

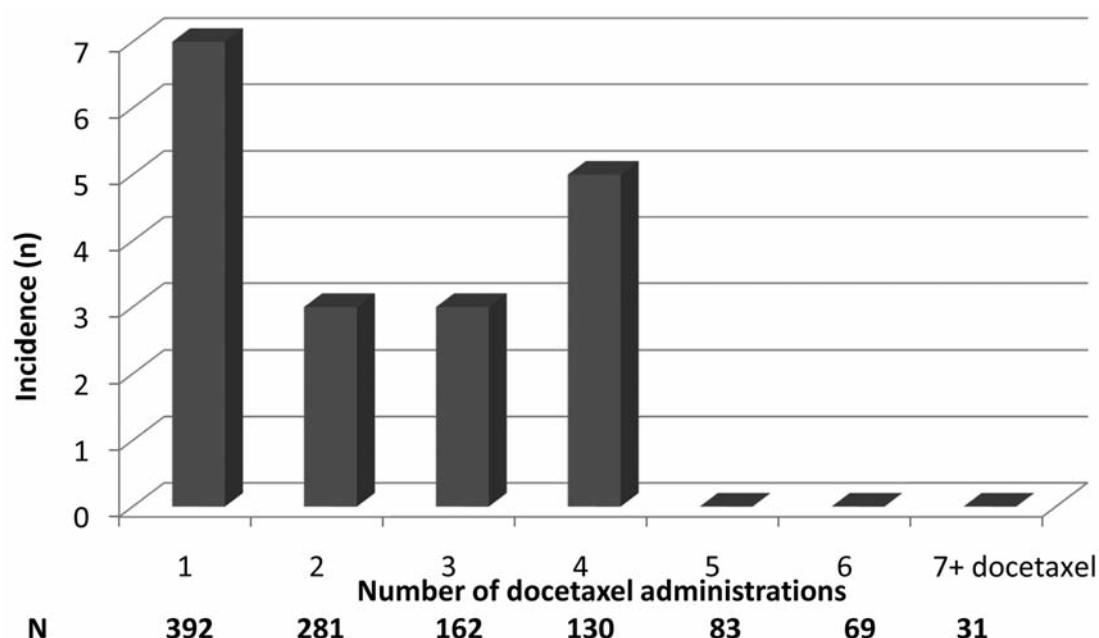


Figure 1. The median time from the first administration to the appearance of toxicity findings on a chest X-ray. N= numbers of patients administered docetaxel.

Discussion

Docetaxel is used to treat a variety of solid neoplasms, including NSCLC. One previous report about ILD associated with docetaxel in NSCLC indicated that its incidence was high when docetaxel was used in combination with gemcitabine or radiation (7). Moreover, the appearance of interstitial pneumonitis appears to be more related to docetaxel delivery schedule than dose (8), where a weekly schedule causes lower myelosuppression but more pneumonitis than tri-weekly administration. Although there are a few reports on the incidence of docetaxel-associated ILD, such as the phase III V15-32 study (2.9%) (9) and the phase III INTREST study (1.1%) (10), no reports describe the features of such ILD, the incidence, time of onset, and imaging findings, in NSCLC patients treated tri-weekly with docetaxel monotherapy which was the most popular pattern of treatment of NSCLC. Thus, this retrospective study is the first report to describe the features of docetaxel-associated ILD in NSCLC patients treated tri-weekly with docetaxel monotherapy.

In the present study, 18 out of the 392 patients (4.6%) developed pulmonary toxicity possibly as a result of the tri-weekly docetaxel treatment, which is a slightly higher incidence compared with previous clinical trials treated with tri-weekly docetaxel monotherapy. The reason for the high incidence is thought to be the possibility of different backgrounds between the patients in this present study and the previous clinical trial studies. Pre-existing interstitial

change has been reported to be the most significant risk factor for the development of anticancer agent-associated ILD (11). In the present study, for the 56 and 27 respective patients with obvious emphysematous or interstitial changes according to chest CT scans, 5 (8.9%) and 7 (25.9%) patients developed this complication, respectively. Furthermore, when we calculated the OR of patients with emphysematous or interstitial change compared with patients without these changes, the OR was very high (4.95 times in patients with emphysematous change and 17.68 times in patients with interstitial change). Whereas no differences in the incidence of this complication was observed when the patients were examined according to age, gender, history of smoking, PS, and history of previous chemotherapy. These data suggest that the incidence of docetaxel-associated ILD in NSCLC patients treated with tri-weekly docetaxel monotherapy may depend on pre-existing changes in the pulmonary structure.

In our study, the most common chest radiography feature for docetaxel-associated ILD was a linear and a diffuse and bilateral GGA.

The present study has some limitations. The first is its retrospective style. Secondly a major limitation of this study is that we could not undertake surgery or bronchoscopy to diagnose docetaxel associated ILD in all cases, which would have enabled histological confirmation of ILD, because of the patients' condition. Therefore, we cannot completely exclude the possibility that the patients had developed lymphangitic carcinomatosis or other

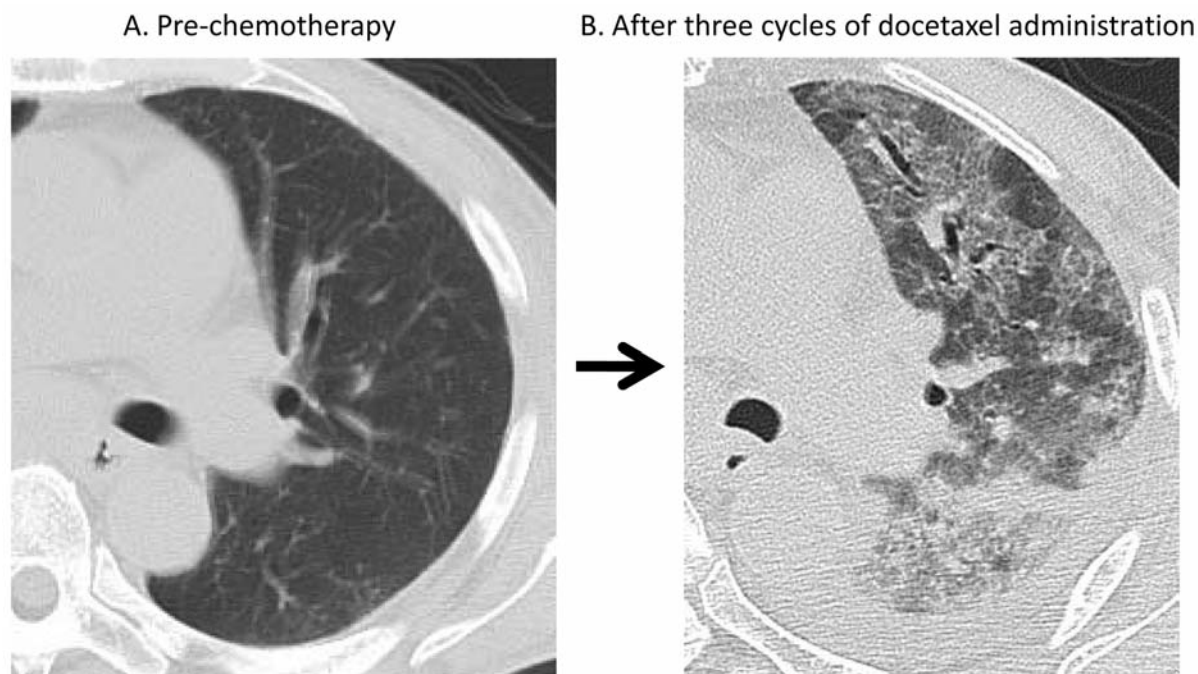


Figure 2. Imaging findings of docetaxel-associated ILD(the male patient was 65 years old, with squamous carcinoma).

diseases and not ILD. However, because the clinical course, laboratory data and radiographic findings of these patients were consistent with drug-induced ILD, we made the diagnosis of docetaxel-associated ILD. Finally, because of the small number of patients enrolled, there is the possibility that these may not be sufficient detection power for the intergroup comparisons.

Conclusion

The findings of our present study suggest a high incidence of docetaxel-associated ILD in patients with pulmonary structural changes, especially in those with an interstitial shadow on their chest CT; pre-existing interstitial change on CT was associated with a higher rate of ILD (25.9%). We do not recommend the administration of docetaxel for NCLC patients with pre-existing interstitial change.

References

- 1 Lee JJ and Harris LN: Antimicrotubule agents. In: DeVita VT, Hellman S and Rosenberg SA (eds.). Cancer Principles and Practice of Oncology, 8th edn. Philadelphia: Lippincott Williams and Wilkins, pp. 447-456, 2008.
- 2 Schiff PB, Fant J and Horwitz SB: Promotion of microtubule assembly in vitro by taxol. *Nature* 277: 665, 1979.
- 3 Karakan O, Eyüboğlu FO, Akçay S and Ozyılkan O: Acute interstitial pneumopathy associated with docetaxel hypersensitivity. *Onkologie* 27: 563-565, 2004.
- 4 Karasawa K, Katsui K, Seki K *et al*: Radiotherapy with concurrent docetaxel for advanced and recurrent breast cancer. *Breast Cancer* 10: 268-274, 2003.
- 5 Behrens RJ, Gulley JL and Dahut WL: Pulmonary toxicity during prostate cancer treatment with docetaxel and thalidomide. *Am J Ther* 10: 228-232, 2003.
- 6 Dunsford ML, Mead GM, Bateman AC *et al*: Severe pulmonary toxicity in patients treated with a combination of docetaxel and gemcitabine for metastatic transitional cell carcinoma. *Ann Oncol* 10: 943-947, 1999.
- 7 Grande C, Villanueva MJ, Huidobro G, Casal J *et al*: Docetaxel-induced interstitial pneumonitis following non-small cell lung cancer treatment. *Clin Transl Oncol* 9: 578-581, 2007.
- 8 Chen YM, Shif JF, Peng RP *et al*: A randomized trial of different docetaxel schedules in non-small cell lung cancer patients who failed previous platinum-based chemotherapy. *Chest* 129: 1031-1038, 2006.
- 9 Maruyama R, Nishiwaki Y, Tamura T *et al*: Phase III study, V15-32, of gefitinib versus docetaxel in previously treated Japanese patients with non-small-cell lung cancer. *J Clin Oncol* 26: 4244-4252, 2008.
- 10 Kim ES, Hirsh V, Mok T *et al*: Gefitinib versus docetaxel in previously treated non-small cell lung cancer (INTEREST): A randomized phase III trial. *Lancet* 372: 1809-1818, 2008.
- 11 Kudoh S, Kato H, Nishiwaki Y *et al*: Interstitial lung disease in Japanese patients with lung cancer. *Am J Respir Crit Care Med* 177: 1348-1357, 2008.

Received January 16, 2012

Revised February 8, 2012

Accepted February 10, 2012