

## Nationwide Survey of Use of Vacuum-assisted Breast Biopsy in South Korea

HAI-LIN PARK<sup>1\*</sup>, SUN YOUNG MIN<sup>2\*</sup>, SEA-HYUN KWON<sup>1</sup>, JUNG-YOON SONG<sup>3</sup>, HYUKJAI SHIN<sup>4</sup>, SEOK-JIN NAM<sup>5</sup>, JUNG-HYUN YANG<sup>6</sup> and KOREAN BREAST CANCER SOCIETY MEMBERS<sup>7</sup>

<sup>1</sup>*Division of Breast and Thyroid Surgery, Department of Surgery, Kangnam CHA Hospital, CHA University College of Medicine, Seoul, South Korea;*

<sup>2</sup>*Department of Surgery, Kyunghee University Medical Center, Kyunghee University College of Medicine, Seoul, South Korea;*

<sup>3</sup>*Department of Surgery, Kyunghee University Hospital at Gangdong, Kyunghee University College of Medicine, Seoul, South Korea;*

<sup>4</sup>*Department of Surgery, Myongji Hospital, Kwandong University College of Medicine, Goyang, South Korea;*

<sup>5</sup>*Department of Surgery, Samsung Medical Center, Sungkyunkwan University, Seoul, South Korea;*

<sup>6</sup>*Department of Surgery, Konkuk University Medical Center, Konkuk University College of Medicine, Seoul, South Korea;*

<sup>7</sup>*Korean Breast Cancer Society, Seoul, South Korea*

**Abstract.** *Background: Image-guided vacuum-assisted breast biopsy (VABB) is used for detecting breast lesions in South Korea. However, no clear guidelines for VABB exist. Materials and Methods: A 53-item survey was administered to members of the Korean Breast Cancer Society between July 27 and August 27, 2010. Results: Among 62 respondents, 87.1% had performed VABB, with 63.0% performing both diagnosis and treatment. Around 62.5% used VABB for diagnosing Ultrasound Breast Imaging-Reporting and Data System (USG BIRAD) Category 3 lesions, 55% for Category 4A, 57.5% for microcalcifications detected by ultrasonography, and 30% for small Category 5. Furthermore, 81.3% used VABB to treat Category 3 lesions; while 67.8% diagnosed benign lesions on core needle biopsy, requiring surgical excision. About 83% used VABB for small tumors (<3 cm). Among therapeutically excised tumors, 86.4% reported fibroadenoma. Conclusion: VABB is performed for diagnosis and treatment in South Korea, and*

*complies with the available guidelines. However, national and global standards and guidelines for VABB need to be established.*

Image-guided vacuum-assisted breast biopsy (VABB) is frequently used for tissue diagnosis of palpable and non-palpable breast lesions in South Korea. Compared to 14-G core needle biopsy of breast tissue, VABB of breast tissue with an 8-G or 11-G needle offers greater reliability, fewer complications, and more satisfactory cosmetic outcomes (1-4). The most common indication for VABB is the detection of palpable or non-palpable nodular lesions classified as ultrasonographic (USG) Breast Imaging-Reporting and Data System (BI-RADS) Category 3 or Category 4a (3-5); VABB is effective for diagnosis of small (<5 mm) lesions when the results of fine-needle aspiration (FNA) or core biopsy are insufficient (4, 6).

Although initially developed for diagnostic purposes, VABB is advantageous for acquiring many types of tissues in a safe and accurate manner, and thus could be useful for the treatment of benign breast lesions. In 2003, VABB was approved by the U.S. Food and Drug Administration for the treatment of some benign breast lesions, including fibroadenoma; since then, its popularity has increased as a treatment tool *in lieu* of excisional biopsy (7, 8). Because of the growing prevalence and awareness about benign breast lesions in Korea, more hospitals in South Korea are performing VABB for therapeutic purposes.

An 8-G needle is recommended for VABB of lesions >1 cm in size; studies have reported that no lesions remained and

\*These Authors contributed equally to this study.

*Correspondence to:* Hai-Lin Park, Division of Breast and Thyroid Surgery, Department of Surgery, Kangnam Cha Hospital, Cha University College of Medicine, 650-9 Yeoksam-dong, Kangnam-gu, Seoul 135-081, South Korea. Tel: +82 0234683206, Fax: +82 0234682608, e-mail: phl1@cha.ac.kr

**Key Words:** Atypical ductal hyperplasia, benign phyllodes tumor, fibroadenoma, intraductal papilloma, vacuum-assisted breast biopsy.

the rate of recurrence was low after excision of lesions <3.0 cm (9-17). In the 2011 diagnostic guidelines for benign breast lesions, the Korean Breast Cancer Society announced that benign papillary lesions should be completely excised by VABB and that follow-up without additional excision can be considered (12). However, it issued no clear guidelines regarding when VABB should be performed or when lesions should be completely excised based on their size, nor regarding treatment for multiple lesions and procedures on the basis of various histological results. In order to collect data that will assist in the development of such guidelines, we administered a survey to members of the Korean Breast Cancer Society to gain an understanding over the current applications of VABB in South Korea.

## Materials and Methods

From July 27 to August 27, 2010, members of the Korean Breast Cancer Society were given a survey consisting of 53 items, 5 on demographic and employment data, and 48 on data regarding VABB use (7, general use; 2, diagnostic purposes; 8, therapeutic purposes; 6, procedures according to the ultrasonography BI-RADS category; 20, additional procedures according to histopathological results; 5, cosmetic purposes). Frequency analysis of the collected responses was performed using the SPSS statistical software system version 17.0 (SPSS Inc., Chicago, IL, USA).

## Results

**Respondent profile.** Sixty-two members, all surgeons, returned completed surveys *via* e-mail or fax: 79.0% (n=49) resided in Seoul, Gyeonggi, and other large cities, and 21.0% (n=13) in areas evenly-distributed nationwide; 56.4% (n=35) worked at university hospitals, 24.2% (n=15) at breast clinics, and 19.4% (n=12) at cancer hospitals, general hospitals, or semi-general hospitals.

**General use of VABB.** Among the 62 respondents, 87.1% (n=54) had direct experience of performing VABB, of whom, 94.4% (n=51) reported having used or to be currently using the Mammotome<sup>®</sup> system (Devicore Medical, Cincinnati, OH, USA). Concerning the most common site for performing VABB, 56.5% (n=35) reported the ultrasound room, 19.2% (n=12) the operating room, 16.1% (n=10) the outpatient surgery room, and 3.2% (n=2) the day-surgery center. The respondents had started performing VABB between 2000 and 2010. However, slightly more than half (51.7%, n=32) reported first performing VABB between 2002 and 2006, indicating that they had a procedural experience of 4-8 years at the time of the survey. Regarding the number of procedures performed since they started using VABB, 75.8% (n=47) reported having performed >101 and 56.4% >201. Among those who had performed more than 201 procedures since they started

using VABB, the total number of procedures performed ranged from 226 to 9,000.

**Indications for VABB for diagnostic purposes.** Out of the 40 respondents who reported using VABB for diagnostic purposes, 62.5% (n=25) reported that they indicate VABB for Category 3 lesions, 55% (n=22) for Category 4A lesions, 57.5% (n=23) for microcalcifications detected by ultrasonography, and 30% (n=12) for small Category 5 lesions for which core needle biopsy is judged to have collected inadequate tissue sample (Figure 1). Regarding cases in which benign lesions are diagnosed on core needle biopsy but the presence of potentially malignant lesions (B3 lesions) indicates additional surgical excision, 47.5% (n=19), out of the 40 respondents reported that they performed VABB while 50.0% (n=20) reported that they performed surgical excisional biopsy.

**Indications for VABB for therapeutic purposes.** A total of 59 respondents (95.2%) reporting indicating VABB for treatment of benign tumors. Regarding the most common category of lesions for which they indicate VABB for treatment purposes, 81.3% (n=48) reported Category 3 lesions and 67.8% (n=40) reported benign lesions diagnosed on core needle biopsy for which additional surgical excision is required (Figure 2). Regarding the purpose of performing VABB, 86.0% (n=51) reported for removal of all Category 3 solitary nodules, while 17% (n=10) reported only for Category 3 lesions that are solitary nodules. Regarding indications for ultrasound-guided VABB excision, only 5.1% (n=3) reported that they remove lesions larger than 1 cm as measured ultrasonically. However, half (n=31) stated that they would remove lesions larger than 1 cm when a patient requested them to do so or if doing so would allay a patient's anxiety and 23.7% that they remove these lesions if their size increased during follow-up. Other reported reasons for removal include consideration of the patient's situation (43.5%, n=27) and an increase in lesion size during the follow-up period (25.8%, n=27).

Regarding the strongest indications of VABB for cases of Category 3 solitary nodules, 66.1% (n=39) reported the presence of palpable or painful lesions, 45.8% (n=27) a family history of breast cancer or a history of breast cancer on the other side, 42.4% (n=25) the relative youth of the patient, 40.6% (n=24) difficulty in follow-up due to geographical challenges, 33.4% (n=21) patient plans to undergo breast cosmetic surgery or to become pregnant, and 30.5% (n=18) the presence of malignant lesions in the same breast at the same time. Regarding cases of multiple bilateral Category 3 lesions, 69.5% (n=41) reported they would remove lesions only if their size changes or increases during monitoring, 25.4% (n=15) that they would remove the largest nodule on both sides, 6.8% (n=4) that they would remove

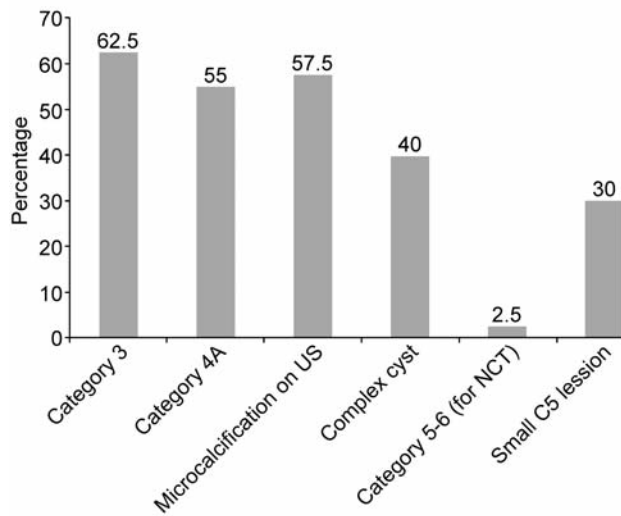


Figure 1. Indications for VABB for diagnostic purposes. US: Ultrasound, NCT: neoadjuvant chemotherapy, FA: fibroadenoma, ADH: atypical ductal hyperplasia, IDP: intraductal papilloma.

only palpable lesions, and 0% (n=0) that they remove all lesions. Regarding the size of masses subject to VABB when benign lesions are diagnosed on core needle biopsy, 47% reported those smaller than 3 cm, 19% those smaller than 2.5 cm, and 17% those smaller than 2 cm, indicating that approximately half perform VABB excision for masses of up to 3 cm in size (Figure 3).

**Indications for VABB by BI-RADS category.** Among all respondents, 53.2% (n=33) reported that they indicate VABB for Category 4A solitary nodules. Regarding the type of biopsy first performed for diagnosis of Category 4A lesions, 87.1% (n=54) reported core needle biopsy, 8% (n=5) FNA, and only 6.4% (n=4) VABB. Regarding the type of biopsy used for diagnosis of Category 4B and 4C-5 lesions, 85.5% (n=53) reported core needle biopsy and 88.7% (n=55) FNA instead of VABB. Regarding category 4B lesions, only 1.6% (n=1) reported using VABB for the purpose of biopsy, and no respondents reported using it for biopsy of higher categories. Regarding actions taken when performing VABB for Category 4C-5 lesions for diagnosis, only 3.2% (n=2) reported that they perform cryosection immediately. Regarding biopsy for neoadjuvant chemotherapy in cases of Category 5 advanced breast cancer, 87.1% (n=54) reported that the use of core needle biopsy allows them to obtain an adequate tissue sample, while only 1.6% (n=1) reported they also perform VABB to obtain an additional tissue sample.

**Indications for VABB after histopathological examination by core needle biopsy.** Among the 59 respondents who reported

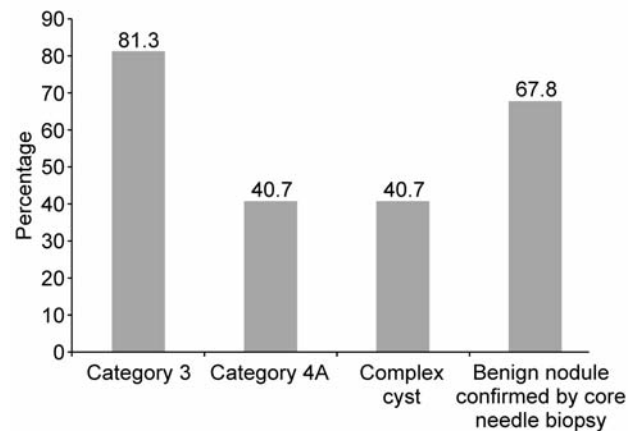


Figure 2. Indications for VABB for treatment purposes. US: Ultrasound, NCT: neoadjuvant chemotherapy, FA: fibroadenoma, ADH: atypical ductal hyperplasia, IDP: intraductal papilloma.

that they perform VABB for treatment of benign breast tumors after confirmation of histopathological results *via* core needle biopsy, 86.4% (n=51) reported that they perform VABB for fibroadenoma, 69.5% for intraductal papilloma, and 67.8% for sclerosing adenosis (Figure 4). All 62 respondents completed several items that assessed their use of additional procedures for confirmed cases of fibroadenoma, benign phyllodes tumor, mucinous lesion, lobular neoplasia, and papillary lesion, after core needle biopsy (Figure 5). Among them, 80.6% (n=50) reported that they selected an excision procedure according to its size in cases of fibroadenoma, 16.1% (n=10) that they remove lesions that are palpable, and 12.9% (n=8) that they monitor lesions. Regarding cases of fibroadenoma diagnosed on core needle biopsy, 48.4% (n=30) reported that they perform VABB excision for lesions smaller than 3 cm, 30.6% (n=19) for lesions smaller than 2 cm, and 11.3% for lesions smaller than 5 cm. On the other hand, 46.8% (n=29) reported that they perform surgical excision for lesions larger than 3 cm and 24.2% for lesions larger than 5 cm. Regarding the procedure performed for treatment of benign tumors, similar percentages reported performing VABB and surgical excision for lesions of 1 cm, 2 cm, and 3 cm in size (1.6%, n=1; 30.6%, n=19; 48.4%, n=30 vs. 3.2%, n=2; 21.0%, n=13; and 46.8%, n=29, respectively). In contrast, for treatment of tumors of 3 to 5 cm in size, more than twice as many reported using surgical excision (24.2%, n=15) than VABB (11.3%, n=7).

Regarding treatment after diagnosis of benign phyllodes tumor on core needle biopsy, 51.6% (n=32) reported that they perform VABB. Among these respondents, 48.4% (n=30) reported that they perform VABB for tumors smaller than 3 cm and only 3.2% (n=2) for tumors larger than 5 cm. Regarding VABB, the respondents reported diverse

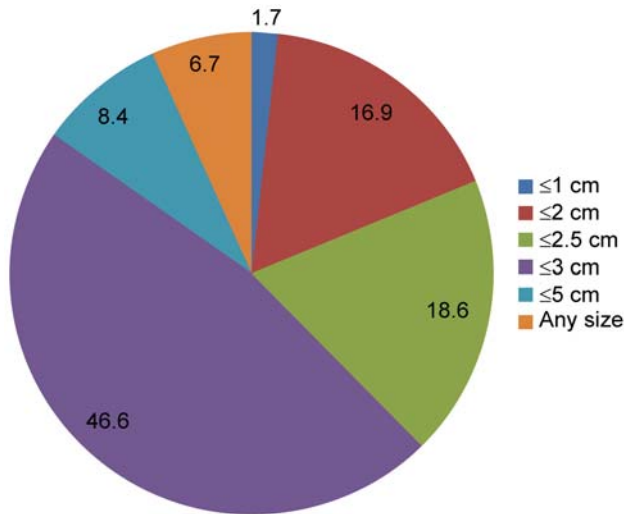


Figure 3. Indications for VABB based on tumor size (percentage of respondents).

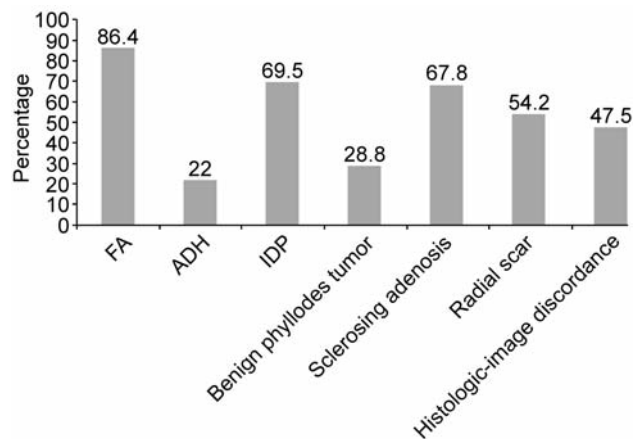


Figure 4. Indications for VABB after histopathological examination by core needle biopsy.

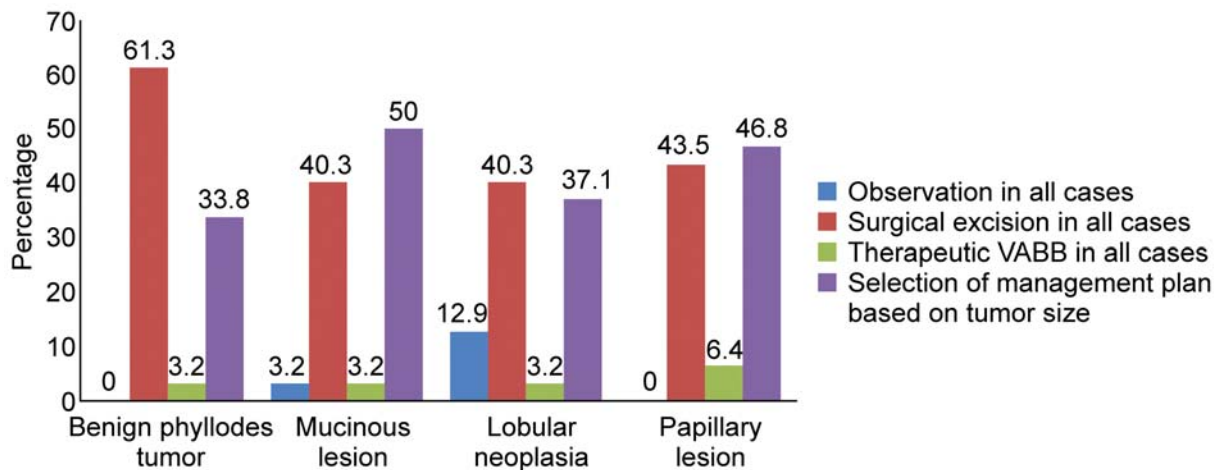


Figure 5. Indications for VABB based on pathological results.

applications according to the lesion size, from less than 1 cm to 5 cm (21.0%, n=13; 14.5%, n=9; 21.0%, n=13; 6.5%, n=4, respectively). Among the 37 respondents who reported that they perform VABB for the treatment of mucous lesions, lobular neoplasias, and papillary lesions, the largest percentages (54.8%, n=34; 40.3%, n=25; and 59.7%, n=37, respectively) reported that they perform it primarily for lesions smaller than 3 cm.

*Indications for additional procedures based on pathological VABB results.* Several items assessed the respondents'

performance of additional procedures after diagnosis of cases of atypical ductal hyperplasia (ADH), benign phyllodes tumor, or benign papillary tumor by final pathological exam after VABB for diagnostic purposes. Regarding ADH, 50.0% (n=31) reported that they follow-up on the patient's condition when they judge the tumor to have been fully-excised by VABB, 32.3% (n=20) that they perform surgical excision in all cases, and 12.9% (n=8) said that they follow-up the patient's condition only in cases of focal ADH. Regarding benign phyllodes tumor, 54.8% (n=34) reported that they follow-up the patient's condition when they judge the tumor



to have been fully excised by VABB; 25.8% (n=16) that they perform surgical excision for all cases; and 12.9% (n=8) that they perform surgical re-excision depending on the tumor size, with 21.0% (n=13) reporting doing so for tumors larger than 1 cm, 14.5% (n=9) for tumors larger than 2 cm, 21.0% (n=13) for tumors larger than 3 cm, and 6.5% (n=4) for tumors larger than 5 cm. Regarding cases of benign papillary tumors 79.0% (n=49) reported they follow-up a case for which they judge a tumor to have been fully-excised by VABB; 8.1% (n=5) that they perform surgical excision for all cases; and 12.9% (n=8) that they perform surgical excision depending on the tumor size, with 4.8% (n=3) reporting performing it for tumors larger than 1 cm, 21.0% (n=13) for tumors larger than 2 cm, 14.5% (n=9) for tumors larger than 3 cm, and 4.8% (n=3) for tumors larger than 5 cm.

## Discussion

Our study results indicate that although the respondents perform VABB according to generally accepted standards and in accordance with previously reported indications for biopsy (13-15), depending on their experience and skills, they use a variety of criteria in their application of VABB. This finding reflects the lack of consensus regarding the maximum size of tumors that can be excised by VABB in literature. Whereas Baez *et al.* (11) reported that complete excision is possible when the mass is smaller than 2.3 cm, Fine *et al.* (9) reported that it is possible when the diameter is smaller than 3 cm. In contrast, Park *et al.* (13) argued that due to surgeons' increasing experience in performing VABB, which has led to higher safety and utility in the use of the procedure, VABB excision is possible for benign tumors larger than 3 cm. Regarding cases of fibroadenoma diagnosed using core needle biopsy, 11.3% of respondents reported performing VABB for lesions smaller than 5 cm. On the other hand, 46.8% reported that they perform surgical excision for lesions larger than 3 cm and 24.2% for lesions larger than 5 cm. More than twice as many respondents reported performing surgical (24.2%, n=15) rather than VABB excision (11.3%, n=7) for tumors 3-5 cm in size.

Regarding the performance of additional procedures in cases of ADH diagnosed by final pathological examination after VABB for diagnostic purposes, 50.0% (n=31) reported that they follow-up on the patient's conditions when they judge the tumor to have been fully-excised by VABB, 32.3% (n=20) that they perform surgical excision in all cases, and 12.9% (n=8) said that they follow-up the patient's condition only in cases of focal ADH. In cases of benign phyllodes tumor, 54.8% (n=34) reported that they follow-up a case for which they judge a tumor to have been fully-excised by VABB, 25.8% (n=16) that they perform surgical re-excision for all cases, and 12.9% (n=8) that they perform surgical re-excision depending on the tumor characteristics. In cases of

benign papillary tumors, 79.0% (n=49) reported they follow-up a case for which they judge a tumor to have been fully-excised by VABB, 8.1% (n=5) that they perform surgical excision for all cases, and 12.9% (n=8) that they perform surgical excision depending on tumor size. These findings are in accordance with those reported in literature, including those of Zografos *et al.* (18) in their study of 706 patients with Category 3 and 4 non-palpable breast lesions on mammography who underwent stereotaxic VABB with an 11-G needle. Whereas they found a histological underestimation rate of 3.6% among the 56 patients who had been diagnosed with benign papillary disease and had subsequently undergone surgical re-excision using wire localization biopsy, they found an underestimation rate of 0% for cases in which papillary lesions did not coexist preoperatively with any other precursor, including ADH, lobular neoplasia, or radial scarring. They stated that, as long as benign papillary lesions diagnosed on VABB are without pre-cancerous lesions, conservative management may be possible without surgical excision. In a study of 82 cases diagnosed with benign papillary disease on VABB who were followed-up for at least 24 months through ultrasound examinations without surgical re-excision, regardless of BI-RADS category, age, or tumor size, Park *et al.* (19) found that no new lesions were detected, indicating a 0% rate of underestimation of benign papillary disease diagnosed on VABB. The high rates of accuracy and low rates of underestimation found in these studies indicate that follow-up without surgical re-excision biopsy is appropriate in cases of benign papillary disease diagnosed through a tissue sample acquired from complete excision of target lesions on VABB.

Analysis of the results of this survey indicates that VABB procedures are currently being widely performed for diagnostic and treatment purposes in South Korea in a manner of compliance with previously reported indications and guidelines. Nevertheless, national and global standards and guidelines for VABB have yet to be established; the collection of data from a greater number of hospitals *via* further prospective research is required.

## Acknowledgements

Kwandong University College of Medicine, Myongji Hospital, Hyeok-jai Shin M.D.; Kwandong University College of Medicine, Cheil General Hospital, Sung-Soo Kang M.D.; Kangnam Cha Hospital, Hai-Lin Park M.D.; Kyung Hee University Hospital at Gangdong, Jung-Yoon Song M.D.; Samsung Medical Center, Yong-Rae Park M.D.; Konkuk University Medical Center, Hyun-Jong Kang M.D.; Konkuk University Medical Center, Kyung-Shik Park M.D.; Konkuk University Chungju Hospital, Soo-Yeon Oh M.D.; Kyungpook National University Medical Center, Wan-Wook Kim M.D.; Kyungpook National University Medical Center, Jin-Hyang Jung M.D.; Kyung Hee University Hospital, Sung-Young Min M.D.; Korea University College of Medicine, Gil-Soo Sohn M.D.; Korea University College of Medicine, Jung-Won Bae M.D.; Korea

University College of Medicine, Sang-Wook Woo M.D.; Cha Gumi Medical Center, Soon-Young Nam M.D.; Goo Hospital, Young-San Jeon M.D.; National Police Hospital, Jin-Woo Cha M.D.; National Cancer Center, So-Yeon Jung M.D.; Kim's Breast Clinic, Jeong-Kyung Kim M.D. and Daniel Jung M.D.; Dankook University Hospital, Myung-Chul Jang M.D.; Dankook University Hospital, Joon-Won Min M.D.; Dongguk University, Ilsan Hospital, Beom-Seok Kwak M.D.; Dong-A University Hospital, Mee-ri Lee M.D.; Dong-A University Hospital, Sae-Hyun Cho M.D.; Samsung Changwon Hospital, Si-Yeal Jeon M.D.; Mediwell Hospital, Sun-Ho Choi M.D.; Mirae Women's Hospital, Sung-Eun Hwang M.D.; Ms Yoo Clinic, Soo-Young Yoo M.D.; Park's Clinic, Hye-Deok Park M.D.; Park Breast Clinic, Hee-Boong Park M.D.; Busan-Paik Hospital, Tae-Hyun Kim M.D.; Busan Saegyro Hospital, Hyeok-Jin Lee M.D.; Seoul National University, Bundang Hospital, Sung-Won Kim M.D.; Pink light Hospital, Dong-seok Lee M.D.; Venus Women's Hospital, Sang-hoon Han M.D.; Sanggye Paik Hospital, Sae-Hwan Han M.D.; SGH Hye-Won Noh M.D., Seoul National University Hospital, Cha-Kyung Yeom M.D.; St. Mary's Hospital, Jung-Im Lee M.D.; Asan Medical Center, Byung-Ho Sohn M.D.; St Vincent's Hospital, Young-Jin Seo M.D.; Lim's Breast Clinic, Jae Yang Lim M.D.; Chonnam National University Hospital, Jung-Hwan Yoon M.D.; Chonbuk National University Hospital, Sung-Hoo Jung M.D.; Baptist Hospital, Yang-Soo Lim M.D.; and Women's I Hospital, Hye-Won Park M.D..

## Conflicts of Interest

The Authors have no conflict of interest to declare.

## References

- Parker SH and Klaus AJ: Performing a breast biopsy with a directional, vacuum-assisted biopsy instrument. *Radiographic* 17: 1233-1252, 1997.
- Hung WK, Lam HS, Lau Y, Chan CM and Yip AW: Diagnostic qccuracy of vacuum-assisted biopsy device for image-detected breast lesions. *ANZ J Surg* 71: 457-460, 2001.
- Cassano E, Urban LA, Pizzamiglio M, Abbate F, Maisonneuve P, Renne G, Viale G and Bellomi M: Ultrasound-guided vacuum-assisted core breast biopsy: Experience with 406 cases. *Breast Cancer Res Treat* 102: 103-110, 2007.
- Carder PJ and Liston JC: Will the spectrum of lesions prompting a "B3" breast core biopsy increase the benign biopsy rate? *J Clin Pathol* 56: 133-138, 2003.
- Zografos G, Zagouri F, Sergentanis TN, Nonni A, Koulocheri D, Dardamanis D, Oikonomou V, Giannopoulos P, Kouerinis I, Tsigris C and Bramis J: Vacuum-assisted breast biopsy in nonpalpable solid breast lesions without microcalcifications: The Greek experience. *Diagn Interv Radiol* 14: 127-130, 2008.
- Sebag P, Tourasse C, Rouyer N, Lebas P, Dénier JF and Michenet P: Value of vacuum assisted biopsies under sonography guidance: results from a multicentric study of 650 lesions. *J Radiol* 87: 29-34, 2006 (Article in French).
- Sperber F, Blank A, Metser U, Flusser G, Klausner JM and Lev-Chelouche D: Diagnosis and treatment of breast fibroadenomas by ultrasound-guided vacuum-assisted biopsy. *Arch Surg* 138: 796-800, 2003.
- Johnson AT, Henry-Tillman RS, Smith LF, Harshfield D, Korourian S, Brown H, Lane S, Colvert M and Klimberg VS: Percutaneous excisional breast biopsy. *Am J Surg* 184: 550-554, 2002.
- Fine RE, Whitworth PW, Kim JA, Harness JK, Boyd BA and Burak WE Jr.: Low-risk palpable breast masses removed using a vacuum-assisted hand-held device. *Am J Surg* 186: 362-367, 2003.
- Sie A, Bryan DC, Gaines V, Killebrew LK, Kim CH, Morrison CC, Poller WR, Romilly AP, Schilling K and Sung JH: Multicenter evaluation of the breast lesion excision system, a percutaneous, vacuum-assisted, intact-specimen breast biopsy device. *Cancer* 107: 945-949, 2006.
- Baez E, Huber A, Vetter M and Hackeloer BJ: Minimal invasive complete excision of benign breast tumors using a three-dimensional ultrasound-guided mammotome vacuum device. *Ultrasound Obstet Gynecol* 21: 267-272, 2003.
- Park HL, Kwak JY, Lee SH, Kim JY, Kim KL, Kim WW, Han SM and Lee KS: Excision of benign breast disease by ultrasound guided vacuum assisted biopsy device (mammotome). *J Kor Surg Soc* 68: 96-101, 2005.
- Park HL, Kwak JY, Jung H, Lee SH, Shim JY, Kim JY and Lee KS: Is mammotome excision feasible for benign breast masses bigger than 3 cm in the greatest dimension? *J Kor Surg Soc* 70: 25-29, 2006.
- Korean Surgical Society. Guidelines for the management of benign breast tumors. 2011.
- Alonso-Bartolome P, Vega-Bolivar A, Torres-Tabanera M, Ortega E, Acebal-Blanco M, Garijo-Ayensa F, Rodrigo I and Muñoz-Cacho P: Sonographically guided 11-G directional vacuum-assisted breast biopsy as an alternative to surgical excision: utility and cost study in probably benign lesions. *Acta Radiol* 45: 390-396, 2004.
- Lindfors KK, O'Connor J, Acredolo CR and Liston SE: Short-interval follow-up mammography versus immediate core biopsy of benign breast lesions: Assessment of patient stress. *AJR Am J Roentgenol* 171: 55-58, 1998.
- Youk JH, Kim EK, Kim MJ and Oh KK: Sonographically guided 14-gauge core needle biopsy of breast masses: A review of 2,420 cases with long-term follow-up. *AJR Am J roentgenol* 190: 202-207, 2008.
- Zografos GC, Zagouri F and Sergentanis TN: Diagnosing papillary lesions using vacuum-assisted breast biopsy: Should conservative or surgical management follow? *Onkologie* 31: 653-656, 2008.
- Park HL CS, Huh JY and Kim JY: Is further diagnostic surgery necessary for the benign papillary lesions that are diagnosed by large volume vacuum assisted breast biopsy? *J Breast Cancer* 13: 206-211, 2010.

Received August 28, 2012

Revised October 18, 2012

Accepted October 22, 2012