Spreading of Acute Myeloid Leukemia Cells by Trafficking along the Peripheral Outflow Pathway of Cerebrospinal Fluid

MICHAEL SCHMITT[1], ANDREAS NEUBAUER[2], JOCHEN GREINER[3], XUN XU[1], THOMAS F. E. BARTH[4] and KARL BECHTER[5]

[1]*Department of Hematology/Oncology, University of Rostock, Rostock, Germany;*
[2]*Department of Hematology/Oncology, University of Marburg, Germany;*
[3]*Department of Hematology/Oncology, and* [4]*Institute of Pathology, Ulm University, Germany;*
[5]*Clinic for Psychiatry and Psychotherapy II, Ulm University, Günzburg, Germany*

Abstract. *Acute myeloid leukemia (AML) can affect not only bone marrow (BM) and peripheral blood (PB), but also the compartment of cerebrospinal fluid (CSF). Besides standard chemotherapy, specific and non-specific immunotherapy has been employed synergistically to treat AML patients. Here we report on a patient who received standard chemotherapy, unspecific immunotherapy with interleukin-2, as well as later specific CD8$^+$ T-cell stimulation by RHAMM-R3 peptide vaccination. The patient maintained a complete remission in BM and PB, while he developed recurrent relapses in the CSF. Moreover, the patient developed a chloroma in the vicinity of neuronal sheaths during hematological CR, but high leukemia cell numbers within the CSF spaces over a long time period. This rare observation demonstrates several aspects. There is a previously unknown site of leukemia cell distribution, namely the peripheral cerebrospinal outflow pathway (PCOP). This demonstrates the ineffective therapy of this previously unknown mechanism of leukemia cell spread. The hypothesis that the PCOP is a site of physiological CSF-T-cell trafficking, and the lumen of the PCOP should be considered as an extension of the subarachnoidal spaces without closed anatomical borders is supported by this observation. The CSF spaces, but possibly specifically the PCOP, may represent a previously unknown survival niche of tumor cells within intrathecal spaces.*

Correspondence to: Michael Schmitt, MD, Head of Clinical Stem Cell Transplantation and Cellular Therapy, Department of Internal Medicine III, University of Rostock, Ernst-Heydemann-Str. 6, 18057 Rostock, Germany. Tel: +49 3814947424, Fax +49 3814947422, e-mail: michael.schmittu@t-online.de

Key Words: Acute myeloid leukemia, immunotherapy, interleukin-2, peptide vaccination, cerebrospinal fluid, CSF, flow of CSF, chloroma.

Cerebrospinal fluid (CSF), mainly produced at the plexus chorioidei in the ventricles, was thought to be mainly reabsorbed at Pacchioni's granulations of the dura encapsulating the brain. However, according to recent studies in mammals, CSF efflux along nerves takes place inside the neuronal sheaths, passing along nerves into various neuronally supported peripheral tissues, where CSF joins the interstitial fluid and then reaches the lymphatic system (1). A recent hypothesis proposed a more detailed scenario of peripheral CSF outflow pathway (PCOP)-associated pathophysiology (2). Here we present a case of unusual spreading of leukemia cells, strongly supporting, if not proving, one important aspect of the PCOP hypothesis, *i.e.* CSF cell trafficking with physiological CSF efflux along the PCOP and into related tissues in the human system, thus demonstrating a previously unknown metastatic pathway of leukemia cells. Another interesting aspect in this patient is an (experimental) immunotherapy for acute myeloid leukemia (AML). The patient received non-specific stimulation of the T-cellular immune system by interleukin-2, as well as later a specific immunotherapy by vaccination with a CD8$^+$ T-cell epitope derived from a leukemia-associated antigen designated RHAMM (receptor for hyaluronic acid mediated motility) (3). The course of the disease demonstrates that both types of immunotherapy might have had an influence on the antileukemic immune response in peripheral blood (PB) and bone marrow (BM), but not in the immunoprivileged CSF compartment.

Case Report

In 1995, a 56-year-old male patient was diagnosed with AML, with an inversion of chromosome 16. The patient received two cycles of chemotherapy of idarubicin, cytarabine and etoposide. After consolidation with high-dose cytarabine, mitoxantrone and thioguanine, the patient was in complete remission (CR). In 1997, the patient experienced

BM relapse of the disease, and received therapy with cytarabine, resulting in a partial remission. The patient was then treated at a different institution using compassionate use of subcutaneously applied interleukin-2. After two cycles, a second CR was obtained. The patient then received five additional cycles of interleukin-2. In contrast to the long-lasting BM and systemic CR, the patient developed several relapses in the central nervous system (CNS): in 2004 he had 1,000 blasts per microliter of CSF, and was treated by intrathecal application of methotrexate and cytarabine, as well as by immunostimulation using interferon-alpha subcutaneously. The patient achieved a CR in the CSF. Six months later, he again developed a relapse presenting as a chloroma in the vicinity of the ischiadic nerve. The chloroma was treated by involved field irradiation. The patient again achieved a CR which was maintained for one year. Thereafter, a third relapse in the CNS developed, with meningeal involvement; again intrathecal treatment by methotrexate and cytarabine followed by liposomal cytarabine (Depocyte™) was given. The patient developed cauda equina syndrome, and underwent involved field radiation of the axillar plexus, as well as of the lumbosacral radiation. After five months, he again exhibited neurological symptoms and a low number of blasts was again detected in the CSF. The patient received intrathecal and systemic chemotherapy; a CR was obtained. However, fifteen months later, a low number of blasts in the CSF was found, as well as a chloroma of the perineum in the vicinity of the scrotal nerve. Histopathological analysis of the chloroma revealed the presence of AML cells infiltrating the nerve. The leukemia cells were characterized through the expression of myeloperoxidase and RHAMM (3) (Figure 1). To boost the T-cellular immune response to RHAMM, the patient received four courses of subcutaneous vaccination with RHAMM-derived peptide R3. No side-effects other than temporary induration and erythema of the skin at the site of injection were detected. Unfortunately, no clinical improvement was observed, and the patient showed further relapses of AML in the CSF. The patient received intrathecal chemotherapy as well as locoregional irradiation for the chloroma, again achieving CR status. Eventually, in March 2009, the patient died from BM relapse despite palliative chemotherapy with thioguanine and 5-azacytidine.

Discussion

Clearly, chemotherapy and immunostimulation by cytokines maintained the patient in CR of the leukemia in the compartments of the PB and the BM over a long period of time (over 11 years). The CNS is considered to be an immunoprivileged compartment where chemotherapy alone is not able to eradicate the malignant clone, but is just able to temporarily reduce the tumor burden in this compartment (4).

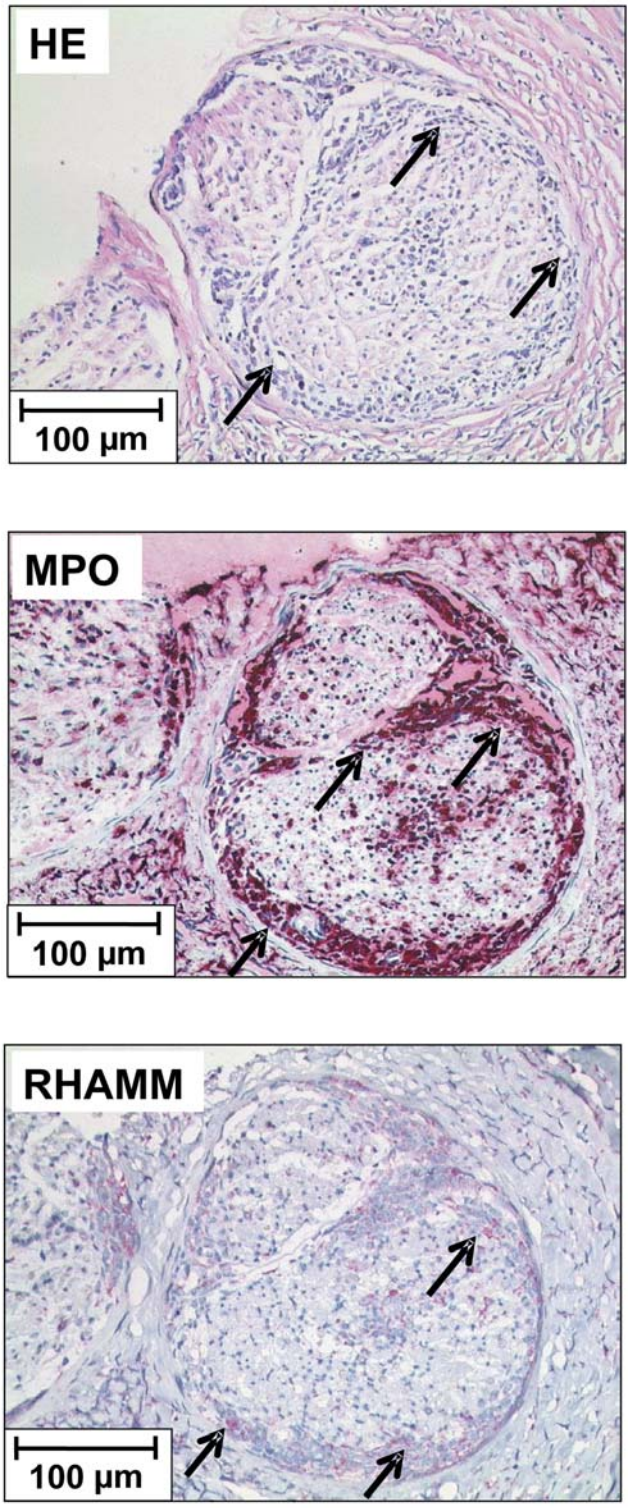

Figure 1. *Histology of a perineal nerve infiltrated by myeloid leukemic cells (serial sections). Standard staining with hematoxylin and eosin (CHE). The leukemia cells were positive for myeloperoxidase (MPO) and the receptor for hyaluronic acid mediated motility (RHAMM). Leukemic cells can be seen to have infiltrated the space between perineurium and epineurium (arrows).*

Relapse of AML may occur in the compartments of BM and PB, as well as CSF (4). Usually relapses within the CSF are followed by systemic relapses. However, exceptional cases of patients exist where CSF relapses occur in an isolated fashion (4, 5). This is true also for our patient, who is an especially interesting case as he developed multiple relapses within the CSF spaces, as well as within the nerves, whereas the BM remained free of blasts for over 11 years. This may be the consequence of a sustained immune response that may have been built after therapy with interleukin-2, and specifically boosted through peptide vaccination therapy (3), but which was apparently not effective in an area near peripheral nerves described as the PCOP (1), which can be considered the extension of the subarachnoidal spaces (2), and which may represent a previously unknown survival niche for leukemia cells.

The most surprising aspect is that our patient had developed several chloromas in the vicinity of spinal nerves and their cutaneous nerves. Although the BM and PB were free of leukemia cells at that time, the CSF contained a high density of leukemia blasts. The chloromas very likely derived from the outflow of the CSF and the leukemia cells contained in this CSF. This type of local disease fits with a scenario predicted by the PCOP hypothesis, where CSF cells were thought to be trafficking with the CSF outflow, involving structures of the PCOP itself, *i.e.* nerves and their sheaths, and PCOP related tissues connected by nerves, *i.e.* cutis and subcutis, especially near nerve endings in parallel (2). The observed localization of leukemia spreading in this patient fits well with the predicted preferential sites of CSF efflux quantities due to gravitational forces (1, 2). The lower part of the body may be more likely to be affected in a person predominantly working in an upright position, as our patient did, and with specific anatomical sites such as distal parts of large nerves for tumor cell accumulation. Such a leukemia cell distribution fulfills the criteria for metastasis and our case demonstrates a previously unknown typology in leukemia. We do not exclude the possibility that minor metastatic leukemia cell dissemination of this type along peripheral nerves is more frequent but has remained unnoticed and that the PCOP site could represent a survival niche for intrathecally hibernating tumor cells. Therefore our case may be also relevant for future approaches to tackle tumor relapse or treatment resistance in leukemia. The PCOP was addressed in several recent publications, but specifically on the CSF outflow through the cribriform plate for which also others assume that cell trafficking may be a physiological phenomenon (6).

Authorship and Disclosures

M.S., A.N. and J.G. treated the patient and discussed the manuscript. M.S. and K.B. wrote the manuscript, X.X. did graphical work. T.F.E.B. performed the immunohistochemistry and microphotography. All authors have nothing to disclose with respect to this case report.

Acknowledgements

This work was supported by generous grants from the German Jose Carreras Leukemia Foundation to M.S. and J.G. (DJCLS A10/01, 10/03, R07/15v and R09/14).

References

1 Bechter K: Cerebrospinal fluid may mediate pathogenic effects on nerves via efflux: a hypothesis from unexpected improved pain syndromes with cerebrospinal fluid filtration. Neurol Psych Brain Res *14*: 37-42, 2007.
2 Bechter K: The peripheral cerebrospinal outflow pathway – physiology and pathophysiology of CSF re-circulation: a review and hypothesis. Neurol Psych Brain Res *17*: xx-xx, 2011 (in press).
3 Schmitt M, Schmitt A, Rojewski M, Chen J, Gotz M, Heyduk M, Giannopoulos K, Ritter G, Gnjatic S, Guillaume P, Ringhogger M, Schlenk R, Liebisch P, Bunjes D, Shiku H, Dohner H and Greiner J: RHAMM-R3 peptide vaccination in patients with acute myeloid leukemia, myelodysplastic syndrome and multiple myeloma elicits immunological and clinical responses. Blood *111*: 1357-1365, 2008.
4 Imataki O, Ohnishi H, Kitanaka A, Kubota Y, Tanaka T and Ishida T: Isolated extramedullary relapse presenting as autologous lymphocyte response. Am J Hematol *83*: 512-514, 2008.
5 Owonikoko T, Agha M, Balassanian R, Smith R and Raptis A: Gemtuzumab therapy for isolated extramedullary AML relapse following allogeneic stem-cell transplant. Nat Clin Pract Oncol *4*: 491-495, 2007.
6 Weller RO, Djuanda E, Yow HY and Carare RO: Lymphatic drainage of the brain and the pathophysiology of neurological disease. Acta Neuropathol *117*: 1-14, 2009.

Received March 15, 2011
Revised May 19, 2011
Accepted May 20, 2011