

Surgical Management of Bisphosphonate-related Osteonecrosis of the Jaw in Oncologic Patients: A Challenging Problem

A. M. ECKARDT, J. LEMOUND, D. LINDHORST, M. RANA and N-C. GELLRICH

Department of Cranio-Maxillofacial Surgery, Hannover Medical School, 30625 Hannover, Germany

Abstract. *Aim: Bisphosphonate-related osteonecrosis of the jaw (BRONJ) is a serious oral complication of supportive cancer therapy and the best method of treatment is still unclear. The purpose of this article is to analyze the type of treatment and outcome in a large patient cohort with BRONJ. Patients and Methods: A total of 142 patients suffering from BRONJ at different sites were studied. All patients had been treated with intravenous bisphosphonates for various oncological disease. A descriptive analysis of all relevant patient data was performed with particular emphasis on surgical outcome. Results: The mandible was affected in 58% of the patients. All but two patients had previous invasive dental procedures. The mean duration of bisphosphonate treatment was 37.1 months. A total of 86% of the patients were treated surgically, including sequestrectomies and mandibular resections. Soft-tissue reconstruction was achieved by local closure, myofascial flap using the mylohyoid muscle, and a vascularized fasciocutaneous flap in one patient. No bony reconstruction was performed. Conclusion: Surgical treatment of BRONJ remains challenging. There is only limited evidence that oncologic patients with BRONJ are candidates for vascularized bone reconstruction.*

Since the first report in 2003 (1), the number of publications describing the development of osteonecrosis of the jaw in patients receiving bisphosphonates has increased continuously.

The introduction of bisphosphonates into the armamentarium was a determining step in the prevention and treatment of skeletal metastases and osteoporosis, as well management of multiple myeloma, Paget's disease and hypercalcaemia.

Correspondence to: André M. Eckardt, MD, DDS, Ph.D., MBA, Department of Cranio-Maxillofacial Surgery, Hannover Medical School, Carl-Neuberg-Strasse 1, 30625 Hannover, Germany. Tel: +49 5115324878, Fax: +49 5115328879, e-mail: eckardt.andre@mh-hannover.de

Key Words: Bisphosphonate, osteonecrosis, mandible, BRONJ.

The beneficial effects of bisphosphonates are to inhibit the resorption of trabecular bone by osteoclasts, preserve its density and prevent the loss of bone mass and pathological fractures (2, 3). Bisphosphonates are divided into two classes according to the presence of a nitrogen side chain on the pyrophosphate group. The non-nitrogen containing bisphosphonates (etidronate, clodronate, tiludronate) lead to apoptosis of osteoclasts by disturbance of cellular energy pathways. The nitrogenous bisphosphonates (pamidronate, alendronate, ibandronate, zoledronate) inhibit the 3-hydroxy-3-methyl-glutaryl-coenzyme A (HMG-CoA) reductase pathway and block the building of hydrophobic molecules which are essential for maintenance of cell membranes, cellular protein connections and trafficking, and hormone production. Inhibition of the HMG-CoA reductase pathway disturbs proper osteoclastogenesis and apoptosis. Changes in cytoskeletal dynamics of osteoclasts disrupts their adherence to the bony surface (4, 5).

The clinical appearance of bisphosphonate-related osteonecrosis of the jaw is defined as exposed necrotic bone of the oral cavity for at least 8 weeks in patients without previous radiotherapy to this area (3, 6-8). Invasive dental procedures, parodontitis, and constant microtrauma can lead to bacterial contamination and infection of the necrotic jawbone, which are accompanied by pain, swelling, non-healing ulceration and loosening of teeth. In an advanced phase, radiological changes such as bone mottling and osteolysis, bony sequestra, and thickened and sclerotic lamina dura can be observed. A reduced bone turnover leads to residual 'ghost sockets' after teeth removal, which can persist for years (9-11).

The prevalence of BRONJ, especially that following intravenous administration of bisphosphonates, has been underestimated in the past; recent findings revealed a range up to 18%, depending on treatment duration (12-19). Generally, the prevalence of osteonecrosis of the jaw among patients taking bisphosphonates orally ranges from 0.001% to 0.2% (10, 15, 19, 20), the relative proportion of patients with BRONJ associated with oral bisphosphonate therapy relative to all BRONJ patients has been found to range from 0.02% to 7.8% (21-23).

The hypotheses regarding the development of BRONJ are controversial. Different theories have attempted to explain such a devastating jaw-specific side-effect of bisphosphonates, such as interference in the regular remodeling processes of the jaw by disturbing of function and apoptosis of osteoclasts (24-26). Other authors postulate as further theories the toxicity of bisphosphonates on fibroblasts and endothelial cells (27), bony microcracks (28), bacterial infection of the jaw, especially by actinomycetes, but also novel forms of yeast, spirochetes and treponemes (29, 30). The risk of BRONJ might be associated with *i.v.* bisphosphonate use and increased duration of treatment (8, 24, 29, 31). A review of 2,400 BRONJ patients this year revealed extractions to be a predisposing factor in 67% and spontaneous development in 26% of cases (32). Furthermore, chemotherapy (55%), steroid use (32%), periodontal disease (16%), hormone therapy (9%), smoking (3%), diabetes (2%), hyperlipidemia (2%) and alcoholism (1%) were identified as potential risk factors (32), results which had been confirmed by other reviewers (14, 33-35).

The mandible is affected by BRONJ twice as often as the maxilla (31). The treatment of BRONJ is difficult, and the reported cure rates are poor (36-38). At present, monitoring and prevention of surgical procedures and trauma are the most important measure for at risk patients (39-41). In severe cases, however, surgical procedures are necessary despite their controversial status in the literature. Recommended therapeutic modalities range from cautious sequestrectomies to the resection of the affected mandible followed by rigid plate fixation without bony reconstruction (8, 24, 42, 43). Marx *et al.* and Ruggiero *et al.* have advocated against microvascular bone reconstruction in cases of BRONJ (24, 39). Some authors even recommend aggressive surgical debridement of necrotic bone areas and immediate reconstruction of defects with vascularized grafts (42-47).

The purpose of this study was to analyze a large patient cohort suffering from BRONJ of various stages from a single institution, with particular emphasis on surgical management of this complication.

Patients and Methods

Institutional Review Board approval was obtained from Hannover Medical School (Hannover, Germany). All patients who were referred to our institution between August 2003 and January 2010 with a suspected diagnosis of BRONJ were analyzed retrospectively based on the individual patient record, imaging files and surgical treatment. The clinical database included patient demographics, indications for bisphosphonate use and route of administration (oral or *i.v.*), and preoperative morbidities related to BRONJ (soft-tissue fistula, pain, infection, pathologic fracture, surgical procedure). Patients were followed-up long-term to determine any surgical complication or residual BRONJ. All data were subjected to a descriptive data analysis.

Results

A total of 142 patients with a proven diagnosis of BRONJ were treated at our institution from 2003 to 2010. There were 95 female patients and 47 male patients, ranging in age from 38 to 94 (median age 62 years) years. On initial clinical examination, most patients complained of a painful exposed bony area in the upper or lower jaw (Figure 1). In addition to clinical examination all patients underwent further diagnostic imaging including orthopantomogram and cone-beam computed tomography (CBCT) to assess the full extent of the involved bone area (Figure 2). In most patients (58%), the mandible was involved, the maxilla was involved in 27%, and both jaws were involved in 15% of the patient cohort. All patients had previous or ongoing bisphosphonate medication for various oncologic diseases (Table I). With regard to the various bisphosphonates given, the analysis revealed that 97% of the patients received nitrogen-containing bisphosphonates intravenously such as zoledronate (57.7%), followed by pamidronate in 14.8% and ibandronate in 14.1% of the patient population (Table I). The mean duration of bisphosphonate treatment was 37.1 months (range 5 to 130 months) in our patient population. All but two patients developed bisphosphonate-associated osteonecrosis following minor surgical procedures (tooth extraction, apicectomies). The majority of patients (86%) required surgical interventions of the involved necrotic bone areas under local or general anesthesia. Patients received pre- and postoperative *i.v.* antibiotic medication with penicillin or clindamycin. Surgical treatment comprised transoral sequestrectomy in the exposed bone area and tension-free soft tissue closure. In patients with large exposed necrotic bone areas (64%), a marginal bone resection was performed followed by local soft tissue closure. In those patients (n=6) with extensive osteonecrosis, infection or pathologic fracture of the mandible, a continuity resection of the involved mandible, with immediate rigid fixation using titanium reconstruction plates was performed using a submandibular approach (Figure 3). No vascularized bone transfer was performed. In cases of oral soft-tissue breakdown, a myofascial flap from the mylohyoid muscle proved to be a reliable method to close soft-tissue defects of the lateral mandibular area. This procedure was performed in 20 patients. Only in one patient with advanced BRONJ, infection, and pathologic fracture of the mandible was intraoral soft-tissue reconstruction performed using a fascio-cutaneous vascularized graft from the upper lateral arm. It is noteworthy that in 40% of the treated patients, additional surgical interventions were required due to refractory BRONJ. In only 14% of the patients was conservative treatment, consisting of intensive oral irrigation with chlorhexidine and antibiotic medications, effective.

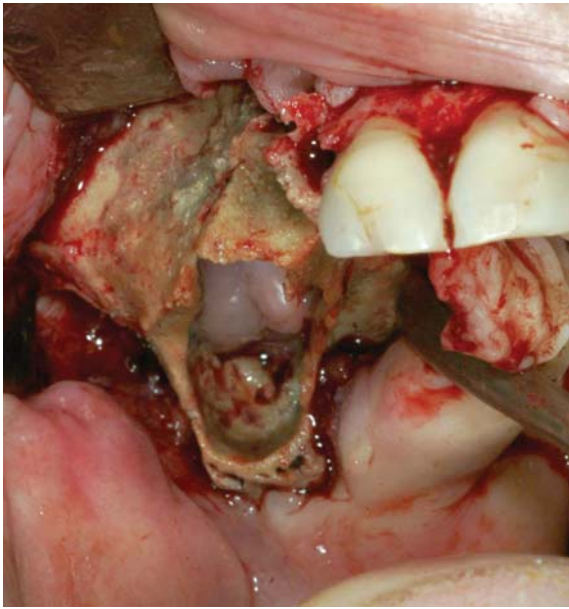

Figure 1. Extensive osteonecrosis of right maxilla in a 57-year-old patient with metastasizing breast cancer. She was treated with i.v. zoledronate for 4 years and had undergone extraction of an upper premolar tooth 2 years earlier.

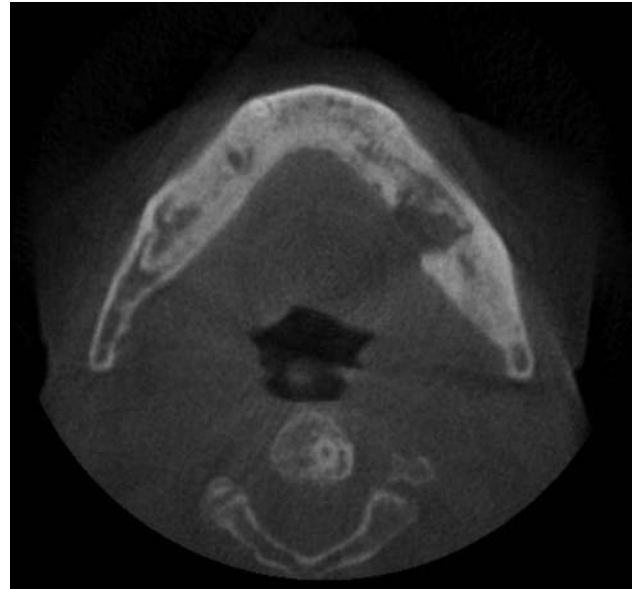


Figure 2. Axial cone-beam CT of the mandible shows extensive sclerosis, mottling, cortical destruction and sequestra formation.

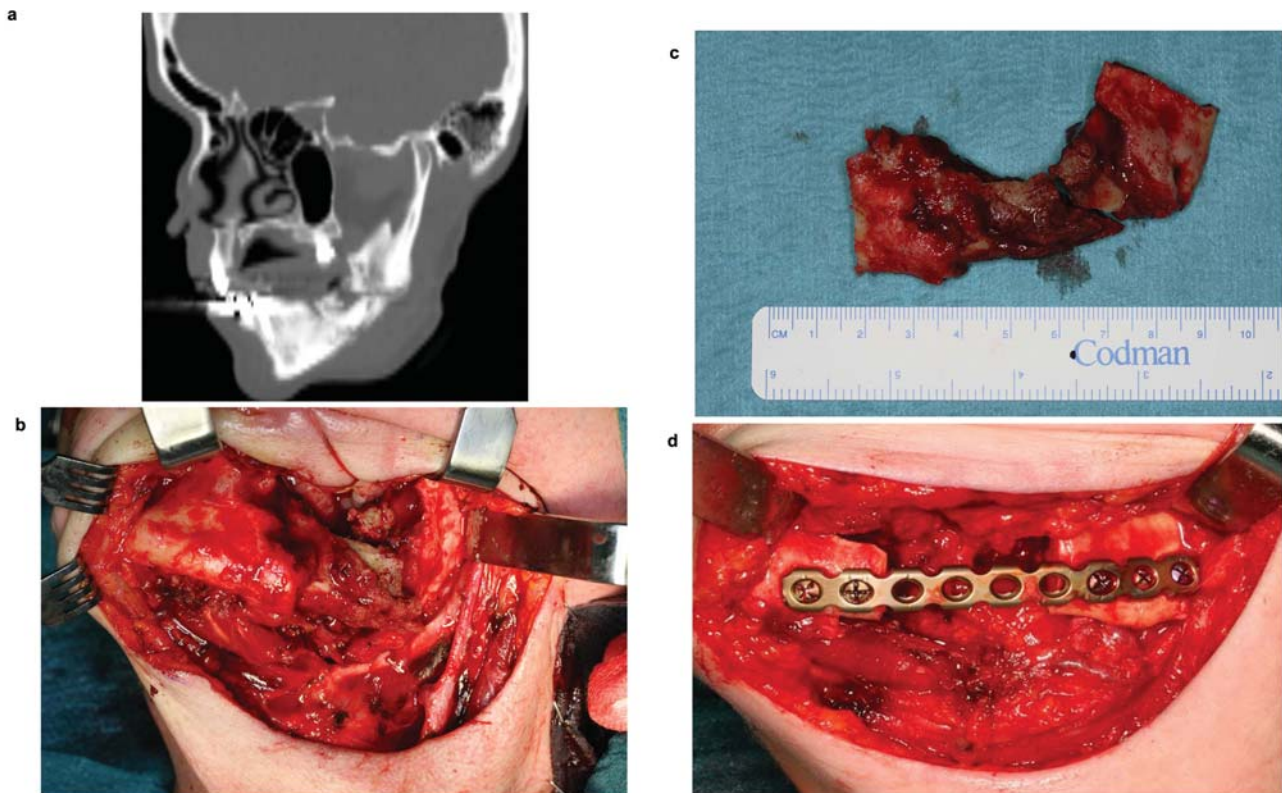


Figure 3. A 54-year-old patient with metastasizing breast cancer had been treated with i.v. zoledronate for 4 years. Following tooth extraction while she was off bisphosphonate treatment, she developed extensive osteonecrosis of the left mandible with pathologic fracture (a). She underwent segmental resection of the affected mandible with a submandibular approach (b). The surgical specimen shows extensive necrotic bone with pathologic fracture (c). Mandibular reconstruction was achieved using a titanium reconstruction plate (d).

Table I. Characteristics of patients with bisphosphonate-related osteonecrosis of the jaw (n=142).

	N	%
Gender		
Male	47	
Female	95	
Age, years		
Median	62	
Range	38-94	
Disease		
Breast cancer	51	36
Prostate cancer	20	14
Plasmocytoma	34	24
Renal cell carcinoma	14	10
Non-Hodgkin lymphoma	1	1
Acute myloid leukemia	1	1
Thyroid cancer	7	5
Colon cancer	1	1
Pancreatic cancer	1	1
Lung cancer	8	6
Type of bisphosphonate		
Etidronate	1	0.7
Risedronate	3	2.1
Clodronate	1	0.7
Pamidronate	21	14.8
Alendronate	12	8.5
Ibandronate	20	14.1
Zoledronate	82	57.7
Pamidronate/ibandronate	2	1.4
Time of exposure, months		
Mean	37.1	
Range	5-130	
Site of BRONJ		
Mandible	82	58
Maxilla	39	27
Both jaws	21	15
Treatment		
Non-surgical	20	14
Surgical	122	86
Type of surgery		
Sequestrectomy, local closure	17	14
Sequestrectomy, myofascial flap	20	16
Marginal bone resection	78	64
Segmental bone resection, plate reconstruction	6	5
Segmental bone resection, soft tissue reconstruction (free fascio-cutaneous flap), plate reconstruction	1	1

Discussion

BRONJ is a rare but significant complication, mostly seen in oncologic patients who are being treated with bisphosphonates (48). The current literature supports a stage-dependent treatment and if resection is required, only conservative defect reconstruction. In contrast, there is a

small group of authors advocating in favor of microvascular bone reconstruction in selected patients (42-47). In the present study, in a total of 23 patients suffering from advanced BRONJ, mandibular resection and immediate microvascular bone reconstruction was performed. Although the technical feasibility of this approach was demonstrated, it is probably too early to draw definitive conclusions with regard to general recommendations for patients with advanced BRONJ.

There is a growing number of publications focusing on the outcome of surgical treatment of BRONJ (49-52). Van der Wyngaert *et al.* concluded in their analysis over two years that 73% of patients showed residual BRONJ after conservative or surgical therapy (49). In a recent study, Scoletta *et al.* (36) reported 54.1% responders in 37 patients treated with conservative or surgical therapy. However, only 23% of BRONJ resolved after conservative therapy in 4,019 patients (13). In a multicenter study, Abu-Id *et al.* reported healing after marginal or segmental bone resection in 86% of cases compared with 46% responders after conservative therapy (11).

There is a consensus among all experts as to the difficulty of treating BRONJ and the importance of prevention. The risk of developing BRONJ can be reduced by optimized oral and dental health and regular monitoring of patients treated with bisphosphonates. Patients should be informed by treating clinicians of the low but real risk of developing BRONJ and of the importance and necessity for regular dental visits and prophylactic dental treatment (39).

It can be concluded that there is no general consensus at present on the extent of surgical resection and reconstruction in cases of advanced BRONJ. Only by continuously expanding our knowledge of this serious side-effect and by careful long-term follow-up of patients will it hopefully become more evident if such extensive surgical reconstructions are justified at all in cancer patients at risk for lengthy surgical procedures.

References

- 1 Marx RE: Pamidronate (Aredia)-and zoledronate (Zometa)-induced avascular necrosis of the jaws: a growing epidemic. *J Oral Maxillofac Surg* 61: 1115-1117, 2003.
- 2 Vasikaran SD: Bisphosphonates: an overview with special reference to alendronate. *Ann Clin Biochem* 38: 608-623, 2001.
- 3 Weitzman R, Sauter N, Eriksen EF, Tarassoff PG, Lacerna LV, Dias R, Altmeyer A, Csermak-Renner K, McGrath L, Lantwicki L and Hohneker JA: Critical review: updated recommendations for the prevention, diagnosis, and treatment of osteonecrosis of the jaw in cancer patients May 2006. *Crit Rev Oncol Hematol* 62: 148-152, 2007.
- 4 Fleisch H: Bisphosphonates: mechanisms of action. *Endocr Rev* 19: 80-100, 1998.
- 5 van Beek ER, Cohen LH, Leroy IM, Ebetino FH, Lowik CW and Papapoulos SE: Differentiating the mechanisms of antiresorptive action of nitrogen-containing bisphosphonates. *Bone* 33: 805-811, 2003.

- 6 Ruggiero SL, Carlson ER and Assael LA: Comprehensive review of bisphosphonate therapy: implications for the oral and maxillofacial surgery patient. *J Oral Maxillofac Surg* 67: 1, 2009.
- 7 Advisory Task Force on Bisphosphonate-Related Osteonecrosis of the Jaws, American Association of Oral and Maxillofacial Surgeons: American Association of Oral and Maxillofacial Surgeons position paper on bisphosphonate-related osteonecrosis of the jaws. *J Oral Maxillofac Surg* 65: 369-376, 2007.
- 8 Ruggiero SL, Dodson TB, Assael LA, Landesberg R, Marx RE and Mehrotra B, American Association of Oral and Maxillofacial Surgeons: American Association of Oral and Maxillofacial Surgeons position paper on bisphosphonate-related osteonecrosis of the jaws - 2009 update. *J Oral Maxillofac Surg* 67: 2-12, 2009.
- 9 Chiandussi S, Biasotto M, Dore F, Cavalli F, Cova MA and Di Lenarda R: Clinical and diagnostic imaging of bisphosphonate-associated osteonecrosis of the jaws. *Dentomaxillofac Radiol* 35: 236-243, 2006.
- 10 Khosla S, Burr D, Cauley J, Dempster DW, Ebeling PR, Felsenberg D, Gagel RF, Gilsanz V, Guise T, Koka S, McCauley LK, McGowan J, McKee MD, Mohla S, Pendrys DG, Raisz LG, Ruggiero SL, Shafer DM, Shum L, Silverman SL, Van Poznak CH, Watts N, Woo SB and Shane E, American Society for Bone and Mineral Research: Bisphosphonate-associated osteonecrosis of the jaw: report of a task force of the American Society for Bone and Mineral Research. *J Bone Miner Res* 22: 1479-1491, 2007.
- 11 Abu-Id MH, Warnke PH, Gottschalk J, Springer I, Wiltfang J, Acil Y, Russo PA and Kreusch T: 'Bis-phosphy jaws' - high and low risk factors for bisphosphonate-induced osteonecrosis of the jaw. *J Craniomaxillofac Surg* 36: 95-103, 2008.
- 12 Walter C, Al-Nawas B, Frickhofen N, Gamm H, Beck J, Reinsch L, Blum C, Grotz KA and Wagner W: Prevalence of bisphosphonate-associated osteonecrosis of the jaws in multiple myeloma patients. *Head Face Med* 6: 11, 2010.
- 13 Hoff AO, Toth BB, Altundag K, Johnson MM, Warneke CL, Hu M, Nooka A, Sayegh G, Guarneri V, Desrouleaux K, Cui J, Adamus A, Gagel RF and Hortobagyi GN: Frequency and risk factors associated with osteonecrosis of the jaw in cancer patients treated with intravenous bisphosphonates. *J Bone Miner Res* 23: 826-836, 2008.
- 14 Mavrokokki T, Cheng A, Stein B and Goss A: Nature and frequency of bisphosphonate-associated osteonecrosis of the jaws in Australia. *J Oral Maxillofac Surg* 65: 415-423, 2007.
- 15 Durie BG, Katz M and Crowley J: Osteonecrosis of the jaw and bisphosphonates. *N Engl J Med* 353: 99-102, 2005.
- 16 Boonyapakorn T, Schirmer I, Reichart PA, Sturm I and Massenkeil G: Bisphosphonate-induced osteonecrosis of the jaws: prospective study of 80 patients with multiple myeloma and other malignancies. *Oral Oncol* 44: 857-869, 2008.
- 17 Badros A, Terpos E, Katodritou E, Goloubeva O, Kastritis E, Verrou E, Zervas K, Baer MR, Meiller T and Dimopoulos MA: Natural history of osteonecrosis of the jaw in patients with multiple myeloma. *J Clin Oncol* 26: 5904-5909, 2008.
- 18 Bamias A, Kastritis E, Bamia C, Mouloupoulos LA, Melakopoulos I, Bozas G, Koutsoukou V, Gika D, Anagnostopoulos A, Papadimitriou C, Terpos E and Dimopoulos MA: Osteonecrosis of the jaw in cancer after treatment with bisphosphonates: incidence and risk factors. *J Clin Oncol* 23: 8580-8587, 2005.
- 19 Ruggiero SL, Fantasia J and Carlson E: Bisphosphonate-related osteonecrosis of the jaw: background and guidelines for diagnosis, staging and management. *Oral Surg Oral Med Oral Pathol Oral Radiol Endod* 102: 433-441, 2006.
- 20 Woo SB, Hellstein JW and Kalmar JR: Narrative [corrected] review: bisphosphonates and osteonecrosis of the jaws. *Ann Intern Med* 144: 753-761, 2006.
- 21 King AE and Umland EM: Osteonecrosis of the jaw in patients receiving intravenous or oral bisphosphonates. *Pharmacotherapy* 28: 667-677, 2008.
- 22 Rizzoli R, Burlet N, Cahall D, Delmas PD, Eriksen EF, Felsenberg D, Grbic J, Jontell M, Landesberg R, Laslop A, Wollenhaupt M, Papapoulos S, Sezer O, Sprafka M and Reginster JY: Osteonecrosis of the jaw and bisphosphonate treatment for osteoporosis. *Bone* 42: 841-847, 2008.
- 23 Silverman SL and Landesberg R: Osteonecrosis of the jaw and the role of bisphosphonates: a critical review. *Am J Med* 122: S33-45, 2009.
- 24 Marx RE, Sawatari Y, Fortin M and Broumand V: Bisphosphonate-induced exposed bone (osteonecrosis/osteopetrosis) of the jaws: risk factors, recognition, prevention, and treatment. *J Oral Maxillofac Surg* 63: 1567-1575, 2005.
- 25 Reid IR: Osteonecrosis of the jaw: Who gets it, and why? *Bone* 44: 4-10, 2009.
- 26 Ruggiero SL: Bisphosphonate-related osteonecrosis of the jaw (BRONJ): initial discovery and subsequent development. *J Oral Maxillofac Surg* 67: 13-18, 2009.
- 27 Schepers MA, Badros A, Chaisuparat R, Cullen KJ and Meiller TF: Effect of zoledronic acid on oral fibroblasts and epithelial cells: a potential mechanism of bisphosphonate-associated osteonecrosis. *Br J Haematol* 144: 667-676, 2009.
- 28 Hoefert S, Schmitz I, Tannapfel A and Eufinger H: Importance of microcracks in etiology of bisphosphonate-related osteonecrosis of the jaw: a possible pathogenetic model of symptomatic and non-symptomatic osteonecrosis of the jaw based on scanning electron microscopy findings. *Clin Oral Invest* 14: 271-284, 2010.
- 29 Sedghizadeh PP, Kumar SK, Gorur A, Schaudinn C, Shuler CF and Costerton JW: Identification of microbial biofilms in osteonecrosis of the jaws secondary to bisphosphonate therapy. *J Oral Maxillofac Surg* 66: 767-775, 2008.
- 30 Sedghizadeh PP, Kumar SK, Gorur A, Schaudinn C, Shuler CF and Costerton JW: Microbial biofilms in osteomyelitis of the jaw and osteonecrosis of the jaw secondary to bisphosphonate therapy. *J Am Dent Assoc* 140: 1259-1265, 2009.
- 31 Migliorati CA, Casiglia J, Epstein J, Jacobsen PL, Siegel MA and Woo SB: Managing the care of patients with bisphosphonate-associated osteonecrosis: an American Academy of Oral Medicine position paper. *J Am Dent Assoc* 136: 1658-1668, 2005.
- 32 Filleul O, Crompton E and Saussez S: Bisphosphonate-induced osteonecrosis of the jaw: a review of 2,400 patient cases. *J Cancer Res Clin Oncol* 136: 1117-1124, 2010.
- 33 Assael LA: Oral bisphosphonates as a cause of bisphosphonate-related osteonecrosis of the jaws: clinical findings, assessment of risks, and preventive strategies. *J Oral Maxillofac Surg* 67: 35-43, 2009.
- 34 Fehm T, Felsenberg D, Krimmel M, Solomayer E, Wallwiener D and Hadji P: Bisphosphonate-associated osteonecrosis of the jaw in breast cancer patients: recommendations for prevention and treatment. *Breast* 18: 213-217, 2009.
- 35 Hess LM, Jeter JM, Benham-Hutchins M and Alberts DS: Factors associated with osteonecrosis of the jaw among bisphosphonate users. *Am J Med* 121: 475-483, 2008.

- 36 Scoletta M, Arduino PG, Dalmaso P, Broccoletti R and Mozzati M: Treatment outcomes in patients with bisphosphonate-related osteonecrosis of the jaws: a prospective study. *Oral Surg Oral Med Oral Pathol Oral Radiol Endod* 110: 46-53, 2010.
- 37 Van den Wyngaert T, Claeys T, Huizing MT, Vermorken JB and Fossion E: Initial experience with conservative treatment in cancer patients with osteonecrosis of the jaw (ONJ) and predictors of outcome. *Ann Oncol* 20: 331-336, 2009.
- 38 Fantasia JE: Bisphosphonates – what the dentist needs to know: practical considerations. *J Oral Maxillofac Surg* 67: 53-60, 2009.
- 39 Ruggiero SL: Bisphosphonate-related osteonecrosis of the jaw: an overview. *Ann NY Acad Sci* 1218: 38-46, 2011.
- 40 Knight RJ, Reddy C, Rtshiladze MA, Lvoeff G, Sherring D and Marucci D: Bisphosphonate-related osteonecrosis of the jaw: tip of the iceberg. *J Craniofac Surg* 21: 25-32, 2010.
- 41 Rayman S, Almas K and Dincer E: Bisphosphonate-related jaw necrosis: a team approach management and prevention. *Int J Dent Hyg* 7: 90-95, 2009.
- 42 Mucke T, Koschinski J, Deppe H, Wagenpfeil S, Pautke C, Mitchell DA, Wolff KD and Holzle F: Outcome of treatment and parameters influencing recurrence in patients with bisphosphonate-related osteonecrosis of the jaws. *J Cancer Res Clin Oncol* 137: 907-913, 2010.
- 43 Carlson ER and Basile JD: The role of surgical resection in the management of bisphosphonate-related osteonecrosis of the jaws. *J Oral Maxillofac Surg* 67: 85-95, 2009.
- 44 Engroff SL and Kim DD: Treating bisphosphonate osteonecrosis of the jaws: Is there a role for resection and vascularized reconstruction? *J Oral Maxillofac Surg* 65: 2374-2385, 2007.
- 45 Ferrari S, Bianchi B, Savi A, Poli T, Multinu A, Balestreri A and Ferri A: Fibula free flap with endosseous implants for reconstructing a resected mandible in bisphosphonate osteonecrosis. *J Oral Maxillofac Surg* 66: 999-1003, 2008.
- 46 Seth R, Futran ND, Alam DS and Knott PD: Outcomes of vascularized bone graft reconstruction of the mandible in bisphosphonate-related osteonecrosis of the jaws. *Laryngoscope* 120: 2165-2171, 2010.
- 47 Nocini PF, Saia G, Bettini G, Ragazzo M, Blandanura S, Chiarini I and Bedogni A: Vascularized fibula flap reconstruction of the mandible in bisphosphonate-related osteonecrosis. *Eur J Surg Oncol* 35: 373-379, 2009.
- 48 Migliorati CA, Schubert MM, Peterson DE and Seneda LM: Bisphosphonate-associated osteonecrosis of mandibular and maxillary bone: an emerging oral complication of supportive cancer therapy. *Cancer* 104: 83-93, 2005.
- 49 Van den Wyngaert T, Huizing MT and Vermorken JB: Osteonecrosis of the jaw related to the use of bisphosphonates. *Curr Opin Oncol* 19: 315-322, 2007.
- 50 Stockmann P, Vairaktaris E, Wehrhan F, Seiss M, Schwarz S, Spriewald B, Neukam FW and Nkenke E: Osteotomy and primary wound closure in bisphosphonate-associated osteonecrosis of the jaw: a prospective clinical study with 12 months' follow-up. *Support Care Cancer* 18: 449-460, 2009.
- 51 Wilde F, Heufelder M, Winter K, Hendricks J, Frerich B, Schramm A and Hemprich A: The role of surgical therapy in the management of intravenous bisphosphonates-related osteonecrosis of the jaw. *Oral Surg Oral Med Oral Pathol Oral Radiol Endod* 111: 153-163, 2010.
- 52 Stanton DC and Balasanian E: Outcome of surgical management of bisphosphonate-related osteonecrosis of the jaws: review of 33 surgical cases. *J Oral Maxillofac Surg* 67: 943-950, 2009.

Received March 9, 2011

Revised May 4, 2011

Accepted May 6, 2011