

# Hemangiopericytoma/Solitary Fibrous Tumor of the Oral Cavity

FRANCESCA ANGIERO<sup>1</sup>, ANTONIO SIGNORE<sup>2</sup> and STEFANO BENEDICENTI<sup>2</sup>

<sup>1</sup>*Department of Pathology, University of Milan-Bicocca, Italy;*

<sup>2</sup>*Department of Biophysical Medical and Stomatological Science and Technology, University of Genoa, Italy*

**Abstract.** *Hemangiopericytoma/solitary fibrous tumor is a very rare tumor of uncertain malignant potential. About 300 such cases have been reported since 1942, when Stout and Murray described these tumors as "vascular tumors arising from Zimmerman's pericytes". Under the World Health Organization (WHO) classification, hemangiopericytomas and solitary fibrous tumors of the soft tissues are regarded as features of the same entity in the soft tissue fascicle. We report the case of a 54-year-old woman who presented with a painless right-side cheek mass of 2 cm maximum diameter. The lesion was completely removed by wide surgical resection. Histologically, the tumour had staghorn-like vasculature and immunohistochemistry for Calponin, CD68 KPI, AE1-AE3, smooth muscle actin and P63, S-100 was negative; that for CD34 was positive. A diagnosis of hemangiopericytoma/solitary fibrous tumor was rendered. The patient had a normal postoperative course of healing, and 24 months later remains asymptomatic, without signs of recurrence or metastasis. Because of the rarity and unpredictable biological behavior of these tumors, long-term follow-up is necessary even after radical resection because recurrence or development of metastasis may be delayed by many years.*

The term hemangiopericytoma (HPC) was introduced by Stout and Murray in 1942 for tumors located in the retroperitoneum, buttock, and thigh (1). They proposed an origin from pericytic-modified smooth muscle cells located around the blood vessels, a cell-type described by Zimmermann in 1923 (2).

The solitary fibrous tumor (SFT) was first described in the pleura, by Klemperer and Rabin in 1931 (3), and was regarded originally as mesothelioma (4). Subsequently, SFTs

have been observed at a number of extrapleural sites (5-7), including the soft tissues (8).

In the 2006 World Health Organization (WHO) fascicle of soft tissue tumors, it is stated that the histological appearance and clinical behavior of HPC and solitary fibrous tumor are similar, a view widely shared (8, 9). Accordingly, the unifying term 'hemangiopericytoma/solitary fibrous tumor' (HPC/SFT) has been proposed (10).

HPC/SFT have been reported at various head and neck sites, including the meninges (11), thyroid (12, 13), larynx (14, 15), nasal cavity (16), paranasal sinuses (17), orbit (18), nasopharynx (19), salivary glands, submandibular gland (20-22), sublingual gland (20, 23, 24), parotid gland (20, 25) and in the oral cavity (26, 27). There are also reports of six cases of SFT of which the exact site of origin remains unclear (20, 25, 26). We describe a case of SFT involving the cheek, of which to our knowledge, very few have been reported.

HPC/SFT located at the oral cavity occurs most often in adults (mean age=52 years), with a slight female predilection. The patients commonly complain of a slowly growing, well-circumscribed, asymptomatic mass. However, other symptoms include pain (20, 25, 28), dysphagia, obstructive sleep apnea, and altered speech (29). Systemic signs and paraneoplastic syndromes have not been reported, although these features have been described in a case of intrathoracic location (30).

Here we report a case of HPC/SFT and illustrate the morphological, immunohistochemical and clinical aspects of this very rare tumor of the oral cavity.

## Case Report

A 54-year-old woman presented to our Department of Oral Pathology with a painless right-side cheek mass of 2 cm in maximum diameter. The mass was well circumscribed, mobile and soft at palpation. The overlying mucosa was intact and normal. The lesion was completely removed by wide surgical resection. The histological diagnosis was of SFT, cellular variant, with hemangiopericytoma-like features. The patient had a normal postoperative course of healing, and 24 months later remains asymptomatic, without signs of recurrence or metastasis.

*Correspondence to:* Professor Francesca Angiero, MD, Anatomia Patologica, Ospedale San Gerardo Monza, Via Pergolesi, 33 Monza, Italy. Tel: +39 0392332556, Fax: +39 02799007, e-mail: f.angiero@teos.it

**Key Words:** Hemangiopericytoma, solitary fibrous tumor, oral cavity, cheek, soft tissue.

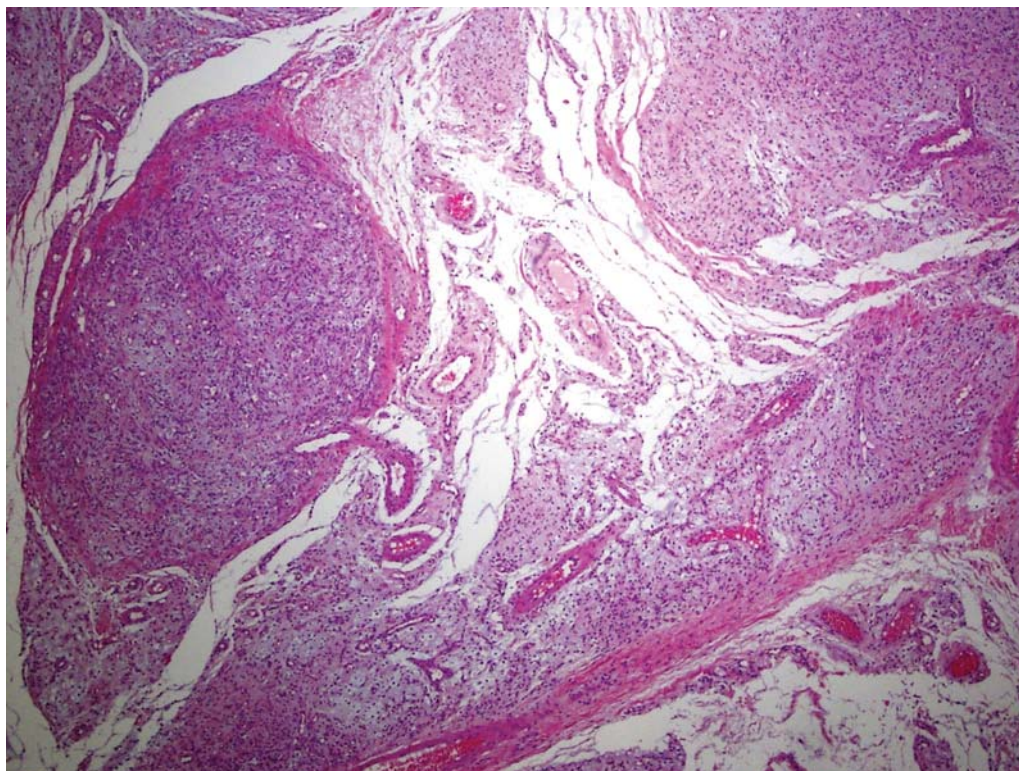


Figure 1. Islands of cells arranged in multilobular aspect separated by collagen fibers (H&E, original magnification  $\times 100$ ).

Histopathological examination revealed a cellular, highly vascularized tumor, with staghorn vasculature, collagen bundles, and rare mitoses. Cellularity was moderate to high (Figures 1 and 2). Immunohistochemistry was carried out for calponin, CD34, CD68KP1, CD31, AE1-AE3, smooth muscle actin (SMA), P63 and S-100: The list of primary antibodies with their respective dilutions is given in Table I. A standard procedure with antibodies and the avidin/biotin method was used. The spindled tumor cells were negative for the following markers: calponin, CD68KP1, AE1-AE3, SMA P63 and S-100; CD34 staining was strongly positive (Figure 3), the immunohistochemical profile was consistent with a diagnosis of HPC/SFT.

## Discussion

The histopathological diagnosis of these vascularized tumors is challenging, in particular because of the difficulty in differentiating HPC from other tumors types that have prominent vascularization: schwannoma, myofibroblastoma, metastasis from spindle-cell carcinoma, low-grade fibromyxoid sarcoma (especially if myxoid foci are prominent), synovial sarcoma, and malignant peripheral nerve sheath tumor (1).

Table I. List of antibodies used and results (Dako, Denmark).

| Antigen             | Clone      | Dilution | Antigen retrieval | Results |
|---------------------|------------|----------|-------------------|---------|
| CD34                | Qbend/10   | 1:50     | None              | +       |
| Calponin            | 1A4        | 1:100    | None              | –       |
| CD68KP1             | KPI        | 1:300    | Citrate PH6       | –       |
| Smooth muscle actin | 1A4        | 1:100    | None              | –       |
| P63                 | 4A4        | 1:50     | Citrate PH6       | –       |
| S-100               | Polyclonal | 1:1000   | None              | –       |

Angiographic features frequently help to differentiate HPC from other hypervascular lesions.

From the morphological standpoint, they generally have a monotonous appearance, with moderate-to-high cellularity, little fibrosis, numerous thin-walled ‘staghorn’ branching vessels, and round-to-oval monomorphic tumor cell nuclei (31). Immunohistochemically, the neoplastic cells do not stain for epithelial, melanocytic, or neural markers. Immunohistochemistry showed reactivity for CD34 and BCL-2 in many cases. These tumor cells are also positive for vimentin



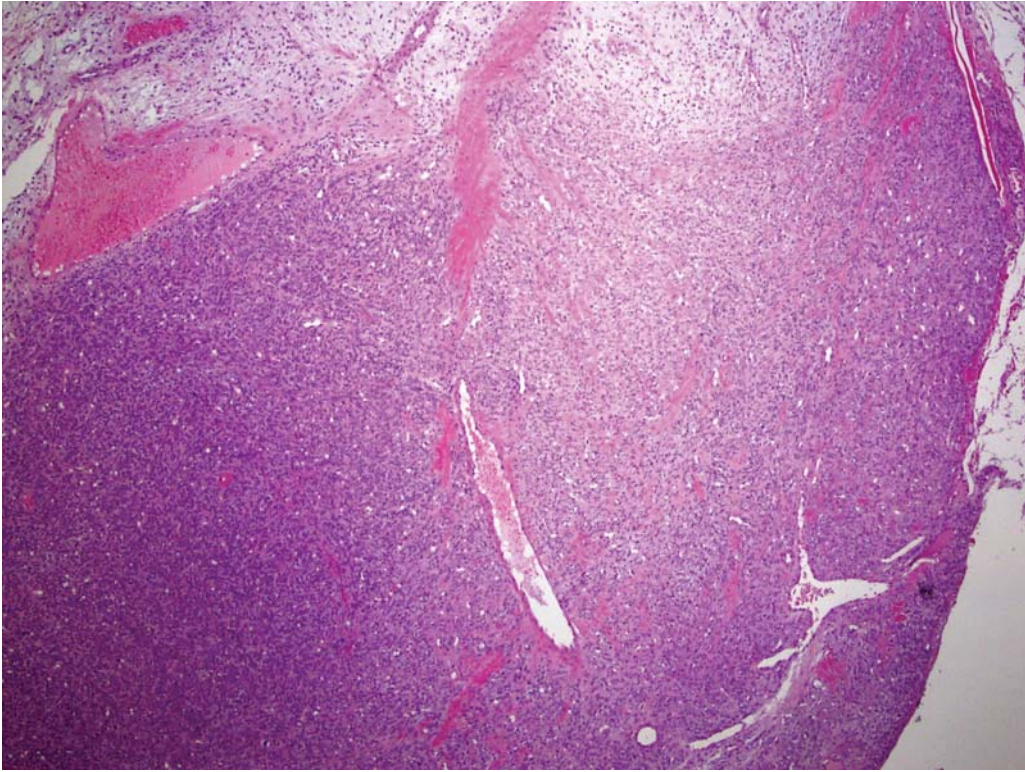


Figure 2. Photomicrograph showing networks of capillary vessels with a staghorn-like shape, whose lumen is lined by flat endothelial cells, surrounded by proliferation of fusiform monomorphic cells, with and without atypia (H&E, original magnification  $\times 200$ ).

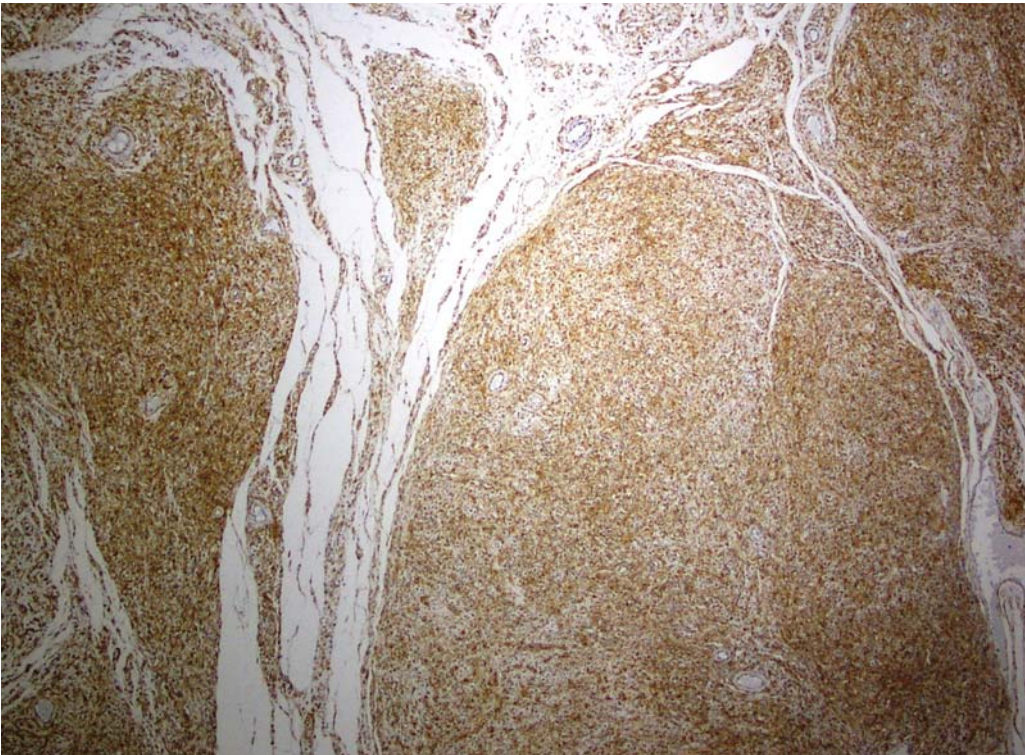


Figure 3. Immunohistochemical staining of tumor cells shows diffuse and strong positivity for CD34 (original magnification  $\times 200$ ).

and SMA stains (32). In our case, immunohistochemistry demonstrated no expression of calponin, CD68KP1, AE1-AE3, SMA, P63 and S-100, but positive expression for CD34, occurring both in spindle cells and vessel walls.

Although the prevalent aspect is that of a benign tumor, these forms characteristically have multilobular or irregular margins (6) and may be associated with adjacent bone erosion or destruction (33). In the present case, the tumor had a well-circumscribed margin with no bone erosion or destruction. These tumors can sometimes behave aggressively. Two potentially malignant cases have been reported in the oral cavity: one occurring in the sublingual gland (23) and the other in the tongue (34). Infiltrative aspects are reported, including infiltration of cranial structures or extensive bone destruction (17, 18, 29, 35-38).

HPCs are classified as benign, borderline, and malignant according to the histological (mitotic activity, cellularity and nuclear atypia) and clinical features (necrosis and tumor size) (38). However, the histological distinction between benign and malignant HPCs may be difficult, because the histologic criteria for prediction of biological behavior are imprecise (39). Criteria of malignancy include large tumor size (>50 mm), disseminated disease at presentation, infiltrative margins, high cellularity, nuclear pleomorphism, areas of tumor necrosis and increased mitotic index (>4 mitoses per 10 high-power fields (HPF) (36). Survival is correlated with the grade, size, and margin status (36). The rate of metastasis from cellular HPC/SFT is low, and most patients do not develop local recurrences. However, in an analysis of 45 cases of cellular HPC/SFT of the head and neck, 40% were found to be locally recurrent (17, 18, 29, 35) and 10% had distant metastases (37). Recurrences can often be very delayed. Enzinger and Smith reported that 7 out of 106 patients had recurrence after a disease-free interval of 3 years (38).

Metastases are known to occur in the lung, bone, liver, regional lymph nodes and pancreas (40). Follow-up examination of recurrent lesions should include a chest radiograph. Because of the rarity and unpredictable biological behavior of these tumors, controversy remains about the best way to manage them. The treatment of choice for HPC/SFT when the tumor is localized and technically resectable is wide surgical resection. The usefulness of adjuvant radiation therapy has not been fully demonstrated, although more recent studies suggest that radiation therapy may be useful in some situations (41). In particular, postoperative radiation therapy has been recommended in cases of incomplete surgical removal. The role of chemotherapy in the treatment of cellular HPC/SFT has not been clearly determined in the case of locally non-operative lesions. Perioperative embolization has been suggested as an adjuvant for decreasing tumor vascularity and size (41). A study by Craven *et al.* (42) encouraged the use of routine angiography and perioperative embolization to reduce intraoperative hemorrhage.

## Conclusion

HPC/SFT is a very rare slow-growing vascular tumor, with variable malignant potential, whose biological behavior is difficult to predict. Treatment of choice is wide surgical resection. Adjuvant radiotherapy and chemotherapy can cause tumor regression and in particular, postoperative radiation therapy has been recommended in cases of incomplete surgical removal. Long-term follow-up is necessary even after radical resection because recurrence or metastasis may be delayed by many years.

## References

- 1 Stout AP and Murray MR: Hemangiopericytoma: a vascular tumor featuring Zimmermann's pericytes. *Ann Surg* 116: 26-33, 1942.
- 2 Zimmermann K: Der feinere Bau der Blutcapillaren. *Z Anat Entwicklungsgesch* 68: 29-109, 1923.
- 3 Klemperer P and Rabin CB: Primary neoplasms of the pleura: a report of five cases. *Arch Pathol* 11: 385-412, 1931.
- 4 Stout AP and Murray MR: Localized pleural mesothelioma. *Arch Pathol* 34: 951-964, 1942.
- 5 Brunnemann RB, Ro JY, Ordenez NG Mooney J, El-Naggar AK and Ayala AG: Extrapleural solitary fibrous tumor: a clinicopathologic study of 24 cases. *Mod Pathol* 12: 1034-1042, 1999.
- 6 Fukunaga M, Naganuma H, Nikaido T Harada T and Ushigome S: Extrapleural solitary fibrous tumor: a report of seven cases. *Mod Pathol* 10: 443-450, 1997.
- 7 Hasegawa T, Matsuno Y, Shimoda T Hasegawa F, Sano T and Hirohashi S: Extrathoracic solitary fibrous tumors: their histological variability and potentially aggressive behavior. *Hum Pathol* 30: 1464-1473, 1999.
- 8 Carneiro SS, Scheithauer BW, Nascimento AG, Hirose T and Davis DH: Solitary fibrous tumor of the meninges: a lesion distinct from fibrous meningioma. A clinicopathologic and immunohistochemical study. *Am J Clin Pathol* 106: 217-224, 1996.
- 9 Tavassoli FA and Eusebi V: Benign soft tissue lesions. In: AFIP Atlas of Tumor Pathology. Tumors of the Mammary Gland, fourth series. Tavassoli FA and Eusebi V (ed.). Fascicle 10. American Registry of Pathology, Washington, pp. 263-290, 2009.
- 10 Guillou L, Fletcher JA, Fletcher CDM and Mandahl N: Extrapleural solitary fibrous tumour and haemangiopericytoma. In: WHO Classification of Tumours of Soft Tissue and Bone. Unni KK, Mertens F, Fletcher CD (ed.). IARC Press, Lyon, pp. 86-90, 2002.
- 11 Perry A, Scheithauer BW and Nascimento AG: The immunophenotypic spectrum of meningeal hemangiopericytoma: a comparison with fibrous meningioma and solitary fibrous tumor of meninges. *Am J Surg Pathol* 21: 1354-1360, 1997.
- 12 Deshmuck NS, Mangham DC, Warfield AT and Watkinson JC: Solitary fibrous tumor of the thyroid gland. *J Laryngol Otol* 115: 940-942, 2001.
- 13 Rodriguez I, Ayala E, Caballero C, De Miguel C, Matias-Guiu X, Cubilla AI and Rosai J: Solitary fibrous tumor of the thyroid gland: report of seven cases. *Am J Surg Pathol* 25: 1424-1428, 2001.
- 14 Safneck JR, Alguacil-Garcia A, Dort JC and Phillips SM: Solitary fibrous tumour: report of two new locations in the upper respiratory tract. *J Laryngol Otol* 107: 252-256, 1993.



- 15 Benlyazid A, Lescanne E, Lefrancq T, Fetisoff F and Beutter P: Solitary fibrous tumour of the larynx: report of a case. *J Laryngol Otol* 112: 286-289, 1998.
- 16 Alobid I, Alos L, Blanch JL, Benitez P, Bernal-Sprekelsen M and Mullol J: Solitary fibrous tumor of the nasal cavity and paranasal sinuses. *Acta Otolaryngol* 123: 71-74, 2003.
- 17 Cassarino DS, Auerbach A and Rushing EJ: Widely invasive solitary fibrous tumor of the sphenoid sinus, cavernous sinus and pituitary fossa. *Ann Diagn Pathol* 7: 16-173, 2003.
- 18 Hayashi S, Kurihara H, Hirato J and Sasaki T: Solitary fibrous tumor of the orbit with extraorbital extension: case report. *Neurosurgery* 49: 1241-1245, 2001.
- 19 Ferrario F, Piantanida R, Spriano G, Cerati M and Maffioli Roselli R: Solitary fibrous tumor of the nasopharynx: *apropos* of a case. *Ann Otolaryngol Chir Cervicofac* 114: 71-75, 1997.
- 20 Ferreira JA and Nascimento AG: Solitary fibrous tumor of the major salivary glands. *Histopathology* 28: 261-264, 1996.
- 21 Guarino M, Giordano F, Pallotti F and Ponzi S: Solitary fibrous tumor of the submandibular gland. *Histopathology* 32: 571-573, 1998.
- 22 Hofmann T, Braun H, Koe W and Beham A: Solitary fibrous tumor of the submandibular gland. *Eur Arch Otorhinolaryngol* 259: 470-473, 2002.
- 23 Ogawa I, Sato S, Kudo Y, Miyauchi M, Sugiyama M, Suei Y and Takata T: Solitary fibrous tumor with malignant potential arising in sublingual gland. *Pathol Int* 53: 40-45, 2003.
- 24 Gunhan O, Yildiz FR, Celasun B, Onder T and Finci R: Solitary fibrous tumor arising from the sublingual gland: report of a case. *J Laryngol Otol* 108: 998-1000, 1994.
- 25 Suárez Roa Mde L, Ruiz Godoy Rivera LM, Meneses García A, Granados-García M and Mosqueda Taylor A: Solitary fibrous tumor of the parotid region. Report of a case and review of the literature. *Med Oral* 9: 82-88, 2004.
- 26 Veltrini VC, Etges A, Magalhaes MH, de Araujo NS and de Araujo VC: Solitary fibrous tumor of the oral mucosa – morphological and immunohistochemical profile in the differential diagnosis with hemangiopericytoma. *Oral Oncol* 39: 420-426, 2003.
- 27 Alawi F, Stratton D and Freedman P: Solitary fibrous tumor of the oral soft tissue. *Am J Surg Pathol* 25: 900-910, 2001.
- 28 Mohammed K, Harbourne G, Walsh M and Royston D: Solitary fibrous tumour of the parotid gland. *J Laryngol Otol* 115: 831-832, 2001.
- 29 Sato J, Asakura K, Yokoyama Y and Satoh M: Solitary fibrous tumor of the parotid gland extending to the parapharyngeal space. *Eur Arch Otorhinolaryngol* 255: 18-21, 1998.
- 30 Rosado-de-Christenson ML, Abbott GF, McAdams HP, Franks TJ and Galvin JR: From the archives of the AFIP: localized fibrous tumor of the pleura. *Radiographics* 23: 759-783, 2002.
- 31 Gold JS, Antonescu CR, Hajdu C, Ferrone CR, Hussain M, Lewis JJ, Brennan MF and Coit DG: Clinicopathologic correlates of solitary fibrous tumor. *Cancer* 94: 1057-1068, 2002.
- 32 Thompson LD, Miettinen M and Wenig BM: Sinonasal-type hemangiopericytoma: a clinicopathologic and immunophenotypic analysis of 104 cases showing perivascular myoid differentiation. *Am J Surg Pathol* 27: 737-749, 2003.
- 33 Cheichi MV, Smirniotopoulos JG and Mena H: Intracranial hemangiopericytomas: MR and CT features. *Am J Neuroradiol* 17: 1365-71, 1996.
- 34 Shnayder Y, Greenfield BJ, Oweity T and Delacure MD: Malignant solitary fibrous tumor of the tongue. *Am J Otolaryngol* 24: 246-249, 2003.
- 35 Polito E, Tosi M, Toti P, Schurfeld K and Caporossi A: Orbital solitary fibrous tumor with aggressive behavior: three cases and review of the literature. *Graefes Arch Clin Exp Ophthalmol* 240: 570-574, 2002.
- 36 Kraus DH, Dubner S, Harrison LB, Strong EW, Hajdu SI, Kher U, Begg C and Brennan MF: Prognostic factors for recurrence and survival in head and neck soft tissue sarcomas. *Cancer* 74(2): 697-702, 1994.
- 37 Walike JW and Bailey BJ: Head and neck hemangiopericytoma. *Arch Otolaryngol* 93(4): 345-53, 1971.
- 38 Enzinger FM and Smith BH: Hemangiopericytoma. An analysis of 106 cases. *Hum Pathol* 7: 61-82, 1976.
- 39 Tsirevelou P, Chlousdis P, Zourou I, Valagiannis D and Skoulakis C: Hemangiopericytoma of the neck. *Head Face Med* 24(6): 23, 2010.
- 40 Aoki S, Sasaki Y, Machida I and Ianioka H: contrast-enhanced MR images in patients with meningiomas: importance of enhancement of the dura adjacent to the tumor. *Am J Neuroradiol* 11: 935-938, 1990.
- 41 Eichhorn JH, Dickersin GR, Bhan AK and Goodman ML: Sinonasal hemangiopericytoma. A reassessment with electron microscopy, immunohistochemistry, and long-term follow-up. *Am J Surg Pathol* 14: 856-866, 1990.
- 42 Craven JP, Quigley TM, Bolen JW and Raker EJ: Current management and clinical outcome of hemangiopericytomas. *Am J Surg* 163(5): 490-493, 1992.

Received December 2, 2010

Revised January 10, 2011

Accepted January 11, 2011