

Expression of Mucin-1, Galectin-1 and Galectin-3 in Human Leiomyosarcoma in Comparison to Leiomyoma and Myometrium

TOBIAS WEISSENBACHER¹, CHRISTINA KUHN¹, DORIS MAYR², ROMAN PAVLIK¹, KLAUS FRIESE,
CHRISTOPH SCHOLZ¹, UDO JESCHKE¹, NINA DITSCH³ and DARIUS DIAN¹

Ludwig Maximilians University Munich:

¹Department of Obstetrics and Gynecology, Maistrasse 11, 80337 Munich, Germany;

²Department of Pathology, Thalkirchner Str. 7, 80337 Munich, Germany;

³Department of Obstetrics and Gynecology, Marchioninistr 15, 81373 Munich, Germany

Abstract. *Background:* The potential mechanism of malignant transformation from leiomyoma to leiomyosarcoma is still debated. The aim was the evaluation of expression patterns of mucin-1 (MUC1) (MUC1 VU-4-H5), galectin-1 (Gal-1) and galectin-3 (Gal-3) in human myometrium and leiomyoma and in comparison to leiomyosarcoma. *Materials and Methods:* Myometrium, leiomyoma and leiomyosarcoma tissues were obtained from 79 patients. Samples were analyzed regarding the expression of MUC1, Gal-1 and Gal-3 by immunohistochemical staining of paraffin-embedded material. *Results:* The expression of MUC1 (VU4-H5) was up-regulated in leiomyoma ($p=0.065$) and leiomyosarcoma ($p=0.039$) as compared to the myometrium. In contrast, there were no significant differences in expression of Gal-3 in the tissues from the myometrium, myoma and leiomyosarcoma. Concerning Gal-1 expression, the differences were not significant comparing myometrium and leiomyosarcoma ($p=0.277$). Myoma had elevated levels of Gal-1 compared to myometrium ($p=0.007$) and leiomyosarcoma ($p<0.0001$). *Conclusion:* MUC1 and Gal-1 might be useful for evaluating the potential of leiomyoma to transform into leiomyosarcoma and, therefore, help in risk-adapted consultation and adjusted treatment.

Uterine leiomyomas are the most common pelvic tumour of women of reproductive age (1, 2). They are the major cause

Correspondence to: Dr. Tobias Weissenbacher, Ludwig-Maximilian-University of Munich, Department of Obstetrics and Gynecology, Maistrasse 11, 80337 Munich, Germany. Tel: +49 8951604111, Fax: +49 8951604580, e-mail: tobias.weissenbacher@med.uni-muenchen.de

Key Words: Mucin-1, galectin-1, galectin-3, leiomyosarcoma, leiomyoma, myometrium.

of hysterectomy in the United states (1). Differences occur by race and age, and black women have a greater burden compared to white women regarding fibroids and their symptoms (3-5). It is still not known if leiomyosarcomas can arise from pre-existing leiomyomas or if they develop *de novo* (6). Malignant transformation of leiomyoma into leiomyosarcoma is still debated in the literature and several studies have focused on that topic (6-8).

Mittal *et al.* demonstrated, that leiomyosarcomas can arise from leiomyoma-like areas (9). Histopathological characterization is often challenging and differentiation between leiomyoma, myoma with pseudosarcomatous features and leiomyosarcoma can be exceedingly difficult (10).

Epithelial mucin-1 (MUC1) is a complex glycoprotein. The mature molecule is anchored within the cell surface by transmembrane proteins, however, most of the mucin is expressed extracellularly (11). Numerous functions are proposed for MUC1. It has a potential role in tumour progression and metastasis by changing expression in the basolateral front. Antiadhesive effects in tumour cells seem to be mediated by MUC1. Furthermore, it is responsible for surveillance by the host immune response. Mucin-expressing cells have been demonstrated to be generally resistant to natural killer cells and cytotoxic T-cells (12). In addition, MUC1 is associated with tyrosine kinase receptor activity and is involved in cell transduction processes (13). Price *et al.* (11) mapped 56 monoclonal reactive antibodies against MUC1 mucin. Regarding the specificity of the antibody clone VU-4-H5 the core reactivity is ambiguous (14).

The overexpression of MUC1 and its relationship to several types of cancer has already been demonstrated (15). The clones DF3 (CA15-3), VU-4-H5 and Panko-Mab of MUC1 were examined by Dian *et al.* and breast cancer. Panko-Mab showed significant differences in staining in breast cancer patients with oestrogen negative carcinomas compared to

Table I. *Antibodies used in the study.*

Antibody	Clone	Isotype	Concentration	Source
Galectin-1	AF1152	Goat IgG	1.4 µg/ml	R&D Systems, Wiesbaden, Germany
Galectin-3	9C4	Mouse IgG	2.0 µg/ml	Novocastra, Wetzlar, Germany
Mucin-1	VU-4-H5	Mouse IgG1	6.8 µg/ml	Zymed, San Francisco, USA

positive carcinomas. While the DF3 staining results were not significant, for the VU-4-H5 antibody, a significant correlation with lymph node involvement and grading, (staining increased from G1 to G3 carcinomas) was found (16).

Galectin-1 (Gal-1) belongs to the family of carbohydrate-binding proteins, with affinity for beta-galactosides. Similar to MUC1, both intracellular and extracellular activity is described and the biological activity has a wide range. Gal-1 regulates immune responses such as T-cell homeostasis and survival, T-cell immune disorders, inflammation and allergies, as well as host-pathogen interactions (17), and is also a mediator in malignant tumour progression (18).

Galectin-3 (Gal-3), like Gal-1, belongs to the family of beta-galactoside-binding proteins (19). Additionally, Gal-3 binds to the Thomsen-Friedenreich (TF) antigen (Galbeta1-3GalNAc), which has been demonstrated to be the glycosylated form of MUC1 (20-22). Biological regulation, such as cell adhesion, cell growth, apoptosis, tumour progression and metastatic potential, is attributed to Gal-3. Up-regulated expression of Gal-3 is associated with tumour progression and neoplastic potential. The inhibition of apoptosis by Gal-3 seems to be related to an inhibition of cytochrome *c* release and caspase activation (23, 24).

Galectins influence immune and inflammatory responses and as a consequence facilitate tumour subversion of immune surveillance. Recent studies have focused on galectins and demonstrated their important role in neoplastic transformations and tumour progression (25).

The aim of this study was to evaluate any individual differences in staining of these glycoproteins and, as a consequence, variation in the potential of leiomyomas to transform malignantly. Accordingly, the expression of MUC1 (VU-4-H5), Gal-1 and Gal-3 was examined immunohistochemically in human myometrium, in uterine myoma and in leiomyosarcoma.

Materials and Methods

All the study subjects had complaints due to uterine myomas, mainly dysmenorrhoea, menorrhagia, metrorrhagia, hypermenorrhoea, pollacisuria and/or painful pressure in the abdomen and were attending consultations in the Department of Obstetrics and Gynecology in the University Hospital, Munich. All the patients were interviewed regarding history of myomas, pregnancies, modality of birth and past or present hormone use. Patients who could not give

informed consent were excluded. To avoid ambiguous results due to differences of uterine malignancies, leiomyosarcomas were focused upon and other histological types, such as adenocarcinomas, were excluded. Forty-four women with uterine myomas and 35 with leiomyosarcomas were included in the study. The Institutional Review Board of the Ludwig Maximilians University Munich, Germany, approved the study and all the patients gave informed consent.

The 44 uterine myoma patients received endoscopic myomectomy and the 35 leiomyosarcoma patients received hysterectomy and further oncological surgery according to age and extension of disease. Two tissue samples from each myoma were examined, totalling 88 samples for immunohistochemical investigation and within the myomectomy, 30 myometrial tissues were taken and also investigated.

The immunohistochemistry was performed using a combination of pressure cooker heating and the standard streptavidin-biotin-peroxidase complex using the mouse IgG-Vectastain Elite ABC kit (Vector Laboratories, Burlingame, CA, USA). The mouse monoclonal antibodies used for these experiments are listed in Table I.

Paraffin-fixed tissue sections were dewaxed using xylol for 15 min, rehydrated in an descending series of alcohol (100%, 96% and 70%), and subjected to epitope retrieval for 10 min in a pressure cooker using sodium citrate buffer (pH 6.0) containing 0.1 M citric acid and 0.1 M sodium citrate in distilled water. After cooling, the sections were washed twice in PBS. Endogenous peroxidase activity was quenched by immersion in 3% hydrogen peroxide (Merck, Darmstadt, Germany) in methanol for 20 min. Non-specific binding of the primary antibodies was blocked by incubating the sections with diluted normal serum (10 ml PBS containing 150 SI horse serum; Vector Laboratories) for 20 min at room temperature. The sections were then incubated at room temperature for 60 min with the primary antibodies. After washing with PBS, the sections were incubated in diluted biotinylated serum (10 ml PBS containing 50 IL horse serum; Vector Laboratories) for 30 min at room temperature. After incubation with the avidin-biotin peroxidase complex (diluted in 10 ml PBS; Vector Laboratories) for 30 min and repeated washing steps with PBS, visualisation was performed with substrate and the chromagen 3,3'-diaminobenzidine (DAB; Dako, Glostrup, Denmark) for 8-10 min. The sections were counterstained with Mayer's acidic haematoxylin and dehydrated in an ascending series of alcohol (50-98%). After xylol treatment, the sections were covered. Negative controls were performed by replacing the primary antibody with normal horse serum. Immunohistochemical staining was performed using an appropriate positive control. Positive cells showed a brownish colour and negative controls, as well as unstained cells, were blue.

The intensity and distribution patterns of specific immunohistochemical staining were evaluated using the semi-quantitative International Remmele Score (IRS), as described elsewhere, to assess the expression pattern of other molecules, such as steroid receptors, glycodeilin and MUC1 (26-28). The IRS score was calculated by multiplication of the optical staining intensity (graded as 0=no, 1=weak, 2=moderate and 3=strong staining) and the percentage of

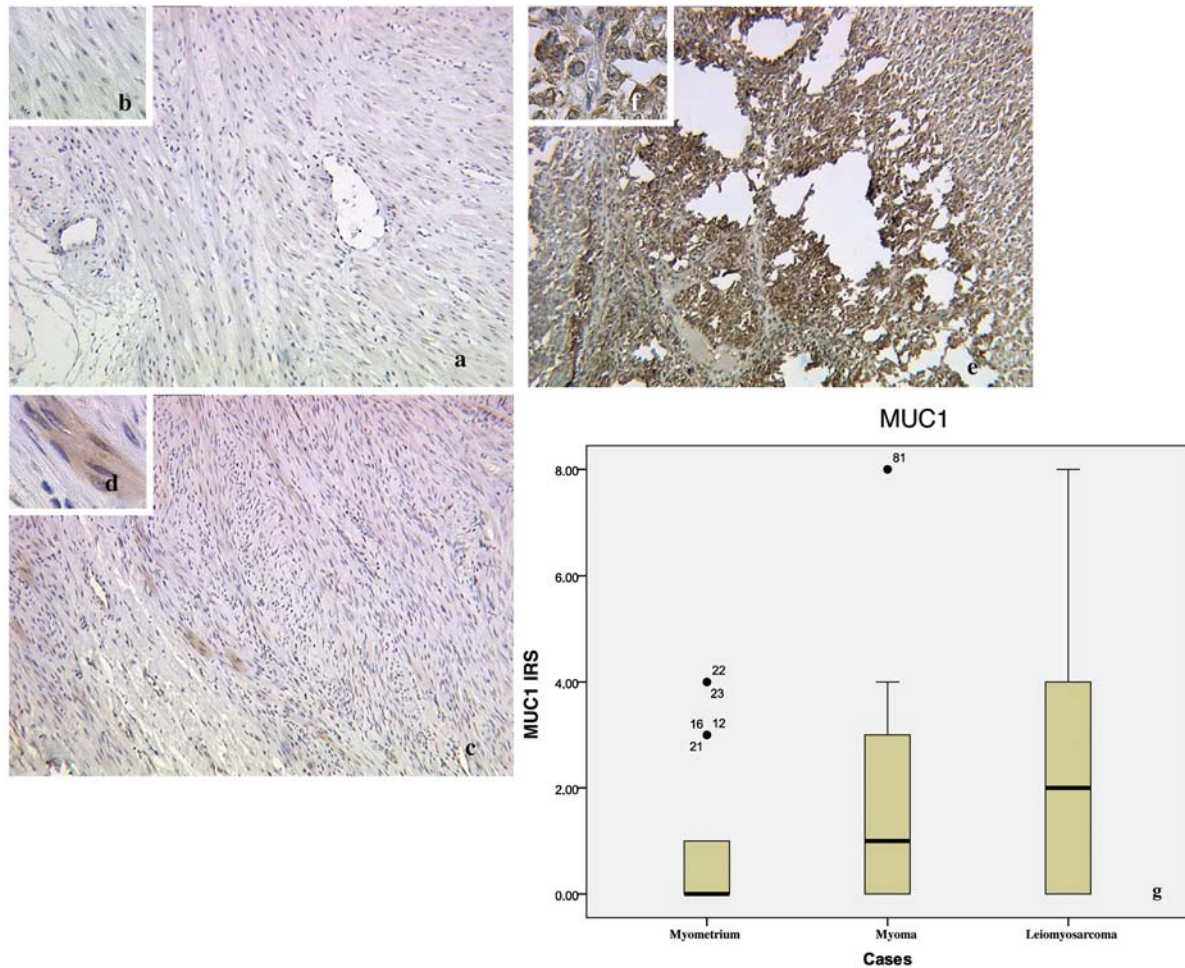


Figure 1. MUC1 (VU-4-H5) expression in myometrium (a, b), myoma (c, d) and leiomyosarcoma (e, f); magnification $\times 10$ (a, c, e) and $\times 40$ (b, d, f). Semi-quantitative evaluation of staining results (IRS score) is presented in box plots (g). The boxes represent the range between the 25th and 75th percentiles, with a horizontal line at the median. The bars delineate the 5th and 95th percentiles. The circles indicate values more than 1.5 box lengths from the 75th percentile.

positively stained cells (0=no staining, 1= $<10\%$ of cells, 2=11-50% of cells, 3=51-80% of cells and 4= $>81\%$ of cells stained). The slides were examined by two independent observers. Sections were examined using a charge coupled device (CCD) colour camera with a special prism block to separate the colors and three CCDs for the red, green and blue color planes (JVC, Victor Company of Japan, Yokohama, Japan) and a Leitz (Wetzlar, Germany) microscope. The results were evaluated using the non-parametric Mann-Whitney *U* test, and the non-parametric Spearman correlation coefficient was used for estimating correlations between MUC1, Gal-3, and Gal-1 (SPSS; Chigaco, IL, USA). Significance was assumed at $p < 0.05$.

Results

MUC1 (VU-4-H5). In the myometrial tissue samples, as expected, no expression of MUC1 (VU-4-H5) was demonstrated (Figure 1). The leiomyosarcomas (Figure 1e, f) showed significantly higher MUC1 expression compared

to the myometria (Figure 1a,1b $p=0.039$). The myomas (Figure 1c, d) revealed up-regulated MUC1 expression compared to the myometria. However, this result was not significant ($p=0.065$). MUC1 expression was high in both leiomyosarcomas and myomas, but the differences were not significant ($p=0.418$). A quantitative summary of the staining results is presented in Figure 1g.

Gal-3. There were no significant differences when comparing all three groups for Gal-3 tissue expression, as demonstrated in Figure 2a-f. A quantitative summary of this staining result is presented in Figure 2g.

Gal-1. Gal-1 demonstrated significantly lower immunohistochemical staining in tissues of the leiomyosarcomas (Figure 3e, f) compared to the myomas (Figure 3c, d) ($p < 0.0001$).

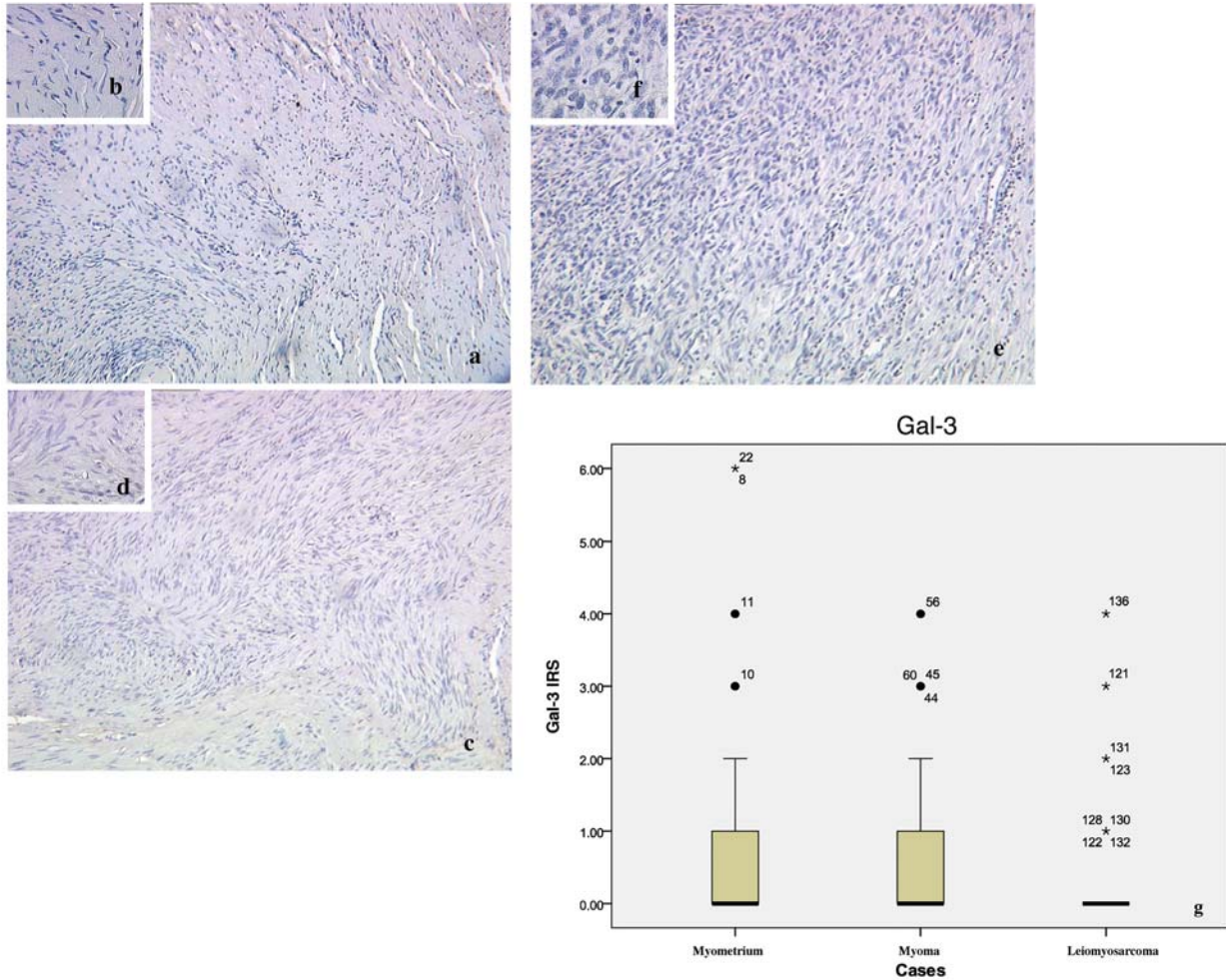


Figure 2. Gal-3 expression in myometrium (a, b), myoma (c, d) and leiomyosarcoma (e, f); magnification $\times 10$ (a, c, e) and $\times 40$ (b, d, f). Semiquantitative evaluation of staining results (IRS score) is presented in box plots (g). The boxes represent the range between the 25th and 75th percentiles with a horizontal line at the median. The bars delineate the 5th and 95th percentiles. The circles indicate values more than 1.5 box lengths from the 75th percentile.

Similar to this result, the myometria (Figure 3a, b) also showed lower staining compared to the myomas ($p=0.007$). No significant differences in staining between the myometria and the leiomyosarcomas was found ($p=0.277$). A quantitative summary of this staining result is presented in Figure 3g.

Discussion

PEP-19, a neurone-specific protein PEP-19 (Purkinje cell protein) seems to be involved in the pathogenesis of leiomyoma. PEP-19 expression was investigated for a series of human leiomyoma, as well as normal myometrium and leiomyosarcoma, and was demonstrated to be involved in leiomyoma pathogenesis (2).

Additionally, angiogenetic factors, such as vascular endothelial growth factor (VEGF) and the expression of the

VEGF receptors, EGF-R and Ki-67 were investigated in leiomyomas and leiomyosarcomas (29, 30). Accordingly, angiogenic growth factors seem to play an important role in the induction of malignant transformation of leiomyosarcomas.

Fascin, an actin bundling protein was recently described to be related to gastric carcinoma (31) and even breast cancer (31, 32). This protein regulates cytoskeletal structures and maintains cell adhesion. In 2009, Kefeli *et al.* described elevated fascin expression in leiomyosarcoma compared to leiomyoma, leiomyoma variants and uterine smooth muscle tumour of uncertain malignant potential (33). Possibly, varied mechanisms of cell adhesion might have been implicated in development of leiomyosarcoma.

In the present study, MUC1 expression was up-regulated in leiomyosarcoma and also in leiomyoma compared to the

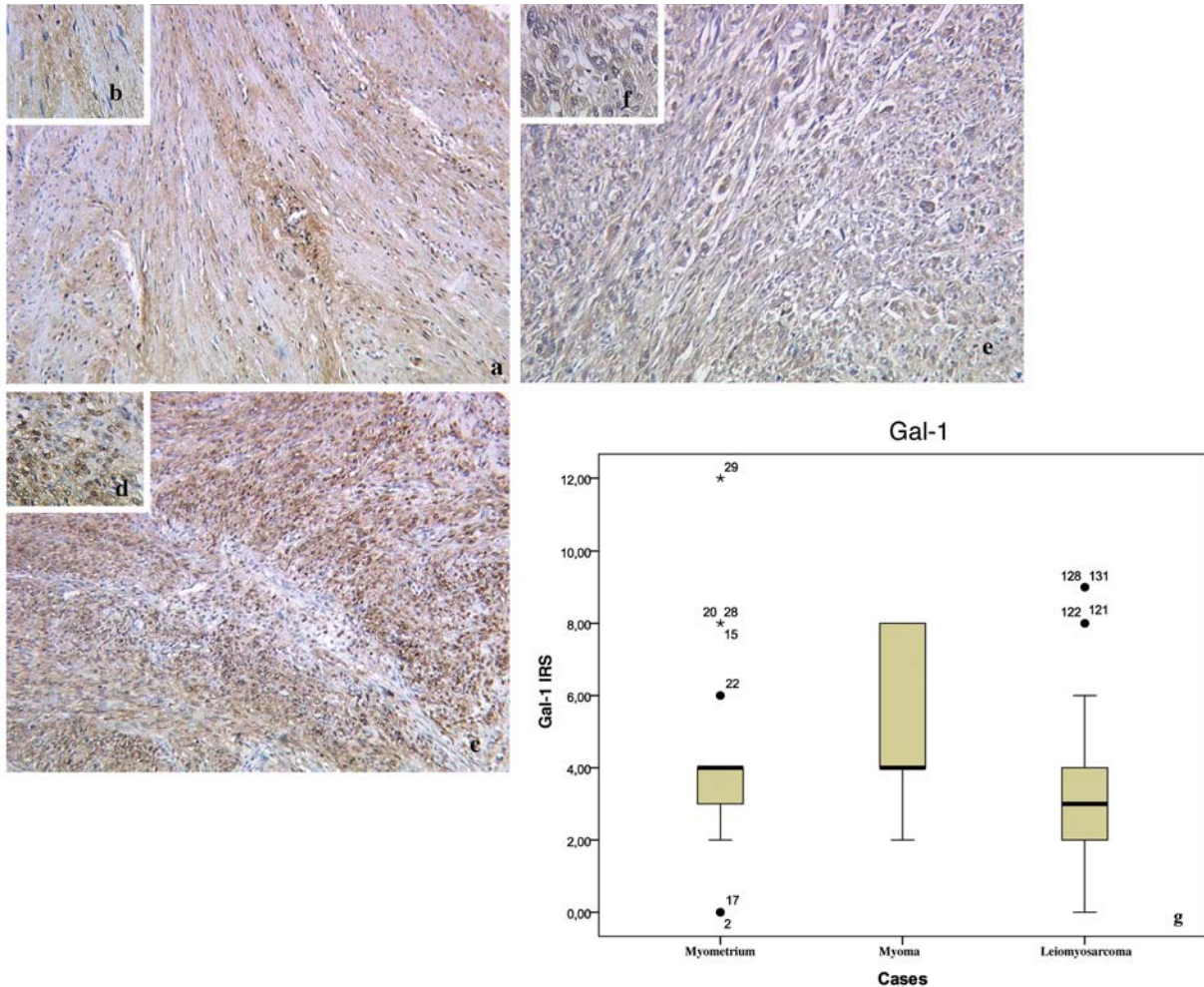


Figure 3. *Gal-1* expression in myometrium (a, b), myoma (c, d) and leiomyosarcoma (e, f); magnification $\times 10$ (a, c, e) and $\times 40$ (b, d, f). Semiquantitative evaluation of staining results (IRS score) is presented in box plots (g). The boxes represent the range between the 25th and 75th percentiles with a horizontal line at the median. The bars delineate the 5th and 95th percentiles. The circles indicate values more than 1.5 box lengths from the 75th percentile.

myometrium samples. Myometrial expression of MUC1 was negative with a few exceptions due to the nature of MUC1 as a glandular marker. Interestingly, only VU-4-H5 out of three anti-MUC1 (16) antibodies tested (PankoMab and DF3) showed positive staining in this tissue. Mylonas *et al.* also found up-regulated expression of MUC1 in endometrioid adenocarcinoma (15). However, tissues of leiomyosarcomas (mesenchymal tumours) and adenocarcinomas (epithelial tumours) are not comparable regarding MUC1 expression. MUC1 is also overexpressed in ovarian cancer and MUC1 signalling pathways have been shown by Hu *et al.* to be responsible for malignant transformation and metastasis (34). Particularly for the VU-4-H5 epitope, a correlation of lymph node involvement and grading and increased staining intensity has been shown in patients with breast cancer (16).

However, MUC1 expression in leiomyomas compared to leiomyosarcomas has not previously been investigated.

VU-4-H5 is directed against the core peptide of MUC1 and stains positively only when the MUC1 molecule is underglycosylated, presenting simpler and fewer carbohydrate chains (35). Incomplete glycosylation, abnormal distribution and ectopic expression of mucins seem to be characteristics of malignancy (36).

In the present study, Gal-3 expression seemed to be down-regulated in the patients with leiomyosarcoma, however, not significantly so when compared to myometrium and to leiomyoma. Since malignant transformation (25) and tumour progression, cell growth and apoptosis (23, 24) are regulated by Gal-3, a correlation of Gal-3 with tumour progression and metastasis has to be assumed.

Tsuboi *et al.* found an association between reduced expression of Gal-3 and invasion and metastasis of colorectal cancer (37), which was consistent with the present trend in leiomyosarcoma. Additionally, interactions between Gal-3 and MUC1 seem to play an important role. Recombinant Gal-3 has been demonstrated to interact with MUC1 *via* the Thomsen-Friedenreich antigen (21, 22).

Strong binding of Gal-1 in stage III/IV endometrioid adenocarcinomas and an association with lymphangiosis have been reported (15). The present study found the highest Gal-1 expression to be in the fibroid tissues and similar expression patterns in myometrium and leiomyosarcoma, but adenocarcinomas, which might have different patterns of galectin expression, were not examined.

Gal-1 expression has been demonstrated to be related to tumour progression and must also be considered regarding dissemination of tumour cells into surrounding normal tissues and tumour immune escape (17). Such findings were confirmed by Rabinovich *et al.* who emphasized galectins as potential targets of anticancer drugs (18). The present results did not show any up-regulated Gal-1 expression in the leiomyosarcomas, on the contrary, Gal-1 expression was highest in the leiomyomas.

In conclusion, VU-4-H5 is an anti-MUC1 antibody with diagnostic potential, showing increasing expression from myometrium to myoma and leiomyosarcoma. Gal-1 expression might be a potential option in the analysis of benign epithelial tumours and MUC1(VU-4-H5) in combination with Gal-1 may be an option for assessing the potential for malignant transformation of myoma.

Acknowledgements

We would like to thank Dr. Steven S. Witkin (Weill Cornell Medical College, New York, USA) for his help with the manuscript.

References

- Hodge JC and Morton CC: Genetic heterogeneity among uterine leiomyomata: insights into malignant progression. *Hum Mol Genet 16 Spec No 1*: R7-13, 2007.
- Kanamori T, Takakura K, Mandai M *et al*: PEP-19 overexpression in human uterine leiomyoma. *Mol Hum Reprod 9*: 709-717, 2003.
- Marshall LM, Spiegelman D, Barbieri RL *et al*: Variation in the incidence of uterine leiomyoma among premenopausal women by age and race. *Obstet Gynecol 90*: 967-973, 1997.
- Peddada SD, Laughlin SK, Miner K *et al*: Growth of uterine leiomyomata among premenopausal black and white women. *Proc Natl Acad Sci USA 105*: 19887-19892, 2008.
- Weiss G, Noorhasan D, Schott LL, Powell L, Randolph JF Jr. and Johnston JM: Racial differences in women who have a hysterectomy for benign conditions. *Womens Health Issues 19*: 202-210, 2009.
- Schwartz PE and Kelly MG: Malignant transformation of myomas: Myth or reality? *Obstet Gynecol Clin North Am 33*: 183-198, xii, 2006.
- Indraccolo U, Luchetti G and Indraccolo SR: Malignant transformation of uterine leiomyomata. *Eur J Gynaecol Oncol 29*: 543-544, 2008.
- Jatoi N: Leiomyosarcoma: a rare malignant change in a leiomyoma. *J Coll Physicians Surg Pak 13*: 106-107, 2003.
- Mittal KR, Chen F, Wei JJ *et al*: Molecular and immunohistochemical evidence for the origin of uterine leiomyosarcomas from associated leiomyoma and symplastic leiomyoma-like areas. *Mod Pathol 22*: 1303-1311, 2009
- Watanabe K and Suzuki T: Uterine leiomyoma *versus* leiomyosarcoma: a new attempt at differential diagnosis based on their cellular characteristics. *Histopathology 48*: 563-568, 2006.
- Price MR, Rye PD, Petrakou E *et al*: Summary report on the ISOBM TD-4 Workshop: analysis of 56 monoclonal antibodies against the MUC1 mucin. San Diego, Calif., November 17-23, 1996. *Tumour Biol 19(Suppl 1)*: 1-20, 1998.
- Hanisch FG and Muller S: MUC1: the polymorphic appearance of a human mucin. *Glycobiology 10*: 439-449, 2000.
- Mukherjee P, Tinder TL, Basu GD and Gendler SJ: MUC1 (CD227) interacts with lck tyrosine kinase in Jurkat lymphoma cells and normal T cells. *J Leukoc Biol 77*: 90-99, 2005.
- Cao Y, Karsten U and Hilgers J: Immunohistochemical characterization of a panel of 56 antibodies with normal human small intestine, colon, and breast tissues. *Tumour Biol 19(Suppl 1)*: 88-99, 1998.
- Mylonas I, Mayr D, Walzel H *et al*: Mucin 1, Thomsen-Friedenreich expression and galectin-1 binding in endometrioid adenocarcinoma: an immunohistochemical analysis. *Anticancer Res 27*: 1975-1980, 2007.
- Dian D, Janni W, Kuhn C *et al*: Evaluation of a novel anti-mucin 1 (MUC1) antibody (PankoMab) as a potential diagnostic tool in human ductal breast cancer; comparison with two established antibodies. *Onkologie 32*: 238-244, 2008.
- Camby I, Le Mercier M, Lefranc F and Kiss R: Galectin-1: a small protein with major functions. *Glycobiology 16*: 137R-157R, 2006.
- Rabinovich GA: Galectin-1 as a potential cancer target. *Br J Cancer 92*: 1188-1192, 2005.
- Jeschke U, Mayr D, Schiessl B *et al*: Expression of galectin-1, -3 (gal-1, gal-3) and the Thomsen-Friedenreich (TF) antigen in normal, IUGR, preeclamptic and HELLP placentas. *Placenta 28*: 1165-1173, 2007.
- Jeschke U, Walzel H, Mylonas I *et al*: The human endometrium expresses the glycoprotein mucin-1 and shows positive correlation for Thomsen-Friedenreich epitope expression and galectin-1 binding. *J Histochem Cytochem 57*: 871-881, 2009.
- Yu LG, Andrews N, Zhao Q *et al*: Galectin-3 interaction with Thomsen-Friedenreich disaccharide on cancer-associated MUC1 causes increased cancer cell endothelial adhesion. *J Biol Chem 282*: 773-781, 2007.
- Zhao Q, Guo X, Nash GB *et al*: Circulating galectin-3 promotes metastasis by modifying MUC1 localization on cancer cell surface. *Cancer Res 69*: 6799-6806, 2009.
- Moon BK, Lee YJ, Battle P, Jessup JM, Raz A and Kim HR: Galectin-3 protects human breast carcinoma cells against nitric oxide-induced apoptosis: implication of galectin-3 function during metastasis. *Am J Pathol 159*: 1055-1060, 2001.
- Yang RY, Hsu DK and Liu FT: Expression of galectin-3 modulates T-cell growth and apoptosis. *Proc Natl Acad Sci USA 93*: 6737-6742, 1996.

- 25 Liu FT and Rabinovich GA: Galectins as modulators of tumour progression. *Nat Rev Cancer* 5: 29-41, 2005.
- 26 Jeschke U, Kuhn C, Mylonas I *et al*: Development and characterization of monoclonal antibodies for the immunohistochemical detection of glycodefin A in decidual, endometrial and gynaecological tumour tissues. *Histopathology* 48: 394-406, 2006.
- 27 Jeschke U, Mylonas I, Shabani N *et al*: Expression of sialyl lewis X, sialyl Lewis A, E-cadherin and cathepsin-D in human breast cancer: immunohistochemical analysis in mammary carcinoma *in situ*, invasive carcinomas and their lymph node metastasis. *Anticancer Res* 25: 1615-1622, 2005.
- 28 Mylonas I, Makovitzky J, Jeschke U, Briese V, Friese K and Gerber B: Expression of Her2/neu, steroid receptors (ER and PR), Ki67 and p53 in invasive mammary ductal carcinoma associated with ductal carcinoma *in situ* (DCIS) *versus* invasive breast cancer alone. *Anticancer Res* 25: 1719-1723, 2005.
- 29 Mayerhofer K, Lozanov P, Bodner K, Bodner-Adler B, Kimberger O and Czerwenka K: Ki-67 expression in patients with uterine leiomyomas, uterine smooth muscle tumors of uncertain malignant potential (STUMP) and uterine leiomyosarcomas (LMS). *Acta Obstet Gynecol Scand* 83: 1085-1088, 2004.
- 30 Sanci M, Dikis C, Inan S, Turkoz E, Dicle N and Ispahi C: Immunolocalization of VEGF, VEGF receptors, EGF-R and Ki-67 in leiomyoma, cellular leiomyoma and leiomyosarcoma. *Acta Histochem*, 2010.
- 31 Hashimoto Y, Shimada Y, Kawamura J, Yamasaki S and Imamura M: The prognostic relevance of fascin expression in human gastric carcinoma. *Oncology* 67: 262-270, 2004.
- 32 Rodriguez-Pinilla SM, Sarrio D, Honrado E *et al*: Prognostic significance of basal-like phenotype and fascin expression in node-negative invasive breast carcinomas. *Clin Cancer Res* 12: 1533-1539, 2006.
- 33 Kefeli M, Yildiz L, Kaya FC, Aydin O and Kandemir B: Fascin expression in uterine smooth muscle tumors. *Int J Gynecol Pathol* 28: 328-333, 2009.
- 34 Hu XF, Yang E, Li J and Xing PX: MUC1 cytoplasmic tail: a potential therapeutic target for ovarian carcinoma. *Expert Rev Anticancer Ther* 6: 1261-1271, 2006.
- 35 Mommers EC, Leonhart AM, von Mensdorff-Pouilly S *et al*: Aberrant expression of MUC1 mucin in ductal hyperplasia and ductal carcinoma *in situ* of the breast. *Int J Cancer* 84: 466-469, 1999.
- 36 Cao Y, Blohm D, Ghadimi BM, Stosiek P, Xing PX and Karsten U: Mucins (MUC1 and MUC3) of gastrointestinal and breast epithelia reveal different and heterogeneous tumor-associated aberrations in glycosylation. *J Histochem Cytochem* 45: 1547-1557, 1997.
- 37 Tsuboi K, Shimura T, Masuda N *et al*: Galectin-3 expression in colorectal cancer: relation to invasion and metastasis. *Anticancer Res* 27: 2289-2296, 2007.

Received November 22, 2010

Revised January 27, 2011

Accepted January 27, 2011