

Repeated Localized Treatment for Extranodal Marginal Zone Lymphoma – Case Report and Review of Literature

CHRISTINE E. SCHÖNKNECHT¹, CARSTEN NIEDER^{2,3}, MICHAEL MOLLS¹ and SABRINA T. ASTNER¹

¹*Klinik und Poliklinik für Strahlentherapie und Radiologische Onkologie, Klinikum rechts der Isar, Technische Universität München, Munich, Germany;*

²*Department of Oncology and Palliative Medicine, Nordland Hospital, Bodø, Norway;*

³*Institute of Clinical Medicine, Faculty of Health Sciences, University of Tromsø, Tromsø, Norway*

Abstract. *Background: Marginal zone lymphomas (MZL) are indolent B-cell lymphomas with variable symptoms related to lymphoma location. Patients with such lymphoma often have an excellent prognosis. Concerning treatment, no large prospective trials have been published, making therapeutic decisions difficult. Case Report: The Authors present the case of a female patient with an MZL which was slowly progressive throughout 9 years after diagnosis. Only clearly progressive lymphoma manifestations were treated with moderate-dose radiotherapy (total doses between 30 and 40 Gy). All irradiated lesions showed a complete regression and relapses only occurred at non-irradiated sites. The performance status remains very good. Conclusion: Moderate-dose radiotherapy is a safe and effective treatment to achieve local tumor control in patients with MZL.*

Marginal zone lymphomas (MZL) are indolent B-cell lymphomas that originate from the marginal zone of B-cell follicles. Those can be found in lymph nodes, mucosal lymphoid tissues and in the spleen (1). For several subtypes, the initiation of disease appears to be a consequence of chronic infection or inflammation. Depending on the site of lymphoma involvement, MZL are categorized into three subtypes: (i) nodal MZL, (ii) splenic MZL and (iii) extranodal MZL of mucosa-associated lymphoid tissue (MALT lymphoma). Thirty percent of MALT lymphomas are gastric, 70% are non-gastric (15). Common presenting sites of non-gastric MALT lymphomas include the parotid and minor salivary glands, orbit, lungs, skin,

intestinal tract, thyroid and breasts. MZL are a relatively rare form of non-Hodgkin's lymphoma, affecting patients with a median age of 56-62 years at diagnosis. The clinical presentation is highly variable with symptoms related to lymphoma location. Regarding treatment, no large-scale prospective studies have been published, making therapeutic decisions difficult and often based on suboptimal levels of evidence. While MALT and splenic MZL are indolent diseases and are associated with long survival, nodal MZL is a more aggressive disease and has lower survival rates (1, 3, 4).

Case Report

In October 2001, a 58-year-old female patient was referred for postoperative radiation therapy of non-Hodgkin's lymphoma of the breast, stage IAE in the right upper outer quadrant protruding into the axilla. The patient had an excellent performance status with a Karnofsky Performance Score (KPS) of 100%. In her medical history, noteworthy points were hyperthyroidism and elevated blood pressure, her family history was unremarkable for lymphoma. The final histological examination was performed by the National Reference Center for lymph node pathology at the University of Würzburg, Germany. A final diagnosis of extranodal marginal zone B-cell lymphoma (MALT lymphoma) was made. Computed tomography (CT), positron-emission tomography (PET) and a bone marrow biopsy did not reveal any evidence of further lymphoma manifestations. Radiation therapy aimed at treating the right breast, as well as the axillary, supra- and infraclavicular lymph nodes, and was delivered to a total dose of 39.6 Gy in single doses of 1.8 Gy, using tangential and static 6-MV photon beams according to commonly accepted treatment regimes for MZL (5-7). At the end of treatment, a slight radiodermatitis was observed.

In September 2002, a subcutaneous nodule of the left upper arm developed and was removed surgically. The histological examination revealed a new manifestation of the known MZL. There was no evidence of further lymphoma

Correspondence to: Dr. Sabrina T. Astner, Klinikum rechts der Isar, Klinik und Poliklinik für Strahlentherapie und Radiologische Onkologie, Technische Universität München, Ismaningerstr. 22, 81675 Munich, Germany. Tel: +49 8941404502, Fax: +49 8941404300, e-mail: sabrina.astner@lrz.tu-muenchen.de

Key Words: B-Cell lymphoma, marginal zone lymphoma, radiation therapy, local tumor control.

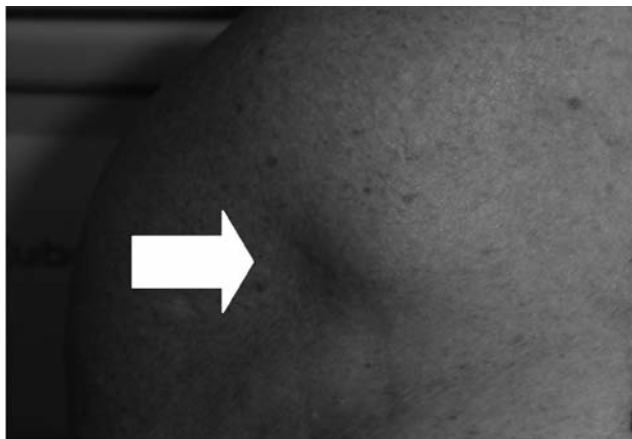


Figure 1. Subcutaneous lymphoma manifestation. Indolent, firm nodule of the trunk.

manifestation on CT and PET scans. Since local residual tumor could not be ruled out, the patient received radiotherapy to the left upper arm and left axilla using opposing fields. Treatment was performed with single daily fractions of 1.8 Gy to a total dose of 36 Gy, using 6-MV photons. Despite a slight radiodermatitis, irradiation was tolerated well, no lymphedema occurred.

At the end of 2004, a dissemination of disease occurred. Magnetic resonance imaging (MRI) showed pathologic cervical lymph nodes, an infiltration of the right parotid gland, and subcutaneous lymphoma manifestation of the left cheek, as well as multiple lesions in the subcutaneous tissue of the trunk. Clinical examination revealed firm, indolent nodules, 1-3 cm in diameter (Figure 1). The performance status was still excellent. In June 2005, at clinical progression, radiotherapy was performed with radiation fields including palpable occipital and cervical (right hand side) lymph nodes, the right parotid gland and the left cheek using 9- respectively 12-MV electron fields to a total dose of 30 Gy (single dose of 2.5 Gy). In the subsequent two years, further progress of non-irradiated cervical lymph nodes occurred. Therefore in July 2007, cervical lymph nodes (left hand side) were irradiated with a total dose of 30 Gy (single dose of 2.5 Gy) following CT-based three-dimensional treatment planning using 6-MV photons. The follow up MRI in January 2008 showed complete regression of the irradiated cervical lymphoma manifestations.

In April 2007, for the first time, pathologic disease of the intra-abdominal lymph nodes occurred. Serial CT scans showed only little growth of these manifestations and the patient did not complain of any clinical disorder. Therefore the intra-abdominal lymphomas, as well as several subcutaneous lesions of the trunk, were not treated. In December 2009, a progressive lymphoma on the roof of the

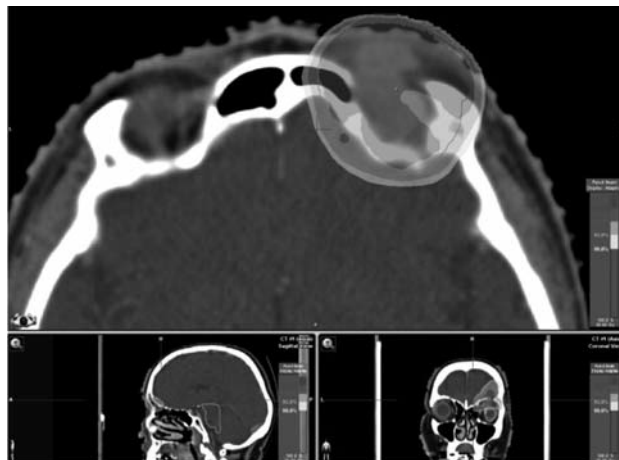


Figure 2. Dose distribution of SFRT of the right orbit. The light grey area shows the 95% isodose.

right orbit was irradiated. CT had shown this slowly growing lesion for the first time in 2005. Clinical examination showed a firm, indolent tumor in the right upper eyelid. The patient reported a progressive diplopia. Due to tumor localization, irradiation was given as stereotactic fractionated radiotherapy (SFRT). SFRT was performed with single daily fractions of 2.5 Gy to a total dose of 30 Gy. The dose was prescribed to the 100% isodose using 6-MV photons *via* 5 static beams directed at a single isocenter (Figure 2). Already during treatment, a decrease in tumor mass and diplopia was detectable. An MRI scan of the orbital region in April 2010 showed no evidence of residual tumor mass. In March 2010, the patient started systemic therapy with rituximab. Table I summarizes the applied irradiation series.

In summary, the patient had a very good KPS of 90-100%, only few clinical symptoms and a slow progression of disease throughout the 9 years after initial diagnosis. Only clearly progressive lymphoma manifestations were irradiated (total doses between 30 and 40 Gy). Treatment was well tolerated, with only minor local side-effects such as skin erythema, mucositis and alopecia. All irradiated lesions showed a complete regression and relapses only occurred at non-irradiated sites.

Discussion

Recent review articles have summarized the current knowledge about MZL (8, 9). The results of most studies indicate that patients with non-gastric MALT lymphoma typically have an excellent prognosis (3, 4, 10). Zucca *et al.* published a retrospective survey of 180 patients with non-gastric MALT lymphoma, demonstrating 5-year overall survival (OS) of 90% and 10-year OS of 80%; the 5-year progression-free survival was 60% regardless of treatment type. Patients were treated with a variety of therapeutic

Table I. Summary of irradiation series applied between 2001 and 2009.

Date	Target volume	Irradiation technique	Irradiation type	Energy (MeV)	Total dose (Gy)	Single dose (Gy)	Fractions/week
Dec 01	R. breast	Tangential fields	p	6	39.9	1.8	5
	R. axillary and paracervical lymph nodes	Static field	p	6	39.9	1.8	5
Nov-02	L. upper arm and axilla	Opposing fields	p	6	36	1.8	5
June 05	R. occipital lymph nodes	Static field	e	9	30	2.5	5
	R. parotid gland	Static field	e	12	30	2.5	5
	R. cervical lymph nodes	Static field	e	9	30	2.5	5
	L. cheek	Static field	e	9	30	2.5	5
July 07	L. cervical lymph nodes	3D	p	6	30	2.5	5
Dec 09	R. orbita	SFRT	p	6	30	2.5	5

p: Photon irradiation; e: Electron irradiation; L: left; R: right; SFRT: stereotactic fractionated radiotherapy.

Table II. Published trials concerning radiotherapy of localized marginal zone lymphoma.

Study (ref)	Cases (n)	Location	Follow-up	Dose (Gy)	LCR	OS
DeBlasio <i>et al.</i> 1989 (6)	14	Breast	4 years	35-44	78%	66%
Kiyohara <i>et al.</i> 2003 (8)	1	Skin	3 years	40	100%	100%
Senff <i>et al.</i> 2007 (15)	25	Skin	5 years	40	100%	90%
Nam <i>et al.</i> 2009 (14)	66	Orbit	5 years	20-45	95%	96%

LCR: Local control rate; OS: overall survival.

strategies, including chemotherapy, radiotherapy and surgery. Thirty-eight patients (21%) had nodal involvement (11). These data confirm the indolent nature of non-gastric MZL and the high rate of patients presenting with disseminated disease, which was not however associated with a poorer outcome. Multi-organ involvement is generally present in 40% of patients (3, 4, 11, 12).

In patients with disseminated disease at presentation, chemotherapy similar to regimens used for other indolent lymphomas is recommended. Recently, single-agent treatment with *i.v.* rituximab has been reported to induce an overall response rate of 75%, with better results when used as first-line therapy. It results in a high rate of durable remissions and should be directly compared with local radiotherapy (4, 9, 13). Asymptomatic patients can be managed with watch-and-wait strategy (3).

Although no large prospective multicenter trials concerning treatment have been published to date, the data that do exist indicate that localized disease can often be managed successfully with local treatment, such as involved field radiotherapy (total dose 30-40 Gy), or surgery (Table II). A previous report by De Blasio *et al.* of a cohort of 14 patients with localized NHL of the breast demonstrated a local control rate of 78%. Patients received involved field radiotherapy, with a total dose between 35 and 44 Gy (6). A retrospective study of 66 patients with orbital MZL showed

that orbital MZL responds extremely well to moderate-dose radiotherapy (median dose 30 Gy), with a high local control rate (5-year relapse-free survival of 92%) (13). Kiyohara *et al.* described a case of cutaneous MZL treated with electron beam irradiation (total dose 40 Gy). The tumor disappeared completely (8). A study by Senff *et al.* evaluated the results of radiotherapy in 153 patients with primary cutaneous B-cell lymphoma. The group included 25 patients with primary cutaneous MZL presenting with solitary, localized and multifocal skin lesions. Most patients had been treated with electron beam irradiation (median dose 40 Gy) to all visible skin lesions. Complete remission was reached in all 25 patients. The 5-year OS was 90% (15). Fifteen patients (60%) experienced a relapse after a median relapse-free interval of 16 months. Relapses always occurred at non-irradiated sites (cutaneous and extracutaneous). The data suggest that radiotherapy is a safe and effective treatment, not only in patients with solitary or localized lesions.

The outcome of patients with nodal MZL is worse than that of patients with MALT lymphoma. The disease is not currently curable, but despite a short time to progression, there is a long median survival, approaching 10 years in some series. Treatment options include a rituximab-chemotherapy combination. Single-agent rituximab or observation alone is appropriate for asymptomatic patients with low tumor burden (2-4).

Conclusion

MZL often seem to be the most indolent of all indolent lymphoma types. Therefore it is important to avoid over-treatment. Based on the literature and our own report, the judicious use of moderate-dose radiotherapy is a safe and effective treatment to achieve local tumor control in patients with MZL.

Competing Interests

The Authors declare that they have no competing interests.

References

- 1 Senff NJ, Noordijk EM, Kim YH, Bagot M, Berti E, Cerroni L, Dummer R, Duvic M, Hoppe RT, Pimpinelli N, Rosen ST, Vermeer MH, Whittaker S and Willemze R: European Organization for Research and Treatment of Cancer and International Society for Cutaneous Lymphoma consensus recommendations for the management of cutaneous B-cell lymphomas. *Blood* 112: 1600-1609, 2008.
- 2 Berger F, Felman P, Thieblemont C, Pradier T, Baseggio L, Bryon PA, Salles G, Callet-Bauchu E and Coiffier B: Non-MALT marginal zone B-cell lymphomas: a description of clinical presentation and outcome in 124 patients. *Blood* 95: 1950-1956, 2000.
- 3 Kahl B and Yang D: Marginal zone lymphomas: management of nodal, splenic and MALT NHL. *Hematology Am Soc Hematol Educ Program*, pp. 359-364, 2008.
- 4 Thieblemont C: Clinical presentation and management of marginal zone lymphomas. *Hematology Am Soc Hematol Educ Program*, pp. 307-313, 2005.
- 5 Brogi E and Harris NL: Lymphomas of the breast: pathology and clinical behavior. *Semin Oncol* 26: 357-364, 1999.
- 6 DeBlasio D, McCormick B, Strauss D, Smith M, Brustein S, Nisce L and Fuks Z: Definitive irradiation for localized non-Hodgkin's lymphoma of breast. *Int J Radiat Oncol Biol Phys* 17: 843-846, 1989.
- 7 Lyons JA, Myles J, Pohlmann B, Macklis RM, Crowe J and Crownover RL: Treatment and prognosis of primary breast lymphoma: a review of 13 cases. *Am J Clin Oncol* 23: 334-336, 2000.
- 8 Kiyohara T, Kumakiri M, Kobayashi H, Nakamura H and Ohkawara A: Cutaneous marginal zone B-cell lymphoma: a case accompanied by massive plasmacytoid cells. *J Am Acad Dermatol* 48(5 Suppl): 82-85, 2003.
- 9 Valencak J, Weihsengruber F, Rappersberger K, Trautinger F, Chott A, Streubel B, Muellauer L, Der-Petrossian M, Jonak C, Binder M and Raderer M: Rituximab monotherapy for primary cutaneous B-cell lymphoma: response and follow-up in 16 patients. *Ann Oncol* 20: 326-330, 2009.
- 10 Servitje O, Gallardo F, Estrach T, Pujol RM, Blanco A, Fernández-Sevilla A, Pétriz L, Peyri J and Romagosa V: Primary cutaneous marginal zone lymphoma: a clinical, histopathological, immunophenotypic and molecular genetic study of 22 cases. *Br J Dermatol* 147: 1147-1158, 2002.
- 11 Zucca E, Conconi A, Pedrinis E, Cortelazzo S, Motta T, Gospodarowicz MK, Patterson BJ, Ferreri AJM, Ponzoni M, Devizzi L, Giardini R, Inotti G, Capella C, Zinzani PL, Pileri S, López-Guillermo, Campo E, Ambrosetti A, Baldini L and Cavalli F: Nongastric marginal zone B-cell lymphoma of mucosa associated lymphoid tissue. *Blood* 101: 2489-2495, 2003.
- 12 Bailey EM, Ferry JA, Harris NL, Mihm MC, Jacobson JO and Duncan LM: Marginal zone lymphoma (low-grade B-cell lymphoma of mucosa-associated lymphoid tissue type) of skin and subcutaneous tissue: a study of 15 patients. *Am J Surg Pathol* 20: 1011-1023, 1996.
- 13 Dalle S, Thomas L, Balme B, Dumontet C and Thieblemont C: Primary cutaneous marginal zone lymphoma. *Crit Rev Oncol Hematol* 74: 156-162, 2010.
- 14 Nam H, Ahn YC, Kim YD, Ko Y and Kim WS: Prognostic significance of anatomic subsites: results of radiation therapy for 66 patients with localized orbital marginal zone B cell lymphoma. *Radiother Oncol* 90: 236-241, 2009.
- 15 Senff NJ, Hoeffnagel JJ, Neelis KJ, Vermeer MH, Noordijk EM and Willemeze R: Results of radiotherapy in 153 primary cutaneous B-Cell lymphomas classified according to the WHO-EORTC classification. *Arch Dermatol* 143: 1520-1526, 2007.

Received March 17, 2011

Revised May 30, 2011

Accepted June 1, 2011