

Immunohistochemical Staining with DeltaNp63 Is Useful for Distinguishing the Squamous Cell Component of Adenosquamous Cell Carcinoma of the Lung

HIDETAKA URAMOTO¹, SOHSUKE YAMADA² and TAKESHI HANAGIRI¹

¹Second Department of Surgery, and ²Department of Pathology and Cell Biology, School of Medicine, University of Occupational and Environmental Health, Kitakyushu, Japan

Abstract. *Background:* DeltaNp63 is an isoform of the p53 homolog p63, which lacks an amino-terminal transactivation domain. The aim of this study was to detect the deltaNp63 expression in the squamous carcinoma component of adenosquamous carcinoma and evaluate its usefulness as a specific squamous carcinoma marker. *Patients and Methods:* Immunohistochemistry was used to analyze the protein expression of deltaNp63 and high molecular weight cytokeratin in paraffin-embedded tumor samples from 17 patients with well-characterized adenosquamous carcinoma. *Results:* Of 17 cases, 13 (76.5%) and 14 (82.4%) cases showed positive staining for deltaNp63 and HMWCK in the tumor cells, respectively. It was easy to discriminate the squamous carcinoma and adenocarcinoma components in all tumors. Interestingly, positive expression of deltaNp63 was detected in one case with a negative expression of HMWCK. *Conclusion:* These findings indicated that the deltaNp63 status was useful for distinguishing squamous carcinoma from adenocarcinoma in formalin-postfixed adenosquamous carcinoma specimens.

The essential histological diagnosis for lung cancer has been its classification into small cell carcinoma (SCLC) or non-small cell carcinoma (NSCLC) because treatment did not differ between the variants. However, several drugs have become available with indications dependent on the precise definition of tumor subtype, in relation to both the efficacy and safety for specific histology. For example, the epidermal growth factor receptor – tyrosine kinase inhibitor (EGFR–TKI) such as

gefitinib have superior efficacy in patients harboring a somatic mutation, which is usually observed in only adenocarcinoma (AD) (1). Squamous carcinoma (SQ) histology is now a contraindication for bevacizumab due to fatal adverse events (2). Pemetrexed is also contraindicated in SQ with no significant efficacy, but has superior efficacy in non-SQ over standard platinum-doublet chemotherapy (3). Therefore, the dichotomization of the NSCLC subtype into SQ and AD is increasingly required for both diagnostic meaning and therapeutic selection. Furthermore, the therapeutic strategy for adenosquamous carcinoma (ADSQ) remains unclear. ADSQs are the most suitable research object to determine a useful marker because these tumors include both SQ and AD components (4).

The tumor suppressor p53 and its two homolog p63 and p73, form a family of proteins (5). P63 and p73 show a much greater molecular complexity than p53 because they are both expressed as multiple alternatively spliced C-terminal isoforms, and as an N-terminally deleted form (6). In addition, several other factors, such as post-translational modifications, result in the subtle modulation of their biological effects (7). P63 knockout animals showed defects in epidermal development, suggesting a role of p63 in regulating differentiation in epithelial cells (8). P63 gene amplification and protein overexpression are more often detected in a variety of carcinomas of the head and neck (9), lung (10), and skin (11). Therefore, p63 may play an important role in tumor progression. On the other hands, the overexpression of DeltaNp63, which is a different isoform due to alternative splicing (12), often enhances the oncogenic growth of squamous cell carcinomas (9). Traditionally, p63 has been used as an immunomarker for SQ on tissue sections (13). However, an immunohistochemical (IHC) examination of the expression of p63 used a nonspecific antibody, which reacts not only with the transactivating domain (TA)-p63, but also with deltaNp63 (14, 15). Furthermore, the positive expression of deltaNp63 on SQ was significantly higher than on AD (5).

This study attempted to identify a specific marker to detect only the SQ component of ADSQs using a

Correspondence to: Hidetaka Uramoto, MD, Ph.D., Second Department of Surgery, School of Medicine, University of Occupational and Environmental Health, 1-1 Iseigaoka, Yahatanishiku, Kitakyushu 807-8555, Japan. Tel: +81 936917442, Fax: +81 936924004, e-mail: hidetaka@med.uoeh-u.ac.jp

Key Words: DeltaNp63, immunohistochemistry, squamous cell carcinoma, non-small cell lung cancer.

commercially available antibody. This study investigated the ability of deltaNp63 to discriminate the histology in NSCLC and compared it to high molecular weight cytokeratin (HMWCK), which is known to be a differential marker for SQ and AD (16).

Patients and Methods

Patient samples. The characteristics and clinicopathological factors were evaluated retrospectively. One thousand and one hundred thirty-four patients with primary lung cancer underwent a surgical resection between June 1995 to March 2010 at the Second Department of Surgery at University of Occupational and Environmental Health, Kitakyushu, Japan. The established criteria classified an ADSQ as a tumor containing at least 20% of AD and SQ each (4). Specimens from each of these patients were reviewed critically by one (S.Y.) pathologist. This study evaluated 17 cases (1.5%) with ADSQ. The characteristics of the patients with ADSQ are shown in Table I. Patients included 6 males and 11 females with a mean age of 68.5 years, ranging in age from 48 to 86 years. Institutional Review Board-approved informed consent was obtained from all patients for the use of tumor tissue specimens collected at the time of tumor resection.

Immunohistochemical (IHC) staining in paraffin-embedded tumor samples. All specimens were stained with hematoxylin-eosin (H-E) for the histological diagnosis. IHC staining was conducted using serial sections from the same paraffin-embedded blocks as previously described (17, 18). Briefly, all tissue specimens were formalin-fixed and processed similarly, according to standard histological practices. The sections were briefly immersed in citrate buffer [0.01 mol/l citric acid (pH 6.0)] and were incubated for two 10-minute periods at 121°C in a high-pressure sterilization oven for antigen retrieval. They were then incubated with anti-deltaNp63 (PC373, Calbiochem, Darmstadt, Germany) diluted at 1:3000, in phosphate-buffered saline for 60 minutes at 4°C. They were also incubated with anti-HMWCK (34beta E12; keratin-903; Enzo Life Science, Inc, NY, USA) diluted at 1:40, in phosphate-buffered saline for 60 minutes at room temperature. Thereafter, IHC staining of deltaNp63 and HMWCK was performed by the labeled polymer method using Histofine Simple Stain MAX-PO kit (Nichirei, Tokyo, Japan) and EnVision kit (DAKO, Tokyo, Japan) according to the manufacturer's instructions, respectively (18, 19). Negative controls were processed by exclusion of the primary antibody.

Evaluation of the stained specimens. IHC detected the protein expression in each specimen, then the stained cancer cells were evaluated by a combination of proportional and intensity score because the tumor samples showed various degrees of staining intensity and different numbers of positive cells, (20). Initially, 4 degrees of a proportional score (PS) for the positively staining cells were assigned according to the frequency of positive tumor cells (0, none; 1, <25%; 2, 25-50%; and 3, >50%). Thereafter, 4 degrees of an intensity score (IS) were assigned according to the intensity of the staining (none, weak, intermediate, and strong). Normal epithelial cells of the basal of the bronchus showed intense nuclear staining of deltaNp63, which was used as an internal positive control of intensity 2 (20). The slides were independently examined by two of the investigators (H.U. and S.Y.) who were blinded to the

Table I. Summary of immunostaining in ADSQ tumors.

Case	Gender	Age (years)	Delta Np63		HMWCK	
			PS	IS	PS	IS
1	F	74	3	Strong	3	Strong
2	F	72	2	Strong	3	Strong
3	F	77	3	Moderate	3	Strong
4	F	68	3	Moderate	3	Strong
5	F	48	3	Moderate	3	Strong
6	M	62	2	Moderate	3	Strong
7	F	86	2	Moderate	2	Strong
8	M	71	1	Moderate	2	Moderate
9	M	72	1	Moderate	3	Strong
10	M	83	3	Moderate	2	Strong
11	M	79	1	Moderate	1	Moderate
12	M	72	2	Weak	1	Moderate
13	M	51	2	Weak	0	None
14	M	56	0	None	1	Weak
15	M	55	0	None	3	Strong
16	M	61	0	None	0	None
17	M	78	0	None	0	None

clinicopathological data. When a discrepancy was found between the two investigators, a consensus was reached *via* their simultaneous examination using a double-headed microscope.

Results

Figure 1A and C show the H-E staining for the tumor cells. The typical appearance of staining for deltaNp63 is shown in Figure 1B and D. DeltaNp63 expression only clearly stained the nuclei in the SQ component deep brown, whereas HMWCK expression was specifically detected in the cytoplasm. It was easy to discriminate the SQ in ADSQ. DeltaNp63- and HMWCK-expressing tumor cells were observed in 13 (76.5%) and 14 (82.4%) out of 17 cases, respectively. Interestingly, positive expression of deltaNp63 was detected in a case with a negative expression of HMWCK. The opposite was equally true.

Discussion

The discrimination of tumor histology is important for selecting the modality of therapy. Therefore, an accurate histological diagnosis is imperative and a specific marker is needed to detect the SQ component. The incidence of the positive expression of deltaNp63 is significantly higher in SQ than AD (5). Most of the SQ component of ADSQ showed positive expression of deltaNp63 in spite of the genetic intratumoral heterogeneity (21). Therefore, deltaNp63 is a useful marker for its histopathologic diagnosis. Surprisingly, positive expression of deltaNp63 was detected in a case with

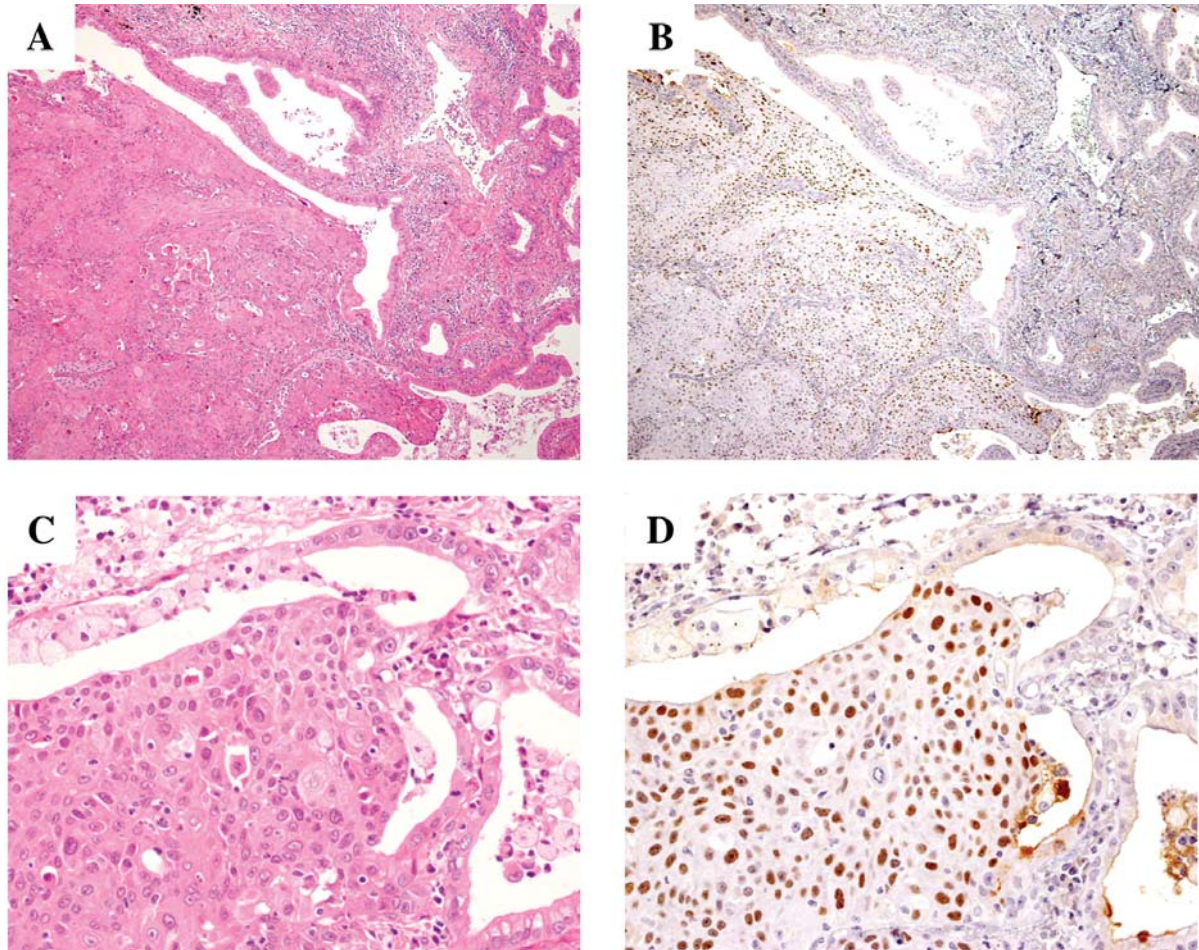


Figure 1. A: Representative low-power view of H-E staining of ADSQ (original magnification $\times 40$). B: DeltaNp63-expressing tumor cells with deep brown-stained nuclei are shown for the same specimen and alignment as shown in A. C: Representative high-power view of H-E staining of ADSQ (original magnification $\times 200$). D: DeltaNp63 IHC staining in the same specimen and alignment as shown in C.

negative expression of cytokeratin. Nicholson *et al.* pointed out low the specificity for SQ of 34beta E2 antibody, though HMWCK is useful as a differential marker for SQ (22). DeltaNp63 and HMWCK antibody might compensate each other as an SQ marker. Why is deltaNp63 localized in the SQ component rather than AD? Boldrup *et al.* reported elevated CD44, which is a marker of cancer stem cells, expression in the clones overexpressing deltaNp63 (12). In fact, deltaNp63 acts as a dominant-negative reagent toward tumor suppressor p53, thus indicating its oncogenic role (23). Higashikawa *et al.* reported that the epithelial-mesenchymal transition (EMT) is accompanied by a down-regulation of deltaNp63 (25). Cancer cells form a new focus through the mesenchymal-epithelial transition (MET) (26). Therefore, cancer cells in the SQ component might have a more aggressive biological behavior than that of the AD component. In fact, the survival rate for patients with ADSQ is statistically worse than for those with

SQ and AD (27). The triangle of relationships among p53 family, EGFR, and EMT might be key in lung cancer translational research (28-30).

No firm conclusion can be drawn from the result of this study because it observed only a small number of patients analyzed at a single institution; nonetheless, the current results apparently indicate that deltaNp63 status is useful as a specific marker of SQ. Further investigation is necessary to determine the clinical benefit of the biomarker in a larger cohort of patients and in prospective studies.

Acknowledgements

We thank Yukiko Koyanagi and Kanako Sasaki and for valuable technical assistance. This work was supported by a Grant-in Aid for Scientific Research from the Ministry of Education, Culture, Sports, Science and Technology, Japan.

References

- 1 Uramoto H and Mitsudomi T: Which biomarker predicts benefit from EGFR-TKI treatment for patients with lung cancer? *Br J Cancer* 96: 857-863, 2007.
- 2 Clément-Duchêne C and Wakelee H: Antiangiogenic agents and vascular disrupting agents for the treatment of lung cancer: a review. *J Thorac Oncol* 5: 129-139, 2010.
- 3 Uramoto H, Onitsuka T, Shimokawa H and Hanagiri T: TS/DHFR/GARFT expression in non-squamous cell carcinoma of NSCLC and malignant pleural mesothelioma patients treated with pemetrexed. *Anticancer Res*, in press.
- 4 Sobin LH and Wittekind C: *TNM Classification of Malignant Tumors*, 6th ed. New York: Wiley; 2002.
- 5 Uramoto H, Sugio K, Oyama T, Nakata S, Ono K, Nozoe T and Yasumoto K: p53 family in lung cancer. *Anticancer Res* 26: 1785-1790, 2006.
- 6 Uramoto H, Sugio K, Oyama T, Nakata S, Ono K, Morita M, Funa K and Yasumoto K: Expression of deltaNp73 predicts poor prognosis in lung cancer. *Clin Cancer Res* 10: 6905-6911, 2004.
- 7 Uramoto H, Wetterskog D, Hackzell A, Hackzell A, Matsumoto Y and Funa K: p73 competes with co-activators and recruits histone deacetylase to NF-Y in the repression of PDGF beta-receptor. *J Cell* 117: 5323-5331, 2004.
- 8 Melino G, Lu X, Gasco M, Crook T and Knight RA: Functional regulation of p73 and p63: development and cancer. *Trends Biochem Sci* 28: 663-670, 2003.
- 9 Hibi K, Trink B, Patturajan M, Westra WH, Caballero OL, Hill DE, Ratovitski EA, Jen J and Sidransky D: AIS is an oncogene amplified in squamous cell carcinoma. *Proc Natl Acad Sci USA* 97: 5462-5467, 2000.
- 10 Massion PP, Taflan PM, Jamshedur Rahman SM, Jamshedur Rahman SM, Yildiz P, Shyr Y, Edgerton ME, Westfall MD, Roberts JR, Pietenpol JA, Carbone DP and Gonzalez AL: Significance of p63 amplification and overexpression in lung cancer development and prognosis. *Cancer Res* 63: 7113-7121, 2003.
- 11 Parsa R, Yang A, McKeon F and Green H: Association of p63 with proliferative potential in normal and neoplastic human keratinocytes. *J Invest Dermatol* 113: 1099-1105, 1999.
- 12 Boldrup L, Coates PJ, Gu X and Nylander K: DeltaNp63 isoforms regulate CD44 and keratins 4, 6, 14 and 19 in squamous cell carcinoma of head and neck. *J Pathol* 213: 384-391, 2007.
- 13 Wu M, Wang B, Gil J, Sabo E, Miller L, Gan L and Burstein DE: p63 and TTF-1 immunostaining: a useful marker for distinguishing small cell carcinoma of lung from poorly differentiated squamous cell carcinoma of lung. *Am J Clin Pathol* 119: 696-702, 2003.
- 14 Hu H, Xia SH, Li AD, Xu X, Cai Y, Han YL, Wei F, Chen BS, Huang XP, Han YS, Zhang JW, Zhang X, Wu M and Wang MR: Elevated expression of p63 protein in human esophageal squamous cell carcinomas. *Int J Cancer* 102: 580-583, 2002.
- 15 Glickman JN, Yang A, Shahsafaei A, McKeon F and Odze RD: Expression of p53-related protein p63 in the gastrointestinal tract and in esophageal metaplastic and neoplastic disorders. *Hum Pathol* 32: 1157-1165, 2001.
- 16 Morice WG and Ferreiro JA: Distinction of basaloid squamous cell carcinoma from adenoid cystic and small cell undifferentiated carcinoma by immunohistochemistry. *Hum Pathol* 29: 609-612, 1998.
- 17 Uramoto H, Osaki T, Inoue M, Taga S, Takenoyama M, Hanagiri T, Yoshino I, Nakanishi R, Ichiyoshi Y and Yasumoto K: Fas expression in non-small cell lung cancer: its prognostic effect in completely resected stage III patients. *Eur J Cancer* 35: 1462-1465, 1999.
- 18 Yamashita T, Onitsuka T, Ono K, Baba T, So T, So T, Takenoyama M, Hanagiri T, Oyama T and Yasumoto K: Association between lymphangiogenesis-/micrometastasis- and adhesion-related molecules in resected stage I NSCLC. *Lung Cancer*, in press.
- 19 Onitsuka T, Uramoto H, Ono K, Takenoyama M, Hanagiri T, Oyama T, Izumi H, Kohno K and Yasumoto K: Comprehensive molecular analyses of lung adenocarcinoma with regard to the epidermal growth factor receptor, K-ras, MET, and hepatocyte growth factor status. *J Thorac Oncol* 5: 591-596, 2010.
- 20 Iwata T, Uramoto H, Sugio K, Fujino Y, Oyama T, Nakata S, Ono K, Morita M and Yasumoto K: A lack of prognostic significance regarding DeltaNp63 immunoreactivity in lung cancer. *Lung Cancer* 50: 67-73, 2005.
- 21 Niho S, Yokose T, Kodama T, Nishiwaki Y and Mukai K: Clonal analysis of adenosquamous carcinoma of the lung. *Jpn J Cancer Res* 90: 1244-1247, 1999.
- 22 Nicholson AG, Gonzalez D, Shah P, Pynegar MJ, Deshmukh M, Rice A and Popat S: Refining the diagnosis and EGFR status of non-small cell lung carcinoma in biopsy and cytologic material, using a panel of mucin staining, TTF-1, cytokeratin 5/6, and P63, and EGFR mutation analysis. *J Thorac Oncol* 5: 436-441, 2010.
- 23 Senoo M, Matsumura Y and Habu S: TAp63gamma (p51A) and dNp63alpha (p73L), two major isoforms of the p63 gene, exert opposite effects on the vascular endothelial growth factor (VEGF) gene expression. *Oncogene* 21: 2455-2465, 2002.
- 24 Rocco JW and Ellisen LW: p63 and p73: life and death in squamous cell carcinoma. *Cell Cycle* 5: 936-940, 2006.
- 25 Higashikawa K, Yoneda S, Tobiume K, Taki M, Shigeishi H and Kamata N: Snail-induced down-regulation of DeltaNp63alpha acquires invasive phenotype of human squamous cell carcinoma. *Cancer Res* 67: 9207-9213, 2007.
- 26 Iwatsuki M, Mimori K, Yokobori T, Ishi H, Beppu T, Nakamori S, Baba H and Mori M: Epithelial-mesenchymal transition in cancer development and its clinical significance. *Cancer Sci* 101: 293-299, 2010.
- 27 Shimizu J, Oda M, Hayashi Y, Nonomura A and Watanabe Y: A clinicopathologic study of resected cases of adenosquamous carcinoma of the lung. *Chest* 109: 989-994, 1996.
- 28 Thiery JP: Epithelial-mesenchymal transitions in tumour progression. *Nat Rev Cancer* 2: 442-454, 2002.
- 29 Herfs M, Hubert P, Suarez-Carmona M, Reschner A, Saussez S, Berx G, Savagner P, Boniver J and Delvenne P: Regulation of p63 isoforms by snail and slug transcription factors in human squamous cell carcinoma. *Am J Pathol* 176: 1941-1949, 2010.
- 30 Uramoto H, Iwata T, Onitsuka T, Shimokawa H, Hanagiri T and Oyama T: Epithelial-mesenchymal transition in EGFR-TKI-acquired resistant lung adenocarcinoma. *Anticancer Res* 30: 2513-2517, 2010.

Received September 13, 2010

Revised October 25, 2010

Accepted October 26, 2010