

Surgical Management of Multiple Bilateral Fibroadenoma of the Breast: The Ribeiro Technique Modified by Rezai*

O. CAMARA¹, A. EGBE¹, I. KOCH¹, J. HERRMANN¹, M. GAJDA², P. BALTZER³ and I.B. RUNNEBAUM¹

Department of ¹Obstetrics and Gynaecology, ²Pathology, and ³Radiology, Friedrich Schiller University Jena, Germany

Abstract. *Background: Fibroadenomas are hyperplasia arising from the terminal ductulo-lobular unit and adjacent tissue of the breast. As single fibroadenoma, even giant ones are easily manageable, however multiple fibroadenomas pose a particular challenge. Case Report: In 1971, Liacyr Ribeiro described his new technique for reduction mammoplasty. Four years later, the first 20 cases were published. This technique was introduced by Rezai in oncoplastic surgery. With free hand design, preoperative marking is performed and the inferior pedicle modulated. Results: Selective resection of more than seventy fibroadenomas was performed on two patients. The technique allowed a modelling of the breast like a mastopexy through the inferior pedicle. Conclusion: Multiple fibroadenomas of the breast are safely removable with the Ribeiro technique modified by Rezai.*

Fibroadenoma is a common cause of discrete breast lumps in young women (1) and occurs in 25% of asymptomatic women (2). The size varies but is on average between 1 and 3 cm (3). Giant fibroadenomas are reported frequently in the literature and the surgical approach varies from local wide excision to mastectomy (4-10).

Thirty years ago, Egger and Muller described 412 women with fibroadenoma, of whom 7.1% had considerable epithelial proliferation and 1.7% carcinoma *in situ* or carcinoma. With increasing age, the risk of carcinomatous degeneration in fibroadenomas rises to 17% (11). This necessitates excision of all such tumours. Fibroadenoma with hyperplasia and atypia confers a higher risk for breast cancer (2).

*Presented at the 8th International Conference of Anticancer Research, 17-22 October 2008, Kos, Greece.

Correspondence to: Oumar Camara, Department of Gynaecology and Obstetrics, Friedrich Schiller University Jena, Bachstr. 18 D-07740 Jena Germany. Tel: +49 3641933057, Fax: +49 3641933064, e-mail: oumar.camara@med.uni-jena.de

Key Words: Multiple fibroadenoma, breast surgery, mammoplasty.

Although fibroadenoma is associated with other pathological entities in 50% of cases (12), the risk is still considered low (13).

Wide local excision has been proposed for the treatment of benign lesions (14).

In cases of multiple unilateral fibroadenomas, circumareolar incision seems to be adequate (15). Complete excision is recommended. Not all women are candidates for conservative treatment (16). Reduction mammoplasty is described in cases of asymmetry (14, 17-20).

The aim of this paper is to describe the usefulness of the Ribeiro technique modified by Rezai in the treatment of bilateral multiple fibroadenomas (21-23)

Case Report

In 1971, Ribeiro described his dermo-lipo-glandular flap and presented his new technique for reduction mammoplasty in 1975 (21). Thirty years later, with more than two thousand patients having been treated, the technique was combined with different incisions and for several indications (22). The modified technique by Rezai was used in January 2002 and in August 2004 to treat multiple bilateral fibroadenomas in two patients aged 28 and 18 years (23, 24). The first patient, multiparous, presented with palpable masses in both breasts as shown in Figure 3. The second patient was a nulliparous (Figure 1). No patient had operative antecedent in their medical history. With the patient in an upright position, the midbreast line was determined. The new nipple position was designated on a point on this midbreast line. The angle of the upper V was determined. By approximating a lateral and medial point and raising the lower quadrants, the proposed new breast can be evaluated in volume and shape. Straight lines joined the lowest points of the V with the inframammary line. De-epithelisation was performed within this area.

Results

From the four breasts of these two patients, more than seventy fibroadenomas were excised. Figure 1 shows an MRI slide

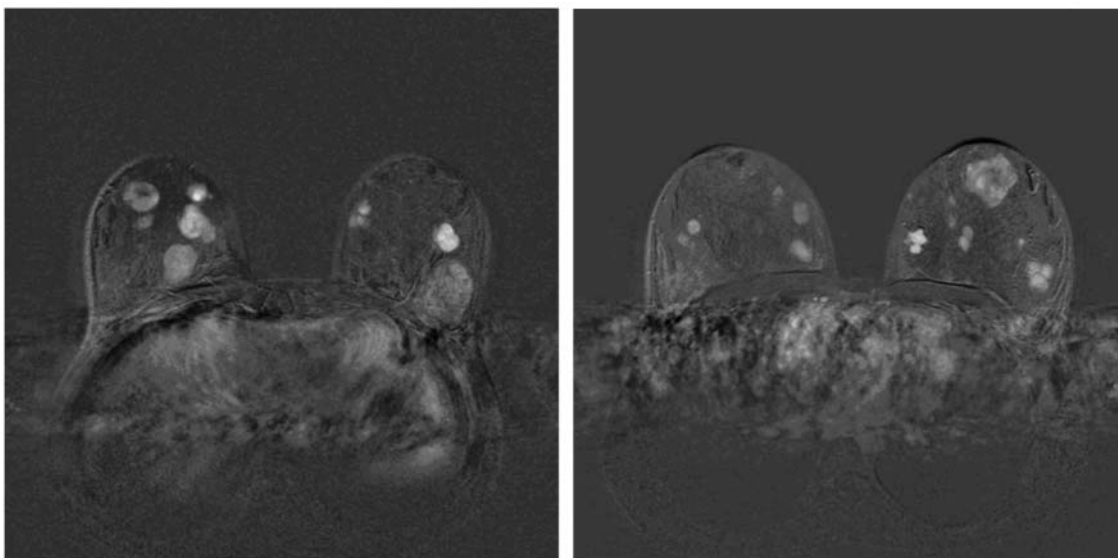


Figure 1. MRI slides of fibroadenomas of different sizes in one patient.

with nine (a) and twelve (b) detectable fibroadenomas in both breasts. Figure 2 shows 16 fibroadenomas of different size removed from the left breast. In August 2008, the younger patient required an excision of one fibroadenoma >2 cm. The old mammoplasty scar was used and the cosmetic results after four years are quite satisfactory (Figure 3).

Discussion

The surgical treatment of choice of fibroadenoma is breast conserving. Gordon *et al.* reported changes in volumes in 1070 consecutive patients with breast lesions diagnosed as fibroadenoma at fine-needle aspiration. Change in volume per month was approximately 16% and 13% for patients younger than 50 years and older than 50 years respectively. The 95th percentile mean change in dimension at a 6-month interval for both was 20%. They concluded that fibroadenomas may be safely followed up if volume growth rate is less than 16% in those younger than 50 years and less than 13% per month in those 50 years or older. Acceptable mean change in dimension for a 6-month interval is 20% for all ages (25). Non-operative management of fibroadenomas seems to be safe (1, 26). In a retrospective summary Edwards and co-workers reported cryoablation of 310 fibroadenomas. At 12 months post procedure, the remaining fibroadenoma progressively involuted (27). Volume-dependent local excision of multiple fibroadenomas, even giant fibroadenomas, can be safely carried out (9, 15, 28). Reduction mammoplasty is mostly reported on giant fibroadenomas (6, 14, 17). Lee and co-workers treated an 11-year-old girl with multiple bilateral fibroadenomas with a central pedicle breast reduction. All

masses were complete excised, resulting in a reduction of 1,750 g from the right breast and 1,900 g from the left breast. The patient reported no recurrent enlargement of her breasts 5 years after surgery (18).

We treated our patients using the inferior pedicle as described by Ribeiro and Rezai (22, 23). It allowed excision in any part of the breast and remodelling. The younger patient had a second intervention two years later due to a fibroadenoma. After 5 years, the cosmetic results are stable.

In conclusion, multiple fibroadenomas of the breast are safely removable with the Ribeiro technique modified by Rezai.

References

- 1 Carty NJ, Carter C, Rubin C, Ravichandran D, Royle GT and Taylor I: Management of fibroadenoma of the breast. *Ann R Coll Surg Engl* 77(2): 127-130, 1995.
- 2 El-Wakeel H and Umpleby HC: Systematic review of fibroadenoma as a risk factor for breast cancer. *Breast* 12(5): 302-307, 2003.
- 3 Larsen TK, Faurschou JP, Bak M and Rytto NF: Fibroadenoma of the breast – modern strategy of treatment. *Ugeskr Laeger*. 165(19): 1979-1983, 2003.
- 4 Dolmans GH, Hoogbergen MM and van Rappard JH: Giant fibroadenoma of one breast: Immediate bilateral reconstruction. *J Plast Reconstr Aesthet Surg* 60(10): 1156-1157, 2007.
- 5 Lo Martire N, Nibid A, Farello G, Gabriele A and Giuliani M: Giant fibroadenoma of the breast in an adolescent: a case report. *Ann Ital Chir* 73(6): 631-634, 2002.
- 6 Park CA, David LR and Argenta LC: Breast asymmetry: presentation of a giant fibroadenoma. *Breast J* 12(5): 451-461, 2006.

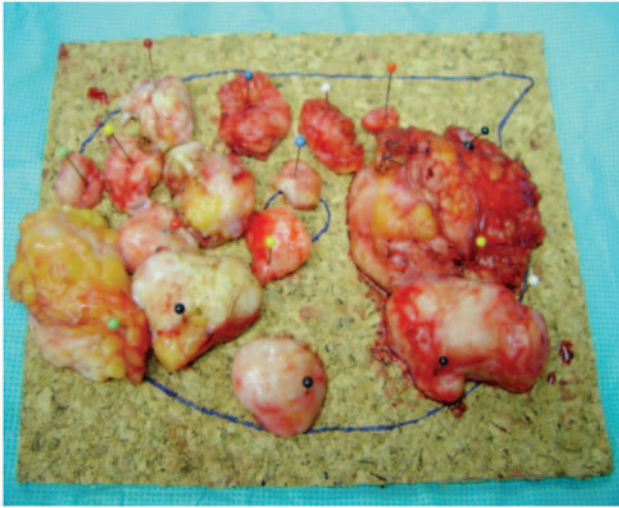


Figure 2. Excised fibroadenomas on the template of the left breast.

- 7 Przeniczna HS. Giant fibroadenoma of the breast in a 14-year-old girl. Case report. *Med Wieku Rozwoj* 8(4 Pt 2): 1099-1104, 2004.
- 8 Simmons RM, Cance WG and Iacicca MV: A giant juvenile fibroadenoma in a 12-year-old girl: a case for breast conservation. *Breast J* 6(6): 418-420, 2000.
- 9 Naraynsingh V, Maharaj D and Rampaul R: "Swiss-roll" operation for giant fibroadenomas. *Breast J* 8(1): 45-46, 2002.
- 10 Musio F, Mozingo D and Otchy DP: Multiple, giant fibroadenoma. *Am Surg* 57(7): 438-441, 1991.
- 11 Egger H and Muller S: Fibroadenoma of the breast (author's transl). *Dtsch Med Wochenschr* 102(42): 1495-1500, 1977.
- 12 Shabtai M, Saavedra-Malinger P, Shabtai EL, Rosin D, Kuriansky J, Ravid-Megido M *et al*: Fibroadenoma of the breast: analysis of associated pathological entities—a different risk marker in different age groups for concurrent breast cancer. *Isr Med Assoc J* 3(11): 813-817, 2001.
- 13 Ranieri E, Barberi S, Caprio G, Civitelli L, Naticchioni E, Ceccarelli F *et al*: Diagnosis and treatment of fibroadenoma of the breast: 20 years' experience. *Chir Ital* 58(3): 295-297, 2006.
- 14 Yilmaz M, Vayvada H, Menderes A, Demirdover C, Barutcu A. Reduction mammoplasty for phyllodes tumor causing asymmetry in an adolescent female. *Breast J* 9(5): 426-427, 2003.
- 15 Amshel CE and Sibley E: Multiple unilateral fibroadenomas. *Breast J* 7(3): 189-191, 2001.
- 16 Greenberg R, Skornick Y and Kaplan O: Management of breast Fibroadenomas. *J Gen Intern Med* 13: 640-645, 1998.
- 17 Chang DS and McGrath MH: Management of benign tumors of the Adolescent Breast. *Plast Reconstr Surg* 120: 13-19, 2007.
- 18 Lee CJ, Kim YJ, Seo YT, Pak SJ and Lee SI: Treatment of Mutiple bilateral juvenile fibroadenomas in a teenage breast by central pedicle breast reduction, with vertical and short horizontal scar: case report. *Aesth Plast Surg* 28: 228-230, 2004.
- 19 Park CA, David LR and Argenta LC: Breast asymmetry: presentation of giant fibroadenoma. *Breast J* 12(5): 451-461, 2006.

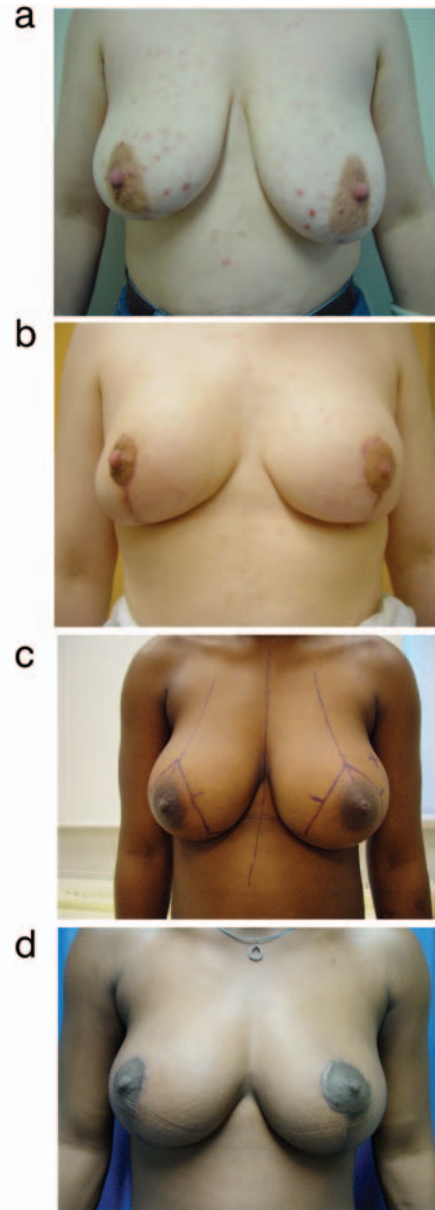


Figure 3. Preoperative (a, c) and postoperative (b, d) views four years later of each patient.

- 20 Wechselberger G, Schoeller T and Piza-Katzer H: Juvenile fibroadenoma of the breast. *Surgery* 132(1): 106-107, 2002.
- 21 Ribeiro L. A new technique for reduction mammoplasty. *Plast Reconstr Surg* 55(3): 330-334, 1975.
- 22 Ribeiro L, Accorsi A, Buss A and Marcal-Pessao M: Creation and evolution of 30 years of the inferior pedicle in reduction mammoplasties. *Plast Reconstr Surg* 110: 960-970, 2002.
- 23 Rezai M and Darsow M: Tumor-adapted reduction mammoplasty in oncological breast surgery. *Breast Care* 2: 308-312, 2007.
- 24 Krämer S, Kümmel S, Camara O, Große R, Friedrich M and Blohmer J-U: Partial mastectomy reconstruction with local and distant tissue flaps. *Breast Care* 2: 299-306, 2007.

- 25 Gordon PB, Gagnon FA and Lanzkowsky L: Solid breast masses diagnosed as fibroadenoma at fine-needle aspiration biopsy: acceptable rates of growth at long-term follow-up. *Radiology* 229(1): 233-238, 2003.
- 26 Cant PJ, Madden MV, Coleman MG and Dent DM: Non-operative management of breast masses diagnosed as fibroadenoma. *Br J Surg* 82(6): 792-794, 1995.
- 27 Edwards MJ, Broadwater R, Tafra L, Jarowenki D, Mabry C, Beitsch P *et al*: Progressive adoption of cryoablative therapy for breast fibroadenoma in community practice. *Am J Surg* 188(3): 221-224, 2004.
- 28 Maharaj D, Naraynsingh V and Ramdass M: Management of giant fibroadenomas: A case for small incisions for large tumors. *Breast J* 9(2): 141, 2003.

Received January 8, 2009

Revised March 13, 2009

Accepted May 4, 2009