

Influence of Catumaxomab on Tumor Cells in Bone Marrow and Blood in Ovarian Cancer

P. WIMBERGER¹, M. HEUBNER¹, H. LINDHOFER², M. JÄGER³, R. KIMMIG¹ and S. KASIMIR-BAUER¹

¹Department of Gynecology and Obstetrics, University of Duisburg-Essen, Essen;

²Trion Pharma GmbH, Munich;

³Trion Research GmbH, Martinsried, Germany

Abstract. *The trifunctional antibody catumaxomab with bispecificity for the epithelial cell adhesion molecule EpCAM and the T-cell antigen CD3, is a new therapeutic strategy for ovarian cancer patients with symptomatic malignant ascites. Whether or not intraperitoneal (i.p.) catumaxomab-therapy has influence on disseminated and circulating tumor cells was investigated by analyzing cytokeratin-positive (CK+) cells in bone marrow (BM) and peripheral blood (PB). Fourteen ovarian cancer patients with symptomatic ascites were treated with catumaxomab (up to 5 i.p.-infusions; increasing dosages (10-200 µg)). CK+-cells were isolated before and after antibody-therapy by density gradient centrifugation and immunocytochemistry (anti-CK antibody A45-B/B3). Catumaxomab-treatment resulted in the sustained reduction of ascites flow and arrested ascites reaccumulation. The mean overall survival was 8 months. CK+-cells in the BM were found in 70% before and 83% after therapy (in the PB 57% and 42%, respectively). A marked reduction of CK+-cells occurred in the BM in 2 and in the PB in 4 patients. Catumaxomab shows a strong intraperitoneal effect and possibly also systemic effects on tumor cells in the BM and PB.*

Ovarian cancer is the most common cause of death from gynecological carcinomas (1). About 75% of all patients with ovarian cancer are diagnosed in advanced stage (International Federation of Gynecology and Obstetrics, FIGO III and IV), because of the lack of symptoms and screening methods (2). The standard therapy of advanced ovarian cancer consists of radical tumor debulking followed

by adjuvant systemic chemotherapy with carboplatin AUC5 (area under curve) and paclitaxel 175 mg/m² (3). In spite of initial good response rates (up to 75%) of the systemic first-line treatment about 70% of the patients suffer from relapse indicating chronic disease. The typical spread of ovarian cancer is intraperitoneally and therefore, patients often suffer from malignant ascites (17% in stage I and up to 89% in stage III/IV) which is an independent prognostic factor for survival (4) and impairs the quality of life of the patients.

The clinical management of malignant ascites, most commonly treated by repeated paracenteses, may be a huge therapeutic problem. Other therapeutic strategies include intraperitoneal chemotherapy and radioactive labeled monoclonal antibodies (5, 6) and stimulation of the immune system (such as interferon, IFN- γ , IFN- α , Interleukin-2, tumor necrosis factor TNF- α) (7-11). Response rates of classical monoclonal antibodies are very small and they last only for a short time.

New therapeutic strategies are necessary. Most tumors of epithelial origin show an overexpression of EpCAM and in about 90% of ascites samples of ovarian cancer patients, EpCAM-positive tumor cells were detected (12). Thus, the treatment of ovarian cancer patients with an antibody targeting EpCAM seems to be promising.

Recently, we described a therapeutic option by intraperitoneal treatment with the novel trifunctional rat/murine hybrid antibody catumaxomab with bispecificity for the epithelial cell adhesion molecule EpCAM and the T-cell antigen CD3, that represents a new generation of monoclonal antibodies, combining heavy chains of mouse IgG2a and rat IgG2b (13). The trifunctionality has the advantage of binding tumor cells and simultaneously two different immune effector cells (*e.g.* macrophages and T-lymphocytes). The resulting tricell complex leads to different mechanisms of tumor cell killing, such as antibody dependent tumor cell lysis, phagocytosis, apoptosis, cytokine release and perforin mediated lysis (14-16). No costimulation with effector cells was found to be necessary with catumaxomab treatment (17). In a phase I/II trial, a 5 log reduction of ascites

Correspondence to: PD Dr. Pauline Wimberger, Department of Gynecology and Obstetrics, University of Duisburg-Essen, Hufelandstr. 55, 45122 Essen, Germany. Tel: +49 02017232441, Fax: +49 02017235688, e-mail: pauline.wimberger@uk-essen.de

Key Words: Tumor cells, ovarian cancer, ascites, antibody therapy, catumaxomab.

Table I. Tumor and patient characteristics including overall survival.

Patient No.	Age	FIGO stage	G	Line of chemotherapy	Antibody dosage (µg)	Time between diagnosis and AB (mo)	OS from AB (mo)	Time (mo) between AB and next paracentesis	CK+ cells before therapy (BM)	CK+ cells after therapy (BM)	CK+ cells before therapy (PB)	CK+ cells after therapy (PB)
1	47	IV	3	5	10-20-50-200-200	17	7	-	n.d.	n.d.	>100	2
2	71	IIIC	2	4	10-20-50-200-200	21	1	-	n.d.	n.d.	1	0
3	62	IIIC	3	7	10-20-50-200	32	6	-	n.d.	n.d.	0	1
4	57	IIIC	2	4	10-20-50	72	5	-	n.d.	n.d.	1	1
5	70	IV	3	4	10-20-50-50	36	10	-	44	3	0	0
6	70	IIIC	3	3	10-20-50-50	16	23	5	0	20	6	0
7	58	IIIC	3	2	10-20-50-150	14	9	-	0	n.d.	4	3
8	66	IIIC	3	2	10-10	9	1	-	1	n.d.	1	n.d.
9	58	IIIC	3	2	10-20-50-100	8	3	-	8	1	1	0
10	58	IIIC	3	2	10-20-50-100	8	4	2	6	n.d.	4	0
11	46	IIIC	1	2	10-10-10-10	51	27	-	1	0	0	0
12	63	IIIC	3	2	10-20-50-100	10	3	-	0	n.d.	0	n.d.
13	75	IV	2	3	10-20-50-100	25	5	-	4	5	0	0
14	41	IV	3	3	10-10-10-10	24	3	-	1	2	0	1

AB, antibody; BM, bone marrow; CK, cytokeratin; G, grading, OS, overall survival; PB, peripheral blood; CK+, number of cells per 9×10⁶ mononuclear cells (MNC) BM or per 20 ml blood MNC, PB; n.d., not determined.

production was recently demonstrated in heavily pretreated patients with ovarian cancer and malignant ascites after intraperitoneal antibody therapy (13). Furthermore, these data were confirmed within a phase II/III study for different entities with symptomatic ascites resulting in a significant prolongation of puncture free interval after catumaxomab therapy of 52 *versus* 11 days, respectively (*p*<0.0001; catumaxomab treatment *vs.* paracentesis only) (18).

In this study the efficacy of intraperitoneal catumaxomab treatment in ovarian cancer patients with symptomatic ascites, on cytokeratin positive (CK+) cells in the bone marrow (BM) and peripheral blood (PB) was investigated. The data were correlated with the clinical outcome.

Patients and Methods

Patients treatment and study design. The study was performed after obtaining approval from the local ethics committee. After giving written informed consent, patients with primary ovarian cancer and malignant ascites were subjected to PB and BM aspiration before and after catumaxomab treatment. Two bilateral BM samples were obtained under general anesthesia from the upper iliac crests by a needle aspiration within the primary surgery for ovarian cancer. The post-catumaxomab BM aspirations were performed under local anesthesia with Xylocain 1%, and post-catumaxomab treatment PB and BM specimen were collected 2 months after the conclusion of the therapy.

The tumor and patient characteristics are shown in Table I. Fourteen patients with histologically confirmed FIGO (19) stages IIIC-IV ovarian cancer, aged 18 years or older were included in the study. All the patients had a serous papillary histological tumor subtype.

Patients were treated with two to five *i.p.* infusions of catumaxomab in doses from 10 µg up to 200 µg. The applied

antibody dosages are documented in Table I. Minimum interval between the antibody applications was three days. First-line chemotherapy consisted of carboplatin/paclitaxel. Patients received two to seven different chemotherapy lines before entering the study.

Preparation of BM. The BM cells were isolated from heparinized BM (5000 U/ml BM) by Ficoll-Hypaque density gradient centrifugation (density 1.077 g/mol; Pharmacia, Freiburg, Germany) at 400 × g for 30 min. The interface cells were washed (400 × g for 15 min) and resuspended in phosphate buffered saline (PBS). A total of 4.5×10⁶ cells (1.5×10⁶ per slide per area of 240 mm²) from each aspiration side were directly spun onto glass slides (400 × g for 5 min) coated with poly-L-lysine (Sigma, Deisenhofen, Germany) using a Hettich cytocentrifuge (Tuttlingen, Germany).

Preparation of PB. Using Oncoquick® kit (Greiner Bio-One GmbH, Frickenhausen, Germany), 20-25 ml EDTA-blood, drawn by vein puncture, was cooled at 4°C for 1 h, poured into a centrifuge tube and centrifuged at 1600 × g at 4°C for 20 min. Following centrifugation, the complete supernatant above the porous barrier was transferred into a new tube and the cells were washed twice with 50 ml of washing buffer using a centrifugation step at 200 × g at 4°C for 10 min. Subsequently, the cells were resuspended in 2 ml washing buffer and spun onto two glass slides on an area of 240 mm². This method has carefully been evaluated in blood samples of breast cancer patients and has been shown to give reliable results for the detection of circulating tumor cells in PB (20).

Immunocytochemistry. After overnight air drying, staining for CK+ cells was performed using an Epimet® kit (Micromet, Martinsried, Germany). The identification of epithelial cells using this kit is based on the reactivity of the murine monoclonal antibody (Mab) A45-B/B3, directed against a common epitope of CK polypeptides. The kit uses Fab fragments of the pan-Mab complexed with alkaline phosphatase molecules. The method includes: permeabilization of the cells with a

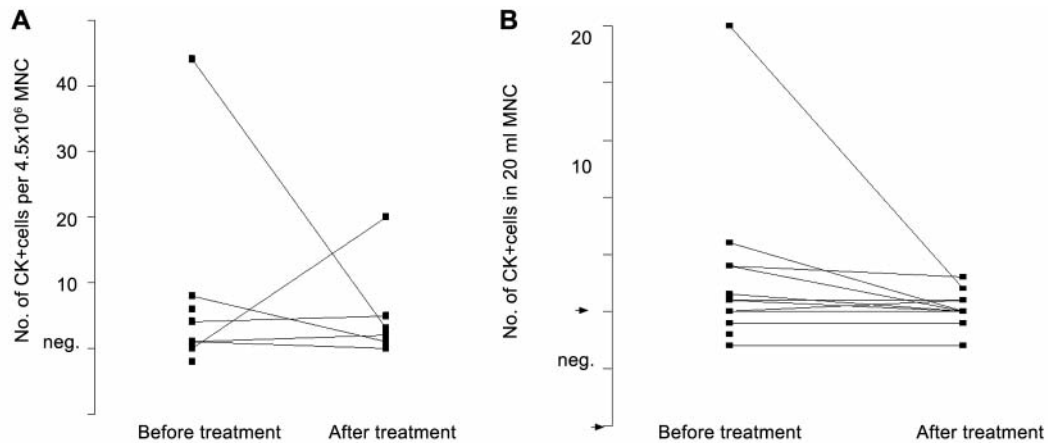


Figure 1. CK+ cells in patients with ovarian cancer undergoing catumaxomab-therapy. A. BM samples. B. PB samples. CK: cytokeratin; MNC: mononuclear cells.

detergent (5 min); fixation with a formaldehyde based solution (10 min); binding of the conjugate Mab A45-B/B3-alkaline phosphatase to cytoskeletal CKs (45 min) and formation of an insoluble red reaction product at the site of binding of the specific conjugate (15 min). Subsequently, the cells were mounted with Kaiser's glycerine/gelatin (Merck, Darmstadt, Germany) in Tris EDTA buffer (Sigma). A negative control antibody (conjugate of Fab-fragment; Micromet, Munich, Germany) served as a negative control. For each test a positive control slide with the carcinoma cell lines MCF-7 (breast) and SKOV-3 (ovary) (American Tissue Culture Collection; ATCC, Rockville, MD, USA) were treated under the same conditions.

Evaluation of CK+ cells. Microscopic evaluation was carried out using an Ariol SL-50 (Applied Imaging, Newcastle upon Tyne, UK), an automated scanning microscope and image analysis system with a slide loader, camera, computer and software for the detection and classification of cells of interest based on particular color, intensity, size, pattern and shape. To use the system, immunostained slides are loaded onto the SL-50 slide loader. The system loads each slide in turn onto the automated microscope stage and scans each frame of the cytospin through red, green and blue filters to recognize candidate objects. These objects are automatically scrutinized by color subtraction, then analyzed and classified by twenty three different morphometric parameters prior to final color ratio analysis. Quantitative data and high-quality images of analyzed objects are presented for review and classification.

Evaluation of data. The patients were classified as tumor cell positive if at least one CK+ cell was detected as analyzed by immunocytochemistry. A marked increase or decrease of disseminated cells was registered if the difference was 2 or more CK+ cells. The overall survival was determined from the start of antibody treatment until the date of death.

Results

Analyses of CK+ cells were performed in the BM of 10/14 patients before and in 6/14 patients after the antibody therapy. As apparent from Table I, CK+ cells were found in

7/10 patients (70%) with a median number of 6 cells / 9×10^6 BM cells (range 1-44) before and in 5/6 patients (83%) with a median of 3 cells / 9×10^6 BM cells (range 1-20) after the catumaxomab treatment, respectively. As illustrated in Figure 1A, in two patients, a marked decrease of CK-positive cells was found (patient No 5 and 9) and in one patient (No 11) no CK+ cells were detected after therapy. In two patients (No 13 and 14), a persistence of CK+ cells was documented and one patient (No 6) with no CK+ cells before treatment had a tumor cell cluster of 20 cells after therapy.

The analyses of the CK+ cells in the PB are also shown in Table I. PB was analyzed in all 14 patients before and in 12/14 patients after the catumaxomab treatment. CK+ cells were found in 8/18 patients (57%) with a median number of 5 cells/20 ml (range 1->100) before and in 5/12 patients (42%) with a median number of 2 cells/20 ml (range 1-3) after the catumaxomab treatment, respectively. In four CK+ patients (No 2, 6, 9, 10), no CK+ cells were found after antibody treatment, two patients showed a persistence of CK+ cells (No 4 and 7) and two patients with no CK+ cells before therapy showed CK+ cells after treatment (No 3 and 14), respectively (illustrated in Figure 1B). In three patients, no CK+ cells were detected at any time point studied. No marked increase of CK-positive cells in the blood was determined after the antibody therapy.

Catumaxomab-treatment resulted in the sustained reduction of ascites flow and arrested ascites reaccumulation. The mean overall survival was 8 months. The mean overall survival after antibody therapy was 8 months (range 1-27 months). Only two patients needed a further paracentesis after 2 and after 5 months, respectively. In this small study population no correlation of marked changes in CK+ cells and outcome was found.

Discussion

New therapeutic strategies in treatment of ovarian cancer are necessary. Thus, the treatment of ovarian cancer patients with catumaxomab, targeting EpCAM, seems to be promising.

In this regard, it has been demonstrated that catumaxomab leads to a simultaneous binding of EpCAM-positive tumor cells, T-cells and accessory cells, thereby resulting in activation of the humoral and cellular immune systems (16, 17). Furthermore, the results of a phase I/ II study with symptomatic ascites in different entities were very promising in 23 heavily pretreated patients where only one patient needed a paracentesis after 4 weeks (13).

In the present study population only two patients needed a further paracentesis 2 months and 5 months, respectively after the end of the catumaxomab therapy, resulting in a median overall survival of eight months (range 1-27 months) after the antibody therapy.

Although the present patient population was small, a systemic effect might have accounted for these observations. The mean cell number of CK+ cells detected before and after antibody therapy in the PB tended to decrease, potentially indicating a systemic effect on the tumor cells. These findings may be important for further clinical trials in the adjuvant setting. In this regard, the persistence of CK+ cells in the BM of patients with ovarian cancer after adjuvant first line chemotherapy with carboplatin and paclitaxel has recently been demonstrated (21). Interestingly, these cells were non-apoptotic and expressed EpCAM on their surface. Therefore, it seems to be reasonable that these patients might benefit from an additive immunotherapy and not only from systemic classical chemotherapy. In addition, treatment with catumaxomab has only moderate side-effects (13, 18). Further analyses and specific characterization of CK+ cells in a bigger study population of patients treated with catumaxomab might be necessary to estimate whether this antibody is effective in targeting circulating and disseminated tumor cells. However, patient selection for tumor biologicals may be more complex due to phenotype changes between the primary lesions and the tumor cells in the PB and BM. There is evidence that expression patterns of individual surface markers on single tumor cells differ from those on the primary tumor (22, 23). Targeted therapy following determination of the phenotype of the circulating cells may overcome the resistance of disseminated tumor cells.

Acknowledgements

No conflict of interest regarding the present work is declared by P. Wimberger, M. Heubner, R. Kimmig and S. Kasimir-Bauer. H. Lindhofer has ownership interest (including patents) (TRION Pharma) and M. Jaeger has fulltime employment (TRION Research).

References

- 1 Yancik P: Ovarian cancer. Age contrasts in incidence, histology, disease stage at diagnosis, and mortality. *Cancer 17(Suppl 2)*: 517-523, 1993.
- 2 Young R, Perez C and Hoskins W: Cancer of the ovary. *In: Cancer-Principles and Practice of Oncology*. De Vita V, Hellman S, Rosenberg S (eds). Philadelphia, PE, JB Lippincott Co., pp. 1993.
- 3 Schink JC: Current initial therapy of stage III and IV ovarian cancer: challenges for managed care. *Semin Oncol 26(Suppl 1)*: 2-7, 1999.
- 4 Shen-Gunther J and Mannel RS: Ascites as a predictor of ovarian malignancy. *Gynecol Oncol 87*: 77-83, 2002.
- 5 Stuart GC, Nation JG, Snider DD and Thunberg P: Intraperitoneal interferon in the management of malignant ascites. *Cancer 71*: 2027-2030, 1993.
- 6 Litvinov SV, Velders MP, Bakker HA *et al*: Ep-CAM: a human epithelial antigen is a homophilic cell-cell adhesion molecule. *J Cell Biol 125*: 437-446, 1994.
- 7 Hirte HW, Miller D, Tonkin K *et al*: A randomized trial of paracentesis plus intraperitoneal tumor necrosis factor-alpha versus paracentesis alone in patients with symptomatic ascites from recurrent ovarian carcinoma. *Gynecol Oncol 64*: 80-87, 1997.
- 8 Stephenson J and Gilbert J: The development of clinical guidelines on paracentesis for ascites related to malignancy. *Palliat Med 16*: 213-218, 2002.
- 9 Smith EM and Jayson GC: The current and future management of malignant ascites. *Clin Oncol (R Coll Radiol) 15*: 59-72, 2003.
- 10 Sartori S, Nielsen I, Tassinari D *et al*: Evaluation of a standardized protocol of intracavitary recombinant interferon alpha-2b in the palliative treatment of malignant peritoneal effusions. A prospective pilot study. *Oncology 61*: 192-196, 2001.
- 11 Kaufmann M, Schmid H, Raeth U *et al*: Therapy of ascites with tumor necrosis factor in ovarian cancer. *Geburtshilfe Frauenheilkd 50*: 678-682, 1990.
- 12 Balzar M, Winter MJ, de Boer CJ *et al*: The biology of the 17-1A antigen (Ep-CAM). *J Mol Med 77*: 699-712, 1999.
- 13 Burges A, Wimberger P, Kumper C *et al*: Effective relief of malignant ascites in patients with advanced ovarian cancer by a trifunctional anti-EpCAM x anti-CD3 antibody: a phase I/II study. *Clin Cancer Res 13*: 3899-3905, 2007.
- 14 Zeidler R, Reisbach G, Wollenberg B *et al*: Simultaneous activation of T cells and accessory cells by a new class of intact bispecific antibody results in efficient tumour cell killing. *J Immunol 163*: 1246-1252, 1999.
- 15 Zeidler R, Mysliwicz J, Csanady M *et al*: The Fc-region of a new class of intact bispecific antibody mediates activation of accessory cells and NK cells and induces direct phagocytosis of tumour cells. *Br J Cancer 83*: 261-266, 2000.
- 16 Riesenberger R, Buchner A, Pohla H *et al*: Lysis of prostate carcinoma cells by trifunctional bispecific antibodies (α EpCAM x α CD3). *J Histochem Cytochem 49*: 1-7, 2001.
- 17 Ruf P and Lindhofer H: Induction of a long-lasting anti-tumour immunity by a trifunctional bispecific antibody. *Blood 98*: 2526-2536, 2001.
- 18 Parsons SL, Kutarska E, Koralewski P, Gore M, Wimberger P *et al*: Treatment of ovarian cancer patients with malignant ascites using the trifunctional antibody catumaxomab: results of a phase II/III study. *J Clin Oncol Suppl*: 5520 (abstract), 2007.

- 19 International Federation of Gynecology and Obstetrics. Changing the definition of clinical staging for carcinoma of the cervix and ovary. *Am J Obstet Gynecol* 156: 263-264, 1987.
- 20 Muller V, Stahmann N, Riethdorf S *et al*: Circulating tumor cells in breast cancer: correlation to bone marrow micrometastases, heterogeneous response to systemic therapy and low proliferative activity. *Clin Cancer Res* 11: 3678-3685, 2005.
- 21 Wimberger P, Heubner M, Otterbach F *et al*: Influence of platinum-based chemotherapy on disseminated tumor cells in blood and bone marrow of patients with ovarian cancer. *Gynecol Oncol* 107: 331-338, 2007.
- 22 Solomayer EF, Becker S, Pergola-Becker G *et al*: Comparison of HER2 status between primary tumor and disseminated tumor cells in primary breast cancer patients. *Breast Cancer Res Treat* 98(2): 179-184, 2006.
- 23 Tewes M, Aktas B, Welt A *et al*: Molecular profiling and predictive value of circulating tumor cells in patients with metastatic breast cancer: an option for monitoring response to breast cancer related therapies. *Breast Cancer Res Treat* 2008; Aug 5. [Epub ahead of print].

Received December 4, 2008

Revised February 9, 2009

Accepted March 16, 2009