Induction Chemotherapy with Docetaxel and Cisplatin Followed by Concomitant Chemoradiotherapy in Patients with Inoperable Non-nasopharyngeal Carcinoma of the Head and Neck

GEORGE FOUNTZILAS[1], ARISTOTELIS BAMIAS[2], ANNA KALOGERA-FOUNTZILA[1], GEORGIA KARAYANNOPOULOU[1], MATTHEOS BOBOS[1], ELENI ATHANASSIOU[3], KONSTANTINE T. KALOGERAS[1,4], CHRISTOS TOLIS[5], PERIKLIS TSEKERIS[5], PAVLOS PAPAKOSTAS[6], CHRYSANTHI VAMVOUKA[7], THOMAS ZARAMBOUKAS[1], PARIS KOSMIDIS[8], NIKOLAOS ZAMBOGLOU[9] and DESPINA MISAILIDOU[1]

[1]*Aristotle University of Thessaloniki School of Medicine, Thessaloniki;*
[2]*Department of Clinical Therapeutics, University of Athens School of Medicine, Athens;*
[3]*Department of Radiation Therapy, "Agios Savvas" Cancer Hospital, Athens;*
[4]*Hellenic Cooperative Oncology Group, Data Office, Athens;*
[5]*Department of Medical Oncology, Ioannina University Hospital, Ioannina;*
[6]*Department of Medical Oncology, "Hippokration" Hospital, Athens;*
[7]*Department of Pathology, "Evangelismos" Hospital, Athens;*
[8]*Second Department of Medical Oncology, "Hygeia" Hospital, Athens, Greece;*
[9]*Department of Radiotherapy, Klinikum Offenbach, Offenbach, Germany*

Abstract. *Background: Induction chemotherapy (IC) followed by concomitant chemoradiotherapy (CCRT) has the potential of being an ideal multi-modality approach for improving the prognosis of patients with squamous cell carcinoma of the head and neck (SSCHN). Patients and Methods: Thirty-four patients with locally advanced SCCHN were treated with 3 cycles of IC, consisting of docetaxel 75 mg/m^2 and cisplatin 75 mg/m^2 every 3 weeks, followed 3-4 weeks later by definitive radiotherapy (70 Gy) and concomitant weekly cisplatin 40 mg/m^2. Results: After a median follow-up of 27.7 months, 6-month progression-free survival (PFS), the primary study end-point, was 84%. The median PFS was 16.4 months and median overall survival 24.4 months. The majority of the patients completed 3 cycles of IC with mild to moderate toxicity. Anemia, nausea/vomiting and mucositis were the prominent toxicities during CCRT. Retrospective analysis of a panel of biomarkers suggested that excision repair cross-complementation group 1 (ERCC1) protein expression was associated with shorter PFS. Conclusion: IC followed by CCRT, as administered in the present study, is a feasible and well-tolerated therapeutic approach. However, its real impact on the prognosis of SCCHN patients has to be demonstrated in a randomized study comparing this treatment to CCRT alone.*

Correspondence to: Professor George Fountzilas, MD, Department of Medical Oncology, "Papageorgiou" Hospital, Aristotle University of Thessaloniki School of Medicine, Thessaloniki, Greece. Tel: +30 2310693959, Fax: +30 2310683136, e-mail: fountzil@med.auth.gr

Key Words: Head and neck cancer, chemotherapy, radiation therapy, docetaxel, ERCC1.

Squamous cell carcinoma of the head and neck (SCCHN) represents the sixth most common form of cancer worldwide, with more than 500,000 cases reported in 2001 (1, 2). Two thirds of the patients present with advanced disease (stage III or IV) and, despite the significant improvements in local management and chemotherapy, there has been no significant increase in long-term survival over the past decades (3). Hence, fewer than 30% of cases presenting with locally advanced disease will be cured, while patients with recurrent or metastatic disease have a median survival rate of no more than 6 months (3, 4). As a result, current research is focused on sequential multi-modality therapeutic approaches that combine different chemotherapy and chemoradiotherapy regimens in an effort to achieve a better outcome for patients with advanced SCCHN.

Radiation therapy (RT), although appearing to have a favorable impact on short-term prognosis in patients with advanced SCCHN, is characterized by only moderate long-term benefit (5-7). The rationale for the addition of

chemotherapy to RT, as a means of increasing efficacy, is to overcome radio-resistance and eradicate any coexistent off-field micrometastases. Indeed, the Meta-Analysis of Chemotherapy in Head and Neck Cancer (MACH-NC) study showed that concomitant chemoradiotherapy (CCRT) is superior to RT alone for patients with advanced SCCHN and should be considered the standard non-surgical treatment in this group of patients (6, 7). Although the chemotherapeutic regimen that is best combined with RT in SCCHN has yet to be defined, the concomitant administration of cisplatin represents a widely accepted choice. Several potential mechanisms through which cisplatin may act as a radiation sensitizer have been reported (reviewed in 8, 9).

The rationale for the use of induction chemotherapy (IC), in general, includes the initial tumor shrinkage that may facilitate the application of local treatment modalities, the early management of micrometastases and improved drug delivery due to the intact tumor vascular bed. The meta-analysis of 31 quite heterogeneous trials in the context of the MACH-HN study indicated no survival advantage at 5 years (7). However, a meta-analysis of a subgroup of the five largest studies with the cisplatin/fluorouracil combination revealed a 5% survival gain at 5 years in favor of the IC (7).

Taxanes represent the most extensively studied novel agents and have recently been incorporated in the treatment of patients with head and neck cancer (10, 11). Given the notable antitumor activity reported in phase II trials in the range of 20%-40%, (12, 13) docetaxel has been tested, in the IC setting, as part of two-drug combinations usually with a platinum compound (cisplatin or carboplatin), or three-drug regimens with a platinum compound and another agent, such as 5-fluorouracil or ifosfamide. These studies have reported high response rates along with promising disease-free and overall survival (OS) rates (11).

Motivated by this information, the Hellenic Cooperative Oncology Group (HeCOG) designed a phase II study to evaluate whether the addition of an induction regimen, with the quite effective docetaxel-cisplatin combination, to a CCRT regimen with cisplatin would be feasible and active in patients with advanced non-nasopharyngeal SCCHN.

Patients and Methods

The primary end-point was 6-month progression-free survival (PFS). Secondary end-points were acute toxicity and OS. A retrospective objective of the study was to also evaluate the prognostic/predictive value of a number of biomarkers.

Eligibility criteria. In order to be eligible for the present study (HE 5/04), all the patients had to have a biopsy-proven previously untreated, stage III or IV (M0), squamous cell carcinoma of the head and neck region, measurable or evaluable disease, no synchronous primary tumors and age ≥18 years. In addition, the patients had to have a performance status (PS) of ≤2 on the Eastern Cooperative Oncology Group (ECOG) scale, adequate bone marrow, hepatic and renal function (creatinine clearance >60 ml/min), and a CT or MRI scan of the head and neck region within 3 weeks prior to the initiation of treatment. The cardiovascular, pulmonary and nutritional status had to be adequate for the patients to tolerate the treatment. Furthermore, the mental status of each patient had to be adequate in order to understand the experimental nature of the study, follow instructions, keep appointments and provide informed consent.

The clinical and collateral translational research protocols were approved by the HeCOG Protocol Review Committee and the Bioethics Committees of the Aristotle University of Thessaloniki School of Medicine and "Hygeia" Hospital. Informed consent was obtained from all the patients prior to study entry.

All the patients were initially evaluated by an ear, nose and throat (ENT) surgeon, a medical oncologist and a radiotherapy oncologist and were staged according to the American Joint Committee on Cancer Staging classification. Initial evaluation included medical history, physical examination, complete endoscopy (with or without esophagography), complete blood count (CBC), blood chemistry, electrocardiogram, chest X-ray, bone scans and liver echography. Resectability, for laryngeal tumors mainly, was determined by the ENT surgeon. Inoperable tumors were considered those with massive extension to the base of the tongue, major involvement of the lateral pharyngeal wall at the level of the oropharynx or hypopharynx and fixed cervical lymph nodes extending to the base of the skull or infiltrating the internal jugular vein. CBC and biochemistry were repeated before each cycle of IC and before the cisplatin administration during CCRT in all the patients.

Treatment. The IC consisted of three cycles of docetaxel 75 mg/m^2 given as a 1-hour infusion with standard premedication, followed by cisplatin 75 mg/m^2 also as a 1-hour infusion with standard pre- and post-hydration. The three cycles of IC were administered every 3 weeks. During the CCRT, cisplatin was administered weekly at a dose of 40 mg/m^2 as a 1-hour infusion, 3-4 hours prior to the RT dose. RT was delivered 3-4 weeks after the completion of the IC with a linear accelerator. Details of the RT technique have been given elsewhere (14). Ondansentron ± dexamethasone was used as antiemetic treatment.

Dose modifications. Doses were adjusted for hematological and non-hematological toxic effects. Once a dose was reduced, escalation of the subsequent doses was not allowed.

Hematological toxicity during IC. The chemotherapy courses were to be given on schedule, provided that the absolute neutrophil count (ANC) was $>1.5\times10^9$/l and the platelet count $>100\times10^9$/l. If the hemoglobin was less than 10.5 g/dl chemotherapy was given on time along with blood transfusion and/or erythropoietin. If the ANC was $<1.5\times10^9$/l granulocyte colony-stimulating factor (G-CSF) was given for 5 days and chemotherapy was delayed by one week.

Additionally, if the platelet count was $\leq100\times10^9$/l chemotherapy was delayed. A maximum of two weeks delay was allowed for platelet recovery, at which point the patient was taken off the protocol if the platelet count was still $\leq100\times10^9$/l. If only a one-week delay was required, the next chemotherapeutic courses were given every 4 weeks. If a two-week delay was required, the next chemotherapeutic courses were given every 4 weeks with a 25% reduction in the dose of docetaxel. No regular blood counts were requested between courses.

Table I. *Primary antibodies and immunohistochemistry staining procedures.*

Antigen (antibody type)	Clone (source)	Pretreatment/ Time	Ab dilution	Incubation time	Staining pattern	Scoring system reference
Cyclin D1 (r)	SP4 (1)	HIER/20'	1:45	30'	N and N/C	18
EGFR (m)	31G7 (2)	Proteinase K/10'	1:50	30'	M/C	19
ERCC1 (m)	8F1 (3)	HIER/30'	1:450	30'	N	20
HER2 (pc, r)	(4)	HIER/20'	1:100	20'	M and M/C	HercepTest
Phospho-mTOR [Ser2448](m)	(5)	HIER/30'	1:30	30'	PN/C	21
Phospho-Akt [Ser473](r)	736E11 (5)	HIER/30'	1:150	o/n	C and C/N	22
PTEN (m)	6H2.1 (4)	HIER/30'	1:300	60'	C and C/N	23

C: cytoplasmic; HIER: heat-induced epitope retrieval; M: membranous; m: mouse; N: nuclear; o/n, overnight; pc: polyclonal; PN: peri-nuclear; r: rabit; EGFR: epidermal growth factor receptor; ERCC1: excision repair cross-complementation group 1; HER2: human epidermal growth factor receptor-2; phospho-mTOR: phosphorylated mammalian target of rapamycin; phospho-Akt; PTEN: phosphatase and tensin homologue deleted on chromosome 10. Antibody sources: (1) Spring Bioscience, Fremont, CA, USA; (2) Zymed, (Invitrogen), Carlsbad, CA, USA; (3) Neomarkers, Fremont, CA, USA; (4) CST, Danvers, MA, USA; (5) Dako, Glostup, Denmark.

The following dose modifications were performed according to the nadir value of the platelet count. If the platelet count was $>50\times10^9$/l no dose reduction was recommended. If the platelet count was $25\text{-}50\times10^9$/l, a 25% dose reduction of all the drugs was proposed. For grade IV thrombocytopenia (platelet count $<25\times10^9$/l) a 50% dose reduction was recommended.

Hematological toxicity during CCRT. Cisplatin was administered, in all subsequent courses, at the full dose in cases of grade 1 or grade 2 hematological toxicity, at 80% of the initially planned dose in cases of grade 3 and at 60% in cases of grade 4 toxicity. The prophylactic administration of G-CSF during CCRT was allowed. Non-hematological toxicity during IC and CCRT. The cisplatin dose was reduced by 25% for each 20 ml/min reduction of the creatinine clearance. If creatinine clearance was <30 ml/min, the treatment was delayed for 2 weeks maximum for recovery, otherwise the patient was taken off the study. In cases of mucositis with vesiculation and/or ulcer WHO grade >2, the cisplatin dose was reduced by 20% and G-CSF was administered. In cases of neurological toxicity WHO grade >2 (intolerable paresthesias and/or marked motor loss), chemotherapy was discontinued.

In cases of symptomatic arrhythmias, AV (artrial venticular) block (except 1st degree) or other heart blocks, treatment with docetaxel was stopped and the arrhythmia was managed according to standard practice. In cases of other major organ toxicity that were not evaluated as disease-related, except alopecia and nausea WHO grade >2, the chemotherapy was interrupted permanently.

Tissue microarray (TMA) construction. Formalin-fixed paraffin-embedded tumor tissue was used for protein and gene analysis. Representative slides (H&E) from the tissue blocks were reviewed by two pathologists (G.K. and M.B.) for confirmation of the diagnosis, adequacy of material and calculation of the percentage of tumor in each case. Thirteen of the specimens were arrayed (2 cores per case, 1.5 mm in diameter) into each recipient paraffin block (Paraplast®, McCormick, St. Louis, MO, USA) using a manual arrayer (Beecher Instruments, Sun Prairie, WI, USA). The TMA block also included cores from normal skin, tonsil and colon tissue and thyroid carcinoma tissue as positive controls.

Immunohistochemistry (IHC). Immunohistochemical labeling was performed according to standard protocols with slight modifications (15) on serial 3 μm-thick sections, from the original blocks or the TMA block (Table I). As previously reported (16-17), the reproducibility of TMA immunostaining of different proteins compared to that obtained from whole sections of the original paraffin blocks is very high. The deparaffinization, antigen retrieval and staining procedures for cyclin D1, EGFR (epidermal growth factor receptor), ERCC1 (excision repair cross-complementation group 1), HER2 (epidermal growth factor receptor-2), and phospho-mTOR (phosphylated mammalian target of rapamycin) (Ser2448) were performed using a Bond Max™ autostainer (Visionbiosystems, Mount Waverley VIC, Australia).

For phospho-Akt (Ser473) and PTEN (phosphatase and tensin homologue deleted on chromosome 10), after deparaffinization, blocking of endogenous peroxidase activity, antigen unmasking by heating the slides in EDTA retrieval solution (ER2, Visionbiosystems), and protein blocking (ProteinBlock, BioGenex, San Ramon, CA, USA), the staining procedures were performed using an automated staining instrument i6000 (BioGenex). The antigen-antibody complex was visualized using the HRP (horseradish peroxidase) super sensitive detection system (BioGenex), with DAB (Dako, Glostup, Denmark) as a chromogen and Mayer's hematoxylin (BioGenex) as a counter-stain. All the stained sections were compared with appropriate positive control sections.

The evaluation of all the IHC sections was conducted simultaneously by two observers, (G.K. and M.B.), blinded as to the patients' clinical characteristics and survival data, according to previously proposed/established criteria (18-23) and staining procedures (Table I). Briefly, for cyclin D1 the intensity of nuclear staining was assessed in relation to normal cells present in the tissue sections. The presence of staining in more than 5% of the tumor cells was considered as positive and evaluated using a four graded scale: 0-5% =0; 6-25% =1; 26-50% =2; >51% =3 (18). EGFR intensity of reactivity was scored using a four-tier system: 0 (negative), no staining or background staining; 1+ definitive cytoplasmic staining and/or equivocal discontinuous membrane staining; 2+ moderate unequivocal membrane staining; 3+ strong and complete membrane staining. The cases were considered positive when more than 10% of

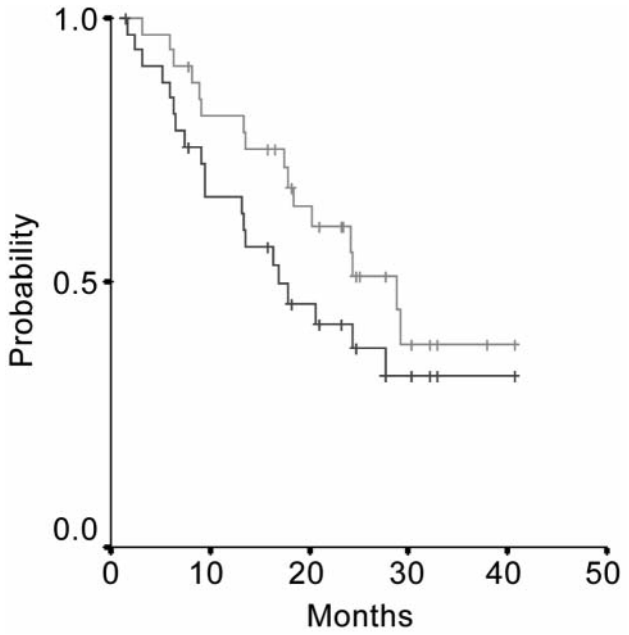

Figure 1. *Progression-free (——) and overall (——) survival in all patients.*

the tumor cells showed at minimum 1+ staining, while 2+ or 3+ staining was classified as EGFR protein overexpression (19). The ERCC1 evaluation of nuclear staining was conducted according to the criteria proposed by Olaussen *et al.* (20). The above system was based on a semi-quantitative H (histo) score, which combines the stain intensity and the percentage of positive tumor cells. The median of all the H scores was chosen as the cut-off point for separating positive from negative cases. HER2 protein expression was scored according to the established breast IHC HercepTest protocol (DakoCytomation). Phospho-mTOR protein expression was considered positive when >10% of the tumor cells showed peri-nuclear and/or cytoplasmic staining (21). For phospho-Akt, an intensity-adjusted scoring system (combining percentage and intensity of staining) was used according to Tang *et al.* (22). PTEN protein expression (cytoplasmic, nuclear or both) was evaluated according to a previously established rank scale of 0 to 2 (23). Vascular endothelial cells were used as a control marker of staining intensity. Tumors with PTEN scores of 0 or 1 were considered to have PTEN loss.

Fluorescence in situ hybridization (FISH). The TMA sections or whole sections (4 μm-thick) were used for FISH analysis. Commercially available probes for the *EGFR* gene (LSI® EGFR/CEP7 Dual Color Probe, Abbott Molecular, Abbott Park, IL, USA) and *HER2* gene (PathVysion HER2 DNA Probe Kit, Abbott Molecular) were used. The procedures were performed according to the manufacturer's instructions with slight modifications. Hybridization signals were enumerated using a Zeiss fluorescence microscope (Axioskop 2 plus HBO 100, Zeiss, Göttingen, Germany) equipped with high quality objectives, an appropriate filter set and a computerized imaging system (FISH Imager™ Metasystems, Altlussheim, Germany).

For the evaluation of *EGFR* and *HER2* gene status, 60 non-overlapping nuclei from the invasive part of the tumor were

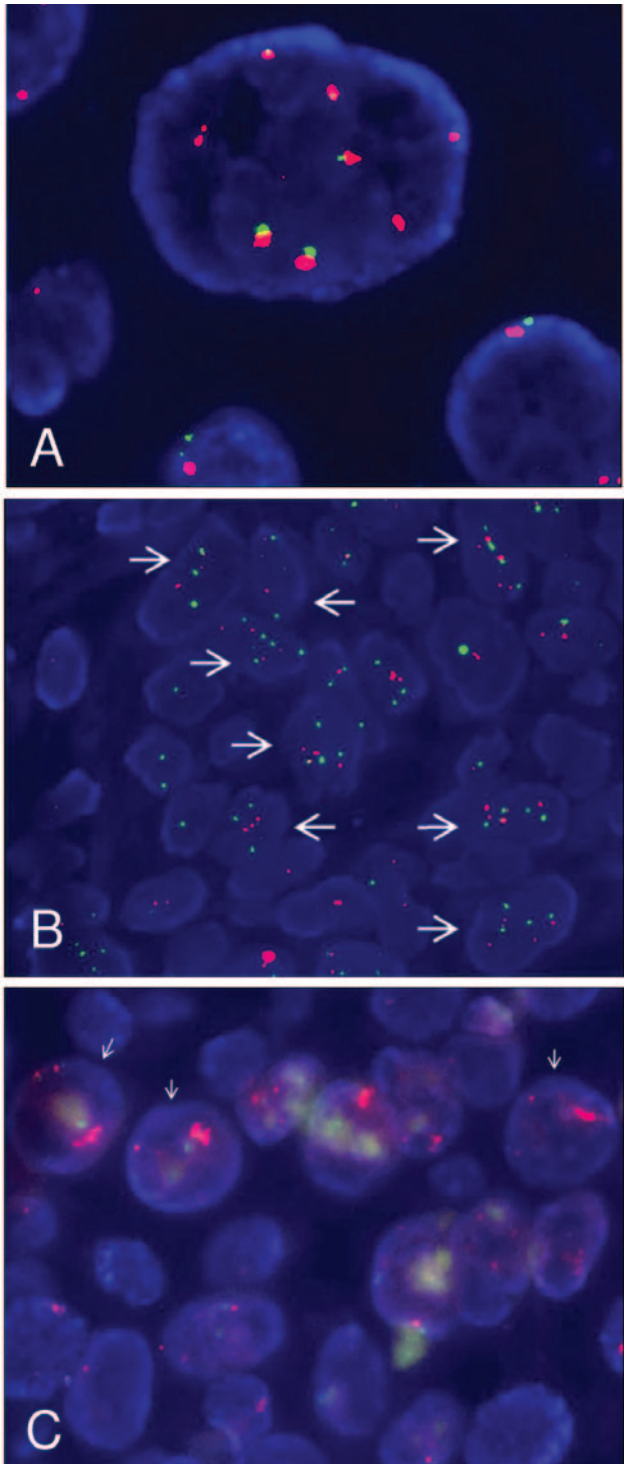

Figure 2. *Fluorescence in situ hybridization (FISH) with gene and centromeric-specific probes performed on tissue microarray sections. A, Neoplastic nucleus with extra copies of chromosome 7 (CEP7, green signals), and EGFR gene gain (red signals); B, Representative case with neoplastic nuclei showing trisomy or polysomy of chromosome 17 (CEP17, green signals) and HER2 gene gain (red signals) (arrows). C, Neoplastic nuclei showing EGFR gene amplification (arrows);*

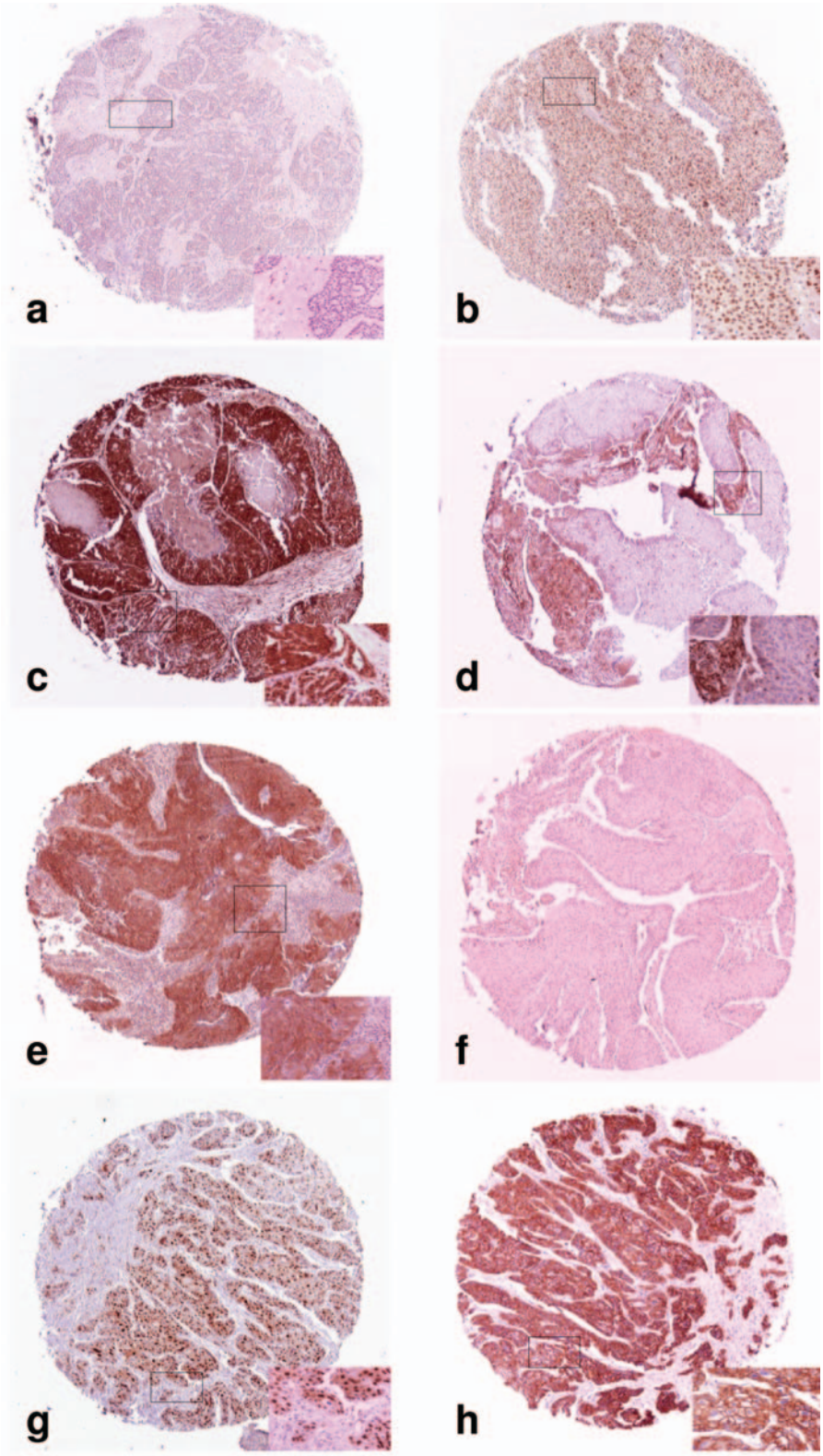

Figure 3. *Protein expression detected by IHC in tissue microarrays. a, ERCC1 absence in neoplastic cells, while the protein is present in the nuclei of stromal fibroblasts; b, ERCC1 strong nuclear positivity; c, PTEN strong nuclear and cytoplasmic immunoreactivity; d, PTEN protein loss; e, phospho-Akt^{Ser473} intense cytoplasmic staining; f, phospho-Akt^{Ser473} lack of immunoreactivity; g, cyclin D1 strong, predominantly nuclear protein expression; h, EGFR intense complete membranous staining (original magnification ×40; insets ×200).*

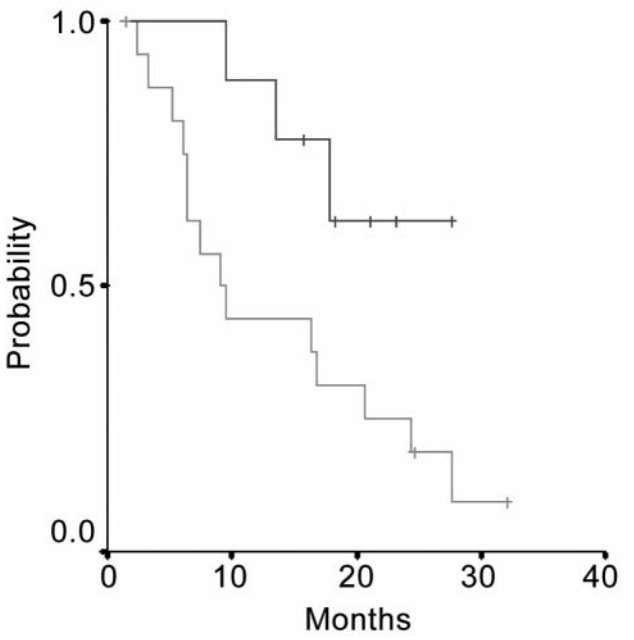

Figure 4. *Progression-free survival in patients with ERCC1 protein expression (——) or absence of ERCC1 expression (-----) in neoplastic cells (p=0.033, Bonferroni adjusted p=0.165).*

Table II. *Patient characteristics (N = 33).*

Age (years)		
Median	58	
Range	38-73	
	N	%
Gender		
Men	28	85
Women	5	15
Performance status		
0	16	48
1	16	48
2	1	3
Primary site		
Oral cavity	13	39
Larynx	11	33
Oropharynx	7	21
Hypopharynx	2	6
Stage		
III	10	30
IV	23	70
Tumor grade		
I	6	18
II	16	48
III	5	15
Undifferentiated	2	6
Unknown	4	12

selected randomly and scored. Images were captured by a computer-controlled digital camera and processed with a software system (FISH Imager). FISH patterns for EGFR/CEP7 (centromeric probe) were defined as previously described (24) with slight modifications. The samples were grouped as: normal if ≤2 CEP7 copies and ≤2 gene copies were found in more than 90% of the tumor cells; trisomy, 3 CEP7 copies and 3 gene copies in >10% of the tumor cells; low level gene gain, ≥4 gene copies in ≥10 and <40% of the tumor cells; and as high level gene gain, ≥4 gene copies in ≥40% of the tumor cells. For EGFR/CEP7, the gene was thought to be amplified when the ratio of the respective gene probe/centromere probe was ≥2.0, or ≥15 gene copies were found in ≥10% of cells. As for HER2/CEP17, the gene was thought to be amplified when the ratio of the respective gene probe/centromere probe was ≥2.0 (25, 26).

Statistical analysis. Sample size calculation was based on the 6-month PFS rate. According to Fleming's single-stage design, assuming that the 6-month PFS rate that would warrant further evaluation of the regimen would be at least 75% *versus* an unacceptable rate of 55%, a sample of 35 patients would be needed for a trial with 80% power, with a one-sided a=5%.

OS was measured from trial initiation to death or last follow-up, while PFS was measured from trial initiation to documented disease progression or death. OS and PFS distributions were evaluated using the Kaplan-Meier method and comparisons, according to the expression of several biomarkers, were performed using the log-rank test. Any association between the related biomarkers was assessed using Fisher's exact test. In order to account for multiple comparisons, Bonferroni adjusted *p*-values were calculated and presented where appropriate.

Results

In total, 37 patients entered the study. Four patients were considered non-eligible, three because they did not start protocol treatment and one patient because he had oropharyngeal stage II (T2N2M0) cancer. The important patient characteristics are shown in Table II.

The majority of the patients presented with stage IV disease. The most frequently involved primary site was the oral cavity. Selected treatment characteristics are shown in Table III. Thirty of the 33 eligible patients completed three cycles of IC. One alcohol-dependent patient was hospitalized after the second IC cycle for portal hypertension and refused to continue further treatment, while two more patients withdrew consent after the first IC cycle. Of the 30 patients that completed IC, one demonstrated progressive disease prior to the initiation of CCRT and was taken off the study. Two patients refused to receive CCRT treatment, while two more underwent surgery prior to the initiation of CCRT and discontinued treatment. Six additional patients never received CCRT, mainly due to poor general health status. Nevertheless, these 11 patients were treated with RT off protocol. Therefore, a total of 30 patients were treated with RT, even though only 19 of them received CCRT. Dose reduction of weekly cisplatin was required in eight of the 19 patients treated with CCRT. The median relative dose intensity of both cisplatin and docetaxel during IC was 0.98. During CCRT, 11 patients received 7 weekly doses of cisplatin.

Table III. *Treatment characteristics during induction chemotherapy.*

Number of patients (N)	33	
Number of cycles per patient	N	%
1	2	6
2	1	3
3	30	91
Total number of cycles delivered	94	
Median (range)	3 (1-3)	
Number of cycles with docetaxel at full dose	87 (93%)	
Number of cycles with cisplatin at full dose	79 (84%)	
DI of docetaxel		
Median delivered	24.5	
Range	20-27	
Relative DI of docetaxel		
Median delivered	0.98	
Range	0.80-1.08	
DI of cisplatin		
Median delivered	24.5	
Range	16-27	
Relative DI of cisplatin		
Median delivered	0.98	
Range	0.65-1.08	

DI; Dose intensity (mg/m^2/week)

Table IV. *Worst toxicity (%) during induction chemotherapy (WHO criteria).*

	Grade 1	Grade 2	Grade 3
Nausea/vomiting	25	6	0
Anemia	25	6	0
Neutropenia	6	0	0
Allergic reaction	6	6	0
Peripheral neuropathy	6	0	0
Stomatitis	12	0	0
Diarrhea	6	0	0
Constipation	25	6	0
Infection	6	0	0
Fatigue	19	12	6

Table V. *Worst toxicity (%) during CCRT (RTOG, Radiation Therapy Oncology Group criteria).*

	Grade 1	Grade 2	Grade 3
Nausea/vomiting	24	9	6
Anemia	36	18	0
Neutropenia	9	12	6
Leucopenia	6	24	0
Thrombocytopenia	6	12	6
Allergic reaction	6	6	0
Dysphagia	0	30	6
Dermatitis	0	18	12
Mouth dryness	6	30	6
Mucositis	12	18	12
Alopecia	6	0	0
Fatigue	6	0	6
Fever	0	6	0

The combined modality treatment was generally well tolerated. The side-effects during IC or CCRT are shown in Tables IV and V. The majority of the patients completed 3 cycles of IC with mild to moderate toxicity. Anemia, nausea/vomiting and mucositis were the prominent side-effects during CCRT.

After a median follow-up of 27.7 months (range 1.5-40.7), 21 patients demonstrated tumor progression and 17 had died. One patient was lost to follow-up. The six-month PFS rate was 85%. The median PFS was 16.4 months (range 1.5-40.7, 95% confidence interval [CI] 10.9-21.9), while the median OS was 24.4 months (range 1.5-40.7, 95% CI 14.4-34.5) (Figure 1). The one-year PFS rate was 63%, while the 1-year and 2-year survival rates were 78% and 52%, respectively.

Adequate tissue for the translational research studies was available from 26 out of the 34 eligible patients. Patient characteristics, survival and protein and gene expression of the 26 patients that had IHC and FISH data are shown in Table VI. *HER2* gene amplification was not observed in any of the cases, while 3 tumors (12%) demonstrated moderate (2+) expression of the HER2 protein. EGFR protein was overexpressed (2+ or 3+) in 24/26 patients (92%), with the corresponding gene being amplified in 4 patients (15%), three of whom had high level gene gain (12%). Disomy was observed in 12 patients (46%) and trisomy in 6 (23%). In one case, the number of the *EGFR* gene copies was non-evaluable. Representative EGFR and HER2 FISH images are shown in Figure 2.

ERCC1 protein was expressed in 17/26 patients (65%), PTEN in 8/26 patients (31%), and phospho-mTOR in 5/26 patients (19%), while cyclin D1 and phospho-Akt were expressed in 16 patients each (62%). Thirteen out of the 16 cyclin D1 protein-positive cases were also phospho-Akt-positive (p=0.015, Bonferroni adjusted p=0.075). No other association between the markers under investigation was indicated by the data. Representative immunohistochemical stains for most of the proteins evaluated are shown in Figure 3.

The patients expressing the ERCC1 protein had a shorter PFS (median 9.1 months, range 1.5-32.1+) compared to the patients with no ERCC1 protein expression (median not reached yet, range 9.5-27.7) (p=0.033, Bonferroni adjusted p=0.165) (Figure 4). PTEN, phospho-Akt, phospho-mTOR, and cyclin D1 were not found to be associated with PFS. Survival was not found to be associated with ERCC1 protein expression or the expression of any other biomarker.

Discussion

The present study clearly demonstrated that IC with three cycles of docetaxel and cisplatin followed by CCRT had significant activity in patients with locally advanced SCCHN

TableVI. *Patient characteristics, survival and protein and gene expression of a cohort of 26 patients with SCCHN.*

Age (years)	Gender	Grade	Survival (months)	PFS (months)	EGFR (IHC)	EGFR (FISH)	HER2 (IHC)	HER2 (FISH)	PTEN (IHC)	Phospho-Akt (IHC)	Phospho-mTOR (IHC)	Cyclin D1 (IHC)	ERCC1 (IHC)
60	M	I	LF	LF	3+	NA	1+	NA	NO LOSS	+	+	–	+
59	M	II	17	2	3+	NA	0	NA	NO LOSS	–	–	–	+
59	M	NS	3	3	3+	NA	2+	NA	LOSS	–	–	+	+
58	M	II	9	5	2+	NA	0	NA	LOSS	+	+	+	+
51	M	I	8	6	2+	NA	2+	NA	LOSS	+	–	+	+
61	M	II	6	6	2+	NA	1+	NA	LOSS	–	–	–	+
71	M	III	6	6	3+	NA	1+	NA	LOSS	+	–	+	+
44	M	II	16+	7	1+	NA	0	NA	LOSS	–	–	–	+
57	M	II	38+	9	3+	NA	0	NA	LOSS	+	–	+	+
51	M	II	8	9	3+	NA	0	NA	LOSS	–	–	–	+
69	M	III	18	9	3+	NA	0	NA	LOSS	–	–	–	+
69	M	III	20	9	3+	A	0	NA	NO LOSS	+	–	+	–
45	M	I	13	13	3+	NA	1+	NA	LOSS	+	+	+	–
47	W	II	24	16	3+	NA	1+	NA	LOSS	+	–	+	+
54	M	II	18	17	3+	NA	0	NA	LOSS	–	–	+	–
57	W	II	25+	21	3+	NA	1+	NA	LOSS	+	–	+	+
56	M	I	24	24	3+	A	0	NA	NO LOSS	+	–	+	+
64	M	II	29	27	2+	NA	0	NA	LOSS	+	–	+	+
69	M	NS	16+	16+	1+	NA	1+	NA	NO LOSS	+	–	+	–
65	M	III	16+	16+	3+	A	1+	NA	NO LOSS	+	+	+	–
50	M	III	18+	18+	3+	A	0	NA	LOSS	–	–	+	–
73	W	II	21+	21+	2+	NA	1+	NE	LOSS	–	+	–	–
42	M	II	23+	23+	3+	NA	1+	NA	NO LOSS	–	–	–	–
61	W	I	25+	25+	3+	NA	0	NA	LOSS	+	–	+	+
50	M	UND	28+	28+	3+	NA	2+	NA	NO LOSS	+	–	–	–
46	W	NS	32+	32+	3+	NA	0	NA	LOSS	+	–	–	+

M: Man; W: woman; NS: non-specified; UND: undifferentiated; LF: lost to follow-up; NA: non-amplified; A: amplified; NE: non-evaluable; IHC: immunohistochemistry; (+) positive; (–) negative; FISH: fluorescence *in situ* hybridization.

with a 6-month PFS rate of 84%. This end-point was selected as primary, instead of the more traditional response rate, because quite often in SCCHN the assessment of response to treatment by imaging techniques is not accurate. It is common for radiologists to characterize some patients as having a partial and not complete response, because of residual abnormalities in post-treatment CT scans, even if they had been free of disease for a long time. For this reason, several investigators (27) have supported the adoption of locoregional control as a more reliable end-point as opposed to complete response, when the activity of a new treatment in being evaluated in such patients.

Treatment-related toxicity is a major concern in these patients, when IC is planned as a component of a multimodality treatment. In the present study, toxicity from the combined modality regimen was generally manageable. During IC, the side-effects were of mild to moderate severity. In contrast to the high neutropenia rates reported by others with the same combination (28), severe neutropenia was not seen in our patients. In a randomized phase II study in SCCHN patients (29), using docetaxel combined with cisplatin (at slightly higher doses) or fluorouracil, severe neutropenia was recorded in 34% and febrile neutropenia in 17% of the patients. Even though the cost of the treatment may be increased with the use of G-CSF, specific cost analysis studies are needed to determine whether the use of G-CSF is cost effective. Furthermore, CCRT induced moderate to severe toxicity in approximately 40% of our patients, similar to that reported by others using weekly cisplatin concomitantly with RT (9). Neutropenia, nausea/vomiting and mucositis were the prominent side-effects with the present CCRT regimen.

The retrospective biomarker evaluation resulted in interesting findings. EGFR protein overexpression was observed in 92% of the patients, a finding that has been consistently reported in the literature (29). The rate of protein expression of PTEN, phospho-Akt and cyclin D1 was in line with that previously reported. For example, PTEN expression was found in 45% of oral carcinomas (30), while phospho-Akt and cyclin D1 were frequently expressed (in the range of 43% to 61%) in SCCHN (31, 32).

EGFR gene amplification was identified in 4 (15%) of the tumors. In a recently published study, *EGFR* gene copy number alterations have been observed in approximately 10% of SCCHN tumors and were associated with poor

clinical outcome (33). Furthermore, it has been demonstrated that EGFR protein overexpression is not necessarily accompanied by gene amplification (34), which was the case in the present study. Results regarding *HER2* gene amplification in SCCHN are often contradictory. Some investigators have demonstrated increased *HER2* gene copy numbers, while others, in agreement with our findings, have found no evidence of gene amplification (34).

Interestingly, the present study is one of the first to report an association between ERCC1 protein expression and survival in patients with SCCHN. The *ERCC1* gene is one of 16 genes encoding for proteins of the nucleotide excision repair complex, which removes cisplatin-induced DNA adducts (35). ERCC1 was shown in a randomized study (17) to be a significant predictive factor in patients with completely resected non-small cell lung cancer (NSCLC) treated with cisplatin-based adjuvant chemotherapy. In that study, only patients with ERCC1-negative tumors benefited from the treatment. Information regarding the role of ERCC1 in SCCHN is very limited. Recently, Handra-Luca *et al*. (36) reported 71% ERCC1 protein expression in 96 SCCHN patients treated with cisplatin-based IC, using the same scoring criteria as us. Low ERCC1 expression was associated with higher rates of tumor response (79% *vs*. 56%, p=0.04) and lower risk of cancer-specific death (risk ratio 0.42, p=0.04). Additionally, at the 2007 Annual Meeting of the American Society of Clinical Oncology, Jun *et al*. (37) reported 54% ERCC1 protein expression in 44 patients with locally advanced SCCHN treated with cisplatin-based CCRT. As in the previous study (36), ERCC1 expression was associated with poor outcome. In the present study, ERCC1 protein expression was observed in 70% of the tumors and it was significantly associated with shorter PFS (even though significance was lost when the p-value was adjusted by the Bonferroni test), but not with OS. It appears therefore, that in SCCHN as in NSCLC, ERCC1 is a biomarker predictive of resistance to cisplatin.

Importantly, it has to be kept in mind that the small number of tumors assessed in the present study and the multiple markers tested preclude any robust statistical association between the expression of these biomarkers and clinical outcome. Our findings should therefore be viewed as hypothesis generating, rather than definitive, stimulating further research in this area with a large number of tumor samples and adequate follow-up. In fact, we are currently performing such a prospective verification study using tissue microarray technology in a large cohort of patients with operable laryngeal cancer.

In conclusion, the present study met its primary end-point of achieving a 6-month PFS rate of over 75% in patients with SCCHN, with manageable toxicity. However, the promising efficacy shown by the combined modality approach needs to be proven in a phase III study with a CCRT arm serving as control. ERCC1 appears to be a potentially important predictive biomarker, although its true value has to be assessed and validated in prospective clinical trials.

Acknowledgements

The authors wish to thank Georgia Vourli, M.Sc. for the statistical analysis, Dimitra Aivazi, MD and Sophia Chrisafi, Ph.D. for their excellent technical assistance, Ms. Evita Fragou for monitoring the study, Ms. Maria Moschoni for coordinating the data management, and Ms. Stella Dallidou for her secretarial assistance. Supported by the HeCOG research grant HE R_5/04.

References

1 Greenlee RT, Hill-Harmon MB, Murray T and Thun M: Cancer statistics, 2001. CA Cancer J Clin *51*: 15-36, 2001.
2 Monnerat C, Faivre S, Temam S, Bourhis Jand Raymond E: End-points for new agents in induction chemotherapy for locally advanced head and neck cancers. Ann Oncol *13*: 995-1006, 2002.
3 Kim ES, Kies M and Herbst RS: Novel therapeutics for head and neck cancer. Curr Opin Oncol *14*: 334-342, 2002.
4 Vokes EE, Weichselbaum RR, Lippman SM and Hong WK: Head and neck cancer. N Engl J Med *328*: 184-194, 1993.
5 Jeremic B, Shibamoto Y, Stanisavljevic B, Milojevic L, Milicic B and Nikolic N: Radiation therapy alone or with concurrent low-dose daily either cisplatin or carboplatin in locally advanced unresectable squamous cell carcinoma of the head and neck: a prospective randomized trial. Radiother Oncol *43*: 29-37, 1997.
6 Argiris A: Update on chemoradiotherapy for head and neck cancer. Curr Opin Oncol *14*: 323-329, 2002.
7 Pignon JP, Bourhis J, Domenge C and Designe L: Chemotherapy added to locoregional treatment for head and neck squamous-cell carcinoma: three meta-analyses of updated individual data. MACH-NC Collaborative Group. Meta-Analysis of Chemotherapy on Head and Neck Cancer. Lancet *355*: 949-955, 2000.
8 Seiwert TY, Salama JK and Vokes EE: The concurrent chemo-radiation paradigm – general principles. Nat Clin Pract Oncol *4*: 86-100, 2007.
9 Seiwert TY, Salama JK and Vokes EE: The chemoradiation paradigm in head and neck cancer. Nat Clin Pract Oncol *4*: 156-171, 2007.
10 Fountzilas G, Tolis C, Kalogera-Fountzila A, Karanikiotis C, Bai M, Misailidou D, Samantas E, Athanassiou E, Papamichael D, Tsekeris P, Catodritis N, Nicolaou A, Plataniotis G, Makatsoris T, Papakostas P, Zamboglou N and Daniilidis J: Induction chemotherapy with cisplatin, epirubicin, and paclitaxel (CEP), followed by concomitant radiotherapy and weekly paclitaxel for the management of locally advanced nasopharyngeal carcinoma. A Hellenic Cooperative Oncology Group Phase II study. Strahlenther Onkol *181*: 223-230, 2005.
11 Posner M: Evolving strategies for combined-modality therapy for locally advanced head and neck cancer. Oncologist *12*: 967-974, 2007.
12 Couteau C, Chouaki N, Leyvraz S, Oulid-Aissa D, Lebecq A, Domenge C, Groult V, Bordessoule S, Janot F, De Forni M and Armand JP: A phase II study of docetaxel in patients with metastatic squamous cell carcinoma of the head and neck. Br J Cancer *81*: 457-462, 1999.
13 Dreyfuss AI, Clark JR, Norris CM, Rossi RM, Lucarini JW, Busse PM, Poulin MD, Thornhill L, Costello R and Posner MR: Docetaxel: an active drug for squamous cell carcinoma of the head and neck. J Clin Oncol *14*: 1672-1678, 1996.

14 Fountzilas G, Tolis C, Kalogera-Fountzila A, Misailidou D, Tsekeris P, Karina M, Nikolaou A, Samantas E, Makatsoris T, Athanassiou E, Skarlos D, Bamias A, Zamboglou N, Economopoulos T, Karanastassi S, Pavlidis N and Daniilidis J: Paclitaxel, cisplatin, leucovorin, and continuous infusion fluorouracil followed by concomitant chemoradiotherapy for locally advanced squamous cell carcinoma of the head and neck: a Hellenic Cooperative Oncology Group Phase II Study. Med Oncol *22*: 269-279, 2005.
15 Dabbs DJ (ed.): Diagnostic Immunohistochemistry, 1st edition. Churchill Livingstone: Philadelphia, PA. p39, 2002.
16 Skacel M, Skilton B, Pettay JD and Tubbs RR: Tissue microarrays: a powerful tool for high-throughput analysis of clinical specimens: a review of the method with validation data. Appl Immunohistochem Mol Morphol *10*: 1-6, 2002.
17 Camp RL, Charette LA and Rimm DL: Validation of tissue microarray technology in breast carcinoma. Lab Invest *80*: 1943-1949, 2000.
18 Palmqvist R, Stenling R, Oberg A and Landberg G: Expression of cyclin D1 and retinoblastoma protein in colorectal cancer. Eur J Cancer *34*: 1575-1581, 1998.
19 Hanawa M, Suzuki S, Dobashi Y, Yamane T, Kono K, Enomoto N and Ooi A: EGFR protein overexpression and gene amplification in squamous cell carcinomas of the esophagus. Int J Cancer *118*: 1173-1180, 2006.
20 Olaussen KA, Dunant A, Fouret P, Brambilla E, Andre F, Haddad V, Taranchon E, Filipits M, Pirker R, Popper HH, Stahel R, Sabatier L, Pignon JP, Tursz T, Le Chevalier T and Soria JC: DNA repair by ERCC1 in non-small cell lung cancer and cisplatin-based adjuvant chemotherapy. N Engl J Med *355*: 983-991, 2006.
21 Peponi E, Drakos E, Reyes G, Leventaki V, Rassidakis GZ and Medeiros LJ: Activation of mammalian target of rapamycin signalling promotes cell cycle progression and protects cells from apoptosis in mantle cell lymphoma. Am J Pathol *169*: 2171-2180, 2006.
22 Tang JM, He QY, Guo RX and Chang XJ: Phosphorylated Akt overexpression and loss of PTEN expression in non-small cell lung cancer confers poor prognosis. Lung Cancer *51*: 181-191, 2006.
23 Perren A, Weng LP, Boag AH, Ziebold U, Thakore K, Dahia PL, Komminoth P, Lees JA, Mulligan LM, Mutter GL and Eng C: Immunohistochemical evidence of loss of PTEN expression in primary ductal adenocarcinomas of the breast. Am J Pathol *155*: 1253-1260, 1999.
24 Chung CH, Ely K, McGavran L, Varella-Garcia M, Parker J, Parker N, Jarrett C, Carter J, Murphy BA, Netterville J, Burkey BB, Sinard R, Cmelak A, Levy S, Yarbrough WG, Slebos RJ and Hirsch FR: Increased epidermal growth factor receptor gene copy number is associated with poor prognosis in head and neck squamous cell carcinomas. J Clin Oncol *24*: 4170-4176, 2006.
25 Khan AJ, King BL, Smith BD, Smith GL, DiGiovanna MP, Carter D and Haffty BG: Characterization of the *HER2/neu* oncogene by immunohistochemical and fluorescence *in situ* hybridization analysis in oral and oropharyngeal squamous cell carcinoma. Clin Cancer Res *8*: 540-548, 2002.
26 Meert AP, Martin B, Verdebout JM, Noel S, Ninane V and Sculier JP: Is there a relationship between *c-erbB-1* and *c-erbB-2* amplification and protein overexpression in NSCLC? Lung Cancer *47*: 325-336, 2005.
27 Pfister DG, Su YB, Kraus DH, Wolden SL, Lis E, Aliff TB, Zahalsky AJ, Lake S, Needle MN, Shaha AR, Shah JP and Zelefsky MJ: Concurrent cetuximab, cisplatin, and concomitant boost radiotherapy for locoregionally advanced, squamous cell head and neck cancer: a pilot phase II study of a new combined-modality paradigm. J Clin Oncol *24*: 1072-1078, 2006.
28 Glisson BS, Murphy BA, Frenette G, Khuri FR and Forastiere AA: Phase II Trial of docetaxel and cisplatin combination chemotherapy in patients with squamous cell carcinoma of the head and neck. J Clin Oncol *20*: 1593-1599, 2002.
29 Ford AC and Grandis JR: Targeting epidermal growth factor receptor in head and neck cancer. Head Neck *25*: 67-73, 2003.
30 Squarize CH, Castilho RM and Santos Pinto D Jr: Immunohistochemical evidence of PTEN in oral squamous cell carcinoma and its correlation with the histological malignancy grading system. J Oral Pathol Med *31*: 379-384, 2002.
31 Massarelli E, Liu DD, Lee JJ, El-Naggar AK, Lo Muzio L, Staibano S, De Placido S, Myers JN and Papadimitrakopoulou VA: Akt activation correlates with adverse outcome in tongue cancer. Cancer *104*: 2430-2436, 2005.
32 Lothaire P, de Azambuja E, Dequanter D, Lalami Y, Sotiriou C, Andry G, Castro G Jr and Awada A: Molecular markers of head and neck squamous cell carcinoma: promising signs in need of prospective evaluation. Head Neck *28*: 256-269, 2006.
33 Temam S, Kawaguchi H, El-Naggar AK, Jelinek J, Tang H, Liu DD, Lang W, Issa JP, Lee JJ and Mao L: Epidermal growth factor receptor copy number alterations correlate with poor clinical outcome in patients with head and neck squamous cancer. J Clin Oncol *25*: 2164-2170, 2007.
34 Oc P, Rhys-Evans PH, Modjtahedi H and Eccles SA: The role of c-erbB receptors and ligands in head and neck squamous cell carcinoma. Oral Oncol *38*: 627-640, 2002.
35 Zamble DB, Mu D, Reardon JT, Sancar A and Lippard SJ: Repair of cisplatin-DNA adducts by the mammalian excision nuclease. Biochemistry *35*: 10004-10013, 1996.
36 Handra-Luca A, Hernandez J, Mountzios G, Taranchon E, Lacau-St-Guily J, Soria JC and Fouret P: Excision repair cross complementation group 1 immunohistochemical expression predicts objective response and cancer-specific survival in patients treated by cisplatin-based induction chemotherapy for locally advanced head and neck squamous cell carcinoma. Clin Cancer Res *13*: 3855-3859, 2007.
37 Jun H, Ahn M, Kim H, Park B, Han J, Ahn Y, Jeong H, Son Y, Baek J and Park K: Clinical significance of ERCC1 expression in advanced squamous cell carcinoma of the head and neck treated with cisplatin-based concurrent chemoradiation. J Clin Oncol *25(18 Suppl)*: 6061 (Abstr), 2007.

Received July 21, 2008
Revised October 24, 2008
Accepted November 10, 2008