

Clinical Studies

Long-term Eradication of Locally Recurrent Invasive Follicular Thyroid Carcinoma after Taxane-based Concomitant Chemoradiotherapy

MARSHALL TULLOCH-REID^{1,†}, MONICA C. SKARULIS¹,
STEVEN I. SHERMAN², NICHOLAS J. SARLIS^{2,#} and LIBERO SANTARPIA^{2,3}

¹National Institute of Diabetes and Digestive and Kidney Diseases,
National Institutes of Health, Bethesda, MD;

²Department of Endocrine Neoplasia and Hormonal Disorders,
The University of Texas - M.D. Anderson Cancer Center, Houston, TX, U.S.A.;

³Translational Research Unit Hospital of Prato and Istituto Toscana Tumori, Florence, Italy

Abstract. A 46-year-old woman with history of radioiodine-refractory follicular thyroid carcinoma (FTC) presented with locally recurrent, high-risk, invasive disease. She was treated with paclitaxel/carboplatin concomitant chemoradiotherapy (CRT), which was well tolerated, resulting in complete remission and freedom from residual or recurrent FTC for longer than 5 years until her last follow-up at age 52. This case highlights the possibility of combining taxane-based chemotherapy with definitive radiotherapy (as CRT) for the management of locally aggressive recurrences in poorly differentiated thyroid carcinoma, thereby resulting in rapid and persistent disease eradication. Even in the light of recent data on the potential benefit of novel targeted therapy agents in poorly differentiated thyroid carcinoma, this approach in similar clinical settings deserves future investigation.

Thyroid cancer accounts for about 1%-2% of all malignancies, with non-medullary differentiated thyroid carcinoma (DTC) accounting for ~93% of all cases (1). Although DTC is not associated with significant mortality, it demonstrates a high rate of local recurrence (2). Involvement

[†]Current address: Epidemiology Research Unit, TMRI, University of West Indies, Kingston, Jamaica, West Indies.

[#]Department of Medical Affairs - Oncology, Sanofi-Aventis US, Bridgewater, NJ, U.S.A.

Correspondence to: Libero Santarpià, MD, Ph.D., Department of Endocrine Neoplasia and Hormonal Disorders, The University of Texas M.D. Anderson Cancer Center, Houston, TX, U.S.A. Tel: +1 7137941997, e-mail: lsantarp@mdanderson.org

Key Words: Aerodigestive tract, external beam, radioiodine, radiosensitizer, radiotherapy, paclitaxel, taxane, carboplatin.

of the aerodigestive tract by DTC via direct extension of either the primary tumor (at the time of initial presentation) or locally recurrent disease deposits is rare. Furthermore, there is no consensus on the optimal management of such patients, as they also typically harbor disease that is refractory to radioiodine (RAI; ¹³¹I) therapy (1, 3) and their surgical curability is low (3).

We present the case of a patient who developed RAI-refractory, locally recurrent, invasive de-differentiated follicular thyroid carcinoma (FTC) which responded fully and in a sustained fashion to a concomitantly administered combination of taxane-based chemotherapy and radiotherapy (RT).

Case Report

A Caucasian woman presented with a T4aN0M0 FTC in June 1996, at the age of 41. She had neither previous exposure to ionizing radiation nor family history of thyroid disease or tumors. The patient underwent a total thyroidectomy for the resection of a right-sided 5.5-cm primary malignancy. The tumor extended to the resection margins, and showed evidence of both vascular and capsular invasion; no pathological findings were noted in 4/4 resected small nodes. The tumor histology was typical for well-differentiated FTC with typical DTC marker immunocytochemistry, with the exception of focal positivity for p53 and ~55% positivity for Ki-67. Her subsequent clinical course, imaging findings and serum thyroglobulin (Tg) levels over time are summarized in Table I. A locally invasive macroscopic recurrence at the level of the lower larynx/trachea was detected in March 2001, when the patient was 46 years old. The computed tomography (CT) of the neck without *i.v.* iodinated contrast, as well as the corresponding neck magnetic resonance imaging (MRI) scan at the time of diagnosis of the recurrence are shown in Figure

Table I. Clinical, laboratory, imaging and pathology data and evolution of the treatment plan over time.

Month/ Year of evaluation	Patient's age	Institution	RAI Dx WBS findings	Method of TSH stimulation	Serum Tg (ng/dl)	RAI Rx (MBq)	RAI post-Rx WBS findings	Other imaging/ cytology/ pathology findings	Therapeutic modality other than RAI
Jun. 1996	41	PHCP	Thyroid remnant/ thyroid bed uptake	THWD	ND	5,550	TB uptake	None	None
Dec. 1997	43.5	PHCP	Central neck uptake	THWD	12.8	5,550	Central neck uptake	Neck US: Negative	None
Jun. 1999	44	PHCP	ND	None	3.3	ND	ND	CXR: Left-sided lung nodule; CT-guided FNAB: FTC (M1 disease)	None
Feb. 2000	44.5	NIH	ND	None	7.3	ND	ND	Chest CT: 2.0-cm nodule left mid-lung field; neck CT (w/o <i>i.v.</i> contrast): 2.5-cm right jugulodigastric LN	Modified radical right neck dissection; 3/39 LN positive for FTC
Apr. 2000	44.5	NIH	Minimal RAI uptake in the left side of the neck at the level of the thyroid cartilage; no uptake in the lung fields	THWD	45.2	11,400*	No pathological uptake	Brain MRI: negative	Left-sided thoracotomy with wedge resection of the lung lesion (under euthyroid conditions); pathology: 2.5x1.3 cm FTC metastasis. Resection margins and adjacent resected LNs: free of tumor
Oct. 2000	45	NIH	Negative	RhTSH	3.0	ND	ND	CT neck & chest, neck MRI, neck U/S, bone scan, FDG-PET: all negative	None
Mar. 2001	46	NIH	Negative	RhTSH	8.4	ND	ND	Neck MRI/neck US: 1.0-cm abnormality with ill-defined borders in the right subglottic area, abutting the larynx; FDG-PET: single focus of increased uptake in the right anterior neck with an SUV of 10.2, corresponding to the abnormality seen in both the MRI and US; direct laryngoscopy: no evidence of vocal cord paralysis or erosion of the mass into the laryngeal mucosa;	Paclitaxel/ carboplatin concomitant CRT [refer to text]
Oct. 2001	46.5	NIH	Negative	RhTSH	<0.8	ND	ND	US-guided FNAB: FTC recurrence Neck MRI/neck US: negative; FDG-PET: Negative	None
Apr. 2002	47	NIH	Negative	THWD	1.2	ND	ND	Bone scan/neck US/neck MRI/FDG-PET: Negative	None
Dec. 2004	49	MDACC	Negative	RhTSH	<0.9	ND	ND	Bone scan/neck US/high-resolution neck & chest CT with <i>i.v.</i> contrast/FDG-PET: Negative	None
Mar. 2006	51	MDACC	Negative	RhTSH	<0.9	ND	ND	Neck US/high-resolution neck & chest CT with <i>i.v.</i> contrast/brain MRI/FDG-PET: Negative	None
May 2007	52	MDACC	Negative	RhTSH	1.0	ND	ND	Bone scan/neck US/neck MRI/ FDG-PET & chest CT: Negative	None

*The RAI Rx in Apr. 2000 was administered following whole-body and blood dosimetry, according to the Memorial Hospital protocol by Benua *et al.* (5), as modified by Reynolds and Robbins (The changing role of radioiodine in the management of differentiated thyroid cancer. *Semin Nucl Med* 27: 152-164, 1997), and more recently applied by Hanscheid *et al.* (Iodine biokinetics and dosimetry in radioiodine therapy of thyroid cancer: procedures and results of a prospective international controlled study of ablation after rhTSH or hormone withdrawal. *J Nucl Med* 47: 648-654, 2006). CRT: Chemoradiotherapy; CXR: chest X-ray; FDG-PET: [18]F-fluorodeoxyglucose positron-emission tomography; FTC: follicular thyroid carcinoma; LN: lymph node; MDACC: M. D. Anderson Cancer Center; MRI: magnetic resonance imaging; ND: not done; NIH: National Institutes of Health; PHCP: primary health care provider; RhTSH: recombinant human thyrotropin; SUV: standard uptake value; TB: total body; Tg: thyroglobulin; THWD: thyroid hormone withdrawal; TSH: thyroid-stimulating hormone; US: ultrasonography; WBS: whole-body scan.

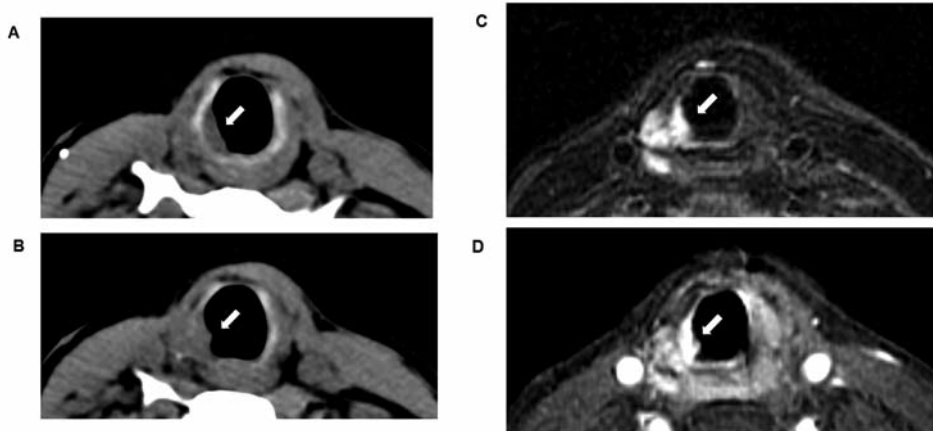


Figure 1. Neck imaging before Ptx/Cb CRT: A and B, Two consecutive axial pre contrast computed tomography images of the neck. There is an infiltrative lesion in the right subglottic area, abutting the luminal wall at the laryngotracheal border (arrows). Since the examination was performed without administration of i.v. contrast, the lateral margins of the tumor are not appreciated. C, Axial T2-weighted MRI scan of the neck with fat suppression: An abnormal mass measuring 1.0 cm in maximal diameter in the right paratracheal region is infiltrating the wall of the trachea (arrows). D, Axial post contrast T1-weighted scan of the neck at the same level. There is abnormal increase enhancement in the tumor (arrows). The part of the tumor that has infiltrated the tracheal wall enhances more intensely.

1. The ^{18}F -fluorodeoxyglucose positron-emission tomography (FDG-PET) scan is shown in Figure 2; this demonstrated a single focus of increased uptake in the right anterior neck with a high standard uptake value (SUV) of 10.2, corresponding to the abnormality depicted on both the MRI and ultrasound (US) examinations. An US-guided fine-needle aspiration biopsy of the paralaryngeal mass confirmed FTC recurrence. Of note, direct laryngoscopy revealed no evidence of vocal cord paralysis or erosion of the mass into the laryngeal mucosa.

At that juncture, the patient had already undergone three previous neck operations, and the risk of significant morbidity from damage to the recurrent laryngeal nerve, or the larynx itself, in another surgery could not be overlooked; furthermore, the surgical curability of the lesion with a functionally sparing procedure was deemed low. A diagnostic ^{131}I whole-body scan showed no elevated RAI uptake and the patient already had history of RAI-non-avid disease deposits, as demonstrated by the previously resected lung solitary metastasis. Considering that the absence of RAI uptake on a diagnostic ^{131}I whole-body scan usually suggests little or no fractional iodine uptake by the tumor deposits (4), it was predicted that the patient's response to yet another maximally safe dose ^{131}I therapy (under whole-blood/bone marrow RAI dosimetry guidance) would be minimal to none. Furthermore, administering RAI therapy under dosimetric guidance could have led to potential delays in the initiation of a more definitive therapy and/or some risk of more prolonged or severe myelosuppression due to bone marrow irradiation (5). Of note, the patient had an ECOG performance status of 0, and was otherwise completely asymptomatic. Definitive external beam RT to the recurrent mass was certainly considered as a possible option at that time

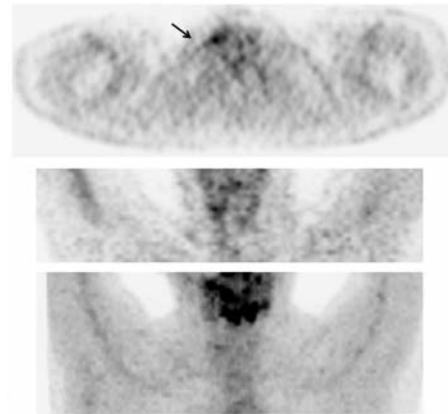


Figure 2. FDG-PET scan before Ptx/Cb CRT (only neck area shown): The malignant metastatic deposit in the right subglottic area (black arrow) was highly metabolically active and seemed to partially extend both medially and rostrally beyond its ill-defined borders, as suggested by the anatomical studies.

(6), with a suggested field coverage extending to the rest of the neck and upper mediastinum, which were territories at high risk for future recurrences. In addition, administration of the radiosensitizing chemotherapy during RT delivery was also considered. More specifically, the doublet of paclitaxel (Ptx)/carboplatin (Cb) was chosen to be administered concomitantly with definitive RT with curative intent. At the time of the patient's evaluation, Ptx, a taxane, had been used as a radiosensitizing agent in the treatment of assorted solid organ malignancies (7).

The CRT regimen was as follows: Chemotherapy: On day 1 of each cycle and concomitantly with RT, the patient received 60 mg/m² of Ptx administered over a 1-hour infusion. Premedication included dexamethasone, ranitidine, and diphenhydramine. The Ptx dose on the day of infusion was scheduled to start at least 2 hours before the RT fraction for that day, thus leaving a 1-hour gap between the end of Ptx infusion and the RT fraction. Cb was administered also concomitantly with RT on day 1 of each cycle as a 30-min infusion administered 3 to 4 hours after the RT fraction at a dose of an area under the concentration x time curve (AUC) of 2.0 (using the Calvert dosing formula) (8). Each Ptx/Cb cycle was 1 week in duration, and a total of 6 cycles were delivered.

RT: RT started from day 2 onward, and continued on a 5-day/week schedule with an initially planned total duration of 6 weeks (42 days). RT was delivered with a linear accelerator using 10-MV photons and suitable electron energies, *via* parallel-opposed lateral fields and an anterior field that allowed shielding of the spinal cord, and appropriate tangential laryngopharyngeal/tracheal doses. Using the above conventional 3-D conformal technique and once-daily standard fractionation, RT was administered to the primary tumor volume (paralaryngeal mass with appropriate margins) at a daily dose of 2.0 Gy/fraction on a 5-day/week schedule in a series of 30 fractions, plus 12 additional boost fractions of 0.85 Gy/fraction (total of 42 fractions at an average of 1.67 Gy/fraction) to a total of 70.2 Gy over a period of 52 days (initially planned RT treatment duration: 6 weeks: 42 days); the bilateral neck lymphatic fields received a total of 46.2 Gy.

The patient's treatment was complicated by oropharyngeal candidiasis, dysphagia, and hyperemia of the skin of the neck and upper chest (the latter anatomically defined by the margins of the radiation therapy fields). However, these effects were promptly managed and did not exceed NCI-CTC grade 2; furthermore, these adverse events did not necessitate therapy interruption, although there was a total delay of 10 days in the delivery of combination chemoradiotherapy (CRT). No hematological or other significant toxic reactions ensued. The patient was fed *via* a percutaneous endoscopic gastrostomy (PEG) tube for 3 weeks during her CRT; the PEG tube was placed prophylactically, was used successfully when needed, and was eventually removed without complications within 4 weeks after the completion of CRT (total duration of PEG tube dependence: 6.5 weeks). The patient did not experience severity of cytopenia greater than grade 2, and did not require transfusions or bone marrow growth factor support.

The patient's clinical course after completion of Ptx/Cb CRT is shown in Table I. By Mar. 2006, the patient was considered as having achieved no evidence of disease (NED) status for 5 years since completion of CRT. Ever since, the patient has been followed by a local oncologist. She remains recurrence-free to date, for a total duration of longer than 8 years.

Discussion

DTC is the second most common endocrine organ malignancy (after ovarian carcinoma) (1). Although not associated with significant mortality, DTC demonstrates a high rate of local recurrence (2). Involvement of the aerodigestive tract by DTC *via* direct extension of either the primary tumor (at the time of initial presentation) or locally recurrent disease deposits is rare. However, such locoregional recurrences, together with distant metastases (M1 status), represent the most frequent causes of death directly attributable to this malignancy (9-12), and are associated with aggressive features (such as the tall-cell or columnar variant of papillary thyroid carcinoma, poorly-differentiated FTC, and Hürthle-cell carcinomas) (13).

Literature on the clinical experience in the management of thyroid carcinoma involving the aerodigestive tract and/or large vessels of the neck remains sparse. Relevant reports combine patients with both undifferentiated (or poorly differentiated) and well-differentiated histologies, tumors at various initial stages, tumors that were invasive since initial presentation *vs.* those that demonstrated invasiveness only at the time of local recurrence, as well as varying levels of involvement of critical midline neck structures by the offending recurrence(s). Not surprisingly, there is no consensus on the optimal means of managing a patient with thyroid carcinoma who presents with invasion of the aerodigestive tract (3).

In cases similar to the one described here, deciding the direction of the management plan toward a specific single modality (surgery or definitive RT) or CRT is challenging. The goal of oncologically sound surgical treatment is to "provide adequate locoregional control, while minimizing not only the morbidity of the tumor, but also the morbidity of the surgical treatment" (3, 14). In cases where no evidence of intraluminal involvement exists, surgical resection to remove macroscopic disease (shave excision) is generally considered to be as effective (15). For invasive thyroid carcinoma (TC), adjuvant treatment with either high-dose ¹³¹I therapy, RT, or a sequence of both is typically required to manage microscopic disease, which usually remains in the surgical bed and/or the surrounding lymphatic territories. This is required for the prevention of the emergence of the postoperative tumor repopulation effect, which is a theoretical possibility based data on this phenomenon in solid malignancies other than thyroid carcinoma (16). Incomplete excision of gross tumor in locally invasive thyroid carcinoma cases is associated with a worse prognosis, mainly due to increased risk of local complications (13). If a decision is made to resect a part of the aerodigestive tract, partial rather than radical procedures are currently preferred, with the hope of preserving an acceptable degree of function (14).

For our patient, with aggressive recurrent disease and three previous neck surgeries, when a high-impact, invasive paralaryngeal locoregional recurrence was identified, the risks associated with surgery outweighed the anticipated benefits. In addition, because the offending lesion was rather small, had not penetrated the larynx transmurally, did not involve any major vascular organs, and had not undergone complete dedifferentiation into a frankly anaplastic phenotype, alternative non-surgical modalities were considered. Treatment with ^{131}I therapy was discussed, despite a negative diagnostic RAI whole-body scan. However, on average, less than 10% of similar patients would experience some benefit (typically partial response or maintenance of stable disease) from the administration of high-dose (~11 GBq) ^{131}I therapy (17). In our case, there was almost certainty regarding the refractoriness of the recurrence to RAI therapy, in view of the previous history of a RAI-non-avid pulmonary metastatic FTC deposit.

In patients with locoregional recurrence from thyroid carcinoma, definitive RT alone has been traditionally used for treatment of disease deposits that are not amenable to surgical resection and/or are no longer ^{131}I avid (6, 18-20). Over the last decade, RT has been used by some as an adjuvant modality after primary or secondary surgery (with/without ^{131}I therapy), particularly if there is evidence of a carcinoma with aggressive features, by either extent of disease or histologic type or grade (*e.g.* tumor harboring microscopic anaplastic components) (19, 20). The ability to administer an effective dose of RT may be limited by the risk of damage to surrounding structures, such as the spinal cord in the case of recurrences in the neck. Although this concern may have been lessened in the current era of intensity-modulated radiation therapy (IMRT), it continues to exist (21).

Chemotherapy agents, administered at lower doses than are typically used systemically for cytoreductive purposes in the context of treatment of distant metastases, have been attempted in combination with RT to improve the tumor's response to treatment in patients with anaplastic thyroid carcinoma (22-24). This combination is defined as concomitant chemoradiation, and its effectiveness has also been reported in a single case series from the late 1980s by Kim and Leeper (25), who reported a 91% objective response rate (ORR) to a combination of weekly doxorubicin and RT, the latter targeted to the bulk of the tumor mass and the neck territories. This series was of consecutive (*i.e.* non-randomized) cases of either advanced DTC or less differentiated subtypes of TC – including mixed histologies (*e.g.* papillary “in transformation” toward anaplastic); the series did not include RT-only controls. The usefulness of doxorubicin in this report reflects the benefit from this agent in anaplastic thyroid carcinoma (26). Nevertheless, the response to doxorubicin-based CRT was short-lived. Side-effects included pharyngoesophagitis, tracheitis, and

erythema of the irradiated skin. In some cases, RT had to be discontinued or given in a hypofractionated manner, particularly in elderly patients (25). Notably, the RT technology used at the time of this report was frankly suboptimal as compared to today's standards (even with 3-D conformal techniques without IMRT). With doxorubicin-containing CRT, 77% of DTC patients were deemed tumor free 2 years after their initial treatment (25). The definition of tumor-free status in this study was based solely on anatomical criteria, considering the lack of application, or crudity, of the imaging techniques available at the time. It is likely that a lower ORR would be observed currently, considering the availability of highly sensitive and reliable methods for identification of persistent/recurrent disease (27-29).

Ptx, as well as its newer congener, docetaxel, are semisynthetic broad-activity antineoplastic agents that can be used alone or in combination for the treatment of solid tumors, including breast, lung, ovarian, and squamous cell head and neck carcinomas (22-24), including the locally advanced context (30-37). As microtubule-active drugs, taxanes act by inducing cell arrest in the G_2/M phase, which is the most radiosensitive phase of the cell cycle, but may also have a cell cycle-independent effect through stimulation of apoptosis (38, 39). Ptx arrests the development of anaplastic malignant thyrocytes *in vitro* (40) and reduces the size of anaplastic thyroid carcinoma deposits *in vivo* (41). The above notwithstanding, Ptx has been much less effective in inducing a measurable clinical response when administered as monotherapy to patients with anaplastic thyroid carcinoma in a phase II trial, but this may be a result of the dosing schedules of the agent used in that particular study (41). With the exception of a report on the beneficial effect of docetaxel CRT in a single case of anaplastic thyroid carcinoma (42), to date there are no reports of the use of either taxane as a radiosensitizer in the context of CRT for locally advanced DTC (either in the primary or locally recurrent setting). The demonstration of activity of the latter approach would provide proof-of-principle, and could potentially provide a CRT paradigm to build upon with the addition of novel agents (administered either synchronously or metachronously) (43-45). Although in our patient a Ptx/Cb combination was used for CRT, future phase I or II studies in similar patients may consider using docetaxel as the agent of choice. This suggestion is based on the latter agent's manageable safety profile and superior efficacy as a radiosensitizer when used in CRT for squamous cell carcinoma of the head and neck (33-35, 46-50).

Several clinicopathological features in our patient, such as the type of her carcinoma (de-differentiated FTC), the size of the initial lesion, and the presence of vascular, capsular, and surrounding soft tissue invasion at presentation, pointed to the need for more aggressive initial

management of her disease than would routinely be used in a patient with low-risk DTC. In retrospect, in our patient, the early use of RT (6, 18-20) or taxane-based CRT (23, 42, 43) delivered mainly to the surgical bed, as well as surrounding neck and mediastinal lymph node territories soon after initial total thyroidectomy and ¹³¹I remnant ablation may have resulted in a more expeditious eradication of her disease.

We thus suggest that taxanes (with or without platinum; both at radiosensitizing doses) be considered in combination with external beam definitive RT for the treatment of an unresectable, RAI-refractory locally invasive locoregional recurrence in DTC.

Acknowledgements

We would like to thank the American Thyroid Association for a THY-CA grant to L.S., Dr. N.J. Patronas, Department of Radiology, and Dr. J.C. Reynolds, Nuclear Medicine Department, both at the Clinical Center, NIH, and Drs. R.M. Altemus and A.T. Fojo of the National Cancer Institute (NCI), NIH, for their expert consultations. Dr. M.J. Merino, Laboratory of Pathology, NCI, NIH, performed the pathology review of all tumor specimens in this case. We also appreciate the critical comments and suggestions provided by Drs. F.C. Holsinger of the University of Texas - M. D. Anderson Cancer Center and M.R. Posner of the Dana-Farber Cancer Institute.

Disclosures/Potential Conflicts of Interest

Dr. Nicholas J. Sarlis is an employee of Sanofi-Aventis US, the manufacturer of docetaxel. He also holds stock options in the same company. The other authors have nothing to disclose.

References

- 1 Sherman SI: Thyroid carcinoma. *Lancet* 361: 501-511, 2003.
- 2 McConahey WM, Hay ID, Woolner LB, van Heerden JA and Taylor WF: Papillary thyroid cancer treated at the Mayo Clinic, 1946 through 1970: initial manifestations, pathologic findings, therapy, and outcome. *Mayo Clin Proc* 61: 978-996, 1986.
- 3 Gillenwater AM and Goepfert H: Surgical management of laryngotracheal and esophageal involvement by locally advanced thyroid cancer. *Semin Surg Oncol* 16: 19-29, 1999.
- 4 Maxon HR IIIrd, Thomas SR, Hertzberg VS, Kereiakes JG, Chen IW, Sperling MI and Saenger EL: Relation between effective radiation dose and outcome of radioiodine therapy for thyroid cancer. *N Engl J Med* 309: 937-941, 1983.
- 5 Benua RS, Cicale NR, Sonenberg M and Rawson RW: The relation of radioiodine dosimetry to results and complications in the treatment of metastatic thyroid cancer. *Am J Roentgenol* 87: 171-182, 1962.
- 6 Brierley JD and Tsang RW: External beam radiation therapy for thyroid cancer. *Endocrinol Metab Clin North Am* 37: 497-509, 2008.
- 7 Tishler RB, Schiff PB, Geard CR and Hall EJ: Taxol: a novel radiation sensitizer. *Int J Radiat Oncol Biol Phys* 22: 613-617, 1992.

- 8 Calvert AH, Newell DR, Gumbrell LA, O'Reilly S, Burnell M, Boxall FE, Siddik ZH, Judson IR, Gore ME and Wiltshaw E: Carboplatin dosage: prospective evaluation of a simple formula based on renal function. *J Clin Oncol* 7: 1748-1756, 1989.
- 9 Beasley NJ, Walfish PG, Witterick I and Freeman JL: Cause of death in patients with well-differentiated thyroid carcinoma. *Laryngoscope* 111: 989-991, 2001.
- 10 Kitamura Y, Shimizu K, Nagahama M, Sugino K, Ozaki O, Mimura T, Ito K, Ito K and Tanaka S: Immediate causes of death in thyroid carcinoma: clinicopathological analysis of 161 fatal cases. *J Clin Endocrinol Metab* 84: 4043-4049, 1999.
- 11 Wu HS, Young MT, Ituarte PH, D'Avanzo A, Duh QY, Greenspan FS, Loh KC and Clark OH: Death from thyroid cancer of follicular cell origin. *J Am Coll Surg* 191: 600-606, 2000.
- 12 Silverberg SG, Hutter RV and Foote FW Jr: Fatal carcinoma of the thyroid: histology, metastases, and causes of death. *Cancer* 25: 792-802, 1970.
- 13 Robbins J, Merino MJ, Boice JD, Jr, Ron E, Ain KB, Alexander HR, Norton JA and Reynolds J: Thyroid cancer: a lethal endocrine neoplasm. *Ann Intern Med* 115: 133-147, 1991.
- 14 McCaffrey JC: Evaluation and treatment of aerodigestive tract invasion by well-differentiated thyroid carcinoma. *Cancer Control* 7: 246-252, 2000.
- 15 Czaja JM and McCaffrey TV: The surgical management of laryngotracheal invasion by well-differentiated papillary thyroid carcinoma. *Arch Otolaryngol Head Neck Surg* 123: 484-490, 1997.
- 16 Suwinski R, Sowa A, Rutkowski T, Wydmanski J, Tarnawski R and Maciejewski B: Time factor in postoperative radiotherapy: a multivariate locoregional control analysis in 868 patients. *Int J Radiat Oncol Biol Phys* 56: 399-412, 2003.
- 17 Pineda JD, Lee T, Ain K, Reynolds JC and Robbins J: Iodine-131 therapy for thyroid cancer patients with elevated thyroglobulin and negative diagnostic scan. *J Clin Endocrinol Metab* 80: 1488-1492, 1995.
- 18 Brierley JD and Tsang RW: External beam radiation therapy in the treatment of differentiated thyroid cancer. *Semin Surg Oncol* 16: 42-49, 1999.
- 19 Meadows KM, Amdur RJ, Morris CG, Villaret DB, Mazzaferrri EL and Mendenhall WM: External beam radiotherapy for differentiated thyroid cancer. *Am J Otolaryngol* 27: 24-28, 2006.
- 20 Tsang RW, Brierley JD, Simpson WJ, Panzarella T, Gospodarowicz MK and Sutcliffe SB: The effects of surgery, radioiodine, and external radiation therapy on the clinical outcome of patients with differentiated thyroid carcinoma. *Cancer* 82: 375-388, 1998.
- 21 Nutting CM, Convery DJ, Cosgrove VP, Rowbottom C, Vini L, Harmer C, Dearnaley DP and Webb S: Improvements in target coverage and reduced spinal cord irradiation using intensity-modulated radiotherapy (IMRT) in patients with carcinoma of the thyroid gland. *Radiother Oncol* 60: 173-180, 2001.
- 22 Tennvall J, Lundell G, Wahlberg P, Bergenfelz A, Grimelius L, Akerman M, Hjelm Skog AL and Wallin G: Anaplastic thyroid carcinoma: three protocols combining doxorubicin, hyperfractionated radiotherapy and surgery. *Br J Cancer* 86: 1848-1853, 2002.
- 23 Haddad R, Mahadevan A, Posner MR and Sullivan C: Long-term survival with adjuvant carboplatin, paclitaxel, and radiation therapy in anaplastic thyroid cancer. *Am J Clin Oncol* 28: 104, 2005.

- 24 Pudney D, Lau H, Ruether JD and Falck V: Clinical experience of the multimodality management of anaplastic thyroid cancer and literature review. *Thyroid* 17: 1243-1250, 2007.
- 25 Kim JH and Leeper RD: Treatment of locally advanced thyroid carcinoma with combination doxorubicin and radiation therapy. *Cancer* 60: 2372-2375, 1987.
- 26 Shimaoka K: Adjunctive management of thyroid cancer: chemotherapy. *J Surg Oncol* 15: 283-286, 1980.
- 27 Spencer CA, LoPresti JS, Fatemi S and Nicoloff JT: Detection of residual and recurrent differentiated thyroid carcinoma by serum thyroglobulin measurement. *Thyroid* 9: 435-441, 1999.
- 28 Gambhir SS, Czernin J, Schwimmer J, Silverman DH, Coleman RE and Phelps ME: A tabulated summary of the FDG-PET literature. *J Nucl Med* 42(5 Suppl): 1S-93S, 2001.
- 29 Sarlis NJ, Gourgiotis L, Guthrie LC, Galen B, Skarulis MC, Shawker TH, Patronas NJ and Reynolds NJ: In-111 DTPA-octreotide scintigraphy for disease detection in metastatic thyroid cancer: comparison with F-18 FDG positron-emission tomography and extensive conventional radiographic imaging. *Clin Nucl Med* 28: 208-217, 2003.
- 30 Eisenhauer EA and Vermorken JB: The taxoids. Comparative clinical pharmacology and therapeutic potential. *Drugs* 55: 5-30, 1998.
- 31 Miller ML and Ojima I: Chemistry and chemical biology of taxane anticancer agents. *Chem Rec* 1: 195-211, 2001.
- 32 Michaud LB, Valero V and Hortobagyi G: Risks and benefits of taxanes in breast and ovarian cancer. *Drug Saf* 23: 401-428, 2000.
- 33 Tishler RB, Posner MR, Norris CM Jr, Mahadevan A, Sullivan C, Goguen L, Wirth LJ, Costello R, Case M, Stowell S, Sammartino D, Busse PM and Haddad RI: Concurrent weekly docetaxel and concomitant boost radiation therapy in the treatment of locally advanced squamous cell cancer of the head and neck. *Int J Radiat Oncol Biol Phys* 65: 1036-1044, 2006.
- 34 Fujii M, Tsukuda M, Satake B, Kubota A, Kida A, Kohno N, Okami K, Inuyama Y; Japan Cooperative Head and Neck Oncology Group (JCHNOG): Phase I/II trial of weekly docetaxel and concomitant radiotherapy for squamous cell carcinoma of the head and neck. *Int J Clin Oncol* 9: 107-112, 2004.
- 35 Brockstein B and Vokes EE: Concurrent chemoradiotherapy for head and neck cancer. *Semin Oncol* 31: 786-793, 2004.
- 36 Calais G, Bardet E, Sire C, Alfonsi M, Bourhis J, Rhein B, Tortochaux J, Man YT, Auvray H and Garaud P: Radiotherapy with concomitant weekly docetaxel for Stages III/IV oropharynx carcinoma. Results of the 98-02 GORTEC Phase II trial. *Int J Radiat Oncol Biol Phys* 58: 161-166, 2004.
- 37 Schwartz DL, Montgomery RB, Yueh B, Donahue M, Anzai Y, Canby R, Buelna R, Anderson L, Boyd C, Hutson J and Keegan K: Phase I and initial phase II results from a trial investigating weekly docetaxel and carboplatin given neoadjuvantly and then concurrently with concomitant boost radiotherapy for locally advanced squamous cell carcinoma of the head and neck. *Cancer* 103: 2534-2543, 2005.
- 38 Blagosklonny MV and Fojo T: Molecular effects of paclitaxel: myths and reality (a critical review). *Int J Cancer* 83: 151-156, 1999.
- 39 Wang TH, Wang HS and Soong YK: Paclitaxel-induced cell death: where the cell cycle and apoptosis come together. *Cancer* 88: 2619-2628, 2000.
- 40 Ain KB, Tofiq S and Taylor KD: Antineoplastic activity of taxol against human anaplastic thyroid carcinoma cell lines *in vitro* and *in vivo*. *J Clin Endocrinol Metab* 81: 3650-3653, 1996.
- 41 Ain KB, Egorin MJ and DeSimone PA: Treatment of anaplastic thyroid carcinoma with paclitaxel: phase 2 trial using a 96-hour infusion. Collaborative Anaplastic Thyroid Cancer Health Intervention Trials (CATCHIT) Group. *Thyroid* 10: 587-594, 2000.
- 42 Kurukahvecioglu O, Ege E, Poyraz A, Tezel E and Taneri F: Anaplastic thyroid carcinoma with long-term survival after combined treatment: case report. *Endocr Regulations* 41: 41-44, 2007.
- 43 Deshpande HA, Gettinger SN and Sosa JA: Novel chemotherapy options for advanced thyroid tumors: small molecules offer great hope. *Curr Opin Oncol* 20: 19-24, 2008.
- 44 Sarlis NJ: Metastatic thyroid cancer unresponsive to conventional therapies: novel management approaches through translational clinical research. *Curr Drug Targets Immune Endocr Metabol Disord* 1: 103-115, 2001.
- 45 Sarlis NJ: Molecular elements of apoptosis-regulating pathways in follicular thyroid cells: mining for novel therapeutic targets in the treatment of thyroid carcinoma. *Curr Drug Targets Immune Endocr Metabol Disord* 4: 187-198, 2004.
- 46 Biete Solà A, Marruecos Querol J, Calvo Manuel FA, Verger Fransoy E, Roviroso Casino A, Grau de Castro JJ, de Las Heras González M, Ramos Aguerri A, Palacios Eito A, Veiras Candal C and Solano López MV: Phase II trial: concurrent radiochemotherapy with weekly docetaxel for advanced squamous cell carcinoma of head and neck. *Clin Transl Oncol* 9: 244-250, 2007.
- 47 Matsumoto F, Karasawa K, Itoh S, Toda M, Haruyama T, Furukawa M and Ikeda K: Concurrent weekly docetaxel and hyperfractionated radiotherapy for advanced head and neck cancer. *Anticancer Res* 26: 3781-3786, 2006.
- 48 Tsao AS, Garden AS, Kies MS, Morrison W, Feng L, Lee JJ, Khuri F, Zinner R, Myers J, Papadimitrakopoulou V, Lewin J, Clayman GL, Ang KK and Glisson BS: Phase I/II study of docetaxel, cisplatin, and concomitant boost radiation for locally advanced squamous cell cancer of the head and neck. *J Clin Oncol* 24: 4163-4169, 2006.
- 49 Ravidis AD, Trichas M, Stavrinidis E, Roupakia A, Ioannidou G, Kritselis G, Liossi P, Giannakouras G, Douzinas EE and Katsilieris I: Induction chemotherapy followed by concurrent chemoradiation in advanced squamous cell carcinoma of the head and neck: final results from a phase II study with docetaxel, cisplatin and 5-fluorouracil with a four-year follow-up. *Oral Oncol* 42: 675-684, 2006.
- 50 Ravidis A, Sarlis N, Lefebvre JL and Kies M: Docetaxel in the treatment of squamous cell carcinoma of the head and neck. *Ther Clin Risk Manag* 4: 865-886, 2008.

Received June 5, 2009

Revised September 4, 2009

Accepted September 14, 2009