

Correspondence between Flat Aberrant Crypt Foci and Mucin-depleted Foci in Rodent Colon Carcinogenesis

ANGELO PIETRO FEMIA^{1*}, JAN ERIK PAULSEN^{2*}, PIERO DOLARA¹,
JAN ALEXANDER² and GIOVANNA CADERNI¹

¹Department of Pharmacology University of Florence, 50139 Florence, Italy;

²Department of Food Safety and Nutrition, Norwegian Institute of Public Health, Nydalen, N-0403 Oslo, Norway

Abstract. *Background:* Flat aberrant crypt foci (flat ACF) and mucin-depleted foci (MDF) are preneoplastic lesions identified in the colon of carcinogen-treated rodents stained with methylene blue (MB) and high iron diamine-alcian blue (HID-AB), respectively. The correspondence between flat ACF and MDF in the same colon of Min mice treated with azoxymethane (AOM) and of F344 rats treated with 1,2-dimethylhydrazine (DMH) was explored. *Materials and Methods:* The position of each flat ACF was recorded on a digitally constructed photographic map of the MB-stained colon. The same colons were then stained with HID-AB and the position of each MDF was compared with that of flat ACF. *Results:* The fraction of coincident lesions, identified as both flat ACF and MDF with the two staining methods, was 57% and 42%, in the Min mice and F344 rats, respectively. Flat ACF or MDF not coincident with the two staining methods were either undetectable or ACF with one of the two methods. *Conclusion:* Flat ACF and MDF show considerable, but not total, overlap.

Identification of preneoplastic lesions is a key step in the development of reliable biomarkers of cancer in short-term carcinogenesis assays. Aberrant crypt foci (ACF), identified in unsectioned colons stained with methylene blue (MB) in azoxymethane (AOM)-treated mice (1) are purportedly preneoplastic lesions well characterized in humans and animals, therefore, they are widely used as biomarkers in colon carcinogenesis (2). However, possibly due to

heterogeneity in ACF genotype and phenotype, the relationship between ACF and colon carcinogenesis is not straightforward (3, 4).

Accordingly, recent reports have described alternative early lesions with better correlation with the development of colonic tumours, such as β -catenin accumulated crypts (BCAC), flat ACF and mucin-depleted foci (MDF) (5-8). While the identification of BCAC is entirely dependent on histological cross-sectioning of the colon and β -catenin immunohistochemistry, flat ACF and MDF can be recognized in unsectioned colons. In MB-stained colons, flat ACF, but not classical ACF, appear as bright blue stained lesions with compressed pit patterns (6, 9-10). MDF are visualized with high iron diamine-alcian blue (HID-AB), a mucin-specific staining (7, 11). Flat ACF and MDF occur in the colon of carcinogen-treated rats at much lower frequency than classical ACF, are dysplastic and show phenotypic and genotypic characteristics of colonic tumours, such as constitutive activation of Wnt pathway or mutations in relevant genes of the carcinogenic process (10-13). These observations suggest that flat ACF, MDF and BCAC could, in principle, be related lesions.

Previously, it has been shown that MDF and BCAC are partially overlapping lesions (14). On the other hand, the relationship between flat ACF and MDF is unclear and given the precancerous nature of both flat ACF and MDF, it is important to clarify the relationship between them. Therefore, whether or not flat ACF and MDF are actually the same lesions identified by two different methods was investigated.

Materials and Methods

Comparison analysis of flat ACF and MDF was carried out in two different sets of colon samples. The first set was composed of whole colons from Min mice (n=3) treated with AOM (Sigma Chemicals St. Louis, MO, USA; 5 mg/kg body weight [bw] \times 2 subcutaneous [s.c.] administered in the first and second week after birth) and sacrificed at 11 weeks of age and the second set was composed of the distal colons of male F344 rats (n=5) treated with 1,2-

*Both authors contributed equally to this work.

Correspondence to: Giovanna Caderni, Dipartimento di Farmacologia Preclinica e Clinica della Università di Firenze, Viale G. Pieraccini, 6, 50139 Firenze, Italy. Tel: +39 0554271319, Fax: +39 0554271280, e-mail: giovanna.caderni@unifi.it

Key Words: Preneoplastic lesions, flat aberrant crypt foci, mucin-depleted foci, colon carcinogenesis.

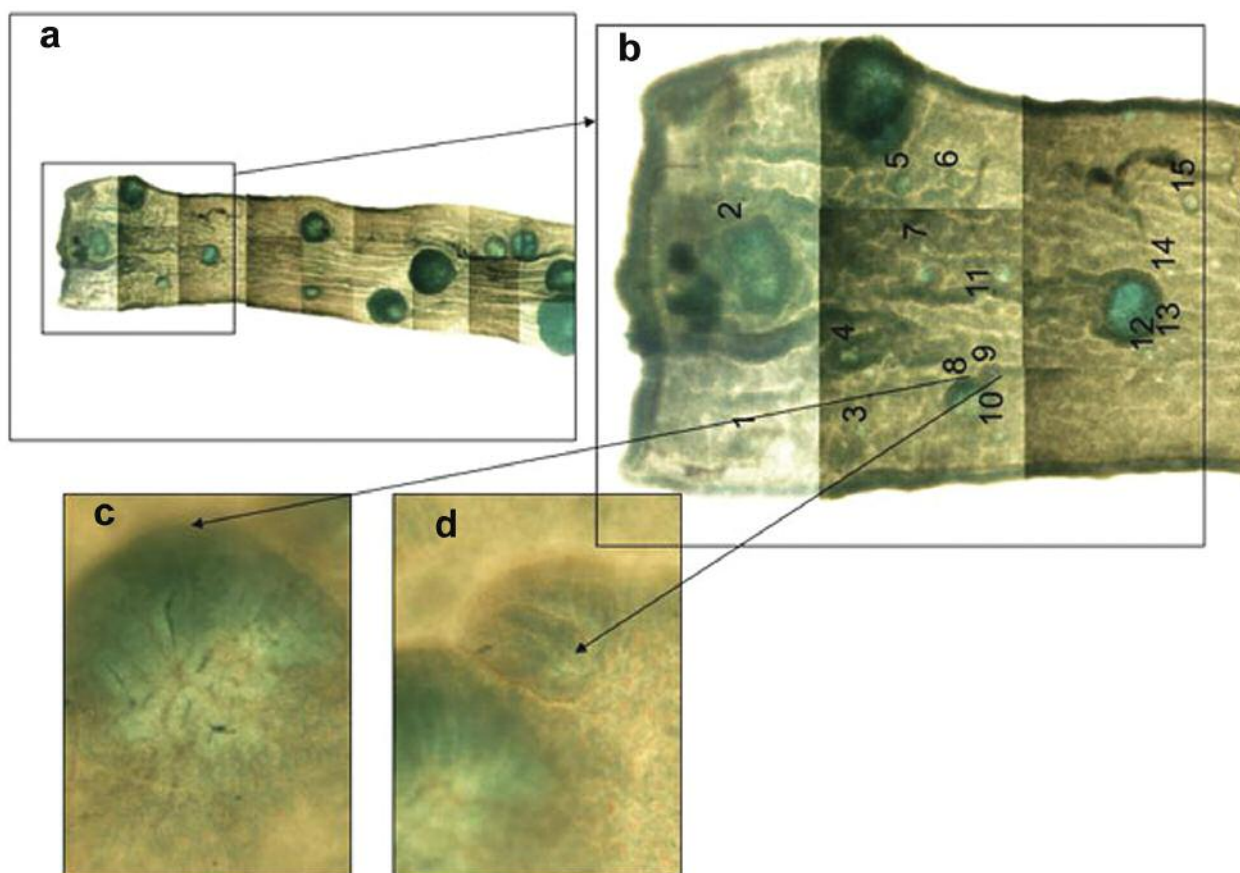


Figure 1. Panel a: Photographic map of MB stained mouse distal colon reconstructed with numerous digital images of adjacent fields; lesions were recorded as flat ACF or classical ACF; Panel b: a higher magnification of part of panel a; note that each lesion was numbered. High resolution images of two of the observed lesions: a flat ACF (panel c) and a classical elevated ACF (panel d).

dimethylhydrazine (DMH, Aldrich Chemical, Milan, Italy; 150 mg/kg bw \times 2 s.c.) and sacrificed 13 weeks from carcinogen injection. These were the two experimental models in which flat ACF and MDF were originally identified (6, 7). A photographic map of each colon stained with MB was reconstructed with numerous digital images of adjacent fields (see an example in Figure 1) and was used to mark the position of each flat ACF or classical ACF scored in the Norwegian laboratory as described below. The MB-stained preparations were then shipped to Italy for HID-AB staining and a blind scoring of MDF was performed as described below. The photographic maps were then used to determine which flat ACF and MDF had coincident localisation, *i.e.* were the same lesions. The correspondence between flat ACF and MDF was expressed as the fraction of lesions identified as flat ACF with MB and as MDF with HID-AB (coincident lesions, Figure 2) over the total number of lesions (*i.e.* the sum of coincident lesions plus the non-coincident lesions).

Identification of flat ACF and classical ACF. The colon samples were fixed flat in 10% neutral buffered formalin for at least 48 h prior to 3-5 s staining with 0.2% MB. The observed lesions were defined as classical ACF or flat ACF as previously described (6, 9, 10). Briefly, classical ACF are characterized by their enlarged crypts,

microscopically elevated from the surrounding epithelium, thickened layer of epithelial cells, increased pericryptal space and their round or elongated luminal openings. Flat ACF are characterized by their bright blue staining, moderate enlarged or small crypts not elevated from the surrounding epithelium and their compressed round or elongated luminal openings, observable as a streak under the microscope.

MDF identification. The colons stained with MB, were stained with high iron diamine (HID) and Alcian blue (AB) solutions. Briefly, the colons were rinsed in distilled water and stained for 18 h at room temperature (RT) with HID solution obtained by dissolving simultaneously 120 mg of *N-N'*-dimethyl-*m*-phenylene diamine and 20 mg of *N-N'*-dimethyl-*p*-phenylene diamine in 50 ml of distilled water and then adding 1.4 ml of 60% ferric chloride. The colons were then rinsed three times in distilled water and stained for 30 min with 1% alcian blue in 3% acetic acid. The colons were then rinsed three times with 80% ethanol followed by distilled water and observed under the microscope for the determination of MDF.

The lesions observed in the HID-AB stained colons were defined as MDF or ACF as previously described (7, 11). Briefly, MDF are focal lesions characterized by the absence or very limited production of mucins. Moreover, MDF are often formed by crypts smaller than the normal ones and their lumen is often distorted. Elevation of the

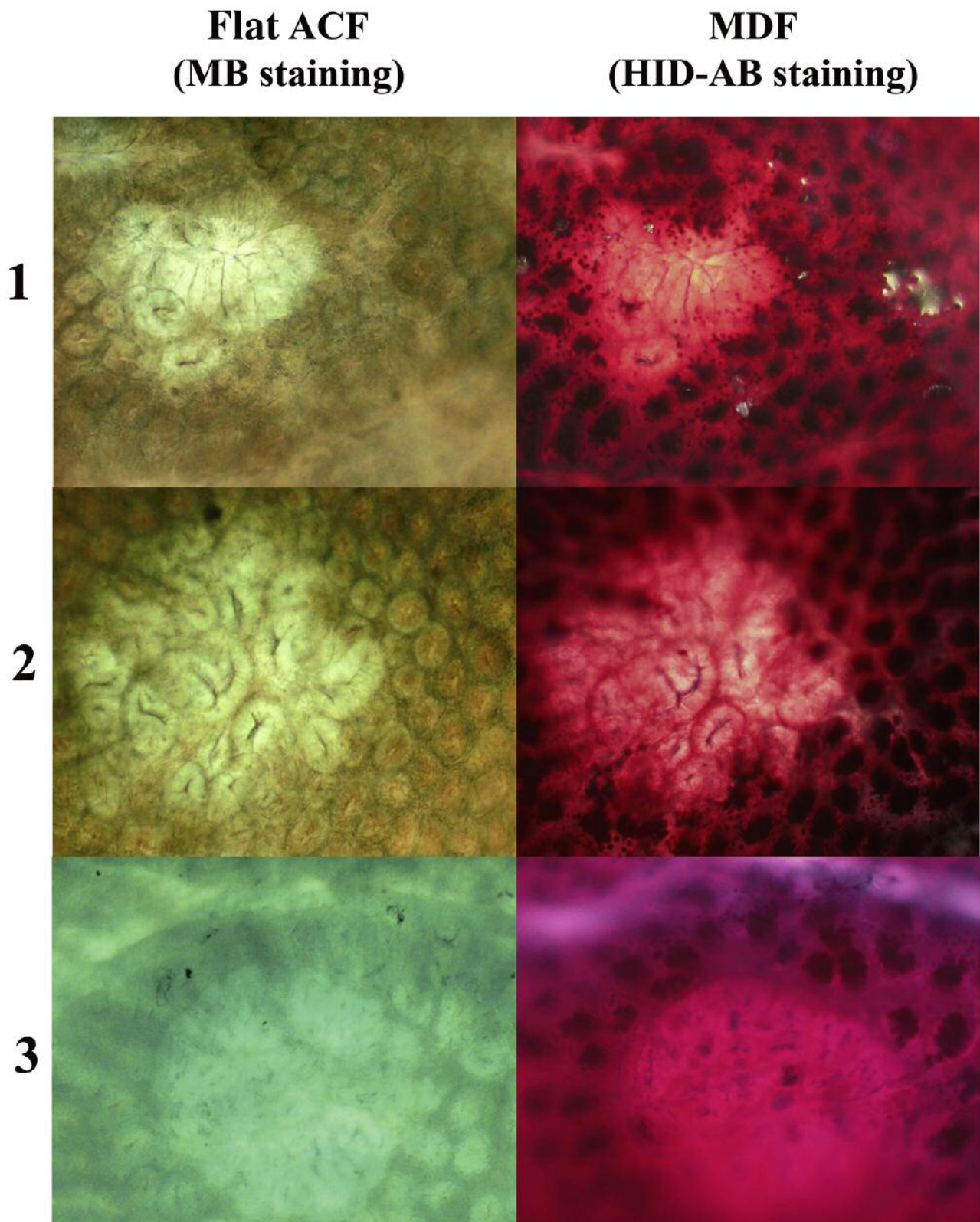


Figure 2. Representative examples of morphological appearances of different coincident lesions (1, 2 and 3) identified as flat ACF with MB (left panels) and as MDF with HID-AB (right panels). Original magnification: $\times 100$.

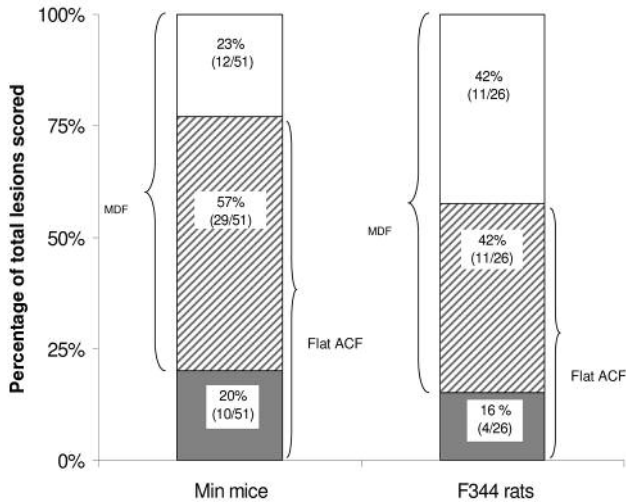


Figure 3. Histogram showing the distribution of flat ACF and MDF identified in the Min mice (left bar) and F344 rats (right bar) as coincident lesions (striped boxes), flat ACF not coincident with MDF in HID-AB (grey boxes) and MDF not coincident with flat ACF in MB (white boxes). Values in parentheses are the number of lesions in each category over the total number of lesions scored.

lesion above the surface of the colon and a multiplicity (*i.e.* the number of crypts forming each focus) higher than 3 are also frequent features of MDF. Single crypts without mucus are never considered as MDF. ACF in HID-AB-stained colons are characterized by mucous production, elevation from the plane of the mucosa, by crypts larger than normal, increased pericryptal space and a thicker layer of epithelial cells.

Results

In the colons of the AOM-treated Min mice, 66 flat ACF and 41 MDF were observed. However, 27 of the flat ACF had only one crypt, a size that is below the detection limit for MDF. Therefore, these small flat ACF were excluded from the counts when the lesions were assessed in the two categories (Figure 3, left bar). The fraction of coincident lesions was 57%, of MDF not coincident with flat ACF 23% and of flat ACF not coincident with MDF 20%.

In the rat colons (Figure 3, right bar), 15 flat ACF and 22 MDF were observed. The fraction of coincident lesions was 42%, of MDF not coincident with flat ACF 42% and of flat ACF not coincident with MDF 16%.

The non-coincident flat ACF were either undetectable or were ACF when observed in HID-AB (Table I). The distribution of these lesions in these two categories was different between mice and rats ($p < 0.001$, Fisher exact test), in fact in the mice, all (n=10) were undetectable, whereas in the rats, all were scored as ACF in HID-AB (n=4). The non-coincident MDF were either undetectable or classical ACF with MB with a similar distribution between mice and rats (Table I).

Table I. Characteristics of the non-coincident flat ACF and MDF.

| | Min mice | F344 rats |
|--------------------------|----------|-----------|
| Non-coincident flat ACF | | |
| Undetectable with HID-AB | 10 | 0 |
| ACF with HID-AB | 0 | 4 |
| Non-coincident MDF | | |
| Undetectable with MB | 5 | 8 |
| ACF with MB | 7 | 3 |

Discussion

In this study, the relationship between flat ACF and MDF preneoplastic lesions was investigated for the first time. Interestingly, recent studies in humans have indicated that flat ACF could represent a robust surface biomarker (15), while it has been suggested that ACF are not a good surrogate endpoint for colorectal adenoma prevention (16, 17).

In the colons of the Min mice treated with AOM and the F344 rats treated with DMH, 60% and 40% coincidence was found between the flat ACF and MDF, respectively, demonstrating considerable, but not total overlap. Among the non-coincident lesions, some of the MDF were scored as classical ACF in the MB-stained colons. This was in agreement with Yoshimi and colleagues who reported that ~10% of MDF (14), identified in Alcian blue-stained colons, corresponded to classical ACF with dysplasia. This result also agreed with the observation that ~20% of classical ACF may exhibit moderate dysplasia, and also shows also a reduced number of mucous-producing goblet cells (10, 13). Moreover, some of the MDF not coincident with flat ACF were undetectable in MB, a result in agreement with previous studies showing that some MDF are not identified with this staining (11).

Their easy identification in unsectioned colon makes flat ACF and MDF good candidates as biomarkers in colon carcinogenesis. Since both flat ACF and MDF are beginning to be used as more consistent surface biomarkers than classical ACF (15, 18, 19), it is essential to characterize these lesions and to determine the surface characteristics which are better related to colorectal cancer. Therefore, further studies are necessary to clarify the significance of the coincident and non-coincident lesions and to understand their relationship with late events of colorectal carcinogenesis.

Acknowledgements

Supported by grant “05A019-REV” from the American Institute for Cancer Research, by AIRC (Italian Association for Cancer Research, Regional Grants), by Fondo Ateneo ex-60% of the University of Florence and by the Norwegian Cancer Society. We thank M. Salvadori for her expert technical assistance and M. Forrest for revision of the manuscript.

References

- 1 Bird RP: Observation and quantification of aberrant crypts in the murine colon treated with a colon carcinogen: Preliminary findings. *Cancer Lett* 37: 147-151, 1987.
- 2 Corpet DE and Taché S: Most effective colon cancer chemopreventive agents in rats: a systematic review of aberrant crypt foci and tumor data, ranked by potency. *Nutr Cancer* 43: 1-21, 2002.
- 3 Zheng Y, Kramer PM, Lubet RA, Steele VE, Keloff GJ and Pereira MA: Effect of retinoids on AOM-induced colon cancer in rats: modulation of cell proliferation, apoptosis and aberrant crypt foci. *Carcinogenesis* 20: 255-260, 1999.
- 4 Magnusson BA, Carr I and Bird RP: Ability of aberrant crypt foci characteristics to predict colonic tumor incidence in rats fed cholic acid. *Cancer Res* 53: 4499-4504, 1993.
- 5 Yamada Y, Yoshimi N, Hirose Y *et al*: Frequent *beta-catenin* gene mutations and accumulations of the protein in the putative preneoplastic lesions lacking macroscopic aberrant crypt foci appearance, in rat colon carcinogenesis. *Cancer Res* 60: 3323-3327, 2000.
- 6 Paulsen JE, Namork E, Steffensen IL, Eide TJ and Alexander J: Identification and quantification of aberrant crypt foci in the colon of Min mice – A murine model of familial adenomatous polyposis. *Scand J Gastroenterol* 35: 534-539, 2000.
- 7 Caderni G, Femia AP, Giannini A *et al*: Identification of mucin-depleted foci in the unsectioned colon of azoxymethane-treated rats: correlation with carcinogenesis. *Cancer Res* 63: 2388-2392, 2003.
- 8 Hirose Y, Kuno T, Yamada Y *et al*: Azoxymethane-induced *beta-catenin*-accumulated crypts in colonic mucosa of rodents as an intermediate biomarker for colon carcinogenesis. *Carcinogenesis* 24: 107-111, 2003.
- 9 Paulsen JE, Steffensen IL, Loberg EM, Husoy T, Namork E and Alexander J: Qualitative and quantitative relationship between dysplastic aberrant crypt foci and tumorigenesis in the Min-/+ mouse colon. *Cancer Res* 61: 5010-5015, 2001.
- 10 Paulsen JE, Loberg EM, Olstorn HB, Knutsen H, Steffensen IL and Alexander J: Flat dysplastic aberrant crypt foci are related to tumorigenesis in the colon of azoxymethane-treated rat. *Cancer Res* 65: 121-129, 2005.
- 11 Femia AP, Bendinelli B, Giannini A *et al*: Mucin-depleted foci have *beta-catenin* gene mutations, altered expression of its protein, and are dose- and time-dependent in the colon of 1,2-dimethylhydrazine-treated rats. *Int J Cancer* 116: 9-15, 2005.
- 12 Femia AP, Dolara P, Giannini A, Salvadori M, Biggeri A and Caderni G: Frequent mutation of *Apc* gene in rat colon tumors and mucin-depleted foci, preneoplastic lesions in experimental colon carcinogenesis. *Cancer Res* 67: 445-449, 2007.
- 13 Paulsen JE, Knutsen H, Olstorn HB, Loberg EM and Alexander J: Identification of flat dysplastic aberrant crypt foci in the colon of azoxymethane-treated A/J mice. *Int J Cancer* 118: 540-546, 2006.
- 14 Yoshimi N, Morioka T, Kinjo T *et al*: Histological and immunohistochemical observations of mucin-depleted foci (MDF) stained with Alcian blue, in rat colon carcinogenesis induced with 1,2-dimethylhydrazine dihydrochloride. *Cancer Sci* 95: 792-797, 2004.
- 15 Kim J, Ng J, Arozullah A, Ewing R *et al*: Aberrant crypt focus size predicts distal polyp histopathology. *Cancer Epidemiol Biomarkers Prev* 17: 1155-1162, 2008.
- 16 Lance P and Hamilton SR: Sporadic aberrant crypt foci are not a surrogate endpoint for colorectal adenoma prevention. *Cancer Prev Res* 1: 4-8, 2008.
- 17 Schoen RE, Mutch M, Rall C *et al*: The natural history of aberrant crypt foci. *Gastrointest Endosc* 67: 1097-1102, 2008.
- 18 Pierre F, Santarelli R, Gueraud F and Corpet DE: Beef meat promotion of dimethylhydrazine-induced colorectal carcinogenesis biomarkers is suppressed by dietary calcium. *Br J Nutr* 99: 1000-1006, 2008.
- 19 Dougherty U, Sehdev A, Cerda S *et al*: Epidermal growth factor receptor controls flat dysplastic aberrant crypt foci development and colon cancer progression in the rat azoxymethane model. *Clin Cancer Res* 14: 2253-2262, 2008.

Received July 18, 2008

Revised October 3, 2008

Accepted October 24, 2008