

Cyclooxygenase-2 Expression Correlates with Apoptosis and Angiogenesis in Endometrial Cancer Tissue

SATOSHI OHNO^{1,2}, YUMIKO OHNO², NOBUTAKA SUZUKI^{1,2}, GEN-ICHIRO SOMA^{3,4} and MASAKI INOUE²

Departments of ¹Complementary and Alternative Medicine Clinical R&D and

²Obstetrics and Gynecology, Kanazawa University, Graduate School of Medical Science, Ishikawa;

³Institute for Health Sciences, Tokushima Bunri University, Tokushima;

⁴Institute for Drug Delivery System, Tokyo University of Science, Chiba, Japan

Abstract. *Background: Recent experimental studies have indicated that cyclooxygenase-2 (COX-2) suppresses tumor-cell apoptosis and induces intratumoral angiogenesis. Patients and Methods: A series of 70 endometrial cancer cases that had undergone a curative resection was studied to determine the correlation between COX-2 expression, apoptosis and angiogenesis in human endometrial cancer tissue. Tissue specimens were evaluated for COX-2, single-strand DNA (ssDNA, apoptosis) and CD31 (angiogenesis) by immunohistochemistry. Results: COX-2 expression was positive exclusively in cancer cells in 37 cases (53%). The apoptotic index was lower in COX-2-positive cancer cells than COX-2-negative cases. Microvessel density was higher in COX-2-positive cancer cases than COX-2-negative cases. COX-2 overexpression was significantly associated with poor prognosis. Conclusion: These results suggested that tumor-produced COX-2, which was associated with inhibiting apoptosis and promoting angiogenesis, provided additional prognostic information in endometrial cancer patients.*

Endometrial cancer is the most common gynecological malignancy in the United States. In Japan, it is the second most common gynecological cancer, but its frequency has dramatically increased in the last decade. Although there are well-established surgical and chemotherapeutic treatments for endometrial cancer, the need for molecular-target therapy has increased, especially for recurrent disease that has acquired radio- or chemoresistance; thus, there is

Correspondence to: Satoshi Ohno, Department of Complementary and Alternative Medicine Clinical R&D, Kanazawa University, Graduate School of Medical Science, 13-1 Takaramachi, Kanazawa, Ishikawa, 920-8640, Japan. Tel: +81 76 265 2147, Fax: +81 76 234 4247, e-mail: satoshi@med.kanazawa-u.ac.jp

Key Words: Cyclooxygenase-2, apoptosis, angiogenesis, endometrial cancer, prognosis.

a need for a better understanding of molecular pathways of endometrial carcinogenesis.

Cyclooxygenase-2 (COX-2), the inducible enzyme expressed at sites of inflammation, has recently emerged as a promising target for cancer therapy. In contrast to normal tissues in which COX-2 is ordinarily not detected, COX-2 is constitutively expressed in a variety of malignant tumors such as colorectal, gastric, esophageal, pancreatic, lung, breast and genitourinary cancer (1). Recent investigations have demonstrated that overexpression of COX-2 correlated with progressive disease and poor prognosis, suggesting that COX-2 may play an important role in cancer development and metastasis (2).

Although the expression of COX-2 interestingly has been found to be stimulated both in the glandular epithelium of proliferative endometrium and in the cancer cells of human endometrial carcinoma, COX-2 expression was higher in endometrial cancer than in normal endometrium. Moreover, COX-2 expression is significantly greater in endometrial adenocarcinoma than in endometrial hyperplasia (3). These findings suggest that COX-2 is involved in the carcinogenesis and tumor progression of endometrial cancer.

Several pathways have been described that link COX-2 and carcinogenesis. COX-2 provides a key enzymatic step required for the production of prostaglandins that, in turn, stimulate angiogenesis and mediate immunosuppression (2). COX-2 also suppresses apoptosis by altering the balance between anti-apoptotic and pro-apoptotic signals in cells (2).

In the light of this evidence, the localization of COX-2 has been widely investigated in a variety of human neoplasms, including endometrial cancer (4-16). However, to date there have been few clinicopathological studies concerning COX-2 mediated apoptosis and angiogenesis in human endometrial cancer tissues.

We therefore examined whether localization of COX-2 expression correlated with clinicopathological factors,

apoptotic index (AI) and microvessel density (MVD) in a large series of endometrial cancer tissues. We also assessed the prognostic significance of COX-2 protein, AI and MVD in endometrial cancer patients.

Patients and Methods

Patients. This study included 70 primary endometrial carcinoma patients who were consecutively admitted, treated and followed-up at the Department of Obstetrics and Gynecology, Kanazawa University Hospital from January 1995 to December 2002. All the patients underwent a total abdominal or radical hysterectomy plus bilateral salphingo-oophorectomy. At the time of celiotomy, peritoneal fluid samples were obtained for cytological testing. Systemic pelvic lymphadenectomy was performed in 51 (72.9%) patients. Paraaortic lymph node sampling was performed in two patients because of visible or palpable enlarged lymph nodes. All the patients were classified by the International Federation of Gynecology and Obstetrics (FIGO) surgical staging system (1988) (17). No patients had remaining macroscopic tumors or known distant metastasis immediately after the time of surgery. High-risk patients (e.g. deep myometrial invasion, cervical involvement, special histology, peritoneal cytology) underwent external radiotherapy and/or six cycles of chemotherapy (Paclitaxel: 180 mg/m², Carboplatin: according to Chatelut's formula [AUC = 5 mg • min/ml]) as post-operative adjuvant therapy. The treatment was followed by a gynecological examination, recording of laboratory data, transvaginal/abdominopelvic ultrasonography, and a radiological investigation. Data from regular follow-up visits to the outpatient department were stored in a database specifically designed for endometrial carcinoma patients. A telephone inquiry to update the present status of all surviving patients was made in July 2003. The exact date of disease recurrence was obtained from the referring physicians or from the physicians who attended the patient for the initial diagnosis of the recurrence. All treatments and clinical research were conducted with written informed consent.

Immunohistochemistry. COX-2, apoptosis (single-strand DNA; ssDNA) and angiogenesis (CD31; platelet-endothelial cell adhesion molecule-1) were evaluated in serial sections stained with appropriate antibodies. Table I shows the primary antibodies, their sources, dilutions, incubation times and epitope retrieval. Slides were deparaffinized, and rehydrated in graded alcohols. Endogenous peroxidase activity was quenched by dipping in 3% hydrogen peroxide for 30 minutes. Staining was performed by the avidin-biotin complex (ABC) technique, using the SAB-PO kit (Nichirei Co., Tokyo, Japan). Color development was carried out with peroxidase substrate 3-amino-9-ethylcarbazole (AEC) against COX-2 and CD31, and 3,3'-diamino-benzidine tetrahydrochloride (DAB) against ssDNA. All the slides were counterstained with Mayer's hematoxylin. Sections without primary antibodies, as well as those with non-immunized mouse serum, served as negative controls.

Evaluation of staining. For evaluation of COX-2, staining intensity was scored as 0 (negative), 1 (weak), 2 (medium), and 3 (strong). Extent of staining was scored as 0 (0%), 1 (1-25%), 2 (26-50%), 3 (51-75%) and 4 (76-100%) according to the percentage of positive staining area in relation to the whole carcinoma area. The sum of

Table I. *Characterization of the antibodies used in this study.*

Antibody (Manufacture)	Species	Dilution	Incubation time (temperature)	Epitope retrieval
COX-2 (TAKARA BIO INC., Shiga, Japan)	Mouse IgG	1:100	Overnight (4°C)	Microwave
Single-strand DNA (DakoCytomation Inc., Carpinteria, USA)	Rabbit IgG	1:100	1 hour (room temperature)	-
CD31 (DakoCytomation Inc., Carpinteria, USA)	Mouse IgG	1:1	1 hour (room temperature)	Microwave

the intensity and extent score was used as the final staining score (0-7) for COX-2. Tumors having a final staining score of ≥4 were considered to exhibit strong expression.

In the assessment of tumor microvessels, the densest vascular areas were identified by scanning tumor sections at lower power (x40). After identification of the densest vascularization, a vessel count was performed on a x400 field. The average vessel number in 5 fields was expressed as the microvessel density (MVD).

To determine the number of apoptotic cells, 5 to 10 representative areas without necrosis and comprising at least 1,000 cancer cells were counted from each sample with a light microscope (x 400 magnification). The results were expressed as the apoptotic index (AI) representing the number of apoptotic cells/1,000 counted cells and recorded in percentages.

Evaluation and counting were conducted by two observers (S.O. and Y.O.) who did not know any details regarding the patients' background.

Statistical analysis. The Chi-square test for 2x2 tables was used to compare the categorical data. The difference in continuous variables between the groups was compared using the Mann-Whitney U-test. In the analysis of relapse-free survival rates, those who died of causes unrelated to endometrial cancer and those who had no detected evidence of disease recurrence were considered to be relapse-free. Life tables were computed using the Kaplan-Meier method while the log-rank test was used to assess statistical significance. A p-value of <0.05 was considered to indicate statistical significance. All statistical analyses were performed using the statistical package StatView version 5.0 for Macintosh (Abacus Concepts, Berkeley, CA, USA).

Results

Characteristics of the patients. The patients' average age at the time of surgery was 57.3 years old (range, 26-78). Patients with endometrial cancer included: 22 with premenopausal status, 4 with perimenopausal status and 44 with postmenopausal status. The patients' mean

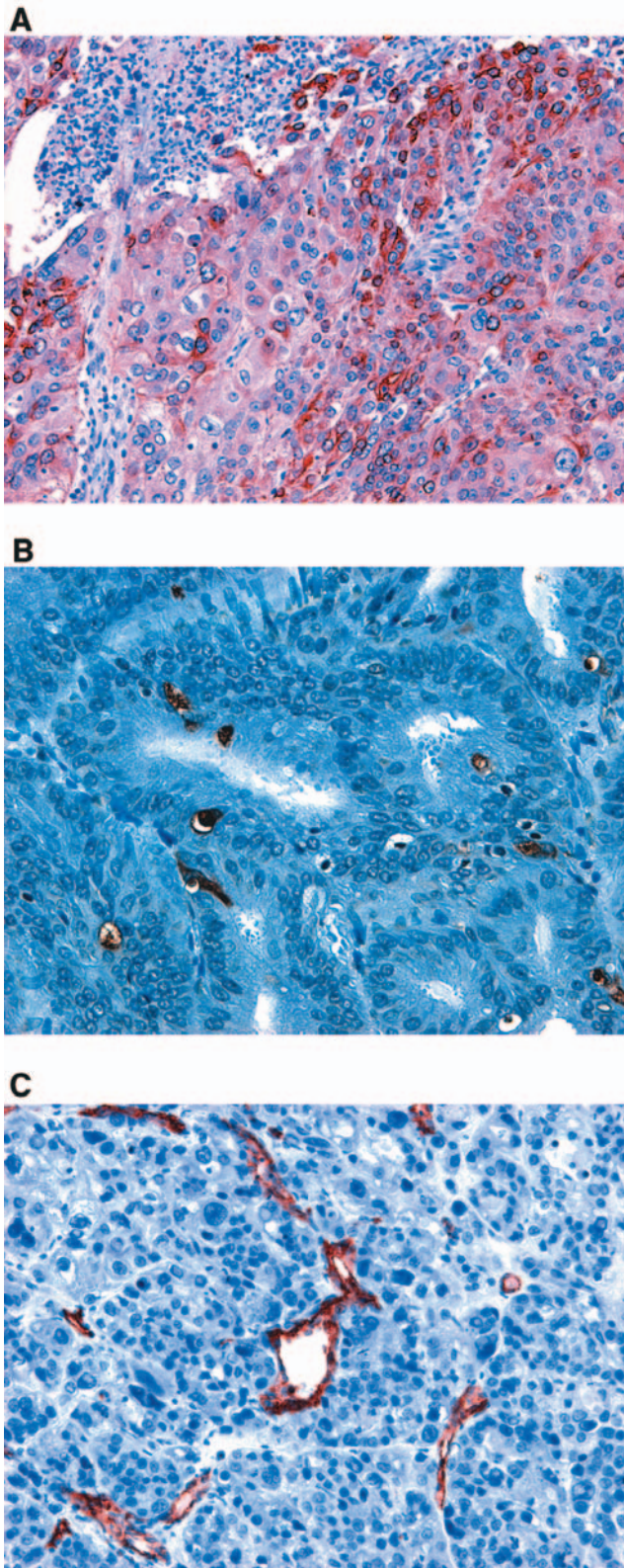


Figure 1. Representative sections of endometrial cancer with immunohistochemical staining of COX-2 (A, x100), apoptotic cells (B, x100) and CD31-positive microvessels (C, x100).

Table II. COX-2 expression and clinicopathological characteristics.

Variables	COX-2 expression		P-value (χ^2 test)
	Strong (n=37)	Weak (n=33)	
Age (years)			
<65 (n=43)	24	19	0.5317
\geq 65 (n=27)	13	14	
FIGO stage			
I (n=52)	24	28	0.0562
II, III, IV (n=18)	13	5	
Lymph node metastasis			
negative (n=65)	34	31	0.7399
positive (n=5)	3	2	
Depth (myometrial invasion)			
a, b (n=53)	25	28	0.0924
c (n=17)	12	5	
Histopathology-degree of differentiation			
Grade 1 (n=38)	21	17	0.6603
Grade 2, 3 (n=32)	16	16	
Menopause			
peri, pre (n=26)	16	10	0.2634
post (n=44)	21	23	
Body mass index			
<25 (n=45)	22	23	0.3722
\geq 25 (n=25)	15	10	

preoperative body mass index (BMI) was 24.0 (range, 16.9 - 32.9). Among the 70 patients, 12 patients (17.1%) had relapses of endometrial cancer at the time of the last follow-up. The median follow-up time for all patients was 3.28 years (range, 0.15-8.50 years).

COX-2 expression. The expression of COX-2 was strong (final staining score of 4-7) in 37 patients (53%) and weak (final staining score of 0-3) in 33 patients (47%). The typical COX-2 expression in endometrial cancer cells is shown in Figure 1A. Although COX-2 overexpression was associated with advanced FIGO stage and more than half myometrial invasion, no statistically significant impact was shown ($p=0.06$ and $p=0.09$, respectively). Patient age, lymph node metastasis, grade of differentiation, menopause and BMI were not associated with COX-2 expression (Table II).

Detection of ssDNA. Almost all of the positively stained cells and bodies were considered to be apoptotic cells and corresponded morphologically to the standard criteria of apoptotic cells including chromatin condensation, nucleolar disintegration and formation of crescentic caps of condensed chromatin at the nuclear periphery (Figure 1B). Nonspecific staining in necrotic foci showed a faint and diffuse staining and could be easily distinguished from the

Table III. Apoptotic index and clinicopathological characteristics.

Variables	Apoptotic index mean±SD* (median)	P-value (Mann-Whitney U-test)
Age (years)		
<65 (n=43)	2.48±1.78 (1.89)	0.3784
≥65 (n=27)	3.03±2.15 (3.04)	
FIGO stage		
I (n=52)	2.70±1.95 (2.07)	0.9571
II, III, IV (n=18)	2.65±1.94 (2.34)	
Lymph node metastasis		
negative (n=65)	2.58±1.83 (1.97)	0.1642
positive (n=5)	4.17±2.85 (5.38)	
Depth (myometrial invasion)		
a, b (n=53)	2.80±2.02 (2.30)	0.4978
c (n=17)	2.35±1.65 (1.89)	
Histopathology-degree of differentiation		
Grade 1 (n=38)	2.57±1.96 (2.07)	0.5437
Grade 2, 3 (n=32)	2.83±1.92 (2.44)	
Menopause		
peri, pre (n=26)	2.11±1.68 (1.72)	0.0556
post (n=44)	3.03±2.01 (2.69)	
Body mass index		
<25 (n=45)	2.73±1.87 (2.24)	0.6949
≥25 (n=25)	2.61±2.07 (2.30)	

*SD: standard deviation.

apoptotic nuclei by simple morphological examination. The AI varied from 0 to 7.44% with a median of 2.27%. The mean AI of all cases was 2.69 (standard deviation, 1.93). There were no statistically significant associations between AI and clinicopathological characteristics (Table III).

CD31 expression. CD31-positive endothelial cells lining microvessels within the tumors were detected in 58 out of the 70 patients (Figure 1C). The MVD varied from 0 to 66.8 with a median of 13.6. The mean MVD of all cases was 20.0 (standard deviation, 20.1). MVD was significantly higher in tumors with advanced FIGO stage and more than half myometrial invasion (Table IV). The other clinicopathological characteristics were not associated with MVD.

Associations between COX-2 expression and AI and MVD. The AI in the strong COX-2 expression group was significantly lower than in the weak COX-2 expression group (Figure 2A). Conversely, there was significantly higher MVD in the strong COX-2 expression group than in the weak COX-2 expression group (Figure 2B).

Survival analysis. Strong expression of COX-2 was a factor negatively influencing the relapse-free survival rate by univariate analysis ($p=0.0294$). The median values of AI

Table IV. Microvessel density and clinicopathological characteristics.

Variables	Microvessel density mean±SD* (median)	P-value (Mann-Whitney U-test)
Age (years)		
<65 (n=43)	19.3±19.9 (13.6)	0.8135
≥65 (n=27)	21.3±20.8 (13.6)	
FIGO stage		
I (n=52)	16.9±18.3 (10.9)	0.0191
II, III, IV (n=18)	29.2±23.0 (19.6)	
Lymph node metastasis		
negative (n=65)	19.9±20.0 (13.6)	0.8999
positive (n=5)	21.8±24.8 (10.8)	
Depth (myometrial invasion)		
a, b (n=53)	17.9±20.0 (10.8)	0.1022
c (n=17)	26.6±19.9 (19.8)	
Histopathology-degree of differentiation		
Grade 1 (n=38)	12.6±14.7 (6.0)	0.0019
Grade 2, 3 (n=32)	28.8±22.3 (19.4)	
Menopause		
peri, pre (n=26)	17.1±18.2 (13.9)	0.5223
post (n=44)	21.7±21.2 (12.2)	
Body mass index		
<25 (n=45)	18.2±19.2 (13.6)	0.4388
≥25 (n=25)	23.3±21.8 (13.6)	

*SD: standard deviation.

and MVD were used as cut-off points to stratify patients into two groups. The AI and MVD had no statistically significant impact on relapse-free survival ($p=0.8823$ and $p=0.4710$, respectively).

Discussion

In this study, immunohistochemical analysis revealed that COX-2 overexpression was correlated with lower AI and higher MVD in human endometrial cancer tissues. Moreover, strong expression of COX-2 was significantly associated with poor prognosis of the endometrial cancer patients.

COX-2 expression was not associated with clinicopathological factors in this study.

There are a number of previous reports relating COX-2 expression to clinicopathological data of endometrial cancer tissues (4-16). However, there is no consensus as to whether there is a relationship between expression of COX-2 and clinicopathological features of endometrial cancer. Some reports (6, 8) have shown that COX-2 overexpression was associated with deep myometrial invasion and poor histological differentiation. However, some reports (11, 15) have argued that COX-2 levels significantly decreased with advancement of FIGO stage and poor histological differentiation. Other reports could not find a relationship

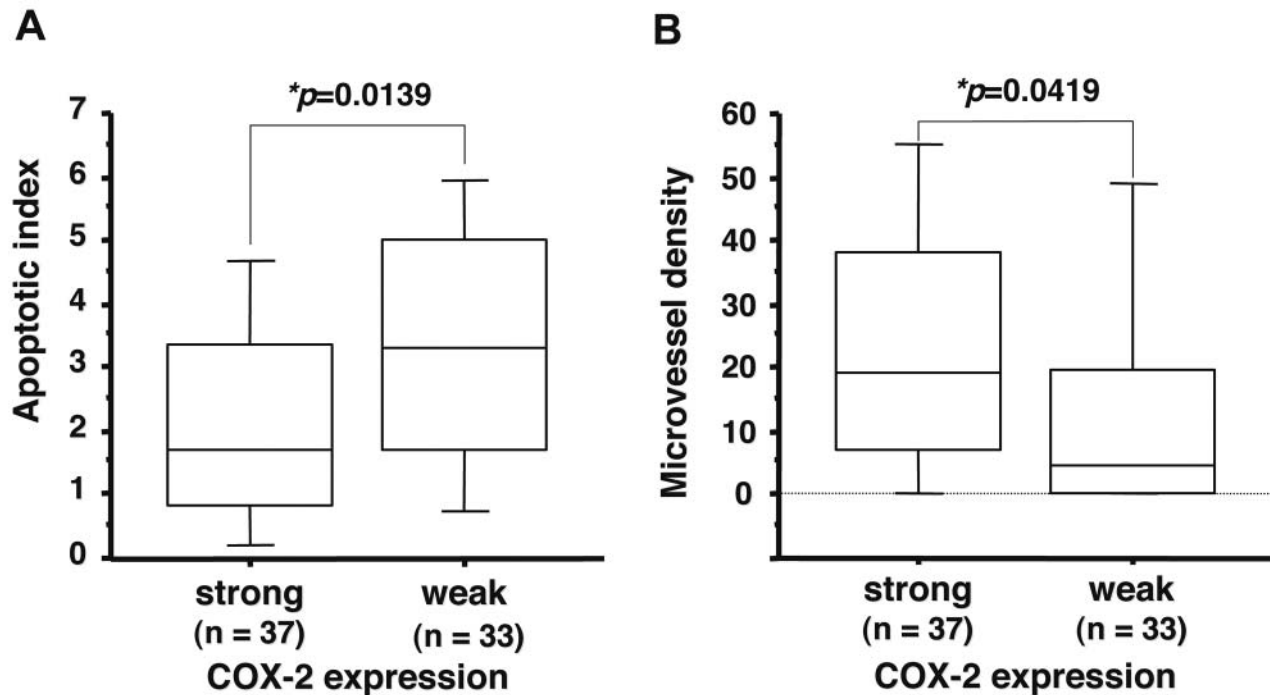


Figure 2. Differences of apoptotic index (A) and microvessel density (B) by COX-2 expression were observed by using the Mann-Whitney U-test. In the box and whisker plot, the median values are indicated by horizontal bars. The vertical bars indicate the 10th and 90th percentiles, and the horizontal boundaries of the boxes represent the 1st and 3rd quartiles.

between COX-2 expression and clinicopathological factors. This contradiction between studies of the same tumor type may reflect differences in the number, grade and size of tumors included in each study. Moreover, it should also be noted that a wide variety of methods was used to assess COX-2 production in these studies. This diverse approach may also contribute to the lack of consistency in their findings.

The COX-2 pathway might play a key role in preventing apoptosis in many cell types and non-steroidal anti-inflammatory drugs (NSAIDs) reverse the response by inhibiting the COX-2 pathway (18). The preventive role of COX-2 in apoptosis is attributable to two possible mechanisms: those mediated by generation of prostaglandin products (the PGE₂-EP pathway) and those mediated by removal of the substrate, arachidonic acid, *via* COX-2 catalytic activity (2). In the downstream signaling pathway, preventive effect of COX-2 in apoptosis, the following three factors have been shown to be involved, the Bcl-2 mediated pathway (19), the nitric oxide pathway (20) and the amount of intracellular ceramide (21). In addition to the above mechanisms, theoretically COX-2 could prevent apoptosis by enhancing the proliferative pathways, such as the Akt kinase-mediated pathway or the NF- κ B pathway (22).

On the other hand, St-Germain *et al.* demonstrated that the PI3K/Akt survival pathway is involved in the regulation of COX-2 and PGE₂ synthesis in human endometrial cancer cells

(23). Moreover, they pointed out that regulation of COX-2 protein expression by Akt in mutated PTEN endometrial cancer cells is mediated through the NF- κ B/I κ B pathway (24).

Although an inverse association between COX-2 expression and tumor-cell apoptosis was shown, no direct cause-effect links between COX-2 expression and anti-apoptotic or pro-apoptotic molecules were assessed in this study. Further studies are needed to clarify the relationship between COX-2 and anti-apoptotic and/or proliferative molecules in human endometrial cancer tissues.

There are a few reports relating COX-2 expression to angiogenesis as measured by CD34 (15) or factor VIII (7, 11) in endometrial cancer tissues and a statistically significant relationship between COX-2 and angiogenesis as measured by CD31 was found in this study. CD31 is a member of the immunoglobulin superfamily that plays a role in a number of endothelial cell functions including migration, angiogenesis and transmigration of leukocytes across the endothelium. Our study revealed that angiogenesis as measured by CD31 associated with advanced FIGO stage and more than half myometrial invasion, but not with patient's prognosis.

With regard to survival analysis, Ferrandina *et al.* (8) observed that COX-2 positive patients showed a trend towards shorter disease-free survival than COX-2 negative patients ($p=0.09$). Joen *et al.* (10) concluded that the hazard

ratio of COX-2 positivity (1.83, 95% confidence interval; 0.42-7.98) was higher than COX-2 negativity in multivariate Cox regression analysis, but statistical significance was not obtained. Furthermore, our study confirmed that the expression level of COX-2 was found to be a significant predictor of disease relapse in univariate analysis ($p=0.03$).

In conclusion, our study has shown that tumor-produced COX-2, which was associated with inhibiting apoptosis and promoting angiogenesis, provided additional prognostic information in endometrial cancer patients.

Acknowledgements

This work was supported by a Grant-in-Aid for Young Scientists (B) (No. 17791108 and 19791140) from the Ministry of Education, Culture, Sports, Science and Technology of Japan, and by the Megumi Medical Foundation, Kanazawa, Japan. We are grateful to the staff at the Pathology Section, Kanazawa University Hospital, for collecting the samples and providing paraffin-embedded tissues.

References

- Turini ME and DuBois RN: Cyclooxygenase-2: a therapeutic target. *Annu Rev Med* 53: 35-57, 2002.
- Ohno S, Ohno Y, Suzuki N, Inagawa H, Kohchi C, Soma G and Inoue M: Multiple roles of cyclooxygenase-2 in endometrial cancer. *Anticancer Res* 25: 3679-3687, 2005.
- Nasir A, Boulware D, Kaiser HE, Lancaster JM, Coppola D, Smith PV, Hakam A, Siegel SE and Bodey B: Cyclooxygenase-2 (COX-2) expression in human endometrial carcinoma and precursor lesions and its possible use in cancer chemoprevention and therapy. *In Vivo* 21: 35-43, 2007.
- Jabbar HN, Milne SA, Williams AR, Anderson RA and Boddy SC: Expression of COX-2 and PGE synthase and synthesis of PGE2 in endometrial adenocarcinoma: a possible autocrine/paracrine regulation of neoplastic cell function *via* EP2/EP4 receptors. *Br J Cancer* 28: 1023-1031, 2001.
- Uotila PJ, Erkkola RU and Klemi PJ: The expression of cyclooxygenase-1 and -2 in proliferative endometrium and endometrial adenocarcinoma. *Ann Med* 34: 428-433, 2002.
- Cao QJ, Einstein MH, Anderson PS, Runowicz CD, Balan R and Jones JG: Expression of COX-2, Ki-67, cyclin D1, and P21 in endometrial endometrioid carcinomas. *Int J Gynecol Pathol* 21: 147-154, 2002.
- Fujiwaki R, Iida K, Kanasaki H, Ozaki T, Hata K and Miyazaki K: Cyclooxygenase-2 expression in endometrial cancer: correlation with microvessel count and expression of vascular endothelial growth factor and thymidine phosphorylase. *Hum Pathol* 33: 213-219, 2002.
- Ferrandina G, Legge F, Ranelletti FO, Zannoni GF, Maggiano N, Evangelisti A, Mancuso S, Scambia G and Lauriola L: Cyclooxygenase-2 expression in endometrial carcinoma: correlation with clinicopathologic parameters and clinical outcome. *Cancer* 95: 801-807, 2002.
- Landen CN Jr, Mathur SP, Richardson MS and Creasman WT: Expression of cyclooxygenase-2 in cervical, endometrial, and ovarian malignancies. *Am J Obstet Gynecol* 188: 1174-1176, 2003.
- Jeon YT, Kang S, Kang DH, Yoo KY, Park IA, Bang YJ, Kim JW, Park NH, Kang SB, Lee HP and Song YS: Cyclooxygenase-2 and p53 expressions in endometrial cancer. *Cancer Epidemiol Biomarkers Prev* 13: 1538-1542, 2004.
- Toyoki H, Fujimoto J, Sato E, Sakaguchi H and Tamaya T: Clinical implications of expression of cyclooxygenase-2 related to angiogenesis in uterine endometrial cancers. *Ann Oncol* 16: 51-55, 2005.
- Ohno Y, Ohno S, Suzuki N, Kamei T, Inagawa H, Soma G and Inoue M: Role of cyclooxygenase-2 in immunomodulation and prognosis of endometrial carcinoma. *Int J Cancer* 114: 696-701, 2005.
- Ferrandina G, Ranelletti FO, Gallotta V, Martinelli E, Zannoni GF, Gessi M and Scambia G: Expression of cyclooxygenase-2 (COX-2), receptors for estrogen (ER), and progesterone (PR), p53, Ki67, and neu protein in endometrial cancer. *Gynecol Oncol* 98: 383-389, 2005.
- Kilic G, Gurates B, Garon J, Kang H, Arun B, Lampley CE, Kurzel R and Ashfaq R: Expression of cyclooxygenase-2 in endometrial adenocarcinoma. *Eur J Gynaecol Oncol* 26: 271-274, 2005.
- Li W, Xu RJ, Zhang HH and Jiang LH: Overexpression of cyclooxygenase-2 correlates with tumor angiogenesis in endometrial carcinoma. *Int J Gynecol Cancer* 16: 1673-1678, 2006.
- Erkanli S, Bolat F, Kayaselcuk F, Demirhan B and Kuscü E: COX-2 and survivin are overexpressed and positively correlated in endometrial carcinoma. *Gynecol Oncol* 104: 320-325, 2007.
- Pecorelli S, Benedet JL, Creasman WT and Shepherd JH: FIGO staging of gynecologic cancer. 1994-1997 FIGO Committee on Gynecologic Oncology. *International Federation of Gynecology and Obstetrics. Int J Gynaecol Obstet* 64: 5-10, 1999.
- Yoshinaka R, Shibata MA, Morimoto J, Tanigawa N and Otsuki Y: COX-2 inhibitor celecoxib suppresses tumor growth and lung metastasis of a murine mammary cancer. *Anticancer Res* 26: 4245-4254, 2006.
- Sheng H, Shao J, Morrow JD, Beauchamp RD and DuBois RN: Modulation of apoptosis and Bcl-2 expression by prostaglandin E2 in human colon cancer cells. *Cancer Res* 58: 362-366, 1998.
- Cao Y and Prescott SM: Many actions of cyclooxygenase-2 in cellular dynamics and in cancer. *J Cell Physiol* 190: 279-286, 2002.
- Chan TA, Morin PJ, Vogelstein B and Kinzler KW: Mechanisms underlying nonsteroidal antiinflammatory drug-mediated apoptosis. *Proc Natl Acad Sci USA* 95: 681-686, 1998.
- Sheng H, Shao J, Washington MK and DuBois RN: Prostaglandin E2 increases growth and motility of colorectal carcinoma cells. *J Biol Chem* 276: 18075-18081, 2001.
- St-Germain ME, Gagnon V, Mathieu I, Parent S and Asselin E: Akt regulates COX-2 mRNA and protein expression in mutated-PTEN human endometrial cancer cells. *Int J Oncol* 24: 1311-1324, 2004.
- St-Germain ME, Gagnon V, Parent S and Asselin E: Regulation of COX-2 protein expression by Akt in endometrial cancer cells is mediated through NF-kappaB/IkappaB pathway. *Mol Cancer* 3: 7, 2004.

Received April 23, 2007

Revised July 16, 2007

Accepted July 30, 2007