

## A Randomized Phase III study: Comparison between Intravenous and Intraarterial ACNU Administration in Newly Diagnosed Primary Glioblastomas

F. IMBESI<sup>1</sup>, E. MARCHIONI<sup>2</sup>, E. BENERICETTI<sup>3</sup>,  
F. ZAPPOLI<sup>4</sup>, A. GALLI<sup>1</sup>, M. CORATO<sup>2</sup> and M. CERONI<sup>1,2</sup>

<sup>1</sup>Department of Neurology Policlinico di Monza, Monza;

<sup>2</sup>Neurological Institute IRCCS Mondino, Pavia;

<sup>3</sup>Department of Neurosurgery Parma Hospital, Parma;

<sup>4</sup>Neuroradiology - Neurological Institute IRCCS Mondino, Pavia, Italy

**Abstract.** *Background:* In this randomized phase III study, the effectiveness as well as the side-effects of intraarterial [i.a.] (17 patients) versus intravenous [i.v.] (16 patients) ACNU [Nimustine] administration in newly diagnosed glioblastoma, were compared. *Patients and Methods:* All patients underwent extensive surgical resection, and both groups were homogeneous for the other known risk factors. Thirty-three patients with glioblastoma were treated with ACNU at the dose of 80-100 mg/m<sup>2</sup>. Treatment was repeated every 5-8 weeks for a minimum of 2 and maximum of 14 cycles. Total survival time (TST) and to time to progression were chosen as outcome variables. *Results and Conclusion:* No significant differences in systemic and hematological toxicity between the i.a. and i.v. ACNU administration routes were detected. In both groups, tolerance of the procedure was excellent. Analysis of the main outcome measured showed no significant differences between i.a. and i.v. ACNU administration: time to progression was 6 months for i.a. ACNU and 4 months for i.v. ACNU and total survival time was 17 months for i.a. ACNU and 20 months for i.v. ACNU. In spite of ACNU dose incrementation, obtained through i.a. route administration, and subsequent higher concentration in the tumor bed, no improvement could be achieved in effectiveness.

Surgical excision is the best therapeutic option for malignant gliomas (1), and adjuvant radiotherapy and chemotherapy are usually added. Nitrosoureas were among the first antitumoral compounds selected for the treatment of malignant cerebral

gliomas, due to their lipophilic characteristics and their capacity to cross the blood-brain barrier. The bis-chloro-ethyl-nitrosourea (carmustine, BCNU) was tested by intravenous (i.v.) administration in a phase III study in various malignant gliomas in conjunction with radiotherapy and was proven to be moderately efficacious (2). BCNU, however, shows systemic and central nervous system (CNS) toxicity (leucoencephalopathy) (3) and severe cumulative toxicity with high incidence of pulmonary fibrosis (20%) after 6-8 cycles (4). Moreover, trials employing BCNU by intraarterial (i.a.) routes were discontinued due to unacceptable CNS toxicity with severe frequent leucoencephalopathy (2, 3). The 1-(4-amino-2-methyl-5-pyrimidinyl) methyl-3-(2-chloroethyl)-3-nitrosourea hydrochloride (Nimustine, ACNU) has been used for both primary and recurrent malignant gliomas. In previous studies, ACNU was reported to give median survival comparable with BCNU, with a greater number of long-term survivors and less toxicity (5), particularly by the i.a. route (6-8). Chemotherapeutic drugs may be delivered locally in the brain by direct injection into the internal carotid artery and its branches or into a vertebral artery. This procedure achieves high drug concentration within the tumor and lower systemic exposure. Mathematical models predict up to 5-fold higher drug delivery in the tumor region with i.a. versus i.v. infusion (9, 10), mostly occurring at the first passage through the brain tumor (10, 11).

Phase II trials of i.a. nitrosoureas and other drugs, singly or in combination, have been performed (12). However, it is unclear whether an increased delivery translates into a clinical advantage for the patients. Although systemic toxicity seems to be lower with i.a. compared with i.v. administration, side-effects involving brain and eye have been found significantly higher in some studies (2, 13). I.a. chemotherapy for gliomas is generally restricted to single lesions for which arterial blood is supplied by a single intracerebral artery.

*Correspondence to:* Prof. Mauro Ceroni, 20052, Monza Italy, Policlinico di Monza, Department of Neurology, Via Amati 111, 20052 Monza, Italy. Tel: (+39)0392810390, Fax: (+39)0392810470, e-mail: mceroni@unipv.it / mauro.ceroni@policlinicodimonza.it

*Key Words:* Glioma ACNU, intraarterial, intravenous.

This difference in indication for *i.a.* and systemic chemotherapy makes comparisons difficult to perform. Complete or partial responses have been demonstrated for PCV regimen in oligodendrogliomas and may be obtained with ACNU in grade III astrocytomas (14). In glioblastoma, no complete or partial responses to any chemotherapy or radiotherapy have been proven; only small nodules with contrast enhancement may disappear with *i.v.* ACNU (personal experience). Chemotherapy with ACNU may be employed as first choice treatment because of its safety, life quality respect, and possibility of long-term continuous treatment. Particularly when ACNU is effective, treatment may be continued for many cycles (we personally performed 25 cycles); in these cases, increase in tumor growth may occur if treatment is interrupted. Other treatments, *e.g.* BCNU and the PCV regimen, may be effective in malignant gliomas, but must be discontinued because of their cumulative toxicity.

In this study, *i.a.* and *i.v.* routes for ACNU administration were directly compared in the unique tumor type glioblastoma by a phase III randomized trial to understand whether ACNU dose magnification by *i.a.* administration increases drug effectiveness.

## Patients and Methods

**General admission criteria.** Eligibility criteria included: a) all patients were 18 years or older; b) they had newly-diagnosed histologically-verified supratentorial glioblastoma; c) they underwent extensive surgical resection; d) the tumor had a unilateral localization with unique arterial supply; e) Karnofsky performance status score was 70 or greater; f) life expectancy was 2 months or more; g) WBC were over 3500 and PLT over 90000; h) informed consent was obtained from all patients.

**Chemotherapy.** *I.a.* or *i.v.* ACNU treatment (80-90 mg/m<sup>2</sup> every 5-6 weeks) was assigned by central randomization. Allocation was concealed from the medical staff until the last day before treatment onset. All patients were hospitalized.

**a) *I.a.* administration.** The Seldinger method was adopted. *I.a.* ACNU was administered through a catheter placed into the femoral artery with the tip placed in the appropriate artery which was confirmed by angiography. If the tumor received blood supply from the anterior and/or medial cerebral artery, a full dose of ACNU was given *via* the ipsilateral internal carotid artery with the catheter tip placed just distal to the carotid bifurcation. If the tumor received a blood supply from the posterior cerebral artery, a full ACNU dose was given *via* a vertebral artery with the tip of the catheter placed in the first segment of the artery. The solution was infused at the rate of 6 ml per min. On the day before chemotherapy, all patients received 16 mg *i.m./i.v.* dexametasone and *i.v.* 18% mannitol 250 ml. On the day of the procedure, mannitol was repeated, and 3 mg *i.v.* granisetron diluted with 100 ml physiological solution were administered twice before and after the procedure. To avoid gastric upset, patients received 300 mg ranitidine in the days before and after treatment. In the follow-up, dexametasone 4-16 mg *i.m./day* and verapamil 80 mg/twice a day orally were administered for 10 days. *I.a.* chemotherapy was

continued until a maximum of 6 course. Patients who completed the 6-course *i.a.* schedule were admitted to receive further *i.v.* ACNU administration.

**b) *I.v.* administration.** Patients received 80-90 mg/m<sup>2</sup> ACNU *i.v.* in less than 10 minutes diluted in 100 ml physiological solution after being given 3 mg granisetron diluted in 100 ml physiological solution. An additional 100 ml physiological solution was administered afterwards to minimize venous wall ACNU toxicity. Chemotherapy continued until the final phase of the disease. *I.a.* and *i.v.* ACNU cycles were repeated every 5 weeks or after a longer period according to hematological results at the 5th week.

**Ancillary treatments.** Steroids (desamethason) and antiepileptic drugs were added to the treatment schedule according to the specific needs.

**Toxicity assessment.** Hematological toxicity was screened during the third, fourth and fifth week after each course. Toxicity was graded according to WHO toxicity criteria.

**Determination of the extent of surgery and radiological follow-up.** The extent of surgery was determined comparing the pre-operative and the first post-operative MRI with gadolinium at least 14 days after surgery. Classification criteria were established as follows: gross total resection – disappearance of any contrast enhancement, and subtotal removal – persistence of nodular contrast enhancement. Pre-treatment brain MRI was performed 2-3 weeks after surgery and no more than 48 hours before chemotherapy onset. Follow-up MRI examinations were taken before every chemotherapy course. Classification of cases (total *versus* partial resection) was independently carried out by 2 neuroradiologists, who were blinded to the treatments. Disagreements were resolved by discussion.

**Radiotherapy.** Whole brain radiotherapy (60-64 Gy) was begun after 6 courses of *i.a.* or *i.v.* chemotherapy to avoid both the effect of blood-brain barrier damage on the drug penetration and the potential risk of leukoencephalopathy occurrence in the *i.a.* group of patients due to vessel wall damage.

## Results

**Patient population.** Seventy patients were enrolled over 2 years, but only 43 were eligible for our study. Exclusion reasons were as follows: 4 patients refused to undergo *i.a.* chemotherapy; 3 had arterial atherosclerosis which hindered *i.a.* administration; 20 had a diffuse or bilateral disease.

**a) *I.a.* group:** 17 patients (12 men and 5 women), mean age 54.5 years and whose Karnofsky mean score was 88, received *i.a.* infusion of ACNU (see Table I). Each patient received a number of courses up to 6 for a total of 85 courses (median=4 and mean=4.17). Among these 17 patients, 5 were shifted to *i.v.* chemotherapy, after 1 (2 patients), 2 (2 patients) and 3 (1 patient) *i.a.* courses because of disease spread and exit from the study.

**b) *I.v.* group:** 16 patients (8 men and 8 women) were treated with *i.v.* infusion of ACNU. The mean age was 58 years and mean Karnofsky score was 82 (see Table I). Each patient

Table I. Patient general features.

Characteristics	Treatment arm	
	Intraarterial [N=17]	Intravenous [N=16]
Sex (M/F)	12/5	8/8
Age (years)		
18 to 54 years	10	4
over 55 years	7	12
Mean	54.5	58
Range	(41-67)	(32-69)
Karnofsky (range: 70-100)	Median : 88	Median : 82
Location		
Frontal lobe	5 [3 left; 2 right]	10 [6 left; 4 right]
Temporal lobe	12 [7 left; 5 right]	4 [3 left; 1 right]
Parietal lobe	0	2 [right]
Extent of surgery		
Gross total	17	10
Subtotal	0	6

underwent a number of courses which ranged from 2 to 10 for a total of 112 (median=4 and mean=4.18). Five patients could not be followed-up until the end of treatment because they refused to continue chemotherapy and left the study. The patient characteristics are listed in Table I.

*Toxicity. a) Systemic toxicity.* We found no significant differences between *i.a.* and *i.v.* treatments in hematological and hepatic tolerance. Among the 85 courses of *i.a.* ACNU, we observed 3 cases of hematological toxicity (WHO=2). Among the 112 courses of *i.v.* ACNU, we observed 8 cases of hematological toxicity: 6 cases (WHO=1), 2 (WHO=2). No case of nausea or vomiting was observed. In none of the treated cases was ACNU withdrawal necessary.

*b) Neurological toxicity.* no signs of neurological toxicity were observed in the *i.v.* ACNU group. *I.a.* ACNU caused, in 1 case, a delayed (2 weeks following the procedure) left side hemiparesis due to an ischemic lesion in the territory of the right MCA. The patient presented with an anatomical variant: he had lack of the A1 left anterior cerebral artery trait and origin of this artery from the anterior communicant artery. Thus *i.a.* ACNU administration into the internal carotid artery produced increased drug dosage in the middle cerebral artery and probably induced arterial wall damage and occlusion. We did not observe transient or permanent effects related to the technical procedures.

Table II. Response to *i.a.* and *i.v.* chemotherapy.

	PD	SD	PR	CR
Intraarterial	7	7	3	0
Intravenous	9	7	0	0

PD: progressive disease; SD: stable disease; PR: partial response; CR: complete remission.

Table III. Time to tumor progression.

	3 months	6 months	9 months	12 months
ACNU <i>i.a.</i>	82%	41%	6%	6%
ACNU <i>i.v.</i>	75%	31%	12.5%	12.5%

Table IV. Survival time.

	6 months	12 months	18 months	24 months	36 months
ACNU <i>i.a.</i>	94%	59%	18%	12%	12%
ACNU <i>i.v.</i>	100%	44%	25%	19%	6%

Results of MRI, according to Mc Donald criteria, following at least 2 CHT courses are illustrated in Table II.

The Kaplan-Meier progression-free period estimates of patients in the 2 treatment arms are depicted in Figure 1.

The median time to tumor progression of the patients treated with *i.a.* ACNU was 6 months (*i.c.* 95% 3.9-8.2). The median time to tumor progression of the patients treated with *i.v.* ACNU was 4 months (*i.c.* 95% 2.7-5.3). The difference between the 2 groups is not statistically significant. TTP rates at 3, 6, 9 and 12 months are depicted in Table III.

The Kaplan-Meier survival estimates of patients in the 2 treatment arms are depicted in Figure 2.

The median survival time was 17 months and 20 months, respectively for *i.a.* and *i.v.* ACNU. The difference between the two groups is not statistically significant. Survival rates at 12, 18, 24 and 36 months are depicted in Table IV.

## Discussion

Intraarterial chemotherapy represents an attractive strategy to reach a many-fold delivery advantage over *i.v.* administration, both in terms of peak concentration and total drug exposure (AUC), minimizing systemic toxicity (15, 16).

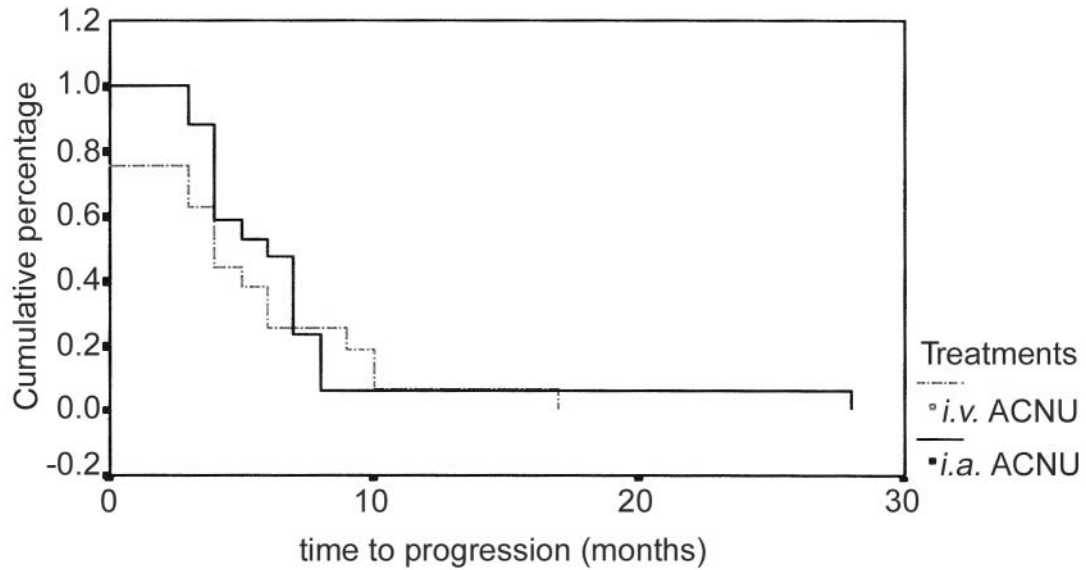


Figure 1. Comparison between *i.a.* and *i.v.* ACNU: time to progression.

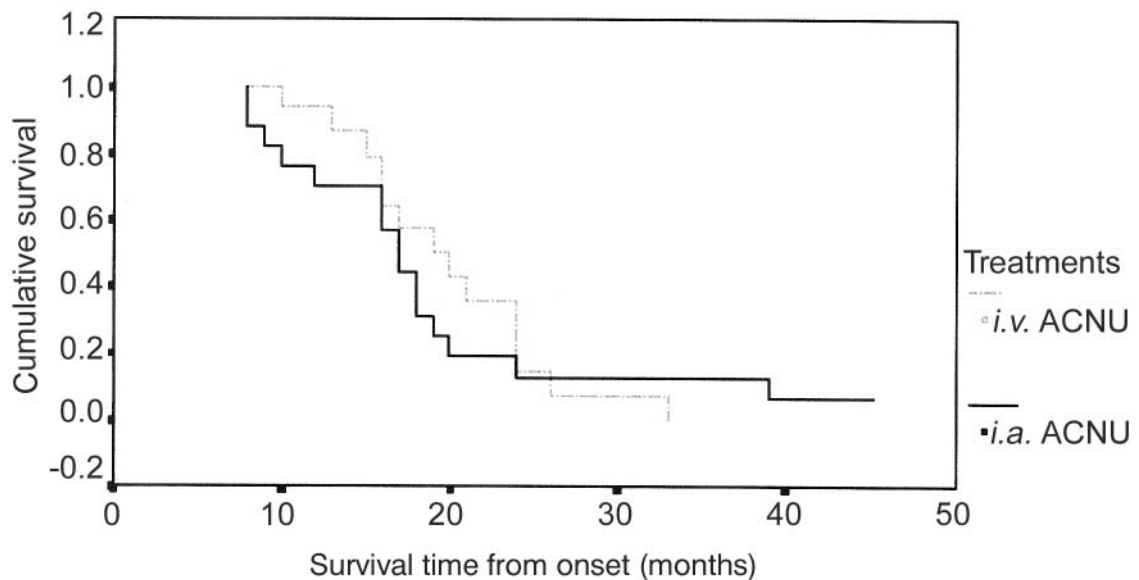


Figure 2. Comparison between *i.a.* and *i.v.* ACNU: survival function.

In order to assess a systematic review on *i.a.* chemotherapy in neurooncology, we performed a "high sensitivity" bibliographic search strategy mainly focused on randomized clinical trials (RCTs) detection (12). The literature concerning nitrosoureas contains several uncontrolled case series (17) but only two phase III randomized open studies (2, 18), respectively focused on BCNU and ACNU comparison of systemic *versus i.a.* drug administration. In the

first study, over 300 patients, comprising glioblastomas, anaplastic astrocytomas and oligodendrogliomas, received *i.v.* or *i.a.* carmustine, with or without the addition of *i.v.* fluorouracil (2). The median survival time was 11.2 months for the *i.a.* carmustine group and 14.0 months for the *i.v.* carmustine group, with 13% and 25% probabilities of 2 years survival, respectively. The addition of fluorouracil had no impact on survival. Most of the survival differences between

the 2 groups resulted from a shorter survival time for the non-glioblastoma *i.a.* patients, most of which had anaplastic astrocytoma. Accrual to the study was halted early because serious toxicity was demonstrated in the *i.a.* group. Sixteen *i.a.* patients (10%) developed severe leukoencephalopathy, and 26 patients (15%) developed visual loss ipsilateral to the infused carotid artery.

In the second study (18), *i.a.* ACNU was compared with *i.v.* ACNU drug administration. *I.a.* ACNU was administered every 6 weeks for at most 3 times. The 3 courses of *i.a.* administration were followed by *i.v.* administration every 6 weeks. In this experimental design, *i.a.* ACNU potential effectiveness might have been overlooked because of the prolonged *i.v.* treatment common to the 2 groups. This article concluded that no difference exists between *i.a.* and *i.v.* ACNU administration routes in terms of drug effectiveness. A number of retrospective and/or prospective uncontrolled trials report controversial conclusions, most of which indicate a mild to moderate beneficial increased effectiveness following *i.a.* administration of various chemotherapeutic drugs (19).

These conclusions are difficult to evaluate since the largest studies were performed with combined drug protocols and irrespectively of radiation therapy schedules. Other problems concern the poor validity of results due to the lack of an adequate number of *i.a.* cycles (20-22). Other factors could have contributed to low cycle number: intrinsic drug toxicity (BCNU in particular), side-effects due to the technical procedure, patients with short life expectancy. Both uncontrolled series and controlled trials evaluated the effects of brief courses of *i.a.* drug administration followed by systemic chemotherapy *versus* systemic chemotherapy alone. Most of the trials also included patients with bilateral supratentorial lesions, which by definition cannot be reached by adequate drug amount using the *i.a.* procedure.

In our study, no significant differences were observed between *i.a.* and *i.v.* ACNU administration at the same dosage in systemic and hematological toxicity, due to the excellent tolerability observed with both treatment routes. A unique neurological complication was observed in 1 out of 17 patients (85 cycles) after *i.a.* ACNU administration. In our hands, *i.a.* administration of ACNU can be considered a safe treatment. ACNU, if compared with other nitrosoureas such as BCNU, is significantly safer. Other patients not included in the study underwent over 20 cycles of systemic ACNU without complications due to cumulative toxicity. No drop outs were recorded in our study. This randomized controlled trial shows that *i.a.* and *i.v.* administration of the nitrosourea ACNU produces similar therapeutic effects in newly-diagnosed glioblastoma patients. Both primary outcomes, measured as "total survival time" and "time to tumor progression", did not differ between the 2 groups of patients.

This study was small, but included specific criteria for patient eligibility, *i.e.* MRI evidence of a strictly unilateral supratentorial mass, the pre-radiotherapy administration of the drug and only one type of tumor-glioblastoma. The first criterion, which in our opinion represents the real indication for *i.a.* administration in neurooncology, improves the consistency of treatment comparison since it increases homogeneity within and between groups. The second criterion essentially pertains to the potential loss of chemo-sensitivity and the capacity to reach the target in the irradiated tumor (20), and is aimed at improving drug penetration and effectiveness and at avoiding a potential confounding factor. The final criterion avoids heterogeneity in the patient natural survival duration and chemotherapy sensitivity by selecting the most frequent and less chemotherapy-sensitive glioma. These eligibility criteria contribute to strengthen study results. Moreover, ACNU safety and tolerability, given by both *i.a.* and *i.v.* administration routes, allowed us to complete the scheduled protocol, so that 90% of patients received 6 therapeutic cycles in the *i.a.* group and at least 10 cycles in the *i.v.* one. These values are significantly higher than any other single-agent chemotherapy application reported in the literature (19).

The real question is why all data derived from controlled studies confirm that no advantage has been observed when the drug is given by locoregional administration compared to the systemic one. In other words, why does the increase in drug delivery to the tumor bed not translate into a real advantage for the patients, considering both total survival time and time to progression outcomes. Moreover, trials on small series of cases, including high-dose poly-chemotherapy followed by bone marrow rescue, produced non-significant survival improvement in comparison with the general population of glioblastoma patients treated with conventional procedures (23). Systematic reviews (12), comparing the effects of poly-chemotherapy and mono-chemotherapy, showed no significant differences in both total survival time and time to progression between these treatments. In recent years, chemotherapy effectiveness in oligodendrogliomas and anaplastic astrocytomas has been demonstrated both with single agent and combined treatments (24, 25); this is confirmed in our personal experience with ACNU or temozolomide. For this reason, we decided to examine ACNU *i.a.* administration exclusively in glioblastomas, which that are known to be the most frequent gliomas and resistant to chemotherapy.

No chemotherapy drug has been proven to be effective in glioblastoma. Neurosurgery and radiotherapy are also of limited usefulness. Glioblastoma chemotherapy resistance has been attributed to lack of drug delivery to the tumor due to the blood-brain barrier. However, glioblastoma is characterized by newly formed vessels (neovascularization)

known to be deprived of the blood-brain barrier. Radiotherapy performed before chemotherapy has also been considered a cause of lack of drug-tissue penetration but, in this study, radiotherapy was postponed to chemotherapy. Moreover, ACNU has been shown to be highly effective in some cases of malignant astrocytoma and oligodendroglioma, that also show neovascularization. Thus, we believe that the main reason for the lack of *i.a.* ACNU effectiveness is the intrinsic glioblastoma tumoral cell resistance to nitrosureas. In this setting, the increase of ACNU delivery to the tumor up to 4 to 5-fold in comparison with the *i.v.* administration does not translate into any improvement of clinical effectiveness.

Furthermore, we think that, if a new chemotherapeutic compound, administered *i.a.*, demonstrated a dose-dependent effectiveness in glioblastoma, then the *i.a.* procedure would be of great help in increasing treatment effectiveness.

Due to its small size, this study also showed that thorough phase II trials or small randomized phase III studies are really needed to demonstrate clinical effectiveness, before turning to large phase III high cost studies that are cumbersome for patients and health personnel. Eventually, *i.a.* chemotherapy should be performed only in the setting of clinical trials which must comply with current standards of clinical research in terms of homogeneous patients, selection and treatment schedules, adequate statistical power, rigorous procedures for assessment of tumor response and progression and accurate recording of toxic effects, in order to obtain results readily comparable with other treatments. A final suggestion, based on the low toxicity of ACNU observed in this and other studies (18), is to employ nimustine as first choice treatment among the nitrosureas, when performing trials of comparison or association with other chemotherapeutic agents.

## References

- Salzman M: The value of cytoreductive surgery. *Clin Neurosurg* 41: 464-488, 1994.
- Shapiro WR, Sylvan B *et al*: A randomized comparison of intra-arterial *versus* intravenous BCNU, with or without intravenous 5-fluorouracil, for newly diagnosed patients with malignant glioma. *J Neurosurg* 76: 772-781, 1992.
- Rosenblum ML, Delattre J Y *et al*: Fatal necrotizing encephalopathy complicating treatment of malignant gliomas with intra-arterial BCNU and irradiation: a pathological study. *J Neurooncol* 7: 269-281, 1989.
- Yung WKA, Janus TJ *et al*: Adjuvant chemotherapy with carmustine and cisplatin for patients with malignant gliomas. *J Neurooncol* 12: 131-134, 1992.
- Takakura K, Hiroshi A *et al*: Effects of ACNU and radiotherapy on malignant glioma. *J Neurosurg* 64: 53-57, 1986.
- Vega F, Davila L *et al*: Treatment of malignant gliomas with surgery, intra-arterial chemotherapy with ACNU and radiation therapy. *J Neurooncol* 13: 131-135, 1992.
- Fujiwara T, Matsumoto Y *et al*: A comparison of intra-arterial carboplatin and ACNU for the treatment of gliomas. *Surg Neurol* 44: 145-150, 1995.
- Hirand Y, Mineura K *et al*: Therapeutic results of intra-arterial chemotherapy in patients with malignant glioma. *Int J Oncol* 13: 532-542, 1998.
- Eckman WW, Patlak CS *et al*: A critical evaluation of the principles governing the advantages of intra-arterial infusion. *J Pharmacokinetic Biopharmac* 2: 257, 1974.
- Fenstermacher JD, Cowles AL *et al*: Theoretic limitations of intracarotid infusions in brain tumor chemotherapy. *Cancer Treat Rep* 61: 519, 1977.
- Collins JM: Pharmacologic rationale for regional drug delivery. *J Clin Oncol* 2: 498, 1984.
- Stewart LA: Chemotherapy in adult high-grade glioma: a systematic review and meta-analysis of individual patient data from randomized trials. *Lancet* 359: 1011-1018, 2002.
- Greenberg HS, Ensminger WD *et al*: Intra-arterial BCNU chemotherapy for treatment of malignant gliomas of the central nervous system. *J Neurosurg* 61: 423-429, 1984.
- Levin V and Silver P: Superiority of post-radiotherapy adjuvant chemotherapy with CCNU, procarbazine, and vincristine (PCV) over BCNU for anaplastic gliomas: NCOG 6G61 final report. *Int J Rad Oncol Biol Phys* 18: 321-324, 1990.
- Eckman WW: A critical evaluation of the principles governing the advantages of intra-arterial infusion. *J Pharmacokinetic Biopharm* 2: 257, 1974.
- Fenstermacher J: Theoretic limitations of intracarotid infusion in brain tumor chemotherapy. *Cancer Treat Rep* 61: 519, 1977.
- Rogers LR *et al*: Alternating sequential intracarotid BCNU and cisplatin in recurrent malignant gliomas. *Cancer* 68: 15, 1991.
- Kochi M, Kitamura I *et al*: Randomized comparison of intra-arterial *versus* intravenous infusion of ACNU for newly diagnosed patients with glioblastoma. *J Neurooncol* 49: 63-67, 2000.
- Basso U *et al*: Is intra-arterial chemotherapy useful in high-grade gliomas? *Exp Rev Anticancer Ther* 2(5): 507-519, 2002.
- Gundersen S *et al*: A retrospective study of the value of chemotherapy as adjuvant therapy to surgery and radiotherapy in grade 3 and 4 gliomas. *Eur J Cancer* 34(10): 1564-1569, 1998.
- Ashby LS *et al*: Intra-arterial cisplatin plus oral etoposide for the treatment of recurrent malignant glioma: a phase II study. *J Neurooncol* 51(1): 67-86, 2001.
- Tfayli A *et al*: Toxicities related to intra-arterial infusion of cisplatin and etoposide in patients with brain tumors. *J Neurooncol* 42(1):73-77, 1999.
- Linassier C *et al*: Role of high-dose chemotherapy with hemopoietic stem-cell support in the treatment of adult patients with high-grade glioma. *Bull Cancer* 88(9): 871-876, 2001.
- Newton HB *et al*: Intra-arterial carboplatin and intravenous etoposide for the treatment of recurrent and progressive non-GBM gliomas. *J Neurooncol* 56(1):79-86, 2002.
- Stegge EM *et al*: Successful treatment of low-grade oligodendroglial tumors with a chemotherapy regimen of procarbazine, lomustine and vincristine. *Cancer* 103(4): 802-809, 2005.

Received May 23, 2005  
Revised September 21, 2005  
Accepted September 28, 2005