

Congenital Anomalies of the Spleen Mimicking Hematological Disorders and Solid Tumors: a Single-center Experience of 2650 Consecutive Diagnostic Laparoscopies

R. ORLANDO¹, F. LUMACHI² and F. LIRUSSI¹

¹Department of Medical and Surgical Sciences and

²Department of Surgical and Gastroenterological Sciences, University of Padua, Italy

Abstract. *Congenital anomalies of the spleen range from splenic lobulation, to accessory spleen to polysplenia. Though most of these anatomical variants have no clinical significance, an accessory spleen may simulate a tumor in the adrenal gland, pancreas, stomach or intestine. Alternatively, a missed accessory spleen may be the site of the relapse of a hematological disorder. We, therefore, assessed retrospectively: i) the frequency of congenital anomalies of the spleen observed during 2650 consecutive laparoscopies and ii) looked for possible misdiagnoses of the accessory spleen as hematological disorders or solid tumors located in the left upper quadrant of the abdomen. Congenital anomalies of the spleen were detected in 55 cases, accounting for 2.07%. Accessory spleens were observed in 44 patients (1.6%) and spleen lobulation in 11 (0.47%). An accessory spleen was the most common of the splenic anomalies. Among the 44 patients in whom an accessory spleen was discovered laparoscopically, the recognition of this anomaly prevented a relapse of a hematological disease in one case and avoided a useless exploratory laparotomy in the second, where the radiologist had interpreted this malformation as a space-occupying lesion. In the third case, the accessory spleen was initially misdiagnosed as a solid tumor of the pancreas, but was eventually recognized as a congenital anomaly by a second laparoscopy.*

Congenital anomalies of the spleen are believed to be rare and include absence of the spleen, splenic lobulation, duplications, displacements (splenoptosis or wandering spleen), polysplenia and the presence of one or more accessory spleens. Among these, accessory spleens are

regarded as the most common of the splenic anomalies, with an incidence ranging between 10% and 30% in autopsy series (1, 2), whereas a wandering spleen and polysplenia are less common. All these pathological conditions result from an altered embryogenesis of the spleen and are generally associated with other congenital abnormalities. A number of studies report laparoscopic observations of congenital anomalies of the liver (3, 4), whereas, to our knowledge, there are no data in the literature concerning congenital anomalies of the spleen detected by laparoscopy. We, therefore, examined retrospectively a series of 2650 diagnostic laparoscopies with the aim of investigating and cataloguing the type of congenital anomalies of the spleen, determining their relative frequency and evaluating the role of this procedure in the differential diagnosis with hematological disorders or solid tumors located in the left upper quadrant of the abdomen.

Patients and Methods

We reviewed, retrospectively, the records of 2650 consecutive patients undergoing laparoscopy over a 14-year period, whose indications are reported in Table I. Of these, 1696 were men and 954 were women, 510 were over 60 years (range 60-81) and 2140 were younger (range 17-59). The procedures were performed by the same physician using a standard Storz laparoscope (diameter 11 mm, Storz GmbH, Tuttlingen, Germany). Informed consent was obtained from all patients before the procedure. To prevent vasovagal reactions, all patients were medicated half an hour before the procedure with intramuscular diazepam and atropine sulphate if no contraindications were noted.

Laparoscopy was performed under local anesthesia (1% lidocaine). Pneumoperitoneum was established by insufflating filtered air into the abdominal cavity. The Veress needle was introduced into the left lower quadrant of the abdomen in the external portion of a line extending from the umbilicus to the anterosuperior iliac crest. The trocar was introduced at the typical site, approximately 2 cm to the left of the midline above the umbilicus. In patients who had previously undergone abdominal surgery, the insufflation needle and laparoscopic trocar were always inserted at an appropriate distance (2-5 cm) from the abdominal

Correspondence to: Dr Flavio Lirussi, MD, Ph.D., Department of Medical and Surgical Sciences, University of Padua, 35128 Padua, Italy. Tel: ++39 049-8212175, Fax ++ 39 049-8212151, e-mail: flavio.lirussi@unipd.it

Key Words: Spleen, congenital anomalies.

Table I. *Indications for laparoscopy.*

	No.
Assessment of chronic liver disease	2525
Diagnosis of hepatic malignant disease	80
Evaluation of ascites	45
Total	2650

Table II. *Frequency of congenital anomalies of the spleen.*

	No.
Splenic lobulation	11
Accessory spleen	44
Polysplenia	0
Wandering spleen	0
Total	55

scar. In order to visualize the spleen, the patient was positioned in the reverse Trendelenburg position with the left side up and the omentum was gently teased. During laparoscopy, the macroscopic appearance of the liver and the spleen surface was recorded and the presence of congenital anomalies of the spleen systematically investigated.

Results

Overall, congenital anomalies of the spleen were detected in 55/2650 patients (2.07%) (Table II). Forty-four patients had accessory spleens (Figure 1). These were single and situated in the left upper quadrant of the splenic bed, near the hilum of the spleen or below the main spleen, to which sometimes they were bound by a pedicle of splenic tissue. Moreover, they appeared round or oval, their size varied from 2 to 5 cm in diameter and they had identical morphology to that of the main spleen.

Lobulation of the spleen was observed in 11 cases (Figures 2a and 2b). The spleen was partially subdivided into lobes due to the presence of deep clefts transversing the medial part of the organ. Splenic lobulation was considered as a congenital variation and not as an acquired abnormality, because the patient's history was negative for abdominal trauma, infection or infarction. No other congenital anomalies of the spleen, such as situs inversus totalis, asplenia, polysplenia and splenoptosis, were detected.

Among the 44 patients in whom an accessory spleen was discovered laparoscopically, a 60-year-old man with chronic hepatitis developed severe spherocytic anemia 3 years after the procedure. He underwent splenectomy by open surgery with removal of the main and of the accessory spleen, thus preventing a relapse of the hematological disease during the 15 years of postoperative follow-up.

Another patient, with a previous laparoscopic diagnosis of an accessory spleen, complained of abdominal discomfort and underwent an abdominal ultrasonography, showing a mass originating presumably in the tail of the pancreas. The serum values of tumor markers were within normal limits. The radiologist, who was not aware of the presence of an accessory spleen, diagnosed a space-occupying lesion in the

left upper abdominal quadrant. The patient underwent further diagnostic imaging studies, such as abdominal contrast CT and splenic scintigraphy, which confirmed the presence of the congenital anomaly, thus avoiding an exploratory laparotomy.

Finally, a 35-year-old man, in whom an accessory spleen had previously been diagnosed laparoscopically, complained of recurrent abdominal pain in the left hypochondrium. Physical examination showed a mildly tender mass with a smooth, regular surface and elastic consistency. Abdominal ultrasonography showed a 3-cm large solid mass in the left upper abdominal quadrant, which was confirmed by the abdominal contrast CT. These imaging techniques were compatible with a neoplasm of the tail of the pancreas. Therefore, the patient underwent laparoscopic exploration of the abdominal cavity, which confirmed that the visible mass was an accessory spleen located below the main spleen.

Discussion

The rate of congenital anomalies of the spleen detected by laparoscopy in our series was 2.07%. Of these, 1.6% were recognized as accessory spleens and 0.47% as spleen lobulations. These rates are lower than those generally reported in autopsy series (1, 2, 5, 6). This difference may be due to the observation that approximately 20% of the accessory spleens are found anywhere in the abdomen, particularly near the tail of the pancreas, the left kidney or in the retroperitoneum. These areas are not readily accessible for examination by laparoscopy (7). However, our data confirm that the accessory spleen is the most common of splenic anomalies (1, 2, 5, 6).

In contrast, splenic lobulation was a rare finding in our series. This low rate could be due to the fact that fetal splenic lobulation normally disappears before birth (8, 9), but sometimes may persist, causing a prominent lobule and being erroneously interpreted as an accessory spleen.

The majority of these anatomical variants have no clinical significance and often represent a CT or US occasional

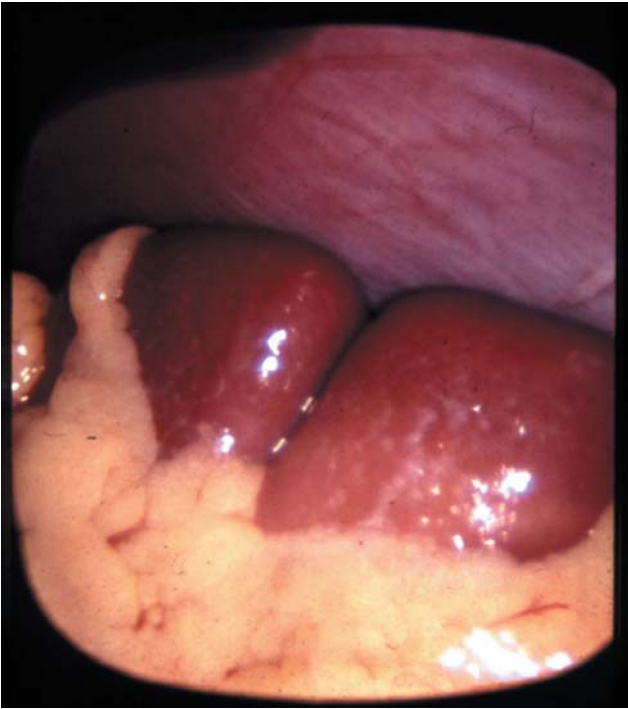


Figure 1. Laparoscopic view of an accessory spleen situated near the lower pole of the main spleen.

finding (5). Radiologists should be aware of this condition in order to avoid incorrectly diagnosing this ectopic tissue as metastasis, adenopathy or another solid tumor (5). In fact, an accessory spleen can mimic an enlarged lymph node, as well as a tumor in the adrenal gland, pancreas, stomach or intestine. The majority of accessory spleens are discovered by a relapse of chronic hematopathy, primarily treated by splenectomy (10, 11). Accessory spleens are found in 10% to 30% of patients with hematological diseases (11-13). Thus, in this condition, it is important to detect the localization of this anomaly prior to initial splenectomy to reduce the risk of missing it and allow complete removal of both the main and accessory spleen, in order to avoid recurrence of hematological disease after splenectomy (14, 15). Indeed, Verheyden *et al.* (16) observed that removal of accessory spleens by open exploration has a lower remission of hematological disease with respect to the clinical success rate (77%) reported by Velanovich *et al.* (17) and by Morris *et al.* (12), with laparoscopic removal of the accessory spleen.

Preoperative CT and preoperative selective spleen scintigraphy are able to identify only 25% of accessory spleens (18, 19). However, an accessory spleen, when large, may interfere with diagnosis of a neoplasm of the left upper quadrant and, in particular, may be confused with solid tumors of the pancreas or the left adrenal gland (20, 21).

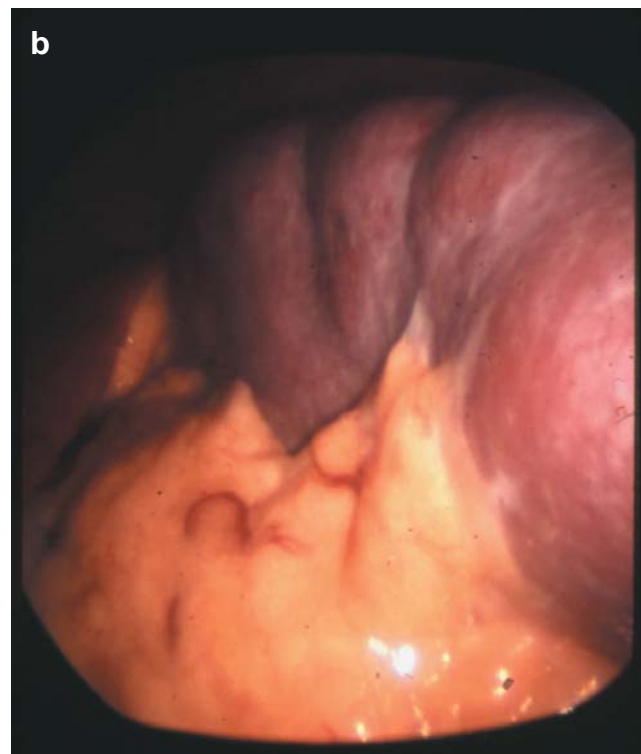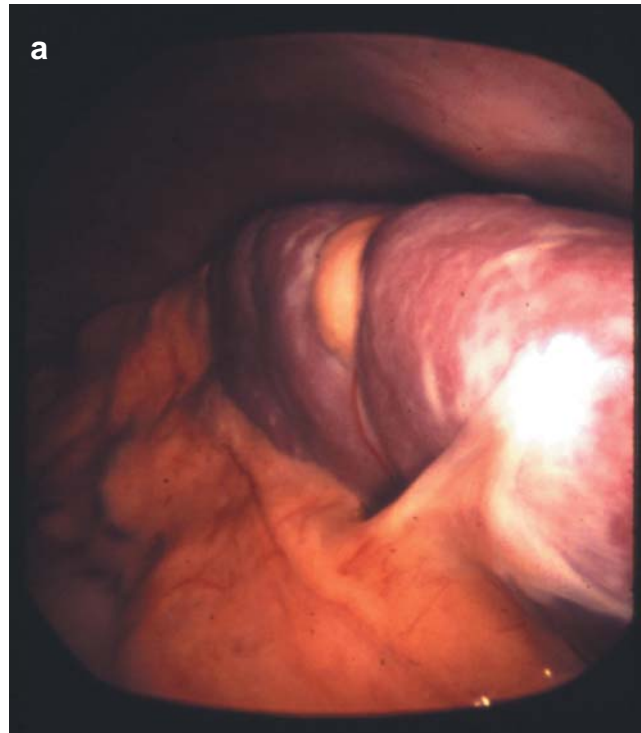


Figure 2. a. Laparoscopic view of splenic lobulation in the medial part of the spleen. b. Laparoscopic view of multiple spleen lobulation.

In conclusion, congenital anomalies of the spleen are rare but need to be taken into account in the differential diagnosis of pathological disorders, including neoplasms, when these are situated in the left upper quadrant of the abdomen. This is particularly true for the accessory spleen, which is easily diagnosed by the laparoscopic approach.

References

- 1 Azar GB, Awwad JT and Mufarrij IK: Accessory spleen presenting as adrenal mass. *Acta Obstet Gynecol Scand* 72: 587-588, 1993.
- 2 Cahalane SF and Kiesselback N: The significance of the accessory spleen. *J Pathol* 100: 139-144, 1970.
- 3 Orlando R and Lirussi F: Congenital anomalies of the liver: laparoscopic observations. *Gastrointest Endosc* 51: 115-116, 2000.
- 4 Sato S, Watanabe M, Nagasawa S, Niigaki M, Sakai S and Akagi S: Laparoscopic observations of congenital anomalies of the liver. *Gastrointest Endosc* 47: 136-140, 1998.
- 5 Gigot J-F, Jamar F, Ferrant A, Van Beers BE, Lengele B, Pauwels S, Pringot J, Kestens PJ, Gianello P and Detry R: Inadequate detection of accessory spleens and splenosis with laparoscopic splenectomy: a shortcoming of the laparoscopic approach in hematologic disease. *Surg Endosc* 12: 101-106, 1998.
- 6 Peddu P, Shah M and Sidhu PS: Splenic abnormalities: a comparative review of ultrasound, microbubble-enhanced ultrasound and tomography. *Clin Radiol* 59: 777-792, 2004.
- 7 Hsiao SM, Lee LC and Chang MH: Large pelvic accessory spleen mimicking an adrenal malignancy in a teenage girl. *J Formos Med Assoc* 100: 565-567, 2001.
- 8 Moore KL and Persaud TVN: The digestive system. *In: Moore KL, Persaud TVN (eds.). The Developing Human, Clinically Oriented Embryology*. Philadelphia, PA: WB Saunders Co., pp. 271-302, 1998.
- 9 Moore KL and Dalley AF: Abdomen. *In: Moore KL, Dalley AF (eds.). Clinically Oriented Anatomy*. Philadelphia, PA: Lippincott Williams & Wilkins, pp. 175-350, 1999.
- 10 Conn WW: Surgical aspects of splenic disease and lymphoma. *Curr Prob Surg* 35: 552-646, 1998.
- 11 Bart JB and Appel MF: Recurrent hemolytic anemia secondary to accessory spleens. *South Med J* 71: 608-609, 1978.
- 12 Morris KT, Horvath KD, Jobe BA and Swanstrom LL: Laparoscopic management of accessory spleens in immune thrombocytopenic purpura. *Surg Endosc* 13: 520-522, 1999.
- 13 Woo JH, Park SH, Park YK, Choi CB, Choi YY, Ahn MJ and Kim IS: Postsplenectomy recurrence of thrombocytopenia with an accessory spleen. *Korean J Intern Med* 19: 199-201, 2004.
- 14 Velanovich V: Laparoscopic versus open surgery: comparison of quality of life outcomes. *Surg Endosc* 14: 16-21, 2000.
- 15 Velanovich V and Shurafa MS: Clinical and quality of life outcomes of laparoscopic and open splenectomy for haematological disease. *Eur J Surg* 16: 23-28, 2001.
- 16 Verheyden EC, Beast RWJr, Clifton MD and Phylily RL: Accessory splenectomy in the management of recurrent idiopathic thrombocytopenic purpura. *Mayo Clin Proc* 53: 442-446, 1978.
- 17 Stanek A, Makarewicz W, Stefaniak T, Podgorezyk H and Hellman A: Accessory spleens: diagnostic and therapeutic problem of the laparoscopic splenectomy in idiopathic thrombocytopenic purpura patients. *Zentralbl Chir* 129: 114-118, 2004.
- 18 Vural M, Kacar S, Kosar U and Altin L: Symptomatic wandering accessory spleen in the pelvis: sonographic findings. *J Clin Ultrasound* 27: 534-536, 1999.
- 19 Ota T, Kusaka S and Mizuno M: A splenic pseudotumor: an accessory spleen. *Ann Nucl Med* 17: 159-160, 2003.
- 20 Kessler A, Miller E, Keidar S, Blachar A, Sira LB, Weinberg M and Rachmel A: Mass at the splenic hilum. *J Ultrasound Med* 22: 527-530, 2003.
- 21 Gayer C, Zissin R, Apter S, Atar E, Portnoy O and Itzchak Y: CT findings in congenital anomalies of the spleen. *BJR* 74: 767-772, 2001.

Received May 9, 2005

Accepted July 5, 2005