

pRb2/p130, p107 and p53 Expression in Precancerous Lesions and Squamous Cell Carcinoma of the Uterine Cervix

MARIA CENCI¹, TIZIANA PISANI², DEBORAH FRENCH², MAURO ALDERISIO³ and ALDO VECCHIONE²

¹Department of Experimental Medicine and Pathology, "La Sapienza" University, Rome;

²S. Andrea Hospital, Second School of Medicine, "La Sapienza" University, Rome;

³Laboratory of Epidemiology and Biostatistics, National Institute of Health, Rome, Italy

Abstract. *The aim of this study was to investigate pRb2/p130, p107 and p53 expressions in precancerous lesions and squamous cell carcinoma (SCC) of the uterine cervix. We evaluated Human Papillomavirus (HPV) testing and typing and pRb2/p130, p107 and p53 expressions (antibody D07) of 48 patients showing low-grade cervical intraepithelial neoplasia (LCIN, 18 cases), high-grade CIN (HCIN, 13 cases) and SCC (17 cases). Paraffin-embedded tissue sections were analyzed for the study. High-risk HPV types were present in 67%, 89% and in 100% of HPV-positive LCIN, HCIN and SCC, respectively (Spearman's correlation coefficient: 0.393, $p=0.035$). Positive pRb2/p130 expression was detected in 89% of LCIN, 77% of HCIN and in 35% of SCC ($p=0.001$), whereas diffuse p107 expression was 72%, 62% and 100%, respectively ($p=0.024$). The results of p53 expression in CINs and SCCs showed values (not statistically significant) comparable with the literature data concerning the antibody D07. For the first time, we tested pRb2/p130 and p107 expressions in CINs and SCCs. We found a progressive decrease in pRb2 expression from CINs to SCCs that suggests an important role of pRb2 in cervical carcinogenesis. Indeed, p107 expression does not seem to be a useful factor. In our opinion, confirmed by the literature data, p53 immunostaining helps to biologically characterize CIN (in particular LCIN) when each case is evaluated separately considering HPV testing/typing.*

Cervical carcinoma is the second most common cancer among women worldwide, in particular in developed countries, whereas in developing countries it is the most

Correspondence to: Prof. Aldo Vecchione, M.D., M.I.A.C., II Facoltà di Medicina e Chirurgia, Università "La Sapienza", Piazza Sassari n.3, 00161 Roma, Italy. Tel/Fax: + +39 06 49973171, e-mail: presmed2@uniroma1.it

Key Words: pRb2/p130, p107, p53, HPV, cervical cancer, immunohistochemistry.

common cancer among women (1). The Papanicolaou test (Pap-test) is an efficient procedure to detect precancerous cervical lesions by cytological sampling of the uterine cervix, whereas molecular or immunohistochemical methods are utilized to characterize these lesions, allowing appropriate clinical management and/or follow-up (2, 3).

Human Papillomavirus (HPV) is the most important risk factor for cancer of the uterine cervix, but cervical carcinogenesis is not completely clear. In fact, only a few HPV-related precancerous lesions develop cervical cancer and the reasons for this are unknown (4). Other factors are probably needed in cervical tumor progression, e.g. p53 polymorphism at codon 72 and microsatellite instability (5, 6), but their role is not fully demonstrated.

In the nuclear compartment, E6 and E7 oncoproteins bind p53 protein and the products of the retinoblastoma (Rb) gene family, respectively, and inactivate them by means of ubiquitin-dependent proteolysis in the cytoplasm. E6 and E7 of high-risk HPVs bind and, consequently, more efficiently degrade p53 and Rb than E6 or E7 of low-risk HPVs.

The Rb gene family consists of three members: *Rb1/p105*, which is one of the most studied tumor suppressor genes, *Rb2/p130* and *p107*. These genes codify for pRb1/p105, pRb2/p130 and p107 proteins. All three Rb proteins are localized mainly in the nucleus and show similar structures and functions at different timing (7). The best known function of Rb proteins is the inhibition of cell cycle progression by interacting with members of the E2F transcription family (7). In addition, the Rb protein family regulates a variety of biological aspects, such as cell cycle regulation, growth suppression, differentiation and apoptosis (7, 8). Different immunohistochemical studies analyzed the correlation of pRb2/p130 and p107 expressions in a wide spectrum of human neoplasms (e.g., lung cancer, vulvar squamous cell carcinoma (SCC), oral SCC and prostatic gland adenocarcinoma) (9-13). Indeed, to our knowledge, there is an absence of similar analyses encompassing precancerous lesions and cancer of the uterine cervix.

The *p53* gene encodes the most common oncosuppressor protein that is mutated in human neoplasms (14). *p53* protects against genomic rearrangement or accumulation of mutations, suppressing cellular transformation due to oncogenic activation or loss of tumor suppressor pathways (15). In cervical cancer, *p53* is frequently inactivated by E6 HPV-oncoprotein and very rarely mutated (16, 17). Immunohistochemical analysis of *p53* expression is controversial because *p53* immunostaining is not always abrogated by high-risk HPV infection. Moreover, many immunohistochemical parameters (*e.g.*, antibody and cut-off) are heterogeneous and conflicting among various studies (18).

The aim of our study was to investigate the expressions of pRb2/p130, p107 and p53 proteins in precancerous lesions and SCC of the uterine cervix.

Materials and Methods

Tissue specimens. A total of 48 Italian women were studied (median age: 41.5 years, range: 24-62): 17 patients with low-grade cervical intraepithelial neoplasia (LCIN) (median age, 32.5 years; range 24-44), 13 patients with high-grade CIN (HCIN) (median age, 42.8 years; range, 25-57) and 17 patients with SCC (median age, 49.1 years; range, 38-42). Intraepithelial lesions were histologically classified as LCIN or HCIN, as previously described (19). Formalin-fixed, paraffin-embedded biopsies were available for the study.

HPV testing and typing. DNA extraction was performed as previously described (19). The suitability of DNA for polymerase chain reaction (PCR) studies was evaluated by amplifying a fragment of *p53* using the method and primers described by Storey *et al.* (20) to detect *p53* polymorphism at codon 72, p53Proline (p53Pro) (142 bp) and p53Arginine (p53Arg) (177 bp). p53Arg and p53Pro sequences were separately amplified from each sample. Cases in which no p53Pro or p53Arg amplification occurred were excluded from further study. The presence of HPV-DNA was detected by PCR (Multigen HPV, DiaTech, Italy). This molecular method was performed in a volume of 50 µl containing 10 µl of digested material, 200 µl of each deoxy-nucleotide triphosphate, 10 mM Tris-HCl (pH 8.3), 50 mM KCl, 2 mM MgCl₂, 2.5 U of Ampli Taq DNA polymerase (Perkin-Elmer Cetus, Norwalk, CT, USA) and 100 pmole of each primer. We used two control DNA samples, one HPV-positive and one HPV-negative. PCR was carried out in a Thermal Cycler (Perkin-Elmer Cetus) under conditions as follows: 50 cycles at 94°C for 30 sec, 37°C for 25 sec and 72°C for 60 sec. Reaction products were analyzed by electrophoresis on a 3% agarose gel and made visible under UV by ethidium bromide staining. The HPV-positive PCR product was from 142 to 151 bp. The HPV-positive cases were followed by restriction enzyme digestion RSA 1 and TRU 9 1, 0.5 µl of each enzyme and 10 µl of digested material, according to the instructions given by the manufacturer (Multigen HPV, DiaTech, Italy). Each sample were separately digested overnight for each restriction enzyme. Digestion products were analyzed by electrophoresis on a 20% polyacrilamide gel and made visible under UV by ethidium bromide staining. As a result, the HPV typing was identified by the presence of different fragments: HPV 6, 33-42-67 bp (RSA 1), 142

Table I. Summary of the main immunohistochemistry conditions.

Protein	Antibody	Dilution and incubation	Staining
pRb2/p130	Clon C-20, polyclonal (Santa Cruz Biotechnology Inc.)	1:75, 30 minutes	nuclear
p107	Clon C-18, polyclonal (Santa Cruz Biotechnology Inc.)	1:40, 45 minutes	nuclear
p53	D07, monoclonal (Biogenex, San Ramon, CA, USA)	1:200, 2 hours	nuclear

bp (TRU 9 1); HPV 11, 33-109 bp (RSA 1), 142 bp (TRU 9 1); HPV 16, 32-43-70 bp (RSA 1), 50-95 bp (TRU 9 1); HPV 18, 33-38-77 bp (RSA 1), 38-52-58 bp (TRU 9 1); HPV 31, 33-112 bp (RSA 1), 11-15-41-78 bp (TRU 9 1); and HPV 33, 32-39-71 bp (RSA 1), 50-92 bp (TRU 9 1). The HPV types were subcategorized into high-risk (16, 18, 31 and 33), low-risk (6, 11), and not further typing (NFT) with the used molecular method. Considering that HPV NFT showed the majority of high-risk HPV, we associated the high-risk subgroup with the NFT HPV subgroup.

Immunohistochemistry. Tissue sections were cut at 2 µ, air-dried overnight at 37°C, dewaxed in xylene, rehydrated through graded ethanols and washed in 0.01 M PBS, pH 7.4. Endogenous peroxidase activity was blocked by 0.3% hydrogen peroxide in methanol for 20 min. After washing in PBS, non-specific proteins were quenched with blocking reagent (Immunotech, A Colter Company, France) for 10 min at room temperature. Tissue sections were washed in distilled water and immersed in citrate buffer, pH 6, for microwave antigen retrieval pretreatment. They were irradiated three times in a microwave oven (800 W) for 5 min and cooled down in this buffer to room temperature for 30 min. After washing in PBS, each primary antibody was added. The type, dilution and time of incubation of all primary antibodies used are reported in Table I. All sections were immunostained with the universal labelled streptavidin-biotin method (Immunotech), according to the manufacturer's instructions.

Positive nuclear staining for pRb2, p107 and p53 was detected with diaminobenzidine, and hematoxylin was used as the nuclear counterstain. Then, the sections were dehydrated through graded ethanols, washed in xylene and mounted on glass. Brown staining of the nucleus indicated positivity for all the three antibodies considered.

In all experiments, sections of carcinoma with previously detected high antibody expression (*e.g.*, a colon or breast carcinoma for p53) were included as the positive control. The primary antibody was omitted for the negative control.

Different qualitative and quantitative parameters of protein expression were evaluated: i) nuclear intensity, graduated as weak (+), moderate (++) and marked (+++); ii) nuclear positivity. A cut-off level of 10% was selected, according to the literature data (12). The evaluation was performed as previously described (21); iii) absent, focal or diffuse distribution (%), and iv) type of cell

Table II. Statistically significant molecular and immunohistochemical parameters.

	High-risk + NFT [°] HPV		pRb2/p130 +/+/+++ intensity		p107 diffuse distribution	
	n.	%	n.	%	n.	%
LCIN*	6/9	67*	16/18	89	13/18	72
HCIN*	8/9	89*	10/13	77	8/13	62
Cancer*	11/11	100*	6/17	35	17/17	100
			$p=0.001$		$p=0.024$	

[°]NFT: not further typing

*High-risk HPV associated with NFT HPV and histopathological stages: Spearman's correlation coefficient 0.393, $p=0.035$

showing protein expression (squamous or glandular; basal, parabasal, intermediate or superficial squamous cells; typical or atypical cells). All tissue sections were analyzed independently by two pathologists.

Statistical analysis. The Chi-square test (or Fisher's Exact Test when appropriate) and Spearman's correlation coefficient were used to analyze the differences or the relationships, respectively, between age, HPV testing and typing, pRb2/p130, p107, p53 expression and histopathological features (SPSS version 7.5.2 Chicago, IL, USA, 1996). A p -value of <0.05 was considered significant.

Results

HPV testing was positive in 50% of LCIN, 69% of HCIN and in 65% of SCC. High-risk HPV types (16, 18, 31, or 33) were present in 33% of LCIN, 56% of HCIN and 55% of SCC. Low-risk HPV types (6 or 11) were present in 33% of LCIN, 11% of HCIN and in no SCC, whereas NFT HPV associated with high-risk types was 67%, 89% and 100% of HPV-positive LCIN, HCIN and SCC, respectively (Spearman's correlation coefficient: 0.393, $p=0.035$) (Table II). One case of HCIN showed a co-infection with 3 HPV subtypes (16, 31 and NFT HPV).

pRb2/p130 overexpression, with marked or moderate intensity, was detected in 89% of LCIN, 77% of HCIN and in 35% of SCC ($p=0.001$). The pRb2 immunostaining was mainly diffuse (78% for LCIN, 84% for HCIN and 59% for SCC).

Diffuse p107 expression was 72% for LCIN, 62% for HCIN and 100% for SCC ($p=0.024$). The other immunohistochemical parameters of p107 expression were not statistically significant.

Negative p53 expression was detected in 56% of LCIN, 62% of HCIN and in 59% of SCC; *vice versa*, positive p53 immunostaining was observed in 44% of LCIN, 38% of

HCIN and 41% of SCC. Weak p53 intensity was 56% in LCIN, 69% in HCIN and 41% in SCC; *vice versa*, a moderate/marked intensity was 44%, 31% and 59%, respectively. p53 expression was absent in 22% of LCIN, 38% of HCIN and 35% of SCC. LCIN with positive p53 immunostaining showed protein overexpression in the basal cell layer (55%, 6/11 cases), in the superficial cell layer (27%, 3/11 cases), or in all the epithelial nuclei (18%, 2/11 cases). In p53-positive HCIN, protein overexpression was found in all the epithelial nuclei (60%, 3/5 cases), or in the superficial cell layer (20%, 1/5 cases) or in the basal cell layer (20%, 1/5 cases).

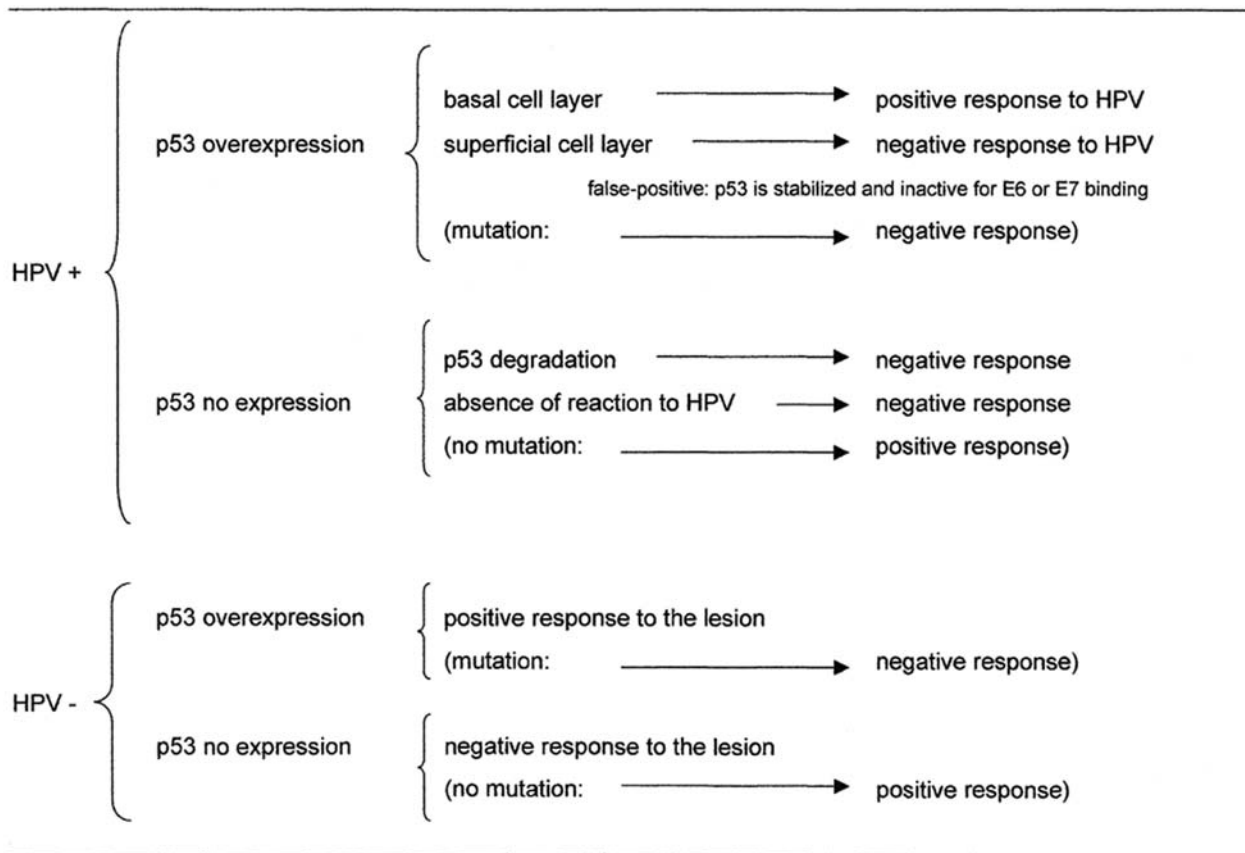
There were no significant differences in the expressions of pRb2/p130, p107 and p53 between HPV-negative and HPV-positive cases.

Discussion

We confirmed the literature data about the relationship between high-risk HPV and HCIN or SCC. In fact, 89% of HPV-positive HCIN and 100% of SCC showed the most oncogenic HPV types (Spearman's correlation coefficient: 0.393, $p=0.035$). In our study, the HPV positivity in CINs and SCCs reached 69% at the most, a lower prevalence than other papers (*e.g.*, 100% in SCC) (22). We agree with the literature that the sensitivity of the PCR test is strongly correlated to the size of the PCR product (22). In fact, we amplified a gene fragment of about 150 bp whereas Van Muyden *et al.* amplified a sequence of 65 bp. The drawback of this last, extremely sensitive, molecular method is "the high-risk of false-positive results because of the possible amplifications of contaminants" (23).

We described, for the first time, the protein expressions of pRb2/p130 and p107 in CINs and SCCs of the uterine cervix. We found a progressive decrease in pRb2 expression from CINs to SCCs as in other neoplasms (9-13). Our results suggest that pRb2 plays an important role in cervical carcinogenesis, according to the data on vulvar precancerous lesions and SCC (12). Vulvar and cervical carcinogenesis are similar because both multistep processes show a strong HPV association. The results on vulvar intraepithelial neoplasia (VIN) and vulvar SCC are very similar to our data about CINs and cervical SCCs (pRb2/p130 positivity: 75% of VIN III vs 77% of HCIN, 43% of vulvar SCC vs 35% of cervical SCC) (12). We agree with Zamparelli *et al.* that the progressive decrease in pRb2 immunostaining from precancerous lesions to SCC "may reflect a possible alteration of pRb2 gene function and could represent an early event in vulvar carcinogenesis" (12). The same conclusion may be reached for cervical carcinogenesis. The lack of pRb2 overexpression in cervical SCC may be due, in some cases, i) to the presence of a mutation that abolishes the protein product, ii) to a protein

Table III. Summary of p53 immunostaining evaluation.



(): rare event.

degradation in the proteolytic pathway after E7 binding, and iii) to a down-regulation of pRb2 in cervical neoplasia. Indeed, p107 expression does not seem to be a useful factor in CINs and SCCs, even though further studies are required to confirm our data. In fact, our only result of statistical significance (diffuse protein expression: $p=0.024$) has no clinical relevance.

In our opinion, the main cause of heterogeneous and controversial p53 expression results is the choice of the p53 antibody. We used the monoclonal antibody D07 because it recognizes both wild-type and mutant p53 protein. In general, overexpression of p53 corresponds to protein mutation (e.g., colon and breast cancer). In fact, the majority of mutated p53 proteins have a longer half-life than their wild-type counterparts, permitting their detection by visible overexpression in immunohistochemistry (25). Indeed, in cervical cancer p53 mutation is a rare event (16, 17) and it is, in practice, absent in precancerous cervical lesions (24). p53 inactivation is achieved by the proteolysis mediated by E6, but protein immunostaining is not always

abrogated by high-risk HPV infection. Considering only the studies with the antibody p53 D07, the literature data are more homogeneous for SCCs (21, 26-28) and more similar to our results (26, 27). In fact, Tjalma *et al.* (26) and Kersemaekers *et al.* (27) detected p53 overexpression of SCC in 42% and in 32%, respectively, compared to 41% of our study. The present results are also similar to our previous data concerning non invasive SCC (29% positivity) (21). Recently, two papers utilizing both antibody p53 D07 and a cut-off level of 10% showed completely different findings. Grace *et al.* detected positive p53 expression in all invasive cancer cases (100%) (29), whereas Koyamatsu *et al.* identified p53 overexpression in only one out of 40 cases of cervical carcinoma considered (30). In our experience, p53 expression is not always abrogated by high-risk HPV infection or there is not always a p53 overexpression due to E6 or E7 binding.

The studies concerning CINs and p53 expression are few (29, 31-33) but very similar, especially for LCIN (see below). We also considered the results obtained with the

monoclonal antibody p53 D01 (19, 34) because it demonstrated its specificity for the same epitope of p53 as the antibody D07 (35). Our data on HCINs are identical to our previous results (31% of marked/moderate intensity) (19) and very similar to the findings of Lie *et al.* (34) (38% vs 30% positivity). In LCINs, we agree with the literature that p53 expression is frequent in basal and parabasal cell layers (31, 32). Moreover, Zioli *et al.* detected moderate/strong p53 intensity in 50% of LCIN vs 44% of our cases (31), whereas Giannodios *et al.* identified strong intensity in 43% of LCIN (32). Considering p53 positivity, Grace *et al.* showed protein expression in 30% (6/20 cases) vs 44% of our study (8/18 cases) (29). However doubts about the interpretation of p53 expression in cervical cancerogenesis remain (*e.g.*, if p53 overexpression is a positive or a negative factor). We noted that HPV-positive or -negative LCIN showed, in the majority of cases, p53 overexpression in the basal cell layer, also according to the literature (31-33). This finding represents a positive response to viral infection or to the lesion. In fact, p53 protein is a suppressor of HPV DNA replication (36) or it may represent a stress response to a lesion (25). Indeed, p53 overexpression of the superficial or intermediate cell layer frequently represents a p53 accumulation due to E6 (in high-risk HPV infection) or to E7 (in low-risk HPV infection) binding (32, 37, 38). This is a negative response because p53 is inactive (Table III). Therefore, confirming previous literature data (30-32), we proposed interpreting p53 expression of each case considered separately on the basis of both i) HPV testing and typing (high-risk or low-risk HPV), and ii) overexpression or absence of immunostaining in the superficial, intermediate, or basal epithelial nuclei. In our opinion, this explanation, summarized in Table III, is useful mainly for the biological characterization of the LCIN or atypical squamous cell of undetermined significance cases. Indeed, HCINs are more similar to SCCs and these lesions need more aggressive management.

There is a lack of statistical association between pRb2, p107 or p53 expressions and HPV infection. Our result is a frequent finding in the literature (34, 39, 40). The final result is probably due to a balance between opposite stimuli (*e.g.*, protein degradation due to HPV infection, or protein overexpression for the lesion or HPV infection), previously described.

In conclusion, even if the Pap-test is a simple cytological method allowing detection of CINs, a biological characterization of cervical lesions is necessary to select the lesions that have to be treated more aggressively. We evaluated p53, Rb2/p130 and p107 expressions in CINs and SCCs, but further studies are needed to confirm our experience.

References

- 1 Parkin DM, Bray FI and Davesi S: Cancer burden in the year 2000. The global picture. *Eur J Cancer* 37: S4-S66, 2000.
- 2 Shneider V, Henry MR, Jimenez-Ayala M, Turnbull LS and Carr Wright T: Cervical cancer screening errors and reporting. *Acta Cytol* 45: 493-498, 2001.
- 3 Cenci M and Vecchione A: Atypical squamous and glandular cells of undetermined significance (ASCUS and AGUS) of the uterine cervix (Review). *Anticancer Res* 20: 3701-3708, 2000.
- 4 Feichter G and Meisels A: Task force consensus report on HPV-related changes of the lower female genital tract. *Acta Cytol* 46: 630-632, 2002.
- 5 Cenci M, French D, Pisani T, Alderisio M, Lombardi AM, Marchese R, Colelli F and Vecchione A: p53 polymorphism at codon 72 is not a risk factor for cervical carcinogenesis in central Italy. *Anticancer Res* 23: 1385-1387, 2003.
- 6 French D, Cermele C, Vecchione A, Cenci M and Vecchione A: HPV infection and microsatellite instability in squamous lesions of the uterine cervix. *Anticancer Res* 20: 3417-3422, 2000.
- 7 Paggi MG, Baldi A, Bonetto F and Giordano A: Retinoblastoma protein family in cell cycle and cancer (Review). *J Cell Biochem* 62: 418-430, 1996.
- 8 Paggi MG and Giordano A: Who is the boss in the Retinoblastoma family? The point of view of Rb2/p130, the little brother (Review). *Cancer Res* 61: 4651-4654, 2001.
- 9 Baldi A, Esposito V, De Luca A, Fu Y, Meoli I, Giordano GG, Caputi M, Baldi F and Giordano G: Differential expression of Rb2/p130 and p107 in normal human tissues and in primary lung cancer. *Clin Cancer Res* 3: 1691-1697, 1997.
- 10 Caputi M, Groeger AM, Esposito V, De Luca A, Maciullo V, Mancini A, Baldi F, Wolner E and Giordano A: Loss of oRb2/p130 expression is associated with unfavorable clinical outcome in lung cancer. *Clin Cancer Res* 8: 3850-3856, 2002.
- 11 Tanaka N, Ogi K, Odajima T, Dehari H, Yamada S, Sonoda T and Kohama G: pRb2/p130 protein expression is correlated with clinicopathologic findings in patients with oral squamous cell carcinoma. *Cancer* 92: 2117-2125, 2001.
- 12 Zamparelli A, Masciullo V, Bovicelli A, Santini D, Ferrandina G, Minimo C, Terzano P, Costa S, Cinti C, Ceccarelli C, Mancuso S, Scambia G, Bovicelli L and Giordano A: Expression of cell-cycle-associated proteins pRb2/p130 and p27kip1 in vulvar squamous cell carcinomas. *Hum Pathol* 32: 4-9, 2001.
- 13 Claudio PP, Zamparelli A, Garcia FU, Claudio L, Ammirati G, Farina A, Bovicelli A, Russo G, Giordano GG, McGinnis DE, Giordano A and Cardi G: Expression of cell-cycle-regulated proteins pRb2/p130, p107, p27kip1, p53, mdm2, and Ki-67 (MIB-1) in prostatic gland adenocarcinoma. *Clin Cancer Res* 8: 1808-1815, 2002.
- 14 Levine AJ, Momand J and Finlay CA: The p53 tumor suppressor gene. *Nature* 351: 453-456, 1991.
- 15 Hickman ES, Moroni MC and Helin K: The role of p53 and pRb in apoptosis and cancer (Review). *Curr Opin Oncol* 12: 60-66, 2002.
- 16 Skomedal H, Kristensen GB, Lie KL and Holm R: Aberrant expression of the cell cycle associated proteins TP53, mdm2, p21, p27, CDK4, cyclin D1, Rb, and EGFR in cervical carcinomas. *Gynecol Oncol* 73: 223-228, 1999.

- 17 Busby-Earle RMC, Steel CM, Williams ARW, Cohen B and Bird CC: p53 mutations in cervical cancerogenesis. Low frequency and lack of correlation with human papillomavirus status. *Br J Cancer* 69: 732-737, 1994.
- 18 Lambkin HA, Mothershill CM and Kelehan P: Variations in immunohistochemical detection of p53 protein overexpression in cervical carcinomas with different antibodies and methods of detection. *J Pathol* 172: 13-18, 1994.
- 19 Vecchione A, Cermele C, Giovagnoli MR, Valli C, Alimandi M, Carico E, Esposito DL, Mariani-Costatini R and French D: p53 expression and genetic evidence for viral infection in intraepithelial neoplasia of the uterine cervix. *Gynecol Oncol* 55: 343-348, 1994.
- 20 Storey A, Thomas M, Kalita A, Harwood C, Gardiol D, Mantovani F, Breuers J, Leigh IM, Matlashewski G and Banks L: Role of a p53 polymorphism in the development of human papillomavirus-associated cancer. *Nature* 21: 229-234, 1998.
- 21 Giarnieri E, Mancini R, Pisani T, Alderisio M and Vecchione A: Msh2, mlh1, Fhit, p53, Bcl-2, and bax expression in invasive and *in situ* squamous cell carcinoma of the uterine cervix. *Clin Cancer Res* 6: 3600-3606, 2000.
- 22 van Muyden RCPA, ter Harmsel BWA, Smedts FMM, Hermans J, Kuijpers JC, Raikhlin NT, Petrov S, Lebedev A, Ramaekers FCS, Trimboos JB, Kleter B and Quint WG: Detection and typing of human papillomavirus in cervical carcinomas in Russian women. *Cancer* 85: 2011-2016, 1999.
- 23 Milde-Langosch K, Riethdorf S and Loning T: Association of human papillomavirus infection with carcinoma of the cervix uteri and its precursor lesions. Theoretical and practical implications. *Virchows Arch* 437: 227-233, 2000.
- 24 Slagle BL, Kaufman RH, Reeves WC and Icenogle JP: Expression of ras, c-myc, and p53 proteins in cervical intraepithelial neoplasia. *Cancer* 83: 1401-1408, 1998.
- 25 Battifora H: p53 immunohistochemistry. A word of caution (Editorial). *Hum Pathol* 25: 435-437, 1994.
- 26 Tjalma GC, Weyler JJ, Bogers JJ, Pollefliet C, Baay M, Goovaerts GC, Vermorken JB, van Dam PA, van Mark EA and Buytaert PM: The importance of biological factors (bcl-2, bax, p53, PCNA, MI, HPV and angiogenesis) in invasive cervical cancer. *Eur J Obstet Gynecol Reprod Biol* 97: 223-230, 2001.
- 27 Kersemaekers AMF, Fleuren GJ, Kenter GG, van den Broek LJC, Ulijie SM, Hermans J and van de Vijver MJ: Oncogene alterations in carcinomas of the uterine cervix. Overexpression of the epidermal growth factor receptor is associated with poor prognosis. *Clin Cancer Res* 5: 577-586, 1999.
- 28 Troncone G, Martinez JC, Palombini L, De Rosa G, Mugica C, Rodriguez JA, Zeppa P, Di Vizio D, Lucariello A and Piris MA: Immunohistochemical expression of mdm2 and p21 in invasive cervical cancer. Correlation with p53 protein and high risk HPV infection. *J Clin Pathol* 51: 754-760, 1998.
- 29 Grace VMB, Shalini JV, Sree lekha TT, Devaraj SN and Devaraj H: Co-overexpression of p53 and bcl-2 proteins in HPV-induced squamous cell carcinoma of the uterine cervix. *Gynecol Oncol* 91: 51-58, 2003.
- 30 Koyamatsu Y, Yokoyama M, Nakao Y, Fukuda K, Saito T, Matsukuma K and Iwasaka T: A comparative analysis of human papillomavirus types 6 and 18 and expression of p53 gene and Ki-67 in cervical, vaginal, and vulvar carcinomas. *Gynecol Oncol* 90: 547-551, 2003.
- 31 Zioli M, Di Tomaso C, Biaggi A, Tepper M, Piquet P, Carbillon L, Uzan M and Guettier C: Virological and biological characteristics of cervical intraepithelial neoplasia grade I with marked koilocytotic atypia. *Hum Pathol* 29: 1068-1073, 1998.
- 32 Giannoudis A and Herrington CS: Differential expression of p53 and p21 in low grade cervical squamous intraepithelial lesions infected with low, intermediate, and high risk human papillomavirus. *Cancer* 89: 1300-1307, 2000.
- 33 Mathevet P, Frappat L and Hittelman W: Expression of p53 and pRb in cervical dysplasia. Correlation with mitotic activity. *Gynecol Obstet Fertil* 1: 44-50, 2000.
- 34 Lie K, Solvi S, Skomedal H, Haugen OA and Holm R: Expression of p53, MDM2, and p21 proteins in high-grade cervical intraepithelial neoplasia and relationship to human papillomavirus infection. *Int J Gynecol Pathol* 18: 5-11, 1999.
- 35 Vojtesek B, Bartek J, Midgley CA and Lane DP: An immunochemical analysis of the human nuclear phosphoprotein p53. *J Immunol Methods* 151: 237-244, 1992.
- 36 Lepik D, Ilves I, Kristjuhan A, Maimets T and Ustav M: p53 protein is a suppressor of papillomavirus DNA amplificational replication. *J Virol* 72: 6822-6831, 1998.
- 37 Seavey SE, Holubar M, Saucedo LJ and Perry ME: The E7 oncoprotein of human papillomavirus type 16 stabilizes p53 through a mechanism independent of p19ARF. *J Virol* 73: 7590-7598, 1999.
- 38 Scheffner M, Werness BA, Huibregtse JM, Levine AJ and Howley PP: The E6 oncoprotein encoded by human papillomavirus types 16 and 18 promotes the degradation of p53. *Cell* 63: 1129-1136, 1990.
- 39 Carrilho C, Gouveia P, Cantel M, Alberto M, Buane L and David L: Characterization of human papillomavirus infection, p53 and Ki-67 expression in cervix cancer of Mozambican women. *Pathol Res Pract* 199: 303-311, 2003.
- 40 Bar Jk, Harlozinska A, Sedlaczek P, Kasiak J and Martowska J: Relations between the expression of p53, c-erbB-2, Ki-67 and HPV infection in cervical carcinomas and cervical dysplasias. *Anticancer Res* 21: 1001-1006, 2001.

Received June 21, 2004

Revised March 23, 2005

Accepted April 4, 2005