

Small Cell Carcinoma of the Endometrium: Light Microscopic and Immunohistochemical Study of a Case

ANGRIT STACHS, JOSEPH MAKOVITZKY and VOLKER BRIESE

Department of Gynaecology and Obstetrics, University of Rostock, Doberaner Strasse 142, 18057 Rostock, Germany

Abstract. *Small cell carcinoma of the endometrium is extremely rare. The clinical behaviour of this tumour is usually very aggressive. The histopathological distinction of endometrial small cell neuroendocrine carcinoma from mesodermal mixed tumours has important prognostic and therapeutic implications. The case of a 62-year-old white female suffering from postmenopausal bleeding is presented. Macroscopic examination revealed a bulky intraluminal mass with infiltration of more than half of the myometrial wall. In H&E-stained sections atypical small tumour cells revealing neuroendocrine features were found. Immunohistochemical evidence of neuroendocrine differentiation was demonstrated using the markers neuron-specific enolase and synaptophysin. The patient died three months after diagnosis.*

Small cell carcinoma of the endometrium is a rare neoplasm. Most of the studies of this tumour entity have been confined to case reports (1-6). Endometrial small cell carcinoma can be intermingled with components of adenocarcinoma and squamous cell carcinoma as well as mesodermal mixed tumour (1, 3, 5). According to the few reports in the literature, the clinical outcome of patients with small cell neuroendocrine carcinoma of the endometrium is poor (7). We present a new case of endometrial small cell neuroendocrine carcinoma to characterize the clinical and morphological qualities of this uncommon neoplasm.

Patients and Methods

The patient, a 62-year-old white female, presented with postmenopausal bleeding. Cervical and endometrial biopsy

Correspondence to: Angrit Stachs, Department of Gynaecology and Obstetrics, Doberaner Strasse 142, 18057 Rostock, Germany. e-mail: angrit.stachs@med.uni-rostock.de

Key Words: Endometrium, small cell carcinoma, neuroendocrine tumours.

specimens were examined histologically using H&E-stained sections. For immunohistochemical analysis, formalin-fixed paraffin-embedded slides were incubated with the antibodies listed in Table I. The antibody reaction was visualized with the alkaline phosphatase - antialkaline phosphatase method.

Results

Histological examination of the endometrial tissue revealed dissociated atypical small tumour cells and extensive areas of necrosis (Figure 1). The morphology of the small cell component had neuroendocrine features. The tumour cells had round and relatively monomorphic nuclei. Round cells were small to intermediate in size and had modest amount of cytoplasm. In some foci, the round cells assumed a spindled morphology.

Immunohistochemical studies provided strong evidence for the neuroendocrine character of the neoplasm. In detail, the small- and intermediate-sized tumour cells showed positive staining with the panepithelial marker AE1/3, but a negative reaction with CK7. They were positive for vimentin. Within the neuroendocrine markers, the tumour cells showed positive staining with NSE (Figure 2) and a focal positive staining with synaptophysin (Figure 3). Staining with chromogranin was negative. The proliferation rate measured with the proliferative marker Ki67 was nearly 50 percent of tumour cells.

Immediately after diagnosis of neuroendocrine small cell carcinoma of the endometrium, the patient underwent surgical therapy including radical hysterectomy, bilateral salpingo-ovariectomy and pelvic lymphadenectomy. Macroscopic examination of the uterus revealed a bulky exophytic haemorrhagic mass infiltrating more than half of myometrial wall (Figure 4). The postoperative stage was defined as stage III. There was no evidence of distant metastases at the time of diagnosis. Adjuvant chemotherapeutic treatment with the combination of carboplatin and etoposide was planned because of the aggressive nature of the neoplasm. Six weeks postoperatively the patient complained of abdominal pain and respiratory

Table I. Antibodies used in the immunohistochemical studies.

Antigen	Source	Dilution
Cytokeratin AE1/3	Sigma (St. Louis, MO, USA)	1:100
Cytokeratin 7	Sigma	1:400
Vimentin	DAKO	1:1600
Chromogranin	Incstar (Stillwater, MN, USA)	1:1600
Neuron-specific enolase	DAKO	1:400
Synaptophysin	Boehringer-Mannheim (Germany)	1:20

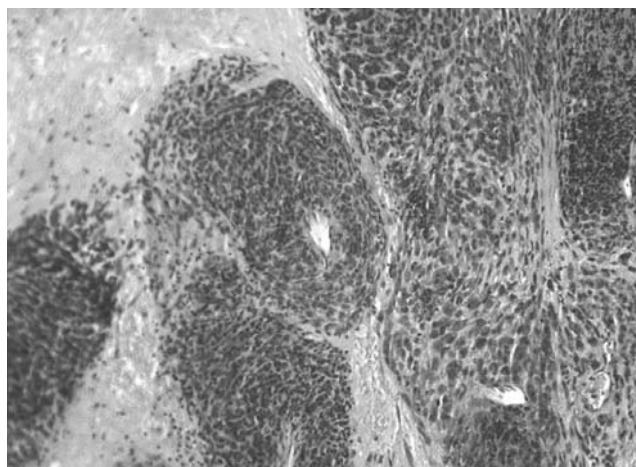


Figure 1. Relatively monomorphic proliferation of small tumour cells in endometrial small cell neuroendocrine carcinoma. H&E, x 200.

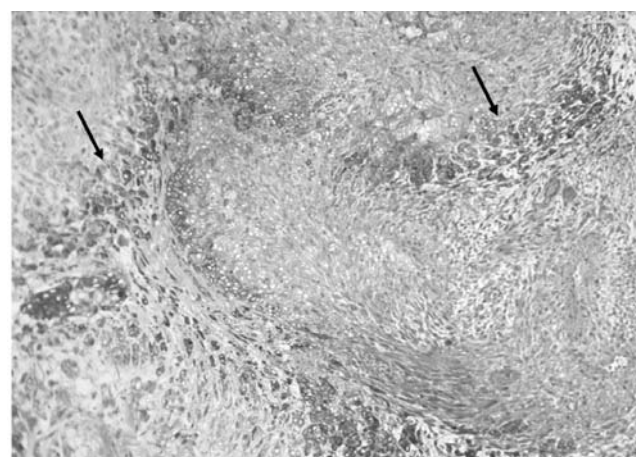


Figure 2. Neuron-specific enolase-labelled tumour cells in small cell neuroendocrine carcinoma of the endometrium, Neuron-specific enolase, x 200.

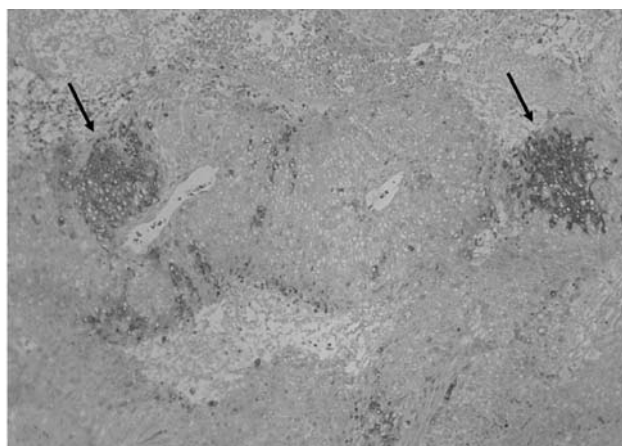


Figure 3. Focal positive staining of small tumour cells using synaptophysin. Synaptophysin, x 200.

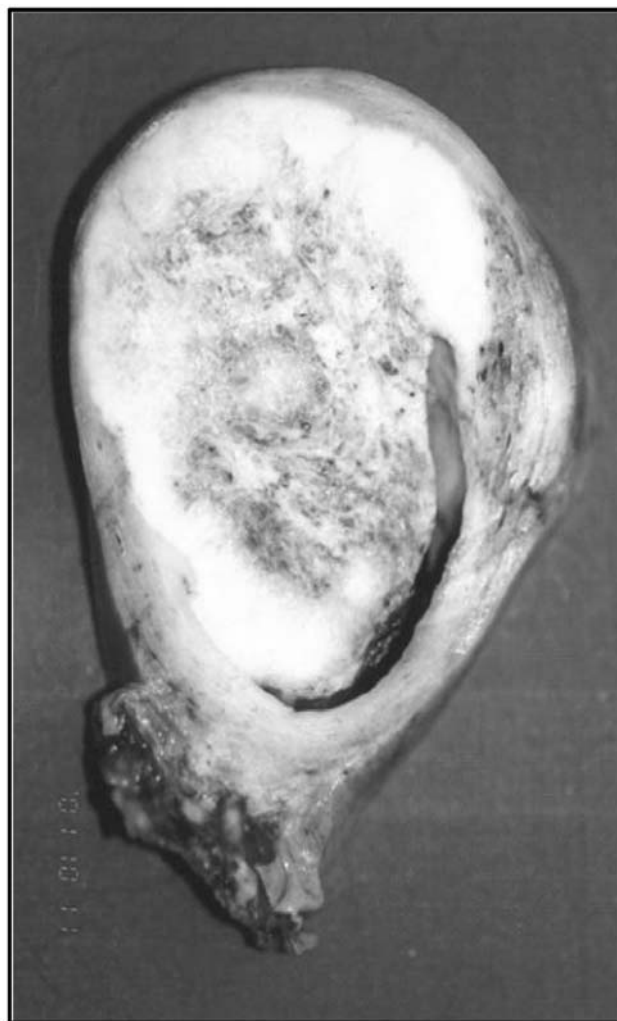

Figure 4. Macroscopic findings of small cell carcinoma of the endometrium. The tumour masses infiltrate nearly the complete myometrial wall.

distress. Computer-tomographic examination revealed an extensive local recurrence within the pelvis and a huge tumour formation on the colon descendens as well as pulmonal metastases. The patient died three months after diagnosis.

Discussion

Small cell neuroendocrine carcinoma is a rare neoplasm of the uterus, which may cause diagnostic difficulties. The leading clinical symptom is a perimenopausal or postmenopausal vaginal bleeding, but this is not specific for this tumour entity. Histological features include small-sized or intermediate-sized tumour cells with monomorphic nuclei and a slight amount of cytoplasm. The neoplasm is often associated with more conventional types of uterine malignancies (1, 3, 5, 7). Sometimes, the small cell neuroendocrine component may be misinterpreted as a stromal sarcomatous component. The presence of dense core (neurosecretory-type) granules in the cytoplasm of tumour cells in endometrial small cell carcinoma, demonstrated by ultrastructural analysis, can serve as a diagnostic aid (1, 2, 4, 8). The distinctive appearance of small cell neuroendocrine carcinoma should lead to immunohistochemical examination to confirm the diagnosis. Neuroendocrine markers include neuron-specific enolase, synaptophysin, chromogranin and several neuropeptides. An only focal staining of tumour cells is possible. The expression of neuroendocrine markers such as chromogranin may be down-regulated in poorly-differentiated tumours (9), however, at least one of the neuroendocrine markers should be expressed by the neuroendocrine small cell components of the tumour. The differential diagnosis of small cell neuroendocrine carcinoma includes stromal sarcoma, homologous mixed mesodermal tumour and primitive neuroectodermal tumours of the uterus. The latter tumours can be distinguished from neuroendocrine carcinoma by the presence of foci of neural, ependymal, glial or medulloepithelial differentiation (10). Much more difficult is the distinction of small cell neuroendocrine carcinoma with admixed adenocarcinoma from homologous mixed mesodermal tumours or stromal sarcoma (11-15), but immunohistochemical evidence of neuroendocrine markers is distinctive for small cell carcinoma.

The clinical outcome of patients with neuroendocrine carcinoma is poor. Van Hoeven *et al.* (7) reported survival times between three months and six years. Most patients died of disease within the first year after diagnosis. Some patients received chemotherapy or radiation therapy after surgical treatment, but the benefit of adjuvant settings remains unclear.

References

- Tohya T, Miyazaki K, Katabuchi H, Fujisaki S and Maeyama M: Small cell carcinoma of the endometrium associated with adenosquamous carcinoma: a light and electron microscopic study. *Gynecol Oncol* 25: 363-371, 1986.
- Olson N, Twigg L and Sibley R: Small-cell carcinoma of the endometrium: light microscopic and ultrastructural study of a case. *Cancer* 50: 760-765, 1982.
- Manivel C, Wick MR and Sibley RK: Neuroendocrine differentiation in Mullerian neoplasms. An immuno-histochemical study of a "pure" endometrial small cell carcinoma and a mixed Mullerian tumor containing small cell carcinoma. *Am J Clin Pathol* 86: 438-434, 1986.
- Kumar NB: Small cell carcinoma of the endometrium in a 23 year old woman: light microscopic and ultrastructural study. *Am J Clin Pathol* 81: 98-101, 1984.
- Campo E, Brunier MN and Merino MJ: Small cell carcinoma of the endometrium with associated ocular paraneoplastic syndrome. *Cancer* 69: 2283-2288, 1992.
- Tenti P, Carnevali L, Paulli M, Franchi M and Babilonti L: Dedifferentiating endometrial adenocarcinoma. Report of a case. *Eur J Gynaec Oncol* 10: 292-294, 1989.
- Van Hoeven KH, Hudock JA, Woodruff JM and Suhrlund MJ: Small cell neuroendocrine carcinoma of the endometrium. *Int J Gynecol Pathol* 14: 21-29, 1995.
- Bannatyne P, Russell P and Wills EJ: Argyrophilia and endometrial carcinoma. *Int J Gynecol Pathol* 2: 235-254, 1983.
- Schmitt-Gräff A, Nitschke R and Wiedenmann B: Gastroenteropankreatische neuroendokrine/endokrine Tumoren. Aktuelle pathologisch-diagnostische Sicht. *Pathologie* 22: 105-113, 2001.
- Daya D, Lukka H and Clement PB: Primitive neuroectodermal tumors of the uterus: a report of four cases. *Human Pathol* 23: 1120-1129, 1992.
- Farhood AI and Abrams J: Immunohistochemistry of endometrial stromal sarcoma. *Human Pathol* 22: 224-230, 1991.
- Liao SY and Choi BH: Expression of glial fibrillary acidic protein by neoplastic cells of Mullerian origin. *Virchows Arch B Cell Pathol* 52: 185-193, 1986.
- Geisinger KR, Dabbs DJ and Marshall RB: Malignant mixed Mullerian tumors. An ultrastructural and immunohistochemical analysis with histogenetic considerations. *Cancer* 59: 1781-1790, 1987.
- Auerbach HE, LiVolsi VA and Merino MJ: Malignant mixed Mullerian tumors of the uterus. An immunohistochemical study. *Int J Gynecol Pathol* 7: 123-130, 1988.
- Nielsen SN, Podratz KL, Scheithauer BW and O'Brien PC: Clinicopathologic analysis of uterine malignant mixed Mullerian tumors. *Gynecol Oncol* 34: 372-378, 1989.

Received August 2, 2005

Accepted February 2, 2005