

## MRI Diagnosis of Mesorectal Lymph Node Metastasis in Patients with Rectal Carcinoma. What is the Optimal Criterion?

HIROYOSHI MATSUOKA<sup>1</sup>, AKIHISA NAKAMURA<sup>2</sup>, MASANORI SUGIYAMA<sup>1</sup>,  
JUNICHI HACHIYA<sup>2</sup>, YUTAKA ATOMI<sup>1</sup> and TADAHIKO MASAKI<sup>1</sup>

<sup>1</sup>Department of Surgery and <sup>2</sup>Department of Radiology, Kyorin University, School of Medicine, Tokyo, Japan

**Abstract.** *Background:* Preoperative diagnosis of lymph node metastasis is often difficult. A number of different criteria have been advocated in the literature, however, an optimal criterion has not yet been determined in patients with rectal carcinoma. *Patients and Methods:* Fifty-one patients, undergoing radical surgery with total mesorectal excision, were examined with reference to regional lymph node status. MRI and pathological findings were compared, and an optimal preoperative criterion was clarified by receiver operating characteristic (ROC) analysis. *Results:* Among size, shape and internal structure criteria, size was a significant factor for diagnosing metastatic lymph node on MRI. ROC analysis showed that a criterion of 6-mm or larger in the longitudinal axis was the most reliable in differentiating metastatic and non-metastatic lymph nodes, with overall accuracy of 78%. *Conclusion:* A 6-mm longitudinal diameter criterion is thought to be most optimal in the evaluation of mesorectal lymph node status in patients with rectal carcinoma.

Rectal carcinoma is one of the major malignancies in the gastrointestinal tract. Significant determinants of patients' survival are positive involvement of the circumferential margin and lymph node metastasis (1-4). Recently, magnetic resonance imaging (MRI) has become one of the promising diagnostic tools in rectal carcinoma patients. In the evaluation of depth of tumor invasion, the diagnostic accuracy of MRI is superior to that of CT scan and almost equal to that of endorectal ultrasound (5,6). On the other hand, preoperative diagnosis of lymph node metastasis is often difficult in spite of the recent refinements of these

imaging studies. There have been a number of different criteria advocated in the literature (7-18), however, an optimal criterion has not yet been determined in patients with rectal carcinoma. Therefore, we conducted this study to explore an optimal criterion for preoperative diagnosis of lymph node metastasis in patients with rectal carcinoma by high resolution MRI.

### Patients and Methods

Fifty-one patients with middle or lower rectal carcinoma, undergoing radical surgery with total mesorectal excision from July 1997 through June 2001, were studied. All patients were prepared with enema on the morning of the examination. MRI was obtained by Magnetom VISION, 1.5 tesla superconducted apparatus (Siemens, Erlangen, Germany). Sequences obtained were T1-weighted image (TR:11ms, TE:550ms), T2-weighted image (TR: 3000ms, TE:100ms) and T2 fat-suppression image (TR 3500 ms, TE 100 ms). The matrix size was 256x192mm for T1-weighted images and 256x256mm for T2-weighted images. Slice thickness was 5 mm, and inter-slice gap was 3 mm. During examination, motion artifacts were reduced by intramuscular administration of 20mg N-butyl-joscina-bromure (Buscopan, Boehringer Ingerheim Co., Hyogo, Japan). Lymph node status was evaluated mainly on T2-weighted imaging without enhancement by one of the authors (A.N.) without knowledge of the findings of colonoscopy with biopsy, barium enema study and pathological examination. If lymph nodes were detected in the mesorectum, their number, size (both longitudinal and transverse axes), shape and internal structure were recorded. The shape of a lymph node on MRI was categorized as elliptical (length of longitudinal axis / length of transverse axis  $\geq 2$ ), round (length of longitudinal axis / length of transverse axis  $< 2$ ), or irregular. The internal structure of a lymph node was categorized as homogeneity, minor heterogeneity, or major (more than or equal to half of lymph node) heterogeneity. The number of lymph nodes seen in each case was counted, evaluated with regards to each factor and recorded in the computer data base. Subsequently, the largest lymph node detected on MRI was used as a representative of each case.

All patients underwent rectal resection with total mesorectal excision (19). Lymph nodes were harvested from surgical specimen just after the operation, fixed in 10% formalin, sectioned along the

*Correspondence to:* Hiroyoshi Matsuoka, M.D., The Department of Surgery, Kyorin University, 6-20-2 Shinkawa, Mitaka, Tokyo 181-8611, Japan. Tel: +81-422-47-5511 (ext.2941), Fax: +81-422-47-9926, e-mail: Hiroelvis@aol.com

*Key Words:* MRI, lymph node metastasis, rectal cancer.

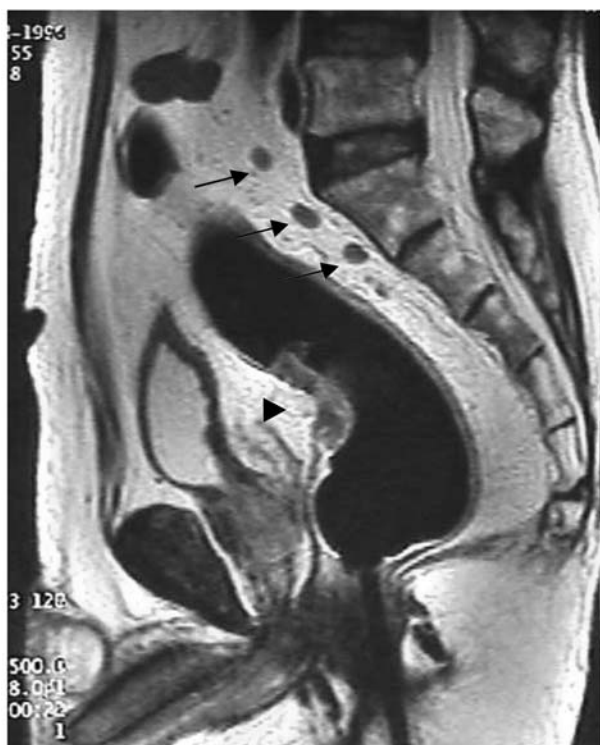

Figure 1. Rectal carcinoma and lymph node metastasis on MRI. (stage T3, N1) (T2-weighted imaging, sagittal section). Arrows indicate metastatic lymph node from 6 to 10 mm in longitudinal diameter with ellipse shape and minor heterogeneous internal structure. An arrowhead indicates the tumor.

longitudinal axis and stained with hematoxylin and eosin. Pathological slides were reviewed by pathologists who had no preoperative MRI information. On MR films, these measurements were also obtained and compared with pathological findings. An optimal preoperative criterion on MRI was clarified by receiver operating characteristic (ROC) analysis (20-22).

Statistical analysis was performed using SPSS version 6.1 for Windows (SPSS Japan Inc., Tokyo, Japan). Univariate analysis was obtained with the Mann Whitney *U*-test for numeric data and Fisher's exact test for categorized data. Differences were considered significant when the *p* value was less than 0.05. To clarify an optimal criterion, ROC analysis was used. When a ROC curve approaches nearest to the point (0,1), both sensitivity and specificity reach their highest value. The area under the ROC curve was also used for the evaluation of an optimal criterion. When both sensitivity and specificity are 100%, the area under the ROC curve indicates value 1, whereas when both sensitivity and specificity are 0%, the area under the ROC curve indicates value 0.

## Results

Of 51 patients, 26 were men and 25 were women with a mean age of 62 years. Tumor location was the middle rectum in 26 cases and lower rectum is 25 cases. Histological differentiation was well- and moderately-

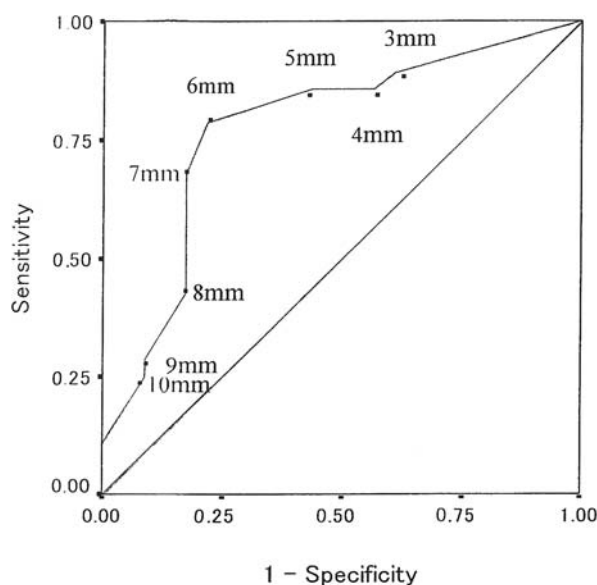


Figure 2. ROC curve of longitudinal axis diameter. A criterion of 6 mm showed the highest sensitivity, specificity and overall accuracy.

differentiated in 28 and 20 cases, respectively. The remaining 2 cases were mucinous carcinoma, while 1 case was a neuroendocrine tumor. The depth of invasion was T1 in 3 cases, T2 in 5 cases, T3 in 38 cases and T4 in 5 cases.

Twenty-eight patients had mesorectal lymph node metastasis pathologically. The number of mesorectal lymph nodes detected pathologically in each case ranged from 1 to 22, with a mean of 6. The largest lymph node always contained tumor deposits in patients with lymph node metastasis. As shown in Figure 1, mesorectal lymph nodes were detected by MRI in 39 patients, however, no mesorectal lymph nodes were detected in the remaining 12 patients. The number of mesorectal lymph nodes detected by MRI in each case ranged from 0 to 17, with a mean of 4. On the slides for histopathology, the size of mesorectal lymph nodes ranged from 3 to 30 mm in 39 patients with lymph nodes detected by MRI, and from 3 to 9 mm in 12 patients with lymph nodes not detected by MRI. The maximum size of lymph nodes detected pathologically was larger than that by MRI in 28 patients, whereas it was smaller than that by MRI in 20 patients. Both sizes were identical in only 2 patients.

With these backgrounds, we evaluated the criterion of predicting mesorectal lymph node metastasis. By univariate analysis, the average size (longitudinal and transverse axis diameters) was significantly larger in the lymph node metastasis (+) group than in the lymph node metastasis (-) group, whereas other factors did not show any significant difference (Table I).

Table I. MRI findings and lymph node metastasis.

MRI findings		Non-metastasis (22)	Metastasis (29)	<i>p</i>
Lymph node detection (No. of cases)	Absent	8	4	ns
	Present	14	25	
Size (mm)	Longitudinal axis (mean) (range)	4 (0*-18)	10 (0*-30)	<i>p</i> <0.05
	Transverse axis (mean) (range)	3 (0*-15)	8 (0*-30)	<i>p</i> <0.05
Shape (No. of cases)	Round	8	10	ns
	Ellipse	5	12	
	Irregular	1	3	
Internal structure (No. of cases)	Homogeneity	1	0	ns
	Minor heterogeneity	3	10	
	Major heterogeneity	10	15	

ns: not significant

\*: figure "0" implies that lymph node is not detected by MR imaging.

Table II. ROC analysis for optimal criterion among 3 categories.

Category	Groups	Area under ROC curve	SE
Category 1	Longitudinal axis	0.776	0.07
Category 2	Transverse axis	0.767	0.07
Category 3	Category 1 or 2	0.759	0.07

SE: Standard Error

To clarify optimal diagnostic criterion for diagnosing lymph node metastasis, ROC analysis was carried out by categorizing longitudinal and transverse axis diameters (Table II). A longitudinal axis diameter was the most reliable criterion. The ROC curve of longitudinal axis diameter showed that a criterion of 6 mm or larger was the most optimal for diagnosing lymph node metastasis, with a sensitivity of 77.8%, specificity of 78.3% and overall accuracy of 78.0% (Figure 2).

## Discussion

Preoperative imaging of metastatic lymph nodes is sometimes inaccurate due to the presence of microscopic metastasis or inflammatory swelling of lymph nodes. As reported previously, site-to-site comparison between pathological and imaging findings is difficult or impossible (7,12,15,16,23,24). In the present study, the largest lymph node was used as a representative node of each case, because the largest lymph node always contained tumor deposits in patients with lymph node metastasis. Due to slice interval and inter-slice gap, it may be reasonable that lymph nodes detected by MRI were smaller in size than those in pathology. However, in 20 cases in our series,

lymph nodes detected by MRI were larger than those in pathology. Sampling manipulation and shrinkage at formalin fixation may contribute to this peculiar finding (25,26). All these factors may underscore diagnostic accuracies of imaging studies. From these observations, whole-mount sectioned histology may be an ideal technique to handle rectal carcinoma specimens (6,18).

Preoperative diagnosis of mesorectal lymph node metastasis is of utmost importance in considering additional treatments such as preoperative or intraoperative radiation therapy in patients with middle or lower rectal carcinoma. For that purpose, endorectal ultrasound and CT have been widely used. Quite recently, MRI has become a mainstay for evaluating patients with rectal carcinoma because of its high resolution imaging and multi-planar images. We have already reported that pelvic-phased array coil MRI was superior to endorectal coil MRI in staging advanced rectal tumors (27).

The maximum diameter of lymph node has long been used as a diagnostic criterion in MRI studies. Subsequently, the technical refinements of MRI made it possible to depict the intrinsic lymph node signal and to improve the diagnostic accuracy by combining several criteria, such as size, shape and internal structure, as shown in Table III. Although these figures are not comparable because

Table III. Previous literature showing diagnostic criteria and diagnostic accuracy of lymph node metastasis by MRI.

Yr.	Authors	Cases	Criteria	Slice interval (mm)	Interslice gap (mm)	Sensitivity (%)	Specificity (%)	Overall accuracy (%)
1986	Butch <i>et al.</i> (7)	16	If recognized	5-10	---	---	---	83.3
1986	Hodgeman <i>et al.</i> (8)	27	If recognized	10	---	13	88	39
1990	de Lange <i>et al.</i> (9)	29	> 8 mm	6	2.4	57.1	87.5	78.3
1990	Guinet <i>et al.</i> (10)	19	≥ 6 mm at para-rectum.					
			≥ 10 mm short axis for others	12	1.2	43	95	73.7
1993	Okizuka <i>et al.</i> (11)	33	Recognizable whatever their diameter	5	2.5	57	95	87
1995	Stark <i>et al.</i> (12)	35	> 8 mm	6	---	64	78	72
1996	Indinimero <i>et al.</i> (13)	23	> 5 mm and homogenous texture	6	1.5	---	---	78.9
1997	Hadfield <i>et al.</i> (14)	38	> 5 mm	8	2	57	88	76
1999	Drew <i>et al.</i> (15)	29	> 5mm and non-homogeneous texture	7	3	58	76	70
1999	Kim <i>et al.</i> (16)	89	> 3 mm, irregular and heterogeneous texture	---	---	78.5	41.9	63.0
2000	Gualdi <i>et al.</i> (17)	26	Round or oval shape Non-tubular present	4	0.4	81	66	77
2003	Brown <i>et al.</i> (18)	98	A mixed signal intensity, Irregular or ill-defined borders	3	0.5	---	---	85
	Present study	51	≥ 6 mm	5	3	77.8	78.3	78.0

different criteria were used in different series of patients, combined criteria did not seem to provide better diagnostic accuracy than a single criterion. For identifying an optimal criterion, ROC analysis is an indispensable method (20-22). Previous ROC analyses showed that a 7-mm or 10-mm long axis diameter criterion was most useful for diagnosing mediastinal or cervical lymph node metastasis by CT scan (25,26). A minimum diameter of 9.3mm has been advocated as a CT criterion for mediastinal lymph node metastasis from epidermoid lung cancers (28). Our findings in rectal carcinoma were comparable with previous observations in different kinds of tumors, even though ROC analysis has not been reported in previous MRI studies.

Gualdi *et al.* and Brown *et al.* suggested that lymph node size was not a useful criterion (17,18). Thin slice MRI of 3- to 4-mm slice interval and 0.4- to 0.5-mm inter-slice gap could detect a larger number of lymph nodes than ours of 5-mm slice interval and 3-mm inter-slice gap, while internal structure and shape irregularities of lymph nodes might be better than size in predicting lymph node metastasis. However, this technique may be performed only with close collaboration among surgeons, pathologists and radiologists. Nevertheless, our overall accuracy was moderate at 78% and may still be reliable in the preoperative decision making for adjuvant chemo-radiation therapy.

## Conclusion

A 6-mm longitudinal diameter criterion is thought to be optimal in the MRI evaluation of mesorectal lymph node metastasis in patients with middle or lower rectal carcinoma.

## References

- 1 Wolmark N, Fisher ER, Wieand HS and Fisher B: The relationship of depth of penetration and tumor size to the number of positive nodes in Dukes C colorectal cancer. *Cancer* 53: 2707-2712, 1984.
- 2 Newland RC, Dent OF, Lyttle MN *et al.*: Pathological determinants of survival associated with colorectal cancer with lymph node metastases. A multivariate analysis of 579 patients. *Cancer* 73: 2076-2082, 1994.
- 3 Quirke P, Durdey P, Dixon MF and Williams NS: Local recurrence of rectal adenocarcinoma due to inadequate surgical resection. Histopathological study of lateral tumour spread and surgical excision. *Lancet* 2: 996-99, 1986.
- 4 Cawthorn SJ, Parums DV, Gibbs NMA *et al.*: Extent of mesorectal spread and involvement of lateral resection margin as prognostic factors after surgery. *Lancet* 335: 1055-1059, 1990.
- 5 Beets-Tan RGH, Beets GL, Vliegen RFA *et al.*: Accuracy of magnetic resonance imaging in prediction of tumor-free resection margin in rectal cancer surgery. *Lancet* 357: 497-504, 2001.

- 6 Brown G, Richards CJ, Newcombe RG *et al*: Rectal carcinoma: thin-section MR imaging for staging in 28 patients. *Radiology* 211: 215-222, 1999.
- 7 Butch RJ, Stark DD, Wittenberg J *et al*: Staging rectal cancer by MR imaging and CT. *Am J Roentgenol* 146: 1155-1160, 1986.
- 8 Hodgeman CG, MacCarty RL, Wolff BG *et al*: Preoperative staging of rectal carcinoma by computed tomography and 0.15T magnetic resonance imaging. Preliminary report. *Dis Colon Rectum* 29: 446-450, 1986.
- 9 de Lange EE, Fechner RE, Edge SB and Spaulding CA: Preoperative staging of rectal carcinoma with MR imaging: surgical and histopathologic correlation. *Radiology* 176: 623-628, 1990.
- 10 Guinet C, Buy JN, Ghossain MA *et al*: Comparison of magnetic resonance imaging and computed tomography in the preoperative staging of rectal cancer. *Arch Surg* 125: 385-388, 1990.
- 11 Okizuka H, Sugimura K and Ishida T: Preoperative local staging of rectal carcinoma with MR imaging and a rectal balloon. *J Magn Reson Imaging* 3: 329-35, 1993.
- 12 Stark M, Bohe M, Fork F-T, Lindström C and Sjöberg S: Endoluminal ultrasound and low-field magnetic resonance imaging are superior to clinical examination in the preoperative staging of rectal cancer. *Eur J Surg* 161: 841-845, 1995.
- 13 Indinnimeo M, Grasso RF, Cicchini C *et al*: Endorectal magnetic resonance imaging in the preoperative staging of rectal tumors. *Int Surg* 81: 419-22, 1996.
- 14 Hadfield MB, Nicholson AA, MacDonald AW *et al*: Preoperative staging of rectal carcinoma by magnetic resonance imaging with a phased array coil. *Br J Surg* 84: 529-31, 1997.
- 15 Drew PJ, Farouk R, Turnbull LW *et al*: Preoperative magnetic resonance staging of rectal cancer with an endorectal coil and dynamic gadolinium enhancement. *Br J Surg* 86: 2550-254, 1999.
- 16 Kim NK, Kim MJ, Yun SH *et al*: Comparative study of ultrasonography, pelvic computerized tomography and magnetic resonance imaging in the preoperative staging of rectal cancer. *Dis Colon Rectum* 42: 770-775, 1999.
- 17 Gualdi GF, Casciani E, Guadalaxara A *et al*: Local staging of rectal cancer with transrectal ultrasound and endorectal magnetic resonance imaging. Comparison with histopathologic findings. *Dis Colon Rectum* 43: 338-345, 2000.
- 18 Brown G, Radcliffe AG, Newcombe RG *et al*: Preoperative assessment of prognostic factors in rectal cancer using high-resolution magnetic resonance imaging. *Br J Surg* 90: 355-364, 2003.
- 19 Heald RJ and Ryall RD: Recurrence and survival after total mesorectal excision for rectal cancer. *Lancet* 1: 1479-1482, 1986.
- 20 Metz CE: Basic principles of ROC analysis. *Seminars in Nuclear Medicine* 8: 283-298, 1978.
- 21 Turner DA: An intuitive approach to receiver operating characteristic curve analysis. *J Nucl Med* 19: 213-220, 1977.
- 22 Hanley JA and McNeil BJ: The meaning and use of the area under a receiver operating characteristic (ROC) curve. *Radiology* 143: 29-36, 1982.
- 23 Mc Nicholas MM, Joyce WP, Dolan J *et al*: Magnetic resonance imaging of rectal carcinoma: a prospective study. *Br J Surg* 81: 911-14, 1994.
- 24 Blomqvist L, Rubio C, Holm T *et al*: Rectal adenocarcinoma: assessment of tumour involvement of the lateral resection margin by MRI of resected specimen. *Br J Radiol* 72: 18-23, 1999.
- 25 Kiyono K, Sone S, Sakai S *et al*: The number and size of normal mediastinal lymph nodes: A postmortem study. *Am J Roentgenol* 150: 771-776, 1988.
- 26 Kusajima Y and Hirono T: The adequate diagnostic criterion of mediastinal lymph node size for detection of metastasis in primary lung cancer. *Jpn J Thorac Cardiovasc Surg* 39: 1032-1038, 1991.
- 27 Matsuoka H, Nakamura A, Masaki T *et al*: Comparison between endorectal coil and pelvic phased-array coil magnetic resonance imaging in patients with anorectal tumor. *Am J Surg* 185: 328-332, 2003.
- 28 Kobayashi J and Kitamura S: Evaluation of lymph nodes on computed tomography images in epidermoid lung cancer. *Internal Medicine* 34: 507-513, 1995.

*Received June 1, 2004*

*Revised October 4, 2004*

*Accepted October 29, 2004*