

Assessment of Microvessel Density in Core Needle Biopsy Specimen in Breast Cancer

LISA RYDÉN¹, POUL BOIESEN² and PER-EBBE JÖNSSON¹

¹Department of Surgery and ²Department of Pathology, Helsingborg Hospital, Helsingborg, Sweden

Abstract. *Aim: Estimation of microvessel density (MVD) in primary breast cancer in core needle biopsies (CNB) may predict response to systemic therapy. The aim of the present study was to explore the accuracy of assessment of MVD in CNB related to MVD in excised tumours. Material and Methods: MVD was estimated in core biopsies and subsequently excised tumours in 54 consecutive patients with breast cancer without pre-operative treatment. Results: The correlation between MVD in CNB and excised tumours was non-significant. However, in tumours larger than 20 mm ($r=0.56$, $p=0.005$) and in lobular carcinomas ($r=0.55$, $p=0.014$) a significant correlation was observed. Conclusion: The overall accuracy between estimation of MVD on CNB and excised breast tumours was non-significant. The usefulness of MVD in CNB as a marker of response to systemic therapy should be further validated before it can be used in clinical practice.*

Core needle biopsy (CNB) is an established diagnostic tool for non-palpable and palpable breast lesions and is often the only pre-treatment tissue sample available for analysis of prognostic and predictive factors helpful in therapy decision making (1-3). Today immunohistochemical staining of estrogen receptor (ER) and progesterone receptor (PR) is routinely performed in CNB and is valuable when non-operative treatment is chosen, especially in the elderly (2-4). Assessment of biological markers, like c-erbB-2 and p53, in CNB is continuously being done and can be of predictive value when systemic treatment is given pre-operatively or in metastatic disease (3). Angiogenic activity has been quantified by estimation of microvessel density (MVD) in CNB, but the level of agreement between MVD in CNB and excised tumours has been low and the

estimation of MVD in CNB has not been found to be a reliable reflection of angiogenic activity within the breast tumour (5, 6).

The diagnostic accuracy of CNB regarding histological diagnosis and assessment of biological markers is influenced by tumour size, number of passed cores and whether the marker is continuously or dichotomously scored. The accuracy of histological diagnosis in CNB increases with tumour size as well as with the number of cores (2, 7-9). When assessing histological grade, the number of passed cores is even more important due to difficulties in correctly estimating the mitotic count in a limited number of cores (8). Quantification of continuously scored markers in CNB, like mitotic count and MVD, have been suggested to be interpreted with caution, whereas dichotomously scored markers have a high concordance (6). Hormone receptor content is a good example of a dichotomously scored marker already used in clinical practice (3, 6). The importance of validating biological markers in CNB in relation to subsequently excised tumours without pre-operative treatment have been addressed (6).

Angiogenic activity, as expressed by MVD or levels of vascular endothelial growth factor (VEGF), seems to be a promising predictive marker for response to medical therapy given pre-operatively or in the metastatic setting (10-13). Although validation of MVD in CNB is sparse, the method has been introduced as a possible marker of response to pre-operative therapy (10, 11). Response to hormonal therapy as well as chemotherapeutic therapy may be predicted by angiogenic activity and validation of surrogate markers such as MVD in CNB is an important issue (5, 6, 10, 11).

The aim of the present study was to assess angiogenic activity in primary breast cancer by MVD in CNB and in excised tumours in 54 consecutive patients without pre-operative treatment. The accuracy of MVD scoring was explored in relation to tumour size, number of passed cores and histopathological type. Additionally, semi-quantitative evaluation of the cytoplasmatic staining intensity of VEGF was performed in 18 out of 54 pairs of CNB and subsequently excised tumours.

Correspondence to: Dr Lisa Rydén, Department of Surgery, Helsingborg Hospital, S-251 87 Helsingborg, Sweden. Tel: +46 (0)42 810 00, Fax: +46042 1021 59, e-mail: lisa.ryden@helsingborgslasarett.se

Key Words: Breast cancer, core needle biopsy, microvessel density, vascular endothelial growth factor.

Materials and Methods

Patient data. From January 1999 to June 2001, 78 patients at Helsingborg Hospital, Sweden, with primary breast cancer were diagnosed by means of CNB when initial triple diagnostic procedure had failed to confirm a cancer diagnosis. Sixteen patients were excluded because they had hormonal therapy without surgery and another four patients were not entered due to pre-operative systemic treatment. The median age was 60 years (range 35-85).

Core needle biopsy. Two mL of mepivacain was infiltrated into the skin and a small skin incision was made. Twenty-four non-palpable lesions were sampled under ultrasound guidance (GE Logic 500 7.5-10MHZ liner transducer, General Electric, USA) with a semi-automatic 14G true-cut-needle (Precisa, Hospital Service, Rome, Italy) and for thirty palpable lesions a 14G Tru-Core I Automatic Biopsy Instrument (Medical Device Technologies Inc., Gainesville, Florida, USA) was used. Two to nine biopsies per patient were obtained (median 3.0). The number of obtained biopsies was not related to the method used (non-palpable *vs* palpable).

Tumour preparation. All tumours were analyzed histologically after fixation in formalin and embedding in paraffin and classified according to the International Union Against Cancer tumour-node-metastasis (UICC-TNM)-classification after staining with hematoxylin and eosin. Histological grade was evaluated in all tumours according to criteria by Elston and Ellis (14).

Hormone receptor content. Estrogen- (ER) and progesterone receptor (PR) content was analyzed by immunohistochemical technique as described by others (4). The tumours were classified as either positive or negative.

Microvessel density. Microvessel density (MVD) was calculated in tumour specimens and core biopsies. Paraffin-embedded and formalin-fixed sections were stained with anti-CD31-antibody (Dakopatts, Copenhagen, Denmark). The immunohistochemically-stained microvessels were counted in three areas of highest vascular density per section of tumour and core biopsy specimen at x 200 magnification as previously described (6, 10, 11, 15). Microvessel density was expressed as the average count in three areas of highest vascularity. All clinical data were blinded to the pathologist.

Four core biopsy specimens were excluded due to staining failure so that a total number of 54 pairs were evaluated.

Vascular endothelial growth factor. In 18 out of 54 subjects the material from CNB was sufficient to allow immunohistochemical staining of VEGF-A in core biopsies

and excised tumours using a rabbit polyclonal VEGF (Santa Cruz Biotechnology, Santa Cruz, CA, USA) at a working dilution of 1/400. The immunological reactivity evaluated as cytoplasmatic staining reactivity was assessed by two independent examiners. A semi-quantitative scale was used from 0-3 (0=no reaction, 1=poor reaction, 2=moderate reaction, 3=intense reaction).

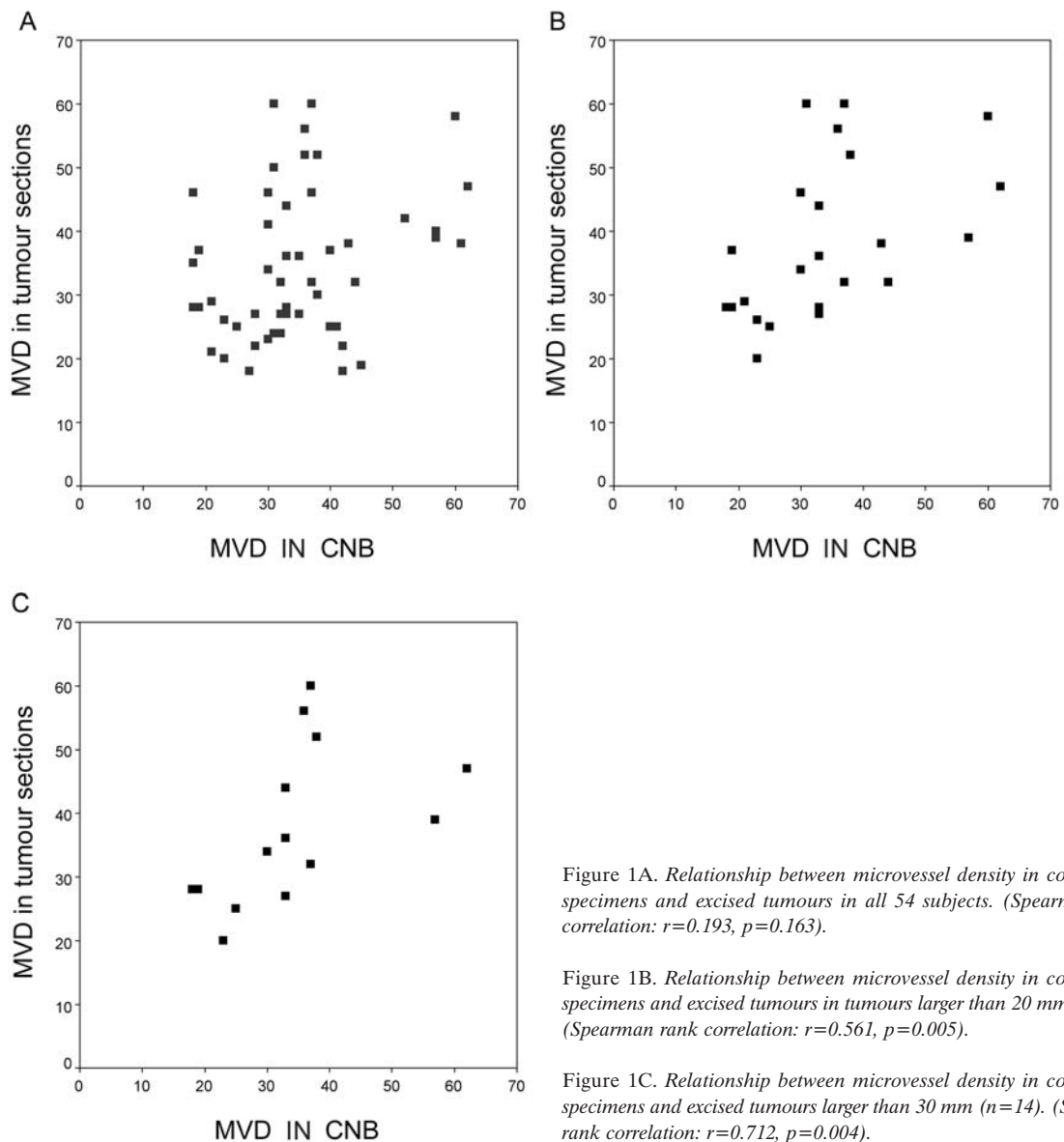
Statistical methods. Correlations were determined using the Spearman rank correlation test. The confidence interval for Spearman rank correlation was based on Fisher's transformation. Comparison of pairs were made using the Wilcoxon rank test. The level of agreement between the two types of specimens for the determination of MVD as a dichotomous variable was assessed by k statistics and Chi-square. The relationship between MVD in tumour sections and histopathological parameters and prognostic factors was assessed using Kruskal-Wallis test and Chi-square test. Linear multiple regression analysis was used when exploring confounding effects of tumour size and histopathological type on the correlation between MVD in the two types of specimens. All calculations were done with SPSS 11.0 (SPSS Inc., Ill., USA).

Results

Histopathological data. The mean tumour size was 23mm, median 20mm (range 7-75) and 31 ductal cancers, 19 lobular cancers and 4 tubular cancers were recorded. Ductal carcinomas had a mean tumour size of 21mm, median 17mm (range 7-50) and lobular carcinomas a mean tumour size of 30mm, median 35mm (range 9-75) and there was a significant difference in tumour size between the two types of breast carcinomas, $p=0.01$. Twenty-nine patients were node-positive and twenty-one node-negative, whereas no axillary surgery was performed in four patients. The ER-content was positive in 80% of the tumours and the PR-content was positive in 42%. There were 17 tumours with histological grade 1, 31 with histological grade 2 and 6 with histological grade 3.

Distribution of microvessel density in CNB and excised tumours and relationship to histopathological data. There was no difference in distribution between MVD in the two types of specimens ($p=0.524$, paired Wilcoxon). The median MVD was 32 (range 18-60) in excised tumours and 33 (range 18-62) in CNB. In excised tumours, 28 had a low value (cut-off at median 32) and 26 a high value, while in CNB, 26 had a low value (cut-off at median 33) and 28 a high value.

MVD in excised tumour sections significantly correlated to larger tumour size ($p=0.014$) and higher histological grade ($p=0.019$). There was no statistically significant correlation with ER negativity ($p=0.104$), PR negativity ($p=0.055$) or node status ($p=0.052$)



Relationship between microvessel density in core biopsy specimens and excised tumour sections. The correlation for all 54 core biopsies and tumour sections was not significant ($r=0.193$, 95% CI: -0.079-0.438, $p=0.163$), Figure 1A. However, in tumours larger than 20 mm ($n=23$), the correlation was significant ($r=0.561$, 95% CI: 0.193-0.790, $p=0.005$) without significant difference in the two sample types ($p=0.509$, paired Wilcoxon), Figure 1B. In 14 tumours 30 mm or larger the correlation was even more obvious ($r=0.712$, $p=0.004$), Figure 1C. In 31 tumours 20 mm or less no significant correlation was noted ($r=0.012$, 95% CI: -0.0344-0.365, $p=0.949$) and for invasive ductal cancers ($n=31$) the correlation was not significant ($r=-0.058$, 95% CI: -0.404-0.303, $p=0.758$).

In lobular cancers ($n=19$) MVD in the two types of specimen correlated significantly ($r=0.555$, 95% CI: 0.135-0.806, $p=0.014$) without any significant difference in counts in the two sample types ($p=0.372$, paired Wilcoxon). There was no evidence of a confounding effect of histological type with respect to the relationship between MVD in excised tumours and MVD in CNB in the two tumour size groups, although lobular cancers correlated significantly with tumour size ($p=0.020$). For tumours 20mm or less unadjusted for histological type ($n=27$), the regression coefficient beta was 0.014 (95% CI: -0.38 - 0.41) and, when adjusted for histological type, the regression coefficient beta was 0.006, (95% CI: -0.41 - 0.42). For tumours larger than 20mm unadjusted for histological type, the regression

coefficient beta was 0.51 (95% CI: 0.11 - 0.92) and, when adjusted for histological type, the regression coefficient beta was 0.51 (95% CI: 0.10 - 0.92).

When scoring MVD as a dichotomous variable with a cut-off at median value similar results were recorded. In 59% of the 54 pairs, identical values were recorded in CNB and excised tumours ($k=0.186$, $p=0.170$). For tumours larger than 20mm, a perfect agreement between the two sample types was achieved in 69% ($k=0.401$, $p=0.0046$) and for lobular cancers 15 out of 19 (79%) pairs had identical values ($k=0.582$, $p=0.009$). For ductal cancers and cancers 20mm or less the kappa-value was 0.091 and 0.057, respectively.

The percentage difference between MVD in CNB and tumour sections (MVD in tumour sections minus MVD in CNB, divided by MVD in tumour sections) did not correlate with the number of passed cores ($r=-0.104$, $p=0.456$), so there was no evidence that the number of passed cores affected the accuracy of MVD assessment.

Relationship of Vascular Endothelial Growth Factor (VEGF) in core biopsy specimens and excised tumours. Cytoplasmatic staining of VEGF was easily evaluable and present in all specimens. Semi-quantitative evaluation of VEGF had identical values in 55% (10/18) of pairs of core biopsies and excised tumours ($k=0.114$, $p=0.058$) and a not statistically significant correlation was recorded ($r=0.237$, $p=0.344$). The small number of observations did not allow sub-group analysis.

Discussion

The estimation of MVD in 54 CNB and subsequently excised tumours in this study has further documented the difficulties of accurate assessment of MVD in CNB of breast cancer, supporting two recent reports (5, 6). Tumour heterogeneity regarding vascularisation and difficulties in obtaining representative areas of high vascularity in a limited number of cores are possible explanations for the low accuracy of MVD in CNB (5, 6). However, we noted a significant correlation for tumours larger than 20 mm for MVD with a moderate kappa-value for dichotomously scored MVD, whereas in tumours 20 mm or less no significant correlation for MVD between core biopsies and excised tumours was observed. The correlation in tumours larger than 30mm was even stronger, suggesting that tumour size is of crucial importance for adequate estimation of MVD in CNB. MVD is increased by tumour size and the higher density of vessels in both specimens can contribute to a more accurate assessment. The importance of tumour size for accuracy of MVD scoring has not been explored previously (5, 6), although the accuracy of breast cancer diagnosis in CNB is significantly increased with increasing tumour size (2, 7, 8). It has been proposed that the method

is less suitable for use in small tumours due to difficulties in obtaining representative cores (7).

The number of passed cores in this study did not affect the representativity of MVD assessment in CNB, supporting data by others (5, 6). For correct estimation of histological grade in CNB the required optimum number of core biopsies is at least four, due to difficulties in estimating the mitotic count (8). Although MVD is a continuous variable influenced by vascular heterogeneity, the number of passed cores did not influence MVD scoring in this material where at least two biopsies were assessed. Accurate assessment of continuously scored biological markers in CNB is reported to be more difficult than dichotomously scored markers are (3, 6). In this study we tried to overcome this by statistical analysis of MVD as a dichotomous variable and by semi-quantitative analysis of staining intensity of VEGF. MVD analyzed as a dichotomous variable with cut-off at median gave the same information concerning representativity of MVD in CNB, *i.e.* low overall agreement, but increasing accuracy with tumour size and in histological subgroups. Additional staining with VEGF in 18 subjects did not assess angiogenesis more accurately in CNB than MVD. However, the number of observations here was limited and VEGF-staining in CNB has to be further explored before any conclusions can be drawn.

The high proportion of lobular cancers in this study reflects the diagnostic difficulties recognized with this histopathological type of breast tumour and explains the high proportion of histological grade 2 and ER-positive tumours. This study, including 35% lobular cancers, is not representative of the breast cancer population but of the population requiring CNB for definitive cancer diagnosis when initial triple diagnosis is based on fine-needle aspiration cytology. The 19 lobular cancers showed a significant correlation between MVD in CNB and tumours. The majority of lobular cancers (13/19) were larger than 20 mm and correlated significantly with tumour size and this may, in part, contribute to the correlation. However, regression-analysis in this material demonstrated that lobular carcinoma itself contributed to a significant correlation between the two types of specimen. The solid growth pattern of lobular cancers can explain why MVD scoring in CNB in this group of breast tumour is more accurate than in ductal cancers, where often areas of *in situ* growth are interposed within the invasive component. Additionally, data propose that angiogenesis in lobular cancers is regulated by other growth factors than in ductal cancers (16, 17). The histological type is usually not defined when evaluating CNB accuracy but the influence of histopathological subgroups on assessment of biological markers in CNB deserves further interest.

Today assessment of prognostic and predictive markers in CNB is important in therapeutic decision making in patients with primary breast cancer managed non-operatively or

having had pre-operative systemic therapy. In patients with disseminated disease, immunohistochemical evaluation of hormone receptor content in CNB from metastases can be assessed before medical therapy is chosen. An increasing number of biological markers are being validated in CNB, *i.e.* p53, c-erbB2 and others, in order to find predictive markers for response to conventional and new systemic therapies (3, 6). The validation of MVD on CNB has focused on the low representativity of the method making it doubtful whether it can be of any clinical value (5, 6). However, angiogenic activity assessed by MVD in CNB and related to MVD in tumours after treatment has already been introduced as a potential marker of response to pre-operative treatment with endocrine therapy and chemotherapeutic agents (10, 11). Analysis of surrogate markers for angiogenesis in CNB may predict response to traditional medical therapy as well as to specific anti-angiogenic drugs, but still deserves further validation in pairs of specimens from CNB and excised tumours without preoperative treatment. Serum analyses of VEGF levels can be used as surrogate markers for angiogenesis in metastatic disease but have no place in evaluating patients with localized disease (12, 13).

In conclusion, this study confirms previous data that overall agreement for MVD in CNB is low. The representativity of MVD in CNB increases with increasing tumour size, a finding that is analogous with histological breast cancer diagnosis in CNB. Interestingly, lobular cancers present with higher accuracy of MVD, reflecting the different growth pattern and regulation of angiogenesis in this tumour type as well as the higher proportion of larger tumours in this histological group. The potential usefulness of MVD in CNB as a surrogate marker for angiogenic activity in primary breast cancer and metastatic disease makes it necessary to validate the accuracy in a larger series before it is introduced as a predictive marker of tumour response.

Acknowledgements

We wish to thank Roland Perfekt, Regional Oncologic Center, Institution of Oncology, University of Lund, Sweden, for statistical analysis; Irene Johnsson, Department of Pathology, Helsingborg Hospital and Elise Nilsson, Department of Pathology, Division of Laboratory Medicine, University Hospital Malmö, Sweden, for their skilled technical assistance; FoU-radet, Högskolan i Kristianstad, the Gorthon Fund and Thelma Zoéga Foundation, University of Lund, Sweden, for grant support.

References

- 1 Taft R, Chao K, Dear P and King C: The role of core biopsy in the diagnosis of mammographically detected lesions. *Aust NZ J Surg* 66: 664-667, 1996.
- 2 Poole GH, Willsher PC, Pinder SE, Robertson JFR, Elston CW and Blamey RW: Diagnosis of breast cancer with core-biopsy and fine needle aspiration cytology. *Aust NZ J Surg* 66: 592-594, 1996.

- 3 Di Loreto C, Puglisi F, Rimondi G *et al*: Large core biopsy for diagnostic and prognostic evaluation of invasive breast carcinomas. *Eur J Cancer* 32: 1693-1700, 1996.
- 4 Pertschuk LP, Kim DS, Nayer K *et al*: Immunocytochemical estrogen and progesterin receptor assay in breast cancer with monoclonal antibodies: histopathologic, demographic, and biochemical correlations and relationship to endocrine response and survival. *Cancer* 66: 1663-1670, 1990.
- 5 Marson LP, Kurian KM, Miller WR and Dixon JM: Reproducibility of microvessel counts in breast cancer specimen. *Br J Cancer* 81: 1088-1093, 1999.
- 6 Jacobs TW, Kalliopi PS, Prioleau JE *et al*: Do prognostic marker studies in core needle biopsy specimens of breast carcinoma accurately reflect the marker status of the tumor? *Mod Pathol* 11: 259-264, 1998.
- 7 Roberts JG, Preece PE, Bolton PM, Baum M and Hughes LE: The "tru-cut" biopsy in breast cancer. *Clin Oncol* 1: 297-303, 1975.
- 8 McIlhenny C, Doughty JC, George WD and Mallon EA: Optimum number of core biopsies for accurate assessment of histological grade in breast cancer. *Br J Surg* 89: 84-85, 2002.
- 9 Kaufman HJ, Witherspoon LE, Gwin JL, Greer MS and Burns RP: Stereotactic breast biopsy: a study of first core samples. *Am Surg* 67: 572-576, 2001.
- 10 Marson LP, Kurian KM, Miller WR and Dixon JM: The effect of tamoxifen on breast tumour vascularity. *Breast Cancer Res Treat* 66(1): 9-15, 2001.
- 11 Bottini A, Berruti A, Bersiga A *et al*: Changes in microvessel density as assessed by CD34 antibodies after primary chemotherapy in human breast cancer. *Clin Cancer Res* 8(6): 1816-1821, 2002.
- 12 Lissoni P, Fugamalli E, Malugani F *et al*: Chemotherapy and angiogenesis in advanced cancer: vascular endothelial growth factor (VEGF) decline as predictor of disease control during taxol therapy in metastatic breast cancer. *Int J Biol Markers* 15: 308-11, 2000.
- 13 Colleoni M, Rocca A, Sandri MT *et al*: Low-dose oral methotrexate and cyclophosphamide in metastatic breast cancer: antitumor activity and correlation with vascular endothelial growth factor levels. *Ann Oncol* 13: 73-80, 2002.
- 14 Elston CW and Ellis IO: Pathological prognostic factors in breast cancer: The value of histological grade in breast cancer: experience from a large study with long-term follow-up: *Histopathology* 19: 403-410, 1991.
- 15 Weidner N, Semple JP, Welch WR and Folkman J: Tumor angiogenesis and metastasis – correlation in invasive breast carcinoma. *N Engl J Med* 324: 1-8, 1991.
- 16 Lee AHS, Dublin EA, Bobrow LG and Poulosom R: Invasive lobular and invasive ductal carcinoma of the breast show distinct patterns of vascular endothelial growth factor expression and angiogenesis. *J Pathol* 185: 394-401, 1998.
- 17 Coradini D, Pellizzaro C, Veneroni S, Ventura L and Daidone MG: Infiltrating ductal and lobular carcinomas are characterised by different interrelationships among markers related to angiogenesis and hormone dependence. *Br J Cancer* 87: 1105-1111, 2002.

Received September 2, 2003
Accepted December 15, 2003