ANTICANCER RESEARCH *41*: 3567-3572 (2021)
doi:10.21873/anticanres.15144

Primary Colonic Medullary Carcinoma With Exclusive Squamous Differentiation

IRENE Y. CHEN[1], JENNIFER J. FINDEIS-HOSEY[1], LISA CANNON[2] and XIAOYAN LIAO[1]

[1]*Department of Pathology and Laboratory Medicine, University of Rochester Medical Center, Rochester, NY, U.S.A.;*
[2]*Department of Surgery, University of Rochester Medical Center, Rochester, NY, U.S.A.*

Abstract. *Background/Aim: Medullary carcinoma (MC) of the colon is a rare subtype of colorectal adenocarcinoma (CRC) with unique histomorphology and frequent mismatch repair (MMR) deficiency. MC with exclusive squamous differentiation has not been reported. We report an unusual case of MC with squamous differentiation and tested this differentiation potential in other MMR-deficient CRC cases. Case Report: A 68-year-old woman presented with a large ascending colon mass and biopsy showed squamoid tumor morphology with immunoprofile concerning for squamous cell carcinoma (SCC). She underwent right hemicolectomy. Immunohistochemistry and next-generation sequencing (NGS) were performed for tumor classification. Macroscopically, the tumor was large and locally advanced. It metastasized to the lung without lymph node metastasis. Microscopically, the tumor cells were monotonous with cytological features of both MC and SCC. Immunostains were diffusely positive for p40 and CK5/6, but negative for other lineage markers including CDX2, CK20, and SATB2. The tumor was MMR deficient with loss of MLH1 and PMS2. NGS confirmed BRAF V600E mutation. In comparison, a tissue microarray comprising 64 previously diagnosed MMR deficient CRC was tested for squamous differentiation, and only 1 case showed focal CK5/6 expression, but none was positive for p40. Conclusion: MC with exclusive squamous differentiation not only posed significant diagnostic challenges, but also unveiled unrecognized differentiation plasticity in this tumor type.*

Correspondence to: Xiaoyan Liao, MD, PhD, Department of Pathology and Laboratory Medicine, University of Rochester Medical Center, 601 Elmwood Avenue, Rochester, New York 14642, U.S.A. Tel: +1 5852765653, Office: +1 5852767156, Fax: +1 5852733637, e-mail: xiaoyan_liao@urmc.rochester.edu

Key Words: Colorectal carcinoma, medullary carcinoma, squamous cell carcinoma, differentiation plasticity.

Medullary carcinoma (MC) of the colon is a rare subtype of colorectal adenocarcinoma (CRC) with an estimated incidence of 5-8 cases per 10,000 colon cancers diagnosed (1). The diagnostic term was first introduced in 1999 by Jessurun describing 11 cases of right colon CRC that all occurred in women, with distinct morphology featuring solid growth pattern, poor gland formation, small to medium sized cells, moderate amount of eosinophilic cytoplasm, and prominent nucleoli (1). MC has been increasingly recognized in the past two decades (2, 3). It has been frequently found to demonstrate high microsatellite instability (MSI-H) or mismatch repair deficiency (dMMR), particularly with loss of MLH1/PMS2 secondary to *MLH1* promoter hypermethylation, a CpG island methylator phenotype (CIMP) tightly associated with the *BRAF* V600E mutation (4, 5). Although morphologically poorly differentiated, the overall survival of MC in colon is paradoxically better than other non-glandular CRC at early stages (6), and may respond to immune-checkpoint inhibitor-mediated therapy (7). On the other hand, squamous cell carcinoma (SCC) of the colon is extremely rare, with an estimated incidence of 1-2.5 cases per 10,000 colon cancers diagnosed (8). SCC commonly occurs in the rectosigmoid colon and often presents at a late stage with poor prognosis (9). Metastatic SCC to colon is also extremely rare, with few reported cases (10). SCC can morphologically mimic MC due to a similar solid growth pattern and eosinophilic cytoplasm of tumor cells, which can be a potential diagnostic pitfall, especially in limited biopsies.

In this study, we identified a unique case of primary colonic MC with exclusive squamous differentiation and evaluated this differentiation potential in 64 previously resected dMMR CRC cases. Our study unveiled a previously unrecognized differentiation plasticity in colonic MC.

Case Report

A 68-year-old female with no significant past medical history presented with a 3-month history of bloody stool and fatigue, along with a 30-pound unintentional weight loss. CT scan

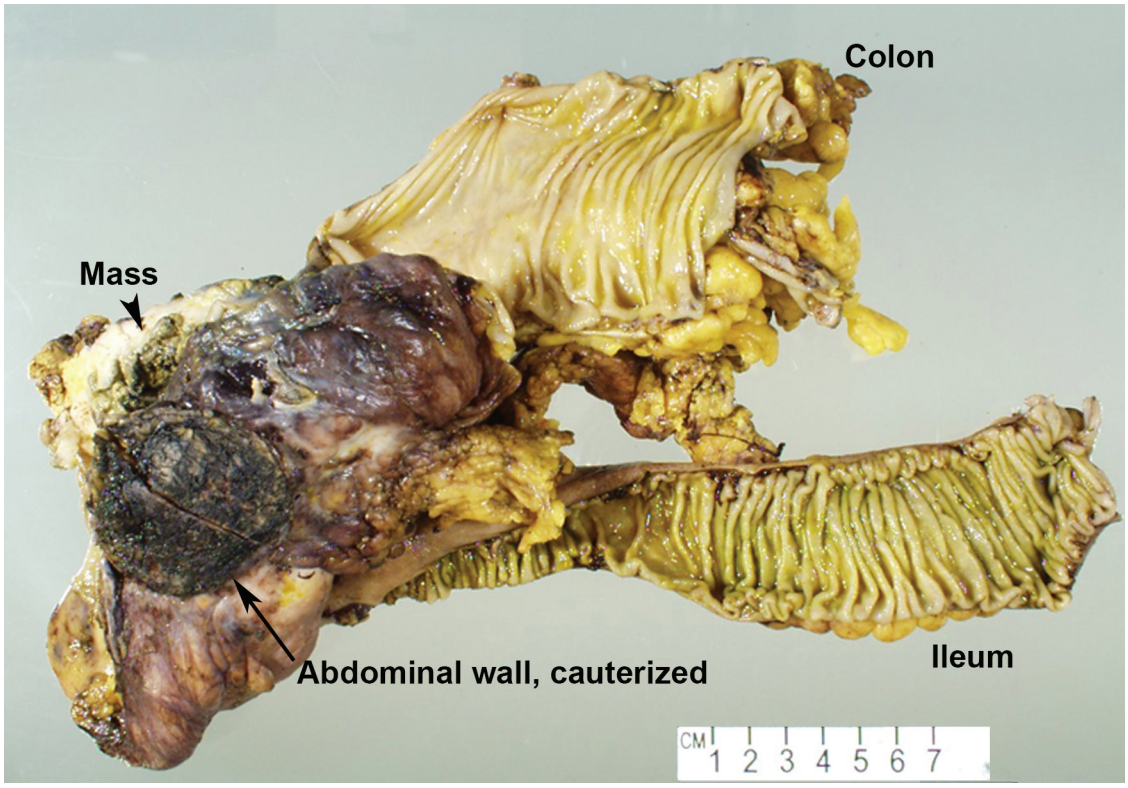

Figure 1. *Macroscopic examination of the right colon mass. The mass (arrow head) is adherent to the terminal ileum and a portion of abdominal wall (arrow).*

revealed a large infiltrative circumferential mass involving the colon wall at the hepatic flexure and causing partial luminal obstruction. A 2.2 cm right lower lobe lung nodule of uncertain behavior was also noted on imaging studies. No liver metastases were identified. Her CEA levels were within normal limits (2.2 ng/ml, range=0.0-4.7 ng/ml). Biopsy of the colon mass showed a poorly differentiated carcinoma with solid growth and squamoid morphology with strong and diffuse positivity for squamous cell markers p40 and CK5/6, raising concern for metastatic SCC to colon from a lung primary. The patient subsequently underwent a right hemicolectomy.

During surgery, a large hepatic flexure mass was identified, fused to the right upper quadrant side wall and adherent to a loop of terminal ileum (Figure 1). Macroscopic examination revealed a 13.0×11.0×5.0 cm tan annular ulcerated mass with heaped up borders located in the cecum/ascending colon. Microscopically, the mucosal surface was extensively eroded without identifiable precursor lesions. The tumor cells were uniformly round to polygonal, with eosinophilic to amphiphilic cytoplasm, vesicular nuclei and prominent nucleoli. The tumor cells were organized in cords and nests and surround by a desmoplastic stromal reaction. Occasional intercellular bridges were identified, but no keratin pearls were noted. The tumor invaded with a pushing border and associated lymphoid tissue reaction, with increased tumor infiltrating lymphocytes (Figure 2A-C). Despite extensive extramural small and large vascular invasions, there were no lymph node metastasis identified in 48 lymph nodes.

Immunohistochemical studies performed on representative tumor sections demonstrated the tumor cells to be strongly and diffusely positive for CK5/6 and p40 (Figure 3), but negative for all other lineage markers including CDX2, CK7, CK20, TTF1, Napsin A, Calretinin, WT-1, Inhibin, Synaptophysin, Chromogranin, S100, SOX10, or GATA3. P53 showed normal wild-type expression. *In situ* hybridization for high-risk human papilloma virus (HPV) and Epstein-Barr virus (EBV) were also negative. IHC studies of the mismatch repair proteins demonstrated no nuclear MLH1 or PMS2 protein expression, but did show MSH2 and MSH6 nuclear expression. Further, molecular analysis revealed the presence of a *BRAF* c. 1799 T>A (p. Val600Glu) activating mutation, suggesting the tumor is likely to be sporadic due to hypermethylation of the *MLH1* promoter. Based on the histologic features, IHC profile, and molecular findings, a diagnosis of primary colonic MC with squamous differentiation was rendered.

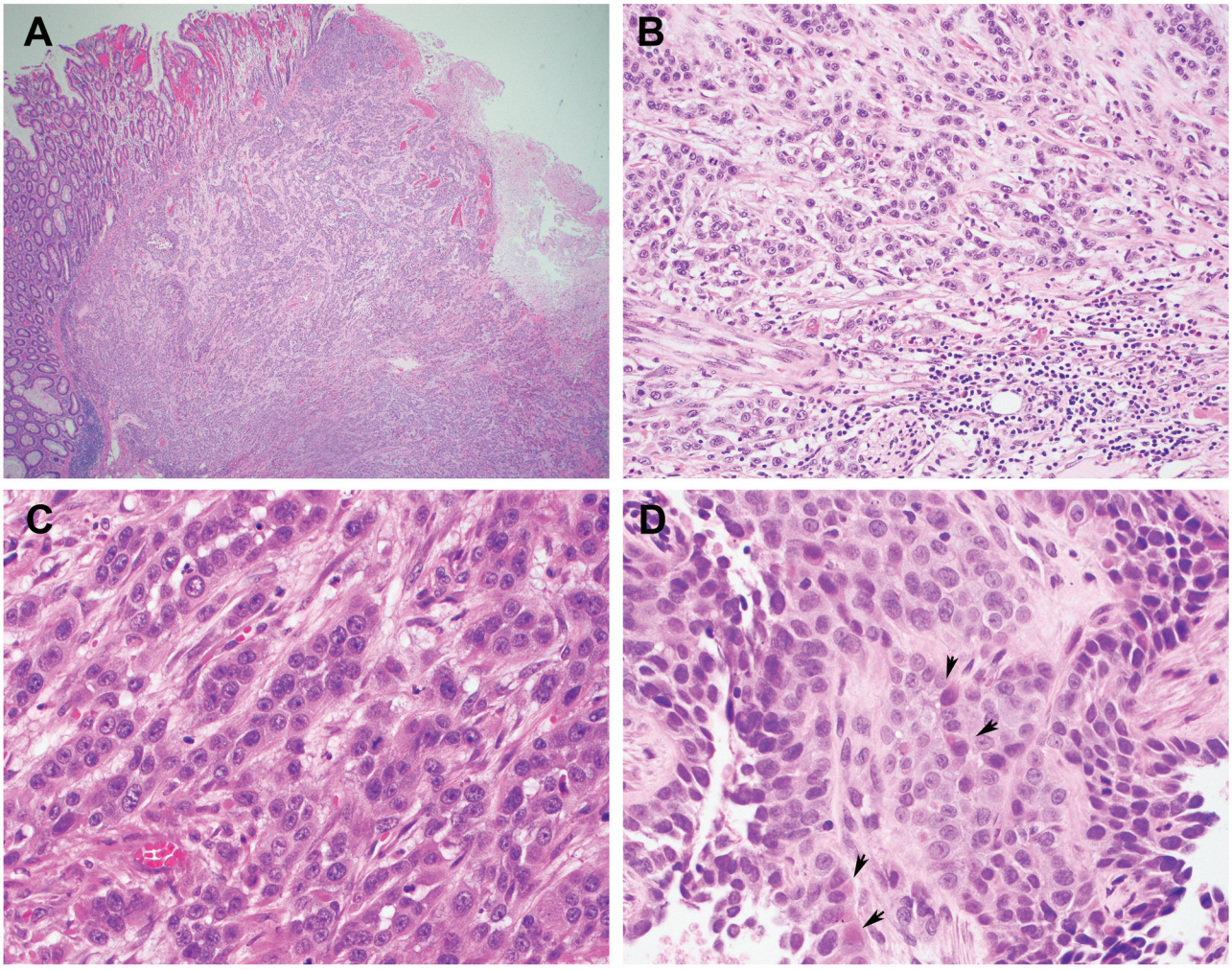

Figure 2. *Histology of the medullary carcinoma in colon (A-C) and its metastasis to the lung (D). (A) The tumor shows mucosal erosion and no identifiable precursor lesion. (B) It invades the stroma with a pushing border and increased intratumoral lymphocytes. (C) The tumor cells are monotonous, having eosinophilic cytoplasm, round nuclei and prominent centrally located nucleoli. Notice the desmoplastic reaction that is not typically seen in an ordinary medullary carcinoma. (D) The tumor metastatic to the lung shows similar morphology as in the colon, with some cells demonstrating dense pink cytoplasm (black arrows). Magnification: A: 20×, B: 100×, C-D: 400×.*

Subsequently, the patient underwent endobronchial ultrasound-guided fine needle biopsy for the solitary right lower lobe lung nodule, which showed exactly the same tumor morphology and immunoprofile as the colon mass, consistent with metastatic disease (Figure 2D). The final pathologic stage was thus pT4b N0 M1. The patient was then referred to oncologists for immunotherapy (pembrolizumab).

To ascertain if this is the first and only MC that demonstrates exclusive squamous differentiation, we performed IHC studies on a tissue microarray (TMA) comprising 64 dMMR CRCs. Our results showed that only 1 of the 64 dMMR CRC demonstrated focal CK5/6 expression, while none showed any nuclear p40 expression. Extensive literature search performed on PubMed also did not reveal any relevant information regarding aberrant squamous differentiation in an otherwise typical colonic MC, suggesting this phenomenon to be extremely rare and unusual.

Discussion

In this study, we report the first description of a colonic MC with exclusive squamous differentiation. Examination of the clinicopathologic findings in this case support the diagnosis. While colonic MC is rare, it is still much more common than a primary colonic SCC or metastatic SCC to the colon. Female sex, right colon location, and no prior history of

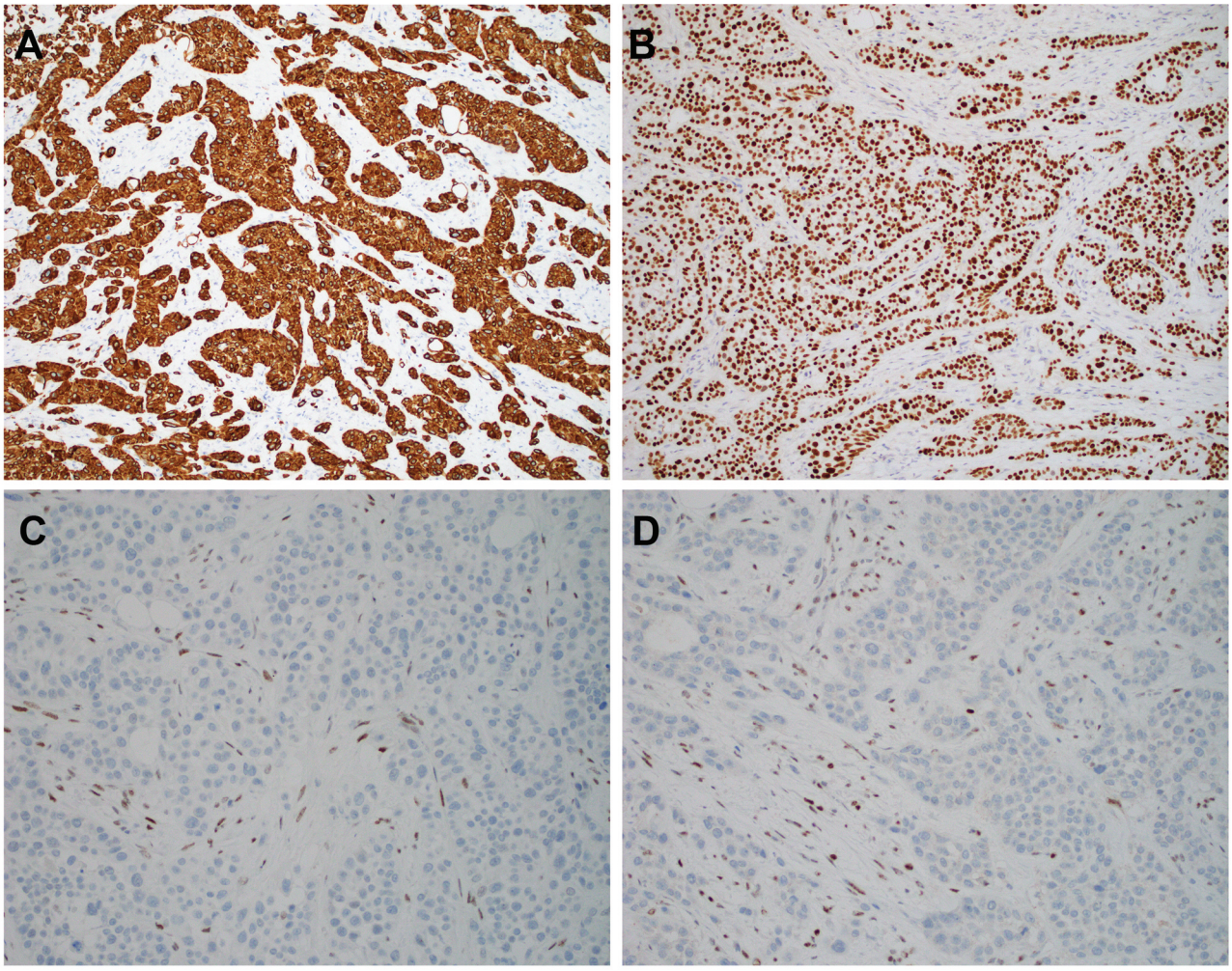

Figure 3. *Immunohistochemistry studies showing that the tumor cells are diffusely positive for CK5/6 (A) and p40 (B). The tumor cells are negative for MLH1 (C) and PMS2 (D), indicating that they are mismatch repair deficient. Magnification: A-D: 200×.*

malignancy additionally support the diagnosis. Lack of lymph node metastasis in such a locally advanced tumor would be much more commonly seen in MC than a primary or metastatic SCC. Of course, the histomorphology is key to diagnosis. The word "medullary" was coined to reflect the histological features of this tumor being solid, with nested, organoid, or trabecular growth pattern mimicking endocrine carcinomas. Cytologically, the tumor cells are classically small, round and uniform with scant eosinophilic cytoplasm and rounded nuclei with small central nucleoli (1). Grossly, MC is usually a locally advanced polypoid mass with central ulceration, often 50% larger in size than non-medullary malignancies, and predominantly involving the right colon (2, 3). Instead of having an infiltrative pattern typically seen in SCC or other conventional CRC, MC has pushing borders with increased intratumoral and peritumoral lymphocytic infiltration. Further, ancillary tests demonstrating dMMR/MSI-H and *BRAF* mutation are confirmatory (11). Despite intercellular bridging, desmoplastic stromal reaction, and diffuse squamous marker expression (CK5/6 and p40) that masqueraded itself as a SCC, the diagnosis of MC is reasonable and should be managed accordingly in our patient.

Complete and exclusive squamous cell differentiation in an otherwise classic MC not only posed diagnostic challenges, but also unveiled a previously unrecognized plasticity of differentiation in this tumor (12). Indeed, MC has been reported to frequently lose its colonic markers (12, 13). Aberrant nuclear and cytoplasmic positivity for a neural marker Calretinin in MC has been reported (13, 14). It is worth noting that the World Health Organization and the American Joint Committee on Cancer (AJCC) specifically separate MC from other undifferentiated CRC for its uniform morphology and

molecular defects (15, 16). Thus, when Nguyen *et al*. described a case of "MC" with aberrant lymphoid marker expression, it was noted that the reported tumor had pleomorphic morphology and microsatellite stable (MSS) phenotype that would best be classified as an undifferentiated carcinoma of colon rather than MC (17). Nevertheless, their case also exemplified that CRC, no matter poorly differentiated or undifferentiated, can present with aberrant differentiation completely deviating from its colonic lineage.

Distinction between a primary MC and SCC is critical for clinical follow-up and management. Compared to other histologically similar entities or undifferentiated carcinomas, the prognosis of MC is more favorable despite frequent large tumor size and local aggressiveness (2). Surgical resection is the main treatment modality (1, 3). Adjuvant chemotherapy is not usually required unless lymph node or distant metastases are present. In addition, the dMMR/MSI-H status may render it responsive to an immune checkpoint inhibitor (18). In contrast, the diagnosis of a large poorly differentiated SCC in visceral organs often portends a poor prognosis (9). The preferred treatment of colonic SCC is surgical resection, with the recommendation of additional of chemotherapy (8). Pure SCC in the right colon is extremely rare and has been mostly associated with adenosquamous carcinoma of the colon (19). It was hypothesized that the squamous differentiation in colonic tumors may be associated with pluripotent stem cell differentiation, malignant transformation of persistent ectopic embryonal nests of ectodermal cells, or squamous differentiation of a preexisting colonic adenoma, which may be also the underlying mechanism in our case (20).

Besides SCC, other differential diagnosis to be considered in our case includes colorectal neuroendocrine carcinoma (NEC), which often exhibits organoid, nested, or trabecular growth pattern similar to those of MC (13). Negative neuroendocrine markers can help differentiating MC from NEC. With the characteristic increased lymphocytic infiltration, a high-grade lymphoma should also be ruled out, especially when the MC demonstrates aberrant lymphoid marker expression (11). Given the lack of mucosal surface precursor lesions, other differential diagnoses to be considered include epithelioid mesenchymal tumors such as epithelioid gastrointestinal stroma tumor (GIST), or malignant gastrointestinal neuroectodermal tumor (GNET), which may morphologically mimic MC, but can be distinguished by ancillary studies (21).

In summary, we report the first case of a colonic MC with exclusive squamous differentiation, masquerading as a primary colonic SCC or metastatic SCC from the lung. The correct diagnosis of MC was dependent on an integrated analysis of the clinical picture, histomorphology, immunophenotype, and molecular studies. The take-home message is to always keep MC in the differential diagnosis when dealing with a poorly differentiated neoplasm of the colon, especially when located in the right colon. In addition, this unusual case appears to open a Pandora's box for unlimited differentiation potential in this type of tumor, which was not previously recognized. Future studies may focus on the pathogenesis of aberrant squamous differentiation and its implication in patient survival, which may or may not be different than an otherwise orthodox colonic MC.

Conflicts of Interest

The Authors declare no conflicts of interest with regard to the present study.

Authors' Contributions

IYC, LC and XL collected the data, JFH and XL designed the study and performed the research, IYC and XL wrote the paper.

Acknowledgements

The Authors thank the histology and molecular diagnostic laboratory of the Department of Pathology and Laboratory Medicine at University of Rochester Medical Center for their technical support.

References

1 Jessurun J, Romero-Guadarrama M and Manivel JC: Medullary adenocarcinoma of the colon: clinicopathologic study of 11 cases. Hum Pathol *30(7)*: 843-848, 1999. PMID: 10414504. DOI: 10.1016/s0046-8177(99)90146-6

2 Knox RD, Luey N, Sioson L, Kedziora A, Clarkson A, Watson N, Toon CW, Cussigh C, Pincott S, Pillinger S, Salama Y, Evans J, Percy J, Schnitzler M, Engel A and Gill AJ: Medullary colorectal carcinoma revisited: a clinical and pathological study of 102 cases. Ann Surg Oncol *22(9)*: 2988-2996, 2015. PMID: 25572685. DOI: 10.1245/s10434-014-4355-5

3 Thirunavukarasu P, Sathaiah M, Singla S, Sukumar S, Karunamurthy A, Pragatheeshwar KD, Lee KK, Zeh H 3rd, Kane KM and Bartlett DL: Medullary carcinoma of the large intestine: a population based analysis. Int J Oncol *37(4)*: 901-907, 2010. PMID: 20811712. DOI: 10.3892/ijo_00000741

4 Pyo JS, Sohn JH and Kang G: Medullary carcinoma in the colorectum: a systematic review and meta-analysis. Hum Pathol *53*: 91-96, 2016. PMID: 27001432. DOI: 10.1016/j.humpath.2016.02.018

5 Lanza G, Gafà R, Maestri I, Santini A, Matteuzzi M and Cavazzini L: Immunohistochemical pattern of MLH1/MSH2 expression is related to clinical and pathological features in colorectal adenocarcinomas with microsatellite instability. Mod Pathol *15(7)*: 741-749, 2002. PMID: 12118112. DOI: 10.1097/01.MP.0000018979.68686.B2

6 Friedman K, Brodsky AS, Lu S, Wood S, Gill AJ, Lombardo K, Yang D and Resnick MB: Medullary carcinoma of the colon: a distinct morphology reveals a distinctive immunoregulatory microenvironment. Mod Pathol *29(5)*: 528-541, 2016. PMID: 26965581. DOI: 10.1038/modpathol.2016.54

7 Llosa NJ, Cruise M, Tam A, Wicks EC, Hechenbleikner EM, Taube JM, Blosser RL, Fan H, Wang H, Luber BS, Zhang M, Papadopoulos N, Kinzler KW, Vogelstein B, Sears CL, Anders RA, Pardoll DM and Housseau F: The vigorous immune microenvironment of microsatellite instable colon cancer is balanced by multiple counter-inhibitory checkpoints. Cancer Discov *5(1)*: 43-51, 2015. PMID: 25358689. DOI: 10.1158/2159-8290.CD-14-0863

8 Abdelqader A, Jabaji R, Albugeaey M and Palese C: Squamous cell carcinoma of the ascending colon: two cases. J Community Hosp Intern Med Perspect *7(1)*: 53-55, 2017. PMID: 28634528. DOI: 10.1080/20009666.2017.1309339

9 Ozuner G, Aytac E, Gorgun E and Bennett A: Colorectal squamous cell carcinoma: a rare tumor with poor prognosis. Int J Colorectal Dis *30(1)*: 127-130, 2015. PMID: 25392258. DOI: 10.1007/s00384-014-2058-9

10 Garg N, Stoehr C, Zhao YS, Rojas H and Hsueh CT: Metastatic squamous cell carcinoma of colon from esophageal cancer. Exp Hematol Oncol *6*: 11, 2017. PMID: 28428908. DOI: 10.1186/s40164-017-0069-2

11 Swadley MJ, Deliu M, Mosunjac MB, Gunthel CJ, Nguyen ML and Hanley KZ: Primary and secondary hepatic lymphomas diagnosed by image-guided fine-needle aspiration: a retrospective study of clinical and cytomorphologic findings. Am J Clin Pathol *141(1)*: 119-127, 2014. PMID: 24343745. DOI: 10.1309/AJCPE58ESCQDZFKX

12 Hinoi T, Tani M, Lucas PC, Caca K, Dunn RL, Macri E, Loda M, Appelman HD, Cho KR and Fearon ER: Loss of CDX2 expression and microsatellite instability are prominent features of large cell minimally differentiated carcinomas of the colon. Am J Pathol *159(6)*: 2239-2248, 2001. PMID: 11733373. DOI: 10.1016/S0002-9440(10)63074-X

13 Winn B, Tavares R, Fanion J, Noble L, Gao J, Sabo E and Resnick MB: Differentiating the undifferentiated: immunohistochemical profile of medullary carcinoma of the colon with an emphasis on intestinal differentiation. Hum Pathol *40(3)*: 398-404, 2009. PMID: 18992917. DOI: 10.1016/j.humpath.2008.08.014

14 Gotzos V, Wintergerst ES, Musy JP, Spichtin HP and Genton CY: Selective distribution of calretinin in adenocarcinomas of the human colon and adjacent tissues. Am J Surg Pathol *23(6)*: 701-711, 1999. PMID: 10366153. DOI: 10.1097/00000478-199906000-00010

15 Amin MB, Greene FL, Edge SB, Compton CC, Gershenwald JE, Brookland RK, Meyer L, Gress DM, Byrd DR and Winchester DP: AJCC cancer staging manual. 8th ed. Springer, New York, 2017.

16 Salomao M, Remotti H, Vaughan R, Siegel AB, Lefkowitch JH and Moreira RK: The steatohepatitic variant of hepatocellular carcinoma and its association with underlying steatohepatitis. Hum Pathol *43(5)*: 737-746, 2012. PMID: 22018903. DOI: 10.1016/j.humpath.2011.07.005

17 Nguyen J, Coppola D, Shan Y and Zhang L: Poorly differentiated medullary carcinoma of the colon with an unusual phenotypic profile mimicking high grade large cell lymphoma - a unique case report and review of the literature. Int J Clin Exp Pathol *7(2)*: 828-834, 2014. PMID: 24551312.

18 Gafà R, Maestri I, Matteuzzi M, Santini A, Ferretti S, Cavazzini L and Lanza G: Sporadic colorectal adenocarcinomas with high-frequency microsatellite instability. Cancer *89(10)*: 2025-2037, 2000. PMID: 11066042.

19 Frizelle FA, Hobday KS, Batts KP and Nelson H: Adenosquamous and squamous carcinoma of the colon and upper rectum: a clinical and histopathologic study. Dis Colon Rectum *44(3)*: 341-346, 2001. PMID: 11289278. DOI: 10.1007/BF02234730

20 Williams GT, Blackshaw AJ and Morson BC: Squamous carcinoma of the colorectum and its genesis. J Pathol *129(3)*: 139-147, 1979. PMID: 529012. DOI: 10.1002/path.1711290306

21 Alyousef MJ, Alratroot JA, ElSharkawy T, Shawarby MA, Al Hamad MA, Hashem TM and Alsayyah A: Malignant gastrointestinal neuroectodermal tumor: a case report and review of the literature. Diagn Pathol *12(1)*: 29, 2017. PMID: 28320420. DOI: 10.1186/s13000-017-0620-9

Received May 4, 2021
Revised May 14, 2021
Accepted May 27, 2021