ANTICANCER RESEARCH *40*: 4419-4423 (2020)
doi:10.21873/anticanres.14447

Fibrosis or Necrosis in Resected Lymph Node Indicate Metastasis Before Chemoradiotherapy in Lung Cancer Patients

YUTA TAKAHASHI[1], JUNICHI SOH[1], KAZUHIKO SHIEN[1], HIROMASA YAMAMOTO[1], MASAOMI YAMANE[1], KATSUYUKI KIURA[2], SUSUMU KANAZAWA[3], HIROYUKI YANAI[4] and SHINICHI TOYOOKA[1]

Departments of [1]General Thoracic Surgery and Breast and Endocrinological Surgery, [2]Respiratory Medicine, [3]Radiology, and [4]Pathology, Okayama University Graduate School of Medicine, Dentistry, and Pharmaceutical Sciences, Okayama, Japan

Abstract. *Background/Aim: The histological features of lymph nodes (LNs) treated by chemoradiotherapy (CRT) in non-small cell lung cancer (NSCLC) have not been well studied. The purpose of this study was to evaluate the histological findings of LNs affected by CRT. Patients and Methods: Among 107 clinically N2 NSCLC patients who underwent induction CRT followed by surgery from 1999 to 2017, 24 patients who received pathological evaluation of mediastinal LN before CRT were enrolled in this study. Postoperatively, we histologically reviewed all resected LNs (n=117) of the station evaluated before CRT. Results: Fibrosis and/or necrosis were observed in all investigated LN stations. Histological observation of fibrosis and/or necrosis in the resected LNs after CRT indicated the presence of LN metastasis before CRT. Conclusion: The metastatic LNs that responded to CRT showed specific histological features, which enabled us to know the accurate clinical stage of the patient even though cancer cells were not found in the post-treated LNs.*

Induction chemoradiotherapy (CRT) followed by surgery is one of the treatment options for locally advanced non-small cell lung cancer (NSCLC) (1). It is well known that histological changes, such as fibrosis or necrosis, are common pathological indicators of therapeutic response in the primary tumor (2). The existence of such histopathological findings indicates the presence of cancer cells before treatment, and based on these findings, several histological grading systems about the effect of CRT on the primary tumor have been reported (3). However, the pathological findings in metastatic lymph nodes (LNs) treated by CRT have not been well-documented.

Downstaging of mediastinal LNs is a favorable prognostic indicator of N2 disease after induction therapy (4). Thus, accurate estimation of LN status before CRT is important not only to determine the pretreatment stage, but also to predict the prognosis of the disease. Endobronchial ultrasound-guided transbronchial needle aspiration (EBUS-TBNA) is the option available to evaluate mediastinal LN metastatic status before CRT. Based on these facts, we investigated the pathological findings of metastatic and non-metastatic LNs after CRT, by reviewing the resected LNs of NSCLC patients treated with CRT, and comparing them to the pathological findings of the LNs obtained by EBUS-TBNA.

Patients and Methods

Patient selection. Between January 1999 and December 2017, a total of 107 NSCLC patients with clinically N2 (cN2) disease underwent induction CRT followed by surgery at Okayama University Hospital. Among them, EBUS-TBNA was performed in 28 patients, to evaluate mediastinal LN metastasis before introduction of treatment. We excluded four of these patients because sufficient material was not obtained by EBUS-TBNA in three patients and curative resection was not performed in one patient. Disease staging was performed according to the International Association of the Study of Lung Cancer TNM staging system, 8th edition (5). This is a retrospective study and the study protocol was approved by the Institutional Review Board and Ethics Committee of Okayama University (permission number 1055). Written informed consent was waived by this ethics committee.

Treatment. Platinum-based chemotherapy with concurrent radiation at a dose of 46 Gy was administered as induction CRT. Patients without unresectable lesions were scheduled to undergo surgery (basically lobectomy with systemic mediastinal lymph nodal dissection) within 4 to 8 weeks after the completion of CRT (6).

Histopathological evaluation of mediastinal LNs before and after induction CRT. Before CRT, EBUS-TBNA followed by histological

Correspondence to: Junichi Soh, MD, Ph.D., Department of General Thoracic Surgery and Breast and Endocrinological Surgery, Okayama University Graduate School of Medicine, Dentistry, and Pharmaceutical Sciences 2-5-1 Shikata-cho, Kitaku, Okayama 700-8558, Japan. Tel: +81 862357265, Fax: +81 862357269, e-mail: drjsou7@gmail.com

Key Words: Fibrosis, necrosis, non-small cell lung cancer, lymph node, chemoradiotherapy.

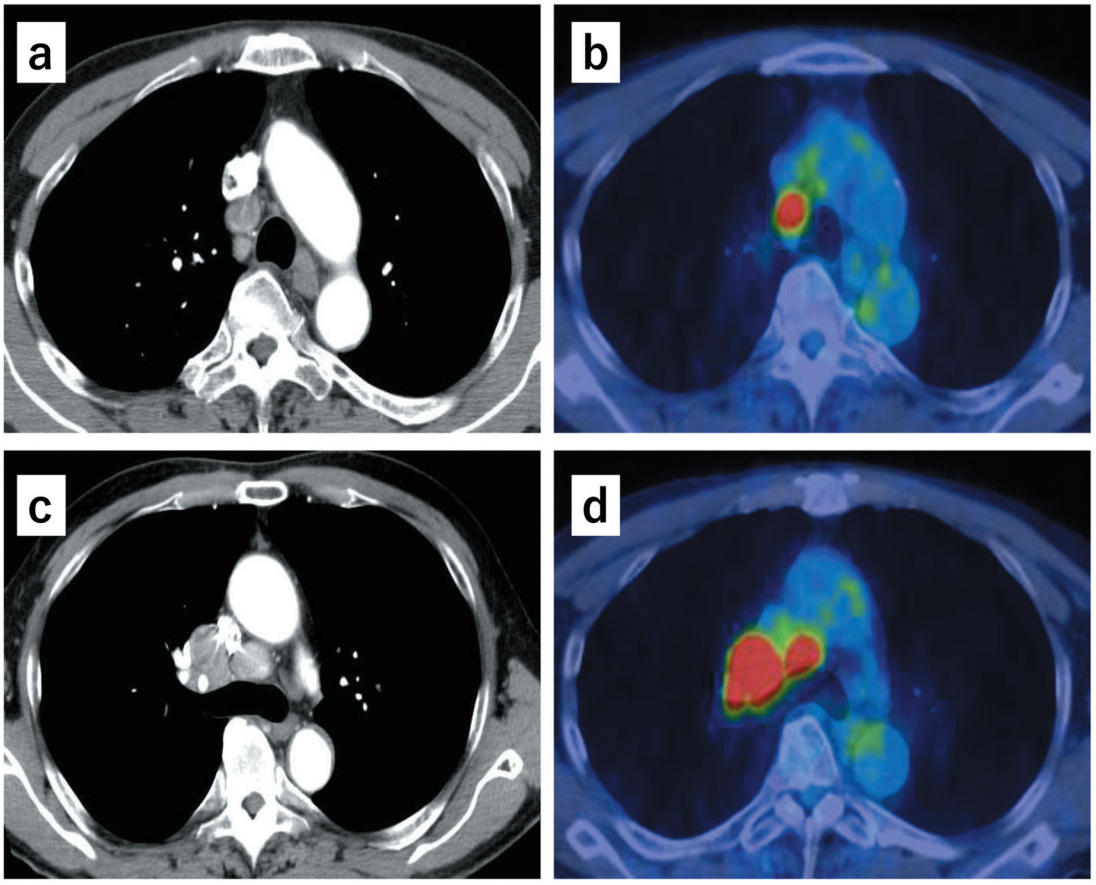

Figure 1. *Radiological images of the lymph nodes (LNs) of case 24. Enhanced chest computed tomography (CT) showed enlargement of the LNs (a: 4R, c: 10R). The maximum diameter of the LNs was 2.2 and 2.8 cm, respectively. The LNs (b: 4R, d: 10R) showed strong 18F-deoxyglucose uptake on positron emission tomography-CT. The #4R LN was pathologically diagnosed as metastasis-negative by endobronchial ultrasound-guided transbronchial needle aspiration.*

assessment was performed for the mediastinal LNs that were suspicious for metastasis by radiological examination and all resected LNs were pathologically evaluated for the presence of metastasis. In this study, we performed an additional pathological evaluation of all resected LNs of the stations that were pathologically diagnosed by EBUS-TBNA in order to assess the presence of fibrosis/necrosis as well as metastasis. Furthermore, we randomly reviewed the resected LNs within the radiation field of an additional cohort of five cN0 patients (non-metastatic LNs) who received induction CRT because of a superior sulcus tumor or chest wall invasion (7).

Results

Patient characteristics and accuracy of EBUS-TBNA. The patients' characteristics are shown in Table I. Median duration from the initiation of CRT to surgery was 11.0 weeks (range=9.9-18.3 weeks). Among them, 23 patients were confirmed as positive for mediastinal LN metastasis by EBUS-TBNA, while one patient (Case 24) was negative for metastasis before CRT. Although EBUS-TBNA failed to

Table I. *Patient characteristics*.

Characteristics	Total (n=24)
Median age (range)	66 (46-77)
Gender, n (%)	
Male	19 (79)
Female	5 (21)
Histological subtype, n (%)	
Adenocarcinoma	11 (46)
Squamous cell carcinoma	12 (50)
Large cell carcinoma	1 (4)
Clinical stage, n (%)	
IIIA	15 (63)
IIIB	9 (37)
Pathological N factor, n (%)	
N0	12 (50)
N1	1 (4)
N2	10 (42)
N3	1(4)
Induction chemotherapy, n (%)	
Paclitaxel plus Carboplatin	3 (13)
Docetaxel plus Cisplatin	20 (83)
S-1	1 (4)

Case No.	LN station	EBUS-TBNA	Resected LNs
Case 1	4R		
Case 2	7		
Case 3	7		
Case 4	7		
Case 5	4R		
Case 6	4R		
Case 7	7		
Case 8	7		
Case 9	4R		
Case 10	4R		
Case 11	4R		
Case 12	4L		
Case 13	4L		
Case 14	4R		
	7		
Case 15	4R		
Case 16	7		
Case 17	7		
Case 18	7		
Case 19	4R		
Case 20	7		
Case 21	4R		
Case 22	4R		
Case 23	4R		
Case 24	4R	no malignancy	

Viable cells Fibrosis and/or necrosis Viable cells with fibrosis and/or necrosis

Figure 2. *Comparison of histological features before and after induction chemoradiotherapy. We histologically reviewed 25 LN stations evaluated by EBUS-TBNA from 24 enrolled patients. Fibrosis and/or necrosis were present in all 25 LN stations. In addition, residual viable cancer cells were also observed along with fibrosis and/or necrosis in 11 stations of 11 patients. LN: Lymph node; EBUS-TBNA: endobronchial ultrasound-guided transbronchial needle aspiration.*

demonstrate mediastinal LN metastasis in this patient, induction CRT was introduced because LN metastasis was strongly suspected by radiological examinations (Figures 1 and 2).

Among the cases where sufficient materials were obtained by EBUS-TBNA, the accuracy of EBUS-TBNA was 96% (24 of the 25 aspirated LNs) in this study (Figure 2).

Histological findings in the resected LNs treated by induction CRT. Among 24 patients enrolled in this study, we histologically reviewed 25 LN stations (a total of 117 resected LNs) evaluated by EBUS-TBNA (median number of evaluated LNs per patient: 4, range=2-16). Representative examples of histological features of resected LNs with metastasis before iCRT are present in Figure 3. Fibrosis and/or necrosis were present in all 25 LN stations evaluated by EBUS-TBNA in all 24 patients. In addition, residual viable cancer cells were also observed along with fibrosis and/or necrosis in 11 LN stations of 11 patients. In case 24, viable cells with fibrosis and/or necrosis were identified by pathological assessment, although the preoperative evaluation by EBUS-TBNA did not show malignancy (Figure 2).

In a total of 15 LN stations (34 resected LNs) from the five cN0 patients treated by induction CRT, all LNs

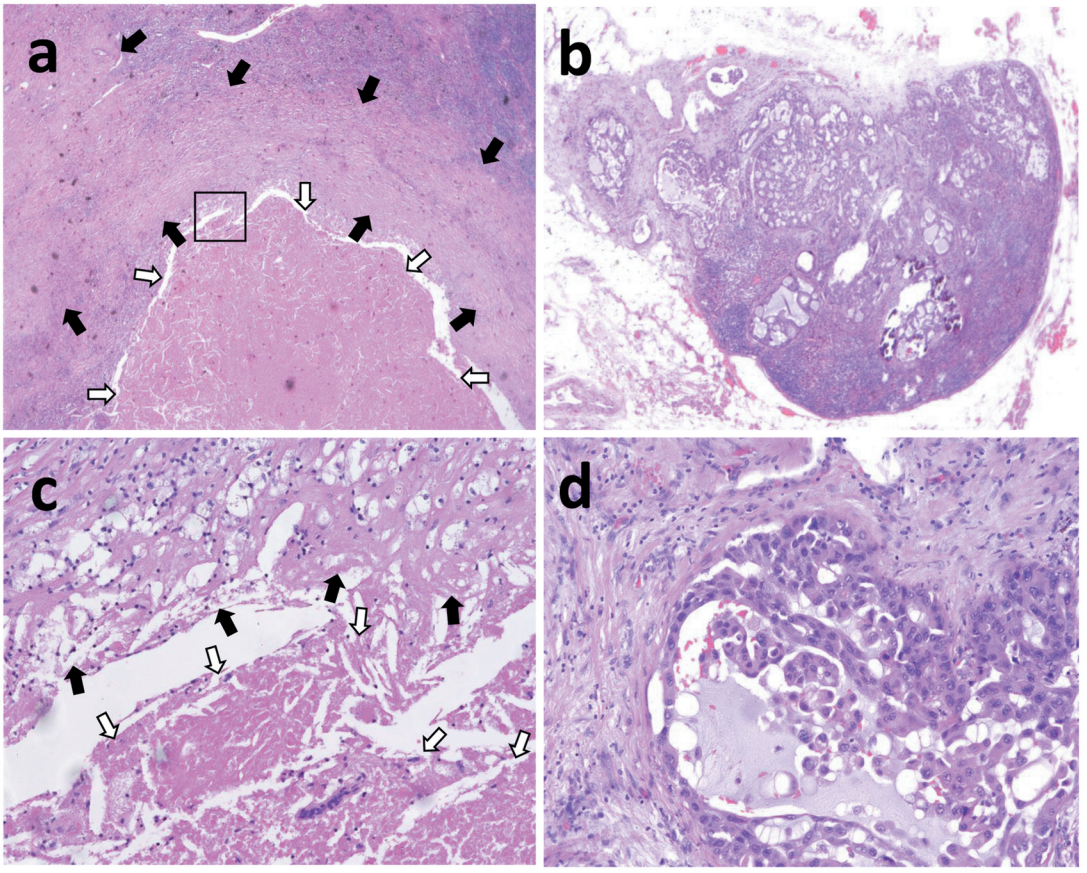

Figure 3. *Representative examples of histological features of resected lymph nodes (LNs) with metastasis before induction chemoradiotherapy. (a and b) LN with fibrosis and necrosis. The black and white arrows show fibrosis and necrosis, respectively. (c and d) LN with both viable cancer cells and fibrosis. (a) Fibrosis and/or necrosis suggest the presence of metastasis before induction chemoradiotherapy (original magnification: ×20). The square region is magnified in (b). (b) Magnified image of the fibrotic and necrotic area (original magnification: ×200). (c) Residual viable cancer cells and fibrotic areas are observed in the resected lymph node (original magnification: ×20). The square region is magnified in (d). (d) Residual viable cancer cells are surrounded by fibrotic tissue (original magnification: ×200).*

maintained the feature of normal LNs, without fibrosis and/or necrosis (Figure 4), indicating that CRT does not induce histological changes in non-metastatic LNs relatively early after initiation of CRT (median period from initiation of CRT to surgery: 10.8 months, range=9.1-22.0 months).

Discussion

LN metastasis is known to be a poor prognostic factor in NSCLC patients. Although the histopathological evaluation of primary tumors treated by CRT has been well known, that for LNs with or without metastasis has not been documented yet. In this study, we found that fibrosis and/or necrosis were present in all LNs of the stations of 24 patients who were confirmed as positive for LN metastasis before CRT. This result suggests that presence of fibrosis and/or necrosis in the LN is a signature of lymph node metastasis before CRT.

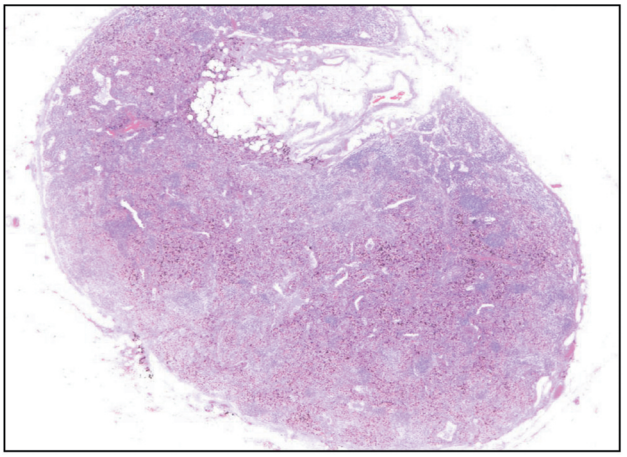

Figure 4. *Representative example of histological features of a resected lymph node (LN) without metastasis (cN0) before induction chemoradiotherapy. The LN was filled with normal lymph nodules, with neither fibrosis nor necrosis. Original magnification: ×20.*

Beppu *et al*. demonstrated that metastasis-negative LNs were histologically distinguishable from total regression LNs (metastasis-positive LNs before treatment), because metastasis-negative LNs with rectal cancer were filled with normal lymph nodules (8). Similarly, our current study revealed that the normal LN structure was maintained, with neither fibrosis nor necrosis, in resected LNs that were diagnosed as having no metastasis before CRT. Since pathological downstaging of mediastinal LN metastasis after induction therapy is known to be a favorable prognostic indicator (4), the regression grade of individual LNs might be useful in predicting prognosis. This fact suggests that pathological findings of resected LNs are a useful clue to accurately determine the clinical stage, and contribute to the prediction of the clinical outcomes of NSCLC patients treated by CRT.

In conclusion, we demonstrated that the presence of characteristic histological features of fibrosis and/or necrosis in resected LNs indicate the presence of LN metastasis before CRT, while CRT did not affect the histological features of non-metastatic LNs.

Conflicts of Interest

The Authors declared no potential conflicts of interest with respect to the research, authorship, and/or publication of this article.

Authors' Contributions

Y.T., J.S., and S.T. contributed to the design and implementation of the research, and to the analysis of the results. Y.T. and J.S. contributed to the writing of the draft. Hiroyuki. Y. carried out the pathological review. All Authors contributed to the writing of the final manuscript.

Acknowledgements

The Authors would like to thank Drs. Eisuke Kurihara, Yusuke Ogoshi, Kei Namba, Takahiro Yoshioka, Hidejiro Torigoe, and Hiroki Sato (Department of General Thoracic Surgery and Breast and Endocrinological Surgery, Okayama University Graduate School of Medicine, Dentistry, and Pharmaceutical Sciences) for collection data from medical records.

References

1 Toyooka S, Kiura K, Takemoto M, Oto T, Takigawa N, Fujiwara T, Miyoshi S and Date H: Long-term outcome of induction chemoradiotherapy with docetaxel and cisplatin followed by surgery for non-small-cell lung cancer with mediastinal lymph node metastasis. Interact Cardiovasc Thorac Surg *14(5)*: 565-569, 2012. PMID: 22354091. DOI: 10.1093/icvts/ivs028

2 Junker K, Thomas M, Schulmann K, Klinke F, Bosse U and Müller KM: Tumour regression in non-small-cell lung cancer following neoadjuvant therapy. Histological assessment. J Cancer Res Clin Oncol *123(9)*: 469-477, 1997. PMID: 9341895. DOI: 10.1007/bf01192200

3 Yamane Y, Ishii G, Goto K, Kojima M, Nakao M, Shimada Y, Nishiwaki Y, Nagai K, Kohrogi H and Ochiai A: A novel histopathological evaluation method predicting the outcome of non-small cell lung cancer treated by neoadjuvant therapy: The prognostic importance of the area of residual tumor. J Thorac Oncol *5(1)*: 49-55, 2010. PMID: 20035185. DOI: 10.1097/JTO.0b013e3181c0a1f8

4 Toyooka S, Kiura K, Shien K, Katsui K, Hotta K, Kanazawa S, Date H and Miyoshi S: Induction chemoradiotherapy is superior to induction chemotherapy for the survival of non-small-cell lung cancer patients with pathological mediastinal lymph node metastasis. Interact Cardiovasc Thorac Surg *15(6)*: 954-960, 2012. PMID: 22976995. DOI: 10.1093/icvts/ivs412

5 Goldstraw P, Chansky K, Crowley J, Rami-Porta R, Asamura H, Eberhardt WE, Nicholson AG, Groome P, Mitchell A and Bolejack V: The iaslc lung cancer staging project: Proposals for revision of the tnm stage groupings in the forthcoming (eighth) edition of the tnm classification for lung cancer. J Thorac Oncol *11(1)*: 39-51, 2016. PMID: 26762738. DOI: 10.1016/j.jtho.2015.09.009

6 Katakami N, Tada H, Mitsudomi T, Kudoh S, Senba H, Matsui K, Saka H, Kurata T, Nishimura Y and Fukuoka M: A phase 3 study of induction treatment with concurrent chemoradiotherapy versus chemotherapy before surgery in patients with pathologically confirmed n2 stage iiia nonsmall cell lung cancer (wjtog9903). Cancer *118(24)*: 6126-6135, 2012. PMID: 22674529. DOI: 10.1002/cncr.26689

7 Shien K, Toyooka S, Kiura K, Matsuo K, Soh J, Yamane M, Oto T, Takemoto M, Date H and Miyoshi S: Induction chemoradiotherapy followed by surgical resection for clinical t3 or t4 locally advanced non-small cell lung cancer. Ann Surg Oncol *19(8)*: 2685-2692, 2012. PMID: 22396006. DOI: 10.1245/s10434-012-2302-x

8 Beppu N, Kobayashi M, Matsubara N, Noda M, Yamano T, Doi H, Kamikonya N, Kakuno A, Kimura F, Yamanaka N, Yanagi H and Tomita N: Comparison of the pathological response of the mesorectal positive nodes between short-course chemoradiotherapy with delayed surgery and long-course chemoradiotherapy in patients with rectal cancer. Int J Colorectal Dis *30(10)*: 1339-1347, 2015. PMID: 26206348. DOI: 10.1007/s00384-015-2321-8

Received June 1, 2020
Revised June 24, 2020
Accepted June 25, 2020