ANTICANCER RESEARCH *40*: 7127-7134 (2020)
doi:10.21873/anticanres.14742

Stage III and Metastatic Lymph Node Ratio Are the only Independent Prognostic Factors in Colorectal Signet-ring Cell Carcinoma Patients

ALFREDO ANNICCHIARICO[1], ANDREA MORINI[1], ANDREA ROMBOLI[1], MATTEO RICCÒ[2], FRANCESCO LEONARDI[3], PELLEGRINO CRAFA[1,4], EDOARDO VIRGILIO[1,5], PAOLO DELL'ABATE[1,6] and RENATO COSTI[1,5]

[1]*Department of Medicine and Surgery, University of Parma, Parma, Italy;*
[2]*Department of Public Health, Local Health Authority of Reggio Emilia, Reggio Emilia, Italy;*
[3]*Department of Oncology, University Hospital of Parma, Parma, Italy;*
[4]*Department of Pathological Anatomy, University Hospital of Parma, Parma, Italy;*
[5]*Department of General Surgery, Vaio Hospital, Fidenza, Italy;*
[6]*Department of General Surgery, University Hospital of Parma, Parma, Italy*

Abstract. *Background/Aim: Signet-ring cell carcinoma (SRCC) is an uncommon histological variant of colorectal cancer (CRC). Knowledge is scarce due to its rarity. Our aim was to better evaluate the clinicopathologic and prognostic features of this little-known malignancy. Patients and Methods: Thirty-nine consecutive patients with non-metastatic colorectal SRCC undergoing curative resection at University Hospital of Parma between 2000 and 2018 were examined in this retrospective analysis. Results: Mean overall (OS) and disease-free survival (DFS) were 33.6 and 31.5 months, respectively. At univariate analysis, the lymph-related parameters (nodal status, Stage III, metastatic lymph node ratio and lymphovascular invasion) were significantly associated with shorter OS and poorer DFS. At multivariate analysis, Stage III and a metastatic lymph node ratio ≥25% were found to be the only independent prognostic factors significantly correlated with worse OS and DFS. Conclusion: Nodal and lymphatic status should be carefully pondered when planning the most appropriate management of patients with colorectal SRCC.*

Colorectal cancer (CRC) is the second and third most common malignancy in women and men with an increasing incidence under the age of 40 and 50 years, respectively (1-3). Differently from mucinous CRC where mucin occupies more than 50% of the extracellular space, signet-ring cell carcinoma (SRCC) characteristically shows intracellular mucin accumulation and peripheral arrangement of the nuclei in more than 50% of tumor cells (4-8). SRCCs have been frequently described in the gastrointestinal tract (especially stomach) but also in the breast, lung, gallbladder, pancreas, ovary, cervix, urinary system and salivary glands (5, 9). The large bowel represents a further, rare site of occurrence. First described in the colon by Laufman and Saphir in 1951, SRCC has been reported to have an incidence of 0.3-4.6% among all subtypes of CRCs, with slight differences between Western countries, Asia and Africa (10-17). A recent review by Tajiri et al. highlighted the clinicopathological and genetic features of SRCC, confirming the general belief that this histological subtype is related to a worse prognosis (18); however, despite this, nowadays little is known about the factors impacting the survival of patients. In fact, the relative literature is scarce, heterogeneous and hampered by small numbers (6, 19-24). The aim of our study was to assess poor outcome's predictors of this uncommon colorectal malignancy.

Patients and Methods

From a database of 2,945 CRC patients undergoing potentially curative resection between 2000 and 2018 at the University Hospital of Parma, Italy, we retrieved the clinical records of 39 consecutive SRCCs (1.32%). CRC clinical and pathological staging were assessed with contrast-enhanced full body computed tomography scan and according to the 8th edition of the American Joint Committee on Cancer (AJCC), respectively. Pelvic magnetic resonance imaging and/or endorectal ultrasound were also used in case of rectal cancer (RC). Metastatic lesions were excluded. The

Correspondence to: Dr. Alfredo Annicchiarico (ORCID ID: 0000-0003-3882-776X), Department of Medicine and Surgery, University of Parma, via Gramsci 14, 43126, Parma, Italy. Tel: +39 3922307577, e-mail: alfredoannicchiarico90@gmail.com

Key Words: Colorectal cancer, signet-ring cell carcinoma, survival.

Table I. *Clinicopathological of the 39 patients with signet-ring cell colorectal cancer.*

Patient	Gender	Age in years	Localization*	T**	N**	TNM Stage**	Positive nodes/ Total nodes	LNR	LVI	PNI	Budding grade°	Signet-ring cells percentage°°
1	F	85	Right Colon	4	1	3	1/19	0.05	–	–	Low	Group A
2	M	71	Right Colon	3	2	3	10/32	0.31	–	–	Low	Group B
3	F	82	Rectum	3	2	3	6/7	0.8	+	–	Low	Group B
4	F	75	Right Colon	3	2	3	4/20	0.2	–	–	Low	Group B
5	F	59	Right Colon	4	2	3	19/37	0.51	+	–	Low	Group B
6	F	92	Right Colon	3	2	3	28/30	0.93	+	–	Low	Group B
7	F	42	Right Colon	4	2	3	13/26	0.5	+	–	Low	Group A
8	M	36	Right Colon	4	2	3	15/37	0.4	–	–	Low	Group B
9	F	84	Right Colon	4	2	3	30/58	0.5	+	–	Low	Group B
10	F	61	Left Colon	4	2	3	9/13	0.69	+	+	High	Group B
11	F	81	Right Colon	3	1	3	2/15	0.13	–	–	Low	Group B
12	F	76	Right Colon	3	0	2	0/11	0	–	–	Low	Group B
13	F	85	Right Colon	3	2	3	7/20	0.35	+	–	Low	Group B
14	M	84	Right Colon	3	1	3	3/16	0.19	+	–	High	Group A
15	F	35	Left Colon	4	2	3	16/16	1	+	–	Low	Group B
16	M	88	Right Colon	4	1	3	3/19	0.15	+	–	Low	Group B
17	M	75	Right Colon	4	0	2	0/17	0	–	–	Low	Group B
18	F	84	Right Colon	4	2	3	37/40	0.9	+	–	Low	Group B
19	M	73	Right Colon	3	2	3	6/42	0.14	–	–	Low	Group B
20	F	47	Right Colon	3	2	3	6/25	0.24	–	–	Low	Group B
21	F	56	Rectum	2	0	1	0/23	0	+	–	High	Group B
22	M	62	Left Colon	3	2	3	13/18	0.72	–	–	Low	Group B
23	M	66	Left Colon	3	0	2	0/13	0	+	–	Low	Group B
24	M	74	Left Colon	3	1	3	1/20	0.05	+	+	Low	Group A
25	F	77	Right Colon	3	0	2	0/22	0	+	–	Low	Group B
26	F	80	Right Colon	4	0	2	0/14	0	–	–	Low	Group B
27	F	75	Right Colon	2	0	1	0/17	0	–	–	Low	Group A
28	F	74	Right Colon	2	0	1	0/18	0	–	–	Low	Group B
29	M	54	Rectum	3	0	2	0/6	0	–	–	Low	Group B
30	F	80	Right Colon	2	0	1	0/16	0	–	–	Low	Group B
31	F	67	Right Colon	2	0	1	0/12	0	–	–	Low	Group B
32	M	83	Right Colon	3	0	2	0/16	0	–	–	Low	Group B
33	M	63	Left Colon	3	0	2	0/16	0	–	–	Low	Group B
34	F	76	Right Colon	1	0	1	0/26	0	+	–	Low	Group B
35	M	49	Left Colon	4	0	2	0/7	0	–	–	Low	Group B
36	F	59	Right Colon	3	1	3	1/71	0.01	+	–	Low	Group B
37	F	69	Rectum	2	1	3	1/13	0.23	–	–	Low	Group B
38	M	67	Right Colon	4	2	3	9/15	0.6	+	–	Low	Group B
39	F	80	Right Colon	4	2	3	37/40	0.92	+	–	Low	Group B

F: Female; M: male; LNR: metastatic lymph node ratio; LVI: lymphovascular invasion; PnI: perineural invasion: +=Present; –=Absent; *Right Colon location includes tumors from the cecum to the splenic flexure; **According to the 8th edition of the American Joint Committee on Cancer; °According to Ueno (26); °°Signet-ring cell percentage: Group A (51-70% of signet-ring cells); Group B (>70% of signet-ring cells).

clinicopathologic characteristics mainly investigated were: sex, age, tumor location, lymph node (N) status, TNM Stage, lymph node ratio (LNR), budding grade, signet-ring cell percentage, lymphovascular (LVI) and perineural invasion (PnI). LNR and budding grade were evaluated as formerly described (<25% *vs*. ≥25% and low *vs*. high grade, respectively) (25-27). All patients were offered adjuvant chemotherapy, tailored on an individual basis; all RCs also received neoadjuvant chemoradiation. Follow-up was evaluated in terms of overall (OS) and disease-free survival (DFS). Concerning the cut-off value of Signet-Ring Cells (SRC) percentage, since this is a new, unpublished histopathologic parameter, based on a semi-quantitative evaluation we classified SRCs into two groups: group A (presenting from 51 to 70% of SRCs), and group B (≥71% of SRCs). Survival of subclasses was also studied.

Statistics. Categorical, ordinal and continuous variables were compared using the Chi-square, Kruskal–Wallis and Student's *t*-test, respectively. Univariate analysis of survival was performed through Kaplan–Meier statistics (Tarone-Ware test for confrontations). Criteria independently related with poor prognosis having *p*-value <0.05 were eventually included in a multivariate Cox regression

Table II. *Sites of metastases from signet-ring cell carcinomas (SRCCs).*

Site	Metastatic SRCC patients (number and percentage)	T*			N*			LVI		Signet-ring cell percentage°	
		T2	T3	T4	N0	N1	N2	LVI–	LVI+	Group A	Group B
Peritoneum	9 (23.1%)	1	4	4	1	2	6	5	4	-	9
Liver	4 (10.3%)	-	2	2	-	-	4	1	3	-	4
Lung	2 (5.1%)	-	2	-	1	1	-	-	2	1	1
Brain	1 (2.6%)	-	-	1	-	1	-	1	-	1	-
Bone	1 (2.6%)	-	-	1	-	-	1	1	-	-	1
Total	17 (43.6%)	1	8	8	2	4	11	8	9	2	15

LVI: Lymphovascular invasion; +=present; –=absent; *According to the 8th edition of the American Joint Committee on Cancer; °Signet-ring cell percentage: Group A (51-70% of signet-ring cells); Group B (>70% of signet-ring cells).

model with calculation of correspondent hazard ratio (HR) and 95% confidence interval (95%CI). More precisely, for multivariate analysis, in order to avoid the potential effect of collinearity of variables dealing with the status of lymph nodes and lymphatic vessels (N, Staging, LNR and LVI), three distinctive models were individually assessed: a) Stage III *vs*. I-II; b) LNR>0 *vs*. 0, LNR <25% *vs*. 0 and LNR ≥25% *vs*. 0; c) N2 *vs*. N1.

Results

Table I shows the clinicopathological data of the examined population. Among the 39 analyzed patients, there were 14 men (35.9%) and 25 women (64.1%) with a mean age of 69.9 years (SD: ±14.4). In 28 patients the tumor was in the right colon (71.8%), in 7 in the left colon (17.9%) and in 4 in the rectum (10.3%). All SRCCs were free of metastasis (M0). Six patients presented with Stage I (15.4%), 9 with Stage II (23.1%) and 24 with Stage III cancers (61.5%). At pathology, 15 patients did not have lymph node involvement (N0, 38.5%), while 24 subjects presented nodal metastasis (N+, 61.5%). Of these, 7 were N1 (17.9%), while 17 were N2 (43.6%). Excluding N0 cases, mean LNR was 27% (SD: ±32.7); applying a 25% cut-off, 10 patients had LNR<25% (25.6%) whereas 14 (35.9%) had LNR≥25%. All SRCCs showed poor differentiation (G3). Tumor budding was high-grade in 3 (7.7%) and low-grade in 36 (96.3%) patients. Considering the SRCs percentage, 5 patients (12.8%) were classified in group A and 34 (87.2%) in B. LVI and PnI were observed in 18 (46.2%) and 2 patients (5.1%), respectively. At a mean 3.8-year follow-up, there were 21 alive (53.8%) and 18 dead (46.2%) subjects. Among the alive ones, 17 (43.6%) developed secondary metastases. Most metastases occurred in the peritoneum (9, 23.1%) followed by liver (4, 10.3%), lung (2, 5.1%), brain (1, 2.6%) and bone (1, 2.6%) (Table II). OS and DFS were 33.6 and 31.5 months, respectively. At univariate analysis, involvement of all the lymph-related parameters (N, TNM Stage, LNR and LVI) appeared related to a poor prognosis (Table III). In fact, compared to TNM Stage I and II, Stage III was significantly associated with shorter OS (40.2 *vs*. 84.6 months; $p<0.001$) and DFS (30.6 *vs*. 85.8 months; $p<0.001$) (Figure 1 and Figure 2, respectively; Table III). The presence of LVI was also associated with a worse OS (27.8 *vs*. 79.9 months; $p=0.007$) and DFS (26.9 *vs*. 68.9 months; $p=0.022$) (Table III). Multivariate analysis is shown in Figure 3. Concerning OS, an increased hazard ratio (HR) was found for tumor Stage III *vs*. I-II (HR=7.227, 95%CI=1.618-32.278), and LNR ≥25 *vs*. 0 (HR=13.227, 95%CI=2.493-70.182), indicating a significantly independent higher risk of death in such subjects. Regarding DFS, an increased HR was found in subjects with Stage III *vs*. I+II (HR=8.764, 95%CI=1.990-38.601), LNR <25% *vs*. 0 (HR=5.095, 95%CI=1.006-25.794) and LNR ≥25% *vs*. 0 (HR=17.549, 95%CI=3.496-88.091) (Figure 3). No significant HR for OS and DFS was identified in N2- when compared to N1-cases.

Discussion

The incidence of SRCC in our CRC population (1.32%) was similar to the one reported in the world literature (0.3%-4.6%) (10-17) with only one series showing an unusual higher rate (18%) (28). The reported sex prevalence is heterogeneous in the literature (9, 12, 12, 21, 29-31); in our work, the female to male ratio was 25 to 14 (1.8:1). In line with some previous studies, in our cohort, SRCC showed higher incidence among elderly patients (mean age: 69.9 years); on the contrary, other authors demonstrated younger patients (mean age: 39 to 42 years) to be the most affected target-population advocating for a major local aggressiveness and predisposition to peritoneal carcinomatosis (9, 30-36). In our study, the right colon was more frequently involved (28 cases, 71%) in comparison with left colon and rectum (7 and 4 cases, respectively): this is in line with some literature, while other articles found a more frequent left-sided localization (12, 29, 31, 37, 38). In our case, the choice to

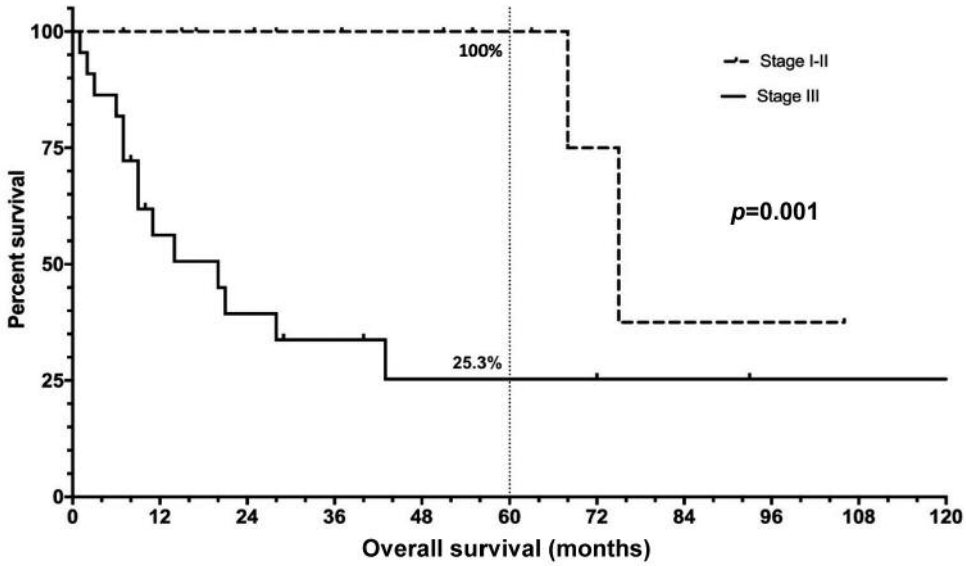

Figure 1. *Kaplan–Meier curves showing differences in overall survival between Stage III and Stage I/II patients with colorectal signet ring cell carcinoma.*

Table III. *Univariate analysis of clinicopathological parameters on overall and disease free-survival.*

Parameter		OS in months Mean (95%CI)	*p*-Value	DFS in months Mean (95%CI)	*p*-Value
Gender	Male	69.5 (35.2-103.8)	0.230	63.0 (30.4-95.5)	0.289
	Female	50.4 (30.4-70.3)		47.2 (41.1-99.4)	
Age in years	<50	35.7 (9.0-62.5)	0.687	35.2 (3.9-66.5)	0.865
	50-65	43.2 (25.6-57.8)		32.4 (14.4-50.4)	
	>65	62.5 (39.5-85.5)		62.1 (39.4-84.6)	
Localization*	Right colon	54.5 (32.7-76.2)	0.591	50.4 (30.4-70.5)	0.717
	Left colon	43.6 (28.2-59.1)		38.0 (21.7-54.3)	
	Rectum	71.4 (31.2-111.6)		71.4 (31.2-111.6)	
Stage**	I-II	84.6 (65.7-103.4)	**<0.001**	85.8 (66.3-105.3)	**<0.001**
	III	40.2 (18.0-62.4)		30.6 (12.0-49.2)	
N**	N0	84.6 (65.7-103.4)	**0.001**	85.8 (66.4-105.3)	**<0.001**
	N1	42.0 (11.0-73.0)	0.319	41.6 (8.1-75.1)	0.341
	N2	34.9 (10.1-59.8)		23.1 (5.6-40.7)	
LNR	N0	84.6 (65.7-103.4)	**<0.001**	85.8 (77.3-106.5)	<0.001
	LNR<25%	64.8 (26.9-102.7)	0.125	55.0 (20.3-89.6)	0.140
	LNR≥25%	16.0 (7.1-24.9)		11.0 (6.1-15.9)	
LVI	Yes	27.8 (12.2-43.3)	**0.007**	26.9 (10.7-43.1)	**0.022**
	No	79.9 (55.7-104.2)		68.9 (46.5-91.2)	
Budding grade°	High	13.1 (8.2-17.9)	0.864	9.1 (6.5-11.6)	0.844
	Low	63.4 (43.0-84.0)		56.3 (37.6-75.0)	
Signet-ring cell percentage°°	Group A	22.9 (6.9-34.8)	0.353	21.9 (7.6-36.2)	0.583
	Group B	66.4 (45.0-87.7)		58.5 (38.9-77.8)	

OS: Overall survival; DFS: disease-free survival; CI: confidence interval; LNR: lymph node ratio; LVI: lymphovascular invasion; *Right Colon includes tumors from the cecum to the splenic flexure; **According to the 8th edition of the American Joint Committee on Cancer; °According to Ueno (26); °°Signet-ring cell percentage: Group A (51-70% of signet-ring cells); Group B (>70% of signet-ring cells). Statistically significant *p*-values are written in bold type.

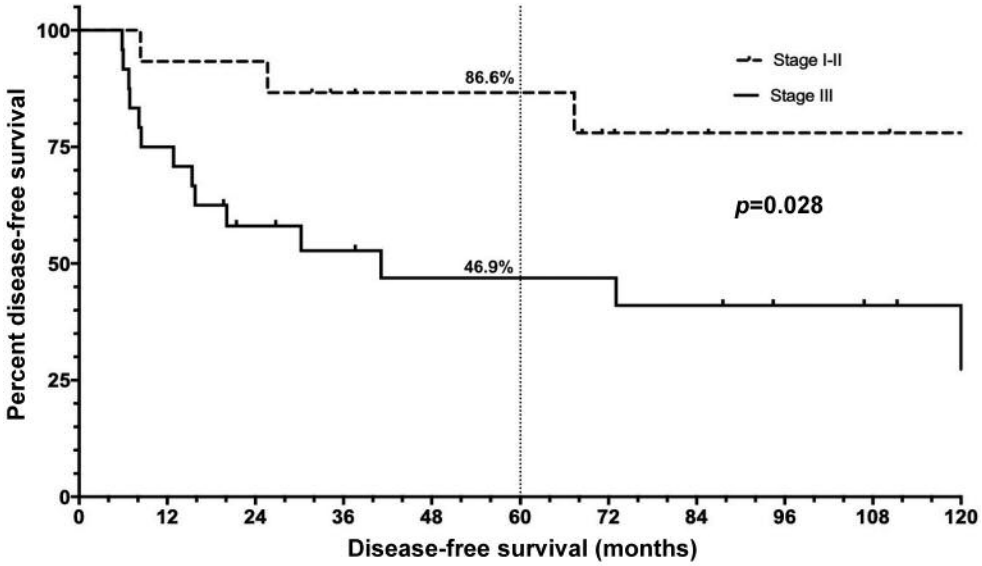

Figure 2. *The Kaplan–Meier method showed statistically significant differences in disease-free survival between Stage III and Stage I/II patients with colorectal signet ring cell carcinoma.*

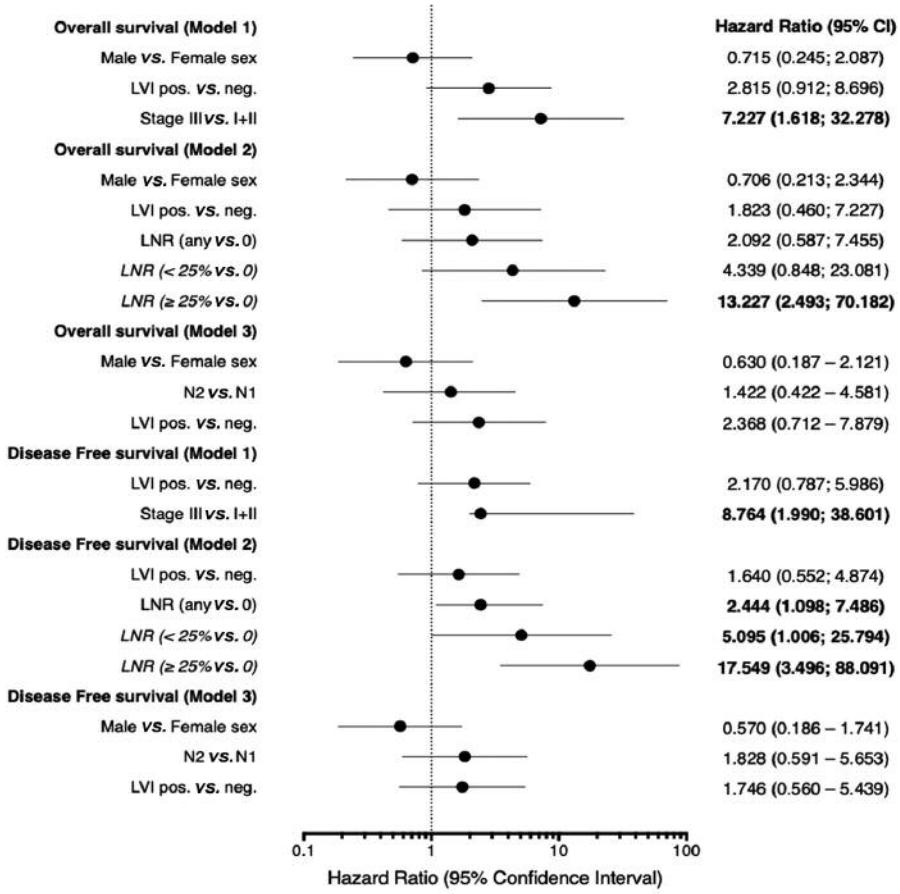

Figure 3. *Multivariate analysis showing independency among prognostic factors of overall and disease-free survival. Statistically significant values (p<0.05) are written in bold type and are located at the right side of Hazard Ratio column.*

consider lesions of the entire transverse colon as right-sided tumors may have been the determinant factor. Compared to non-SRCCs, SRCCs were found to have worse behavior and poorer prognosis with a 33.6-month OS and 31.5-month DFS. These data are consistent with the literature where SRCC is considered a predictor of poor outcome (19, 20). Actually, analysis of the clinicopathological and survival data of our patient population demonstrated an important local aggressiveness since all SRCCs showed poor differentiation (G3), frequent nodal metastases (Stage III: 24 of 39 patients, 61.5%), LVI (50%) and predisposition to develop peritoneal metastases (9 of 39 subjects) (Tables I and II). Moreover, the 18 SRCC patients belonging to Group B (those with a percentage of SRCs exceeding 70%) also showed a high-grade tumor budding. The impact of nodal and lymphatic metastasis on prognosis of our patients appears worth noting. At univariate analysis, in fact, lymph-related parameters (N, Stage, LNR and LVI) were significantly associated with poorer OS (p=0.001, <0.001, <0.001 and 0.007, respectively) and DFS (p<0.001, <0.001, 0.001 and 0.022, respectively) showing a difference of approximately 40 months of life expectancy (Table III, Figures 1 and 2). Furthermore, at multivariate analysis, such lymph-related parameters were found to be the only independent prognostic factors (Figure 3). More precisely, Stage III and LNR≥25% were statistically significant independent prognostic factors predictive of poor OS whereas Stage III and the entire LNR classification (that is LNR>0, LNR <25% and LNR≥25%) appeared independently associated with worse DFS (Figure 3). The comparison between N1 and N2 group did not show any significant difference in prognosis probably due to the small number of patients. Our results on SRCCs prognosis are in agreement with the previously reported studies (12, 19, 35, 37-39). Some authors have hypothesized the loss of E-cadherin expression and activation of Wingless-related integration site cascade as the leading molecular culprits for the described local tumor severity with development accompanied with nodal metastasis and peritoneal recurrences (27, 40). Further analyses (including multi-center trials) on larger populations are needed for corroborating our interesting findings on this rare colorectal malignancy.

Conclusion

SRCC is a rare form of CRC. Prognosis of affected patients appears dismal with a mean OS of less than 3 years after surgery. In our study, the lymph-related parameters (N, TNM Stage and LNR) were found to be the only independently related to worse survival (both OS and DFS). As for SRCC, the impact of nodal and lymphatic status on prognosis should be carefully pondered when planning the most appropriate treatment and follow up.

Conflicts of Interest

The Authors declare no conflicts of interest in relation to this study.

Authors' Contributions

All the Authors agreed with the content of the article. Dr. Annicchiarico and Dr. Costi conceived the research. Dr. Annicchiarico and Dr. Virgilio wrote the manuscript. Dr. Morini and Dr. Romboli reviewed the literature. Dr. Crafa performed histology. Dr. Leonardo provided the survival data. Dr. Riccò and Dr. Virgilio conducted statistics. Dr. Dell'Abate and Dr. Costi supervised the project.

References

1 AIOM: I numeri del Cancro in Italia 2019 by AIOM, 2020. Available at: https://www.aiom.it/wp-content/uploads/2019/09/2019_Numeri_Cancro-operatori-web.pdf. [Last accessed October 20, 2020]

2 Bray F, Ferlay J, Soerjomataram I, Siegel RL, Torre LA and Jemal A: Global cancer statistics 2018: GLOBOCAN estimates of incidence and mortality worldwide for 36 cancers in 185 countries. CA Cancer J Clin *68*: 394-424, 2018. PMID: 30207593. DOI: 10.3322/caac.21492

3 Vuik FE, Nieuwenburg SA, Bardou M, Lansdorp-Vogelaar I, Dinis-Ribeiro M, Bento MJ, Zadnik V, Pellisé M, Esteban L, Kaminski MF, Suchanek S, Ngo O, Majek O, Leja M, Kuipers EJ and Spaander MC: Increasing incidence of colorectal cancer in young adults in Europe over the last 25 years. Gut *68*: 1820-1826, 2019. PMID: 31097539. DOI: 10.1136/gutjnl-2018-317592

4 De Angelis R, Sant M, Coleman MP, Francisci S, Baili P, Pierannunzio D, Trama A, Visser O, Brenner H, Ardanaz E, Bielska-Lasota M, Engholm G, Nennecke A, Siesling S, Berrino F, Capocaccia R and EUROCARE-5 Working Group: Cancer survival in Europe 1999-2007 by country and age: results of EUROCARE--5-a population-based study. Lancet Oncol *15*: 23-34, 2014. PMID: 24314615. DOI: 10.1016/S1470-2045(13)70546-1

5 Parham D: Colloid carcinoma. Ann Surg *77*: 90-105, 1923. PMID: 17864773.

6 Hyngstrom JR, Hu CY, Xing Y, You YN, Feig BW, Skibber JM, Rodriguez-Bigas MA, Cormier JN and Chang GJ: Clinicopathology and outcomes for mucinous and signet ring colorectal adenocarcinoma: analysis from the National Cancer Data Base. Ann Surg Oncol *19*: 2814-2821, 2012. PMID: 22476818. DOI: 10.1245/s10434-012-2321-7

7 Korphaisarn K, Morris V, Davis JS, Overman MJ, Fogelman DR, Kee BK, Dasari A, Raghav KP, Shureiqi I, Trupti M, Wolff RA, Eng C, Menter DG, Hamilton S and Kopetz S: Signet ring cell colorectal cancer: genomic insights into a rare subpopulation of colorectal adenocarcinoma. Br J Cancer *121*: 505-510, 2019. PMID: 31406299. DOI: 10.1038/s41416-019-0548-9

8 Hamilton SR and Aaltonen LA: Carcinoma of the colon and rectum. *In*: WHO Pathology and Genetics of the Tumors of the Digestive System. IARC Press Lyon 2000, pp. 109-110, 2000.

9 Tung SY, Wu CS and Chen PC: Primary signet ring cell carcinoma of colorectum: an age- and sex-matched controlled study. Am J Gastroenterol *91*: 2195-2199, 1996. PMID: 8855747.

10 Laufman H and Saphir O: Primary linitis plastica type of carcinoma of the colon. AMA Arch Surg *62*: 79-91, 1951. PMID: 14789350. DOI: 10.1001/archsurg.1951.01250030082009

11 Nitsche U, Zimmermann A, Späth C, Müller T, Maak M, Schuster T, Slotta-Huspenina J, Käser SA, Michalski CW, Janssen K-P, Friess H, Rosenberg R and Bader FG: Mucinous and signet-ring cell colorectal cancers differ from classical adenocarcinomas in tumor biology and prognosis. Ann Surg *258*: 775-782, 2013. PMID: 23989057. DOI: 10.1097/SLA.0b013e3182a69f7e

12 Ooi BS, Ho YH, Eu KW and Choen FS: Primary colorectal signet-ring cell carcinoma in Singapore. ANZ J Surg *71*: 703-706, 2001. PMID: 11906382. DOI: 10.1046/j.1445-1433.2001.02269.x

13 Lee WS, Chun HK, Lee WY, Yun SH, Cho YB, Yun H-R, Park S-H and Song SY: Treatment outcomes in patients with signet ring cell carcinoma of the colorectum. Am J Surg *194*: 294-298, 2007. PMID: 17693269. DOI: 10.1016/j.amjsurg.2006.12.041

14 Hartman DJ, Nikiforova MN, Chang DT, Chu E, Bahary N, Brand RE, Zureikat AH, Zeh HJ, Choudry H and Pai RK: Signet ring cell colorectal carcinoma: a distinct subset of mucin-poor microsatellite-stable signet ring cell carcinoma associated with dismal prognosis. Am J Surg Pathol *37*: 969-977, 2013. PMID: 23681075. DOI: 10.1097/PAS.0b013e3182851e2b

15 Hugen N, Verhoeven RH, Lemmens VE, van Aart CJ, Elferink MA, Radema SA, Nagtegaal ID and de Wilt JH: Colorectal signet-ring cell carcinoma: benefit from adjuvant chemotherapy but a poor prognostic factor. Int J Cancer *136*: 333-339, 2015. PMID: 24841868. DOI: 10.1002/ijc.28981

16 Chalya PL, McHembe MD, Mabula JB, Rambau PF, Jaka H, Koy M, Mkongo E and Masalu N: Clinicopathological patterns and challenges of management of colorectal cancer in a resource-limited setting: a Tanzanian experience. World J Surg Oncol *11*: 88, 2013. PMID: 23597032. DOI: 10.1186/1477-7819-11-88

17 Thota R, Fang X and Subbiah S: Clinicopathological features and survival outcomes of primary signet ring cell and mucinous adenocarcinoma of colon: retrospective analysis of VACCR database. J Gastrointest Oncol *5*: 18-24, 2014. PMID: 24490039. DOI: 10.3978/j.issn.2078-6891.2013.051

18 Tajiri K, Sudou T, Fujita F, Hisaka T, Kinugasa T and Akagi Y: Clinicopathological and corresponding genetic features of colorectal signet ring cell carcinoma. Anticancer Res *37*: 3817-3823, 2017. PMID: 28668881. DOI: 10.21873/anticanres.11760.

19 Pozos-Ochoa LI, Lino-Silva LS, Leon-Takahashi AM and Salcedo-Hernandez RA: Prognosis of signet ring cell carcinoma of the colon and rectum and their distinction of mucinous adenocarcinoma with signet ring cells. A comparative study. Pathol Oncol Res *24*: 609-616, 2018. PMID: 28785968. DOI: 10.1007/s12253-017-0283-6

20 Arifi S, Elmesbahi O and Amarti Riffi A: Primary signet ring cell carcinoma of the colon and rectum. Bull Cancer *102*: 880-888, 2015. PMID: 26412710. DOI: 10.1016/j.bulcan.2015.07.005

21 Kang H, O'Connell JB, Maggard MA, Sack J and Ko CY: A 10-year outcomes evaluation of mucinous and signet-ring cell carcinoma of the colon and rectum. Dis Colon Rectum *48*: 1161-1168, 2005. PMID: 15868237. DOI: 10.1007/s10350-004-0932-1

22 Hosseini S, Bananzadeh AM, Salek R, Zare-Bandamiri M, Kermani AT and Mohammadianpanah M: Prognostic significance of mucinous histologic subtype on oncologic outcomes in patients with colorectal cancer. Ann Coloproctol *33*: 57-63, 2017. PMID: 28503517. DOI: 10.3393/ac.2017.33.2.57

23 Verhulst J, Ferdinande L, Demetter P and Ceelen W: Mucinous subtype as prognostic factor in colorectal cancer: a systematic review and meta-analysis. J Clin Pathol *65*: 381-388, 2012. PMID: 22259177. DOI: 10.1136/jclinpath-2011-200340

24 Hogan J, Burke JP, Samaha G, Condon E, Waldron D, Faul P and Calvin Coffey J: Overall survival is improved in mucinous adenocarcinoma of the colon. Int J Colorectal Dis *29*: 563-569, 2014. PMID: 24425620. DOI: 10.1007/s00384-013-1826-2

25 Costi R, Beggi F, Reggiani V, Riccò M, Crafa P, Bersanelli M, Tartamella F, Violi V, Roncoroni L and Sarli L: Lymph node ratio improves TNM and Astler-Coller's assessment of colorectal cancer prognosis: an analysis of 761 node positive cases. J Gastrointest Surg *18*: 1824-1836, 2014. PMID: 25091835. DOI: 10.1007/s11605-014-2591-4

26 Ferri M, Lorenzon L, Rapazzotti Onelli M, La Torre M, Mercantini P, Virgilio E, Balducci G, Ruco L, Ziparo V and Pilozzi E: Lymph node ratio is a stronger prognostic factor than microsatellite instability in colorectal cancer patients: results from a 7 years follow-up study. Int J Surg *11*: 1016-1021, 2013. PMID: 23747976. DOI: 10.1016/j.ijsu.2013.05.031

27 Ueno H, Price AB, Wilkinson KH, Jass JR, Mochizuki H and Talbot IC: A new prognostic staging system for rectal cancer. Ann Surg *240*: 832-839, 2004. PMID: 15492565. DOI: 10.1097/01.sla.0000143243.81014.f2

28 Dajani YF, Zayid I, Malatjalian DA and Kamal MF: Colorectal cancer in Jordan and Nova Scotia: a comparative epidemiologic and histopathologic study. Cancer *46*: 420-428, 1980. PMID: 6248196. DOI: 10.1002/1097-0142(19800715)46:2<420::aid-cncr2820460236>3.0.co;2-1

29 Mizushima T, Nomura M, Fujii M, Akamatsu H, Mizuno H, Tominaga H, Hasegawa J, Nakajima K, Yasumasa K, Yoshikawa M and Nishida T: Primary colorectal signet-ring cell carcinoma: clinicopathological features and postoperative survival. Surg Today *40*: 234-238, 2010. PMID: 20180076. DOI: 10.1007/s00595-009-4057-y

30 Chua TC, Pelz JO, Kerscher A, Morris DL and Esquivel J: Critical analysis of 33 patients with peritoneal carcinomatosis secondary to colorectal and appendiceal signet ring cell carcinoma. Ann Surg Oncol *16*: 2765-2770, 2009. PMID: 19641972. DOI: 10.1245/s10434-009-0536-z

31 Chen JS, Hsieh PS, Hung SY, Tang R, Tsai W-S, Changchien C-R, Lin P-Y, Wang J-Y and Yeh C-Y: Clinical significance of signet ring cell rectal carcinoma. Int J Colorectal Dis *19*: 102-107, 2004. PMID: 14752674. DOI: 10.1007/s00384-003-0515-y

32 Bittorf B, Merkel S, Matzel KE, Wein A, Dimmler A and Hohenberger W: Primary signet-ring cell carcinoma of the colorectum. Langenbecks Arch Surg *389*: 178-183, 2004. PMID: 15188084. DOI: 10.1007/s00423-004-0474-y

33 Messerini L, Palomba A and Zampi G: Primary signet-ring cell carcinoma of the colon and rectum. Dis Colon Rectum *38*: 1189-1192, 1995. PMID: 7587762. DOI: 10.1007/BF02048335

34 Secco GB, Fardelli R, Campora E, Lapertosa G, Gentile R, Zoli S and Prior C: Primary mucinous adenocarcinomas and signet-ring cell carcinomas of colon and rectum. Oncology *51*: 30-34, 1994. PMID: 8265100. DOI: 10.1159/000227306

35 Psathakis D, Schiedeck TH, Krug F, Oevermann E, Kujath P and Bruch HP: Ordinary colorectal adenocarcinoma *vs*. primary colorectal signet-ring cell carcinoma: study matched for age, gender, grade, and stage. Dis Colon Rectum *42*: 1618-1625, 1999. PMID: 10613484. DOI: 10.1007/BF02236218

36 Connelly JH, Robey-Cafferty SS, el-Naggar AK and Cleary KR: Exophytic signet-ring cell carcinoma of the colorectum. Arch Pathol Lab Med *115*: 134-136, 1991. PMID: 1850587.
37 Liang Z, Yan D, Li G and Cheng H: Clinical analysis of primary colorectal signet-ring cell carcinoma. Clin Colorectal Cancer *17*: e39-e44, 2018. PMID: 28789931. DOI: 10.1016/j.clcc.2017.06.010
38 Chew MH, Yeo SA, Ng ZP, Lim KH, Koh PK, Ng KH and Eu KW: Critical analysis of mucin and signet ring cell as prognostic factors in an Asian population of 2,764 sporadic colorectal cancers. Int J Colorectal Dis *25*: 1221-1229, 2010. PMID: 20686777. DOI: 10.1007/s00384-010-1033-3
39 Makino T, Tsujinaka T, Mishima H, Ikenaga M, Sawamura T, Nakamori S, Fujitani K, Hirao M, Kashiwazaki M, Masuda N, Takeda M and Mano M: Primary signet-ring cell carcinoma of the colon and rectum: report of eight cases and review of 154 Japanese cases. Hepatogastroenterology *53*: 845-849, 2006. PMID: 17153438.
40 Pande R, Sunga A, Levea C, Wilding GE, Bshara W, Reid M and Fakih MG: Significance of signet-ring cells in patients with colorectal cancer. Dis Colon Rectum *51*: 50-55, 2008. PMID: 18030531. DOI: 10.1007/s10350-007-9073-7

Received October 13, 2020
Revised October 25, 2020
Accepted October 26, 2020