ANTICANCER RESEARCH *40*: 6355-6366 (2020)
doi:10.21873/anticanres.14656

Significance of *P16*^{INK4A} Expression and *PTEN* Loss of Heterozygosity in Human Papilloma Virus-related Oral Squamous Cell Carcinoma

VALDENIRA DE JESUS OLIVEIRA KATO[1,2*], MICHELLE CARVALHO DE ABREU[3,4*], ALBERTO MITSUYUKI DE BRITO KATO[5,6], LUCAS LACERDA DE SOUZA[4,7], FLAVIA SIROTHEAU CORREA PONTES[7], CARLA DE CASTRO SANT'ANNA[2,3], ARNALDO GONÇALVES JUNIOR[7], HÉLDER ANTÔNIO REBELO PONTES[4,7], ANDRE SALIM KHAYAT[3] and ROMMEL MARIO RODRIGUEZ BURBANO[2,3]

[1]*Laboratory of Human Cytogenetics, Federal University of Pará, Belém, Brazil;*
[2]*Laboratory of Molecular Biology, Ophir Loyola Hospital, Belém, Brazil;*
[3]*Oncology Research Center, João de Barros Barreto University Hospital, Federal University of Pará, Belém, Brazil;*
[4]*Oral Diagnosis Department (Pathology and Semiology Areas), Piracicaba Dental School, University of Campinas, Piracicaba, Brazil;*
[5]*Head and Neck Surgery Department, Ophir Loyola Hospital, Belém, Brazil;*
[6]*Head and Neck Surgery Department, João de Barros Barreto University Hospital, Federal University of Pará, Belém, Brazil;*
[7]*Oral Surgery and Pathology Department, João de Barros Barreto University Hospital, Federal University of Pará, Belém, Brazil*

Abstract. *Background/Aim: p16 and PTEN are tumor suppressor genes. Loss of these molecules in oral squamous cell carcinoma (OSCC) has been studied worldwide. In this study, we explored whether p16 cooperates with inactive PTEN during the pathogenesis of OSCC, especially in regard to tumor aggressiveness and proliferation. Materials and Methods: Immunocytochemistry and western blot analysis were used to examine the levels of p16 and PTEN. Sequencing analysis was performed to identify mutations in the PTEN gene and HPV infection. Fluorescence in situ hybridization was used to examine the presence of the PTEN locus. Results: PTEN analysis showed high positivity in T4 samples. HPV-positive tumors correlated with tabagism, tumor size 3 and 4, disease stages 3 and 4, presence of lymph node metastasis (N1) and poor differentiation. Immunoexpression of p16 was strongly correlated with the presence of HPV. Conclusion: PTEN demonstrated a higher reactivity in advanced disease stages and p16 was strongly associated with HPV. Viral presence decreases tumor aggressiveness. Patients with advanced stage lesions demonstrated lower survival rate.*

Correspondence to: Carla de Castro Sant' Anna, Núcleo de Pesquisa em Oncologia, Mundurucus Street, 4487, 66073-000 Guamá, Belém, PA, Brazil. Tel: +55 91980118880, e-mail: santannacarla@yahoo.com.br

Key Words: Head and neck, HPV, p16, PTEN, oral squamous cell carcinoma.

Oral squamous cell carcinoma (OSCC) is a subgroup of head and neck cancer squamous cell carcinoma (HNSCC), and the sixth most common malignancy in the world. Despite achievements in the prevention, diagnosis, and treatment management in the last three decades, it still has a weak 50% overall 5-year survival rate (1-3). Despite the well-described synergistic interaction between heavy tobacco and alcohol consumption as significant risk factors, in the last decades, epidemiological studies have shown an essential role for high-risk human papillomavirus (HPV) infections in a subset of HNSCCs, predominantly in oropharynx tumorigenesis (4-7).

HPV-positive head and neck tumors, mainly in the oropharynx, have inherently different epidemiological, clinical, and molecular characteristics compared to those caused by classic risk factors and their HPV-negative counterparts. Noteworthy, the global impact of HPV-associated OSCC cases and the distinct molecular mechanisms that play a significant role in HPV-positive and HPV-negative tumor progression are still unclear (8-10). Oral carcinogenesis is a complex process characterized by aberrant gene and protein expression. In this context, the investigation of p16 expression changes and the *PTEN* gene status has gained prominence (11, 12).

p16 overexpression has been recognized as a reliable surrogate marker for oncogenic HPV infection (13, 14). This protein binds to CDK4 or 6 to impair complex formation with cyclins, which in turn is responsible for the phosphorylation and consequent inactivation of pRB, resulting in cell cycle arrest at G_1/S checkpoint, a way through which p16 protein can inhibit cancer cell proliferation (8, 15).

PTEN is a well-established tumor suppressor gene and a negative regulator of the PI3K/Akt/mTOR pathway; loss of PTEN results in Akt hyperactivation (16, 17). Importantly, loss of PTEN expression was found in 29% of tongue cancers, and loss of heterozygosity (LOH) was identified in 40% of HNSCCs, which has been related to worse outcomes after adjuvant radiotherapy (18-20).

Based on the above, this study aimed to provide an initial insight into $p16^{INK2a}$ expression as a potential prognostic marker, as well as the relevance of additional LOH of the PTEN gene and its protein expression levels in OSCC in a Northern Brazilian cohort.

Materials and Methods

Study design. This retrospective study included a cohort of 119 patients diagnosed with primary OSCC at the Oral Pathology Department of João de Barros Barreto University Hospital (Belém, Brazil) (Table I). The study was conducted following the principles of the Declaration of Helsinki, and the Ethics Committee approved the protocol of the University Hospital João de Barros Barreto (n° 1.426.757). Two oral pathologists and one head and neck surgeon analyzed the available samples to define the TNM classification according to the American Society of Clinical Oncology classification (21).

Table I. *Clinicopathological characteristics of the analyzed samples*.

Clinicopathological features	
N=119	N (%)
Age	
≤40 years	12 (10%)
>40 years	107 (90%)
Gender	
Female	52 (43.7%)
Male	67 (56.3%)
Smoking	
No	45 (37.8%)
Yes	74 (62.2%)
Primary tumor site	
Tongue/Floor of the mouth	65 (54.6%)
Other locations	54 (45.4%)
T (Tumor size)	
T1 or T2	47 (39.5%)
T3 or T4	72 (60.5%)
N (Lymph node metastasis)	
N0 or N1	78 (65.5%)
N2 or N3	41 (34.5%)
Disease stage	
I or II	41 (34.5%)
III or IV	78 (65.5%)
Mutational evaluation	
Mutated	23 (19.3%)
Non-mutated	96 (80.7%)
Histological grade	
Poorly differentiated	56 (47%)
Moderate	29 (24.4%)
Well differentiated	34 (28.6%)

Immunohistochemistry (IHC). The reactions were carried out in 3 μm thick histological sections, dewaxed in two xylol baths, the first in an oven at 60ºC and the second at room temperature. Then, the sections were hydrated in a descending series of ethanol (100%, 95% and 85%). To remove the formolic pigment, the sections were dipped in 10% ammonium hydroxide and 95% ethanol and washed with distilled water. To uncover antibody epitopes, the sections were immersed in 10 mM EDTA buffer solution (pH 8.0), incubated in a microwave for 15 min, and then washed in distilled water. To block endogenous peroxidase, the sections were dipped in a solution of 6% hydrogen peroxide and methanol (1: 1, v/v) twice for 15 min at room temperature and then, washed with Tris solution (pH 7, 4). Then, 3 μm thick histological sections were incubated with antibodies against PTEN (polyclonal anti-human PTEN, Invitrogen, Waltham, MA, USA) and p16 (monoclonal anti-human p16, Santa Cruz Biotechnology, Dallas, TX, USA). After rinsing with PBS, slides were incubated with secondary antibody followed by streptavidin-biotin-peroxidase complex, both for 30 min at room temperature with a PBS wash between each step (LSAB-Kit + HRP; Agilent Technologies, Santa Clara, CA, USA). After diaminobenzidine (DAB+; Agilent Technologies) visualization of peroxidase activity, sections were subsequently counterstained with Mayer's hematoxylin solution (Merck, Darmstadt, Germany). Two pathologists classified the results according to Tsurutani and colleagues (22).

Fluorescence in situ hybridization (FISH). The FISH assay was carried out using 5 μl of Vysis LSI PTEN SpectrumOrange Probe (Abbott Molecular Inc. Chicago, IL, USA) in a humidified chamber at 37˚C overnight and the slides were counterstained with DAPI (4',6-diamidino-2-phenylindole, dihydrochloride). For FISH evaluation, 200 randomly chosen cells stained with the probe in each allele of the *PTEN* gene per sample were counted. Signals of homozygous *PTEN* deletion were considered when a simultaneous lack of both *PTEN* locus signals in 25%-30% of the analyzed cells' scored nuclei was observed (23-25).

Western blotting analysis. Fifty protein samples from human mouth lining epithelium were extracted using RIPA lysis and extraction buffer (25 mM Tris•HCl pH 7.6, 150 mM NaCl, 1% NP-40, 1% sodium deoxycholate, 0.1% SDS; Thermo Fisher Scientific, Waltham, MA, USA), solubilized in 4X Laemmli sample buffer and denatured for 5 min at 95˚C. The proteins were separated by electrophoresis on 12% or 15% SDS-PAGE and transferred onto polyvinylidene fluoride (PVDF) membranes (GE Healthcare Chicago, Illinois, USA). PVDF membranes (Millipore, Billerica, MA, USA) were then blocked at 4˚C overnight with 5% non-fat dry milk in PBS containing 0.1% Tween 20. Then, the membranes were incubated with an antibody against p16 (dilution 1:1000; Thermo

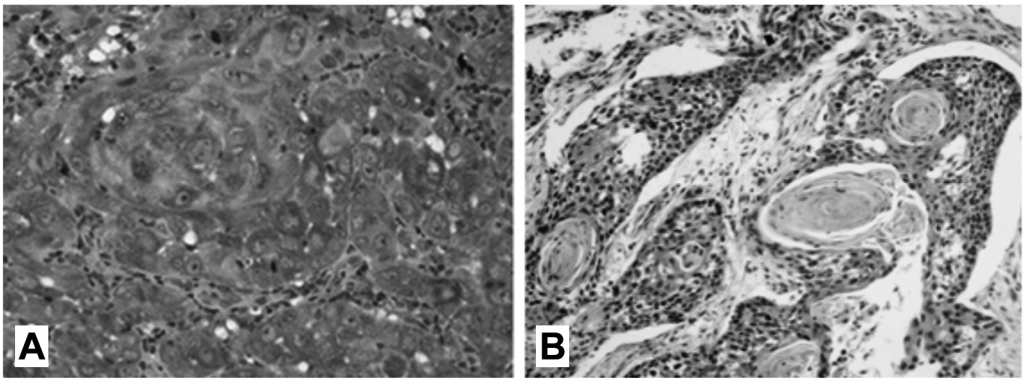

Figure 1. *Immunohistochemical analysis of PTEN and p16 protein expression in OSCC. (A) Immunoreaction for PTEN protein was predominantly in the cytoplasm, less frequent in the nucleus (DAB, ×40). (B) Immunolabeling for p16 demonstrating a nucleus pattern (DAB, ×20).*

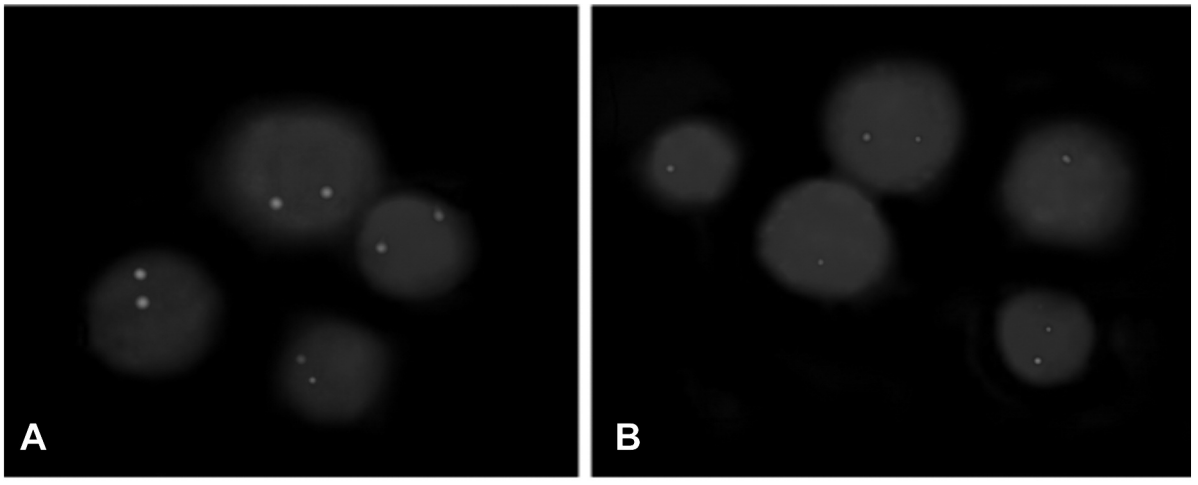

Figure 2. *Immunofluorescence for PTEN evaluating the loss of alleles. (A) Two signals, homozygosity. (B) Loss of homozygosity, one signal.*

Fisher Scientific). The antigen-antibody complexes were visualized using an HRP-conjugated secondary antibody and an enhanced chemiluminescence system (Pierce™ ECL Western Blotting Substrate, Thermo Fisher Scientific). Acquired images were quantified by ImageQuant 350 digital image system (GE) and β-Actin (1:200, Abcam, Cambridge, UK) was used as an internal control of the experiments.

DNA isolation and molecular analysis of PTEN. Ten 5-μm thick histological sections were obtained for DNA extraction by the QIAamp DNA FFPE Tissue Kit (Qiagen, Venlo, the Netherlands), following the protocol of the manufacturer. *PTEN* gene exons 1-9 (26-28) were amplified by polymerase chain reaction (PCR), and samples were then purified with Sephadex® G-50 (Merck KGaA, Darmstadt, Germany). Subsequently, the sequencing reactions were performed using the BigDye Terminator v3.1 (Applied Biosystems 3500, Darmstadt, Germany). Sequencing of non-tumor DNA (from normal mucosa) was used to ascertain that *PTEN* mutations found in the tumors were somatic. Independent repeated analyses confirmed the mutations.

HPV analysis by direct sequencing. The efficacy of DNA extraction was evaluated by PCR amplification of the β-globin gene (29). For the HPV PCR detection, viral gene-specific reactions were performed using GP5+ and GP6+ primers, which amplify a 150 bp fragment of the L1 viral gene, corresponding to a conserved region of the virus genome (30). The viral identification was performed by direct sequencing of the PCR product using the 3500 Genetic Analyzer (Thermo Fisher Scientific).

Statistical analyses. Data were analyzed statistically using the GraphPad Prism 5.0 (GraphPad Software, San Diego, CA, USA) and PASW Statistics program 18.0 (Quarry Bay, Hong Kong). Associations between HPV and other clinicopathological features were analyzed using chi-square (χ^2) and logistic regression. Overall survival rates were estimated by the Kaplan–Meier method and

Table II. *Somatic origin of mutations*.

Case	Mutational status[A]	Protein change[B]	Exon	Consequence	1	2
9	c.253+1 G>C	Splice site	4	Frameshift	8.0%	92.0%
11	c.386 G>A	G129E	5	Missense	7.5%	92.5%
16	c.697 C>T	R233X	7	Nonsense	3.5%	96.5%
26	exon 6-9 del	-	-	Deletion	5.0%	95.0%
28	exon 2 del	-	-	Deletion	2.0%	98.0%
30	c.388 C>T	R130X	5	Nonsense	37.5%	62.5%
32	c.1003 C>T	R335X	8	Nonsense	12.5%	87.5%
33	c.368 A>G	H123R	5	Missense	8.0%	92.0%
36	c.359 T>G	A120X	5	Nonsense	8.0%	92.0%
56	c.253+1 G>C	Splice site	4	Frameshift	36.0%	64.0%
61	c.253+1 G>C	Splice site	4	Frameshift	25.5%	74.5%
65	c.395 G>A	G132N	5	Missense	18.0%	82.0%
70	c.406 T>C	C136R	5	Missense	39.5%	60.5%
73	c.406 T>C	C136R	5	Missense	29.5%	70.5%
76	c.389 G>A	R130Q	5	Missense	10.0%	90.0%
82	c.253+1 G>C	Splice site	4	Frameshift	25.0%	75.0%
83	c.388 C>T	R130X	5	Nonsense	40.0%	60.0%
86	c.528 T>C	Y176X	6	Nonsense	5.0%	95.0%
88	c.388 C>T	R130X	5	Nonsense	8.5%	91.5%
98	c.209 T>C	L70P	3	Missense	18.0%	82.0%
99	c.388 C>T	R130X	5	Nonsense	35.0%	65.0%
106	c.388 C>T	R130X	5	Nonsense	40.0%	60.0%
119	c.253+1 G>C	Splice site	4	Frameshift	50.5%	49.5%

[A]Numbering of the bases indicating the alteration is given relative to the cDNA sequence, with the initiator ATG beginning at base 1. [B]The original amino acid and position of the residues in the protein (with the initiator Met numbered as 1) are followed by an "X" in the case of nonsense mutations.

compared using a Log-rank test. The level of significance was based on a *p*-value ≤0.05, and the confidence interval was 95%.

Results

PTEN immunohistochemistry. PTEN was positive in 79 cases (66.4%), and negative in 40 cases (33.6%). The immunoreaction of PTEN protein was predominantly in the cytoplasm (72.3%), less frequent in the nucleus (5%) and concomitantly in the cytoplasm/nucleus (22.7%). Stage IV tumors showed a higher cytoplasmic/nuclear (51, 9%) immunolabeling (p=0.002) (Figure 1).

High positivity of PTEN was observed in T4 tumors (46.8%) when compared to T1 (22.8%), T2 (11.4%) and T3 (19%) tumors (p<0.01). Patients who presented lymph node metastasis showed a higher PTEN positive index when compared to those who did not present lymph node metastasis (55% *vs*. 44.6%, p=0.02). In contrast, there was no statistically significant correlation between PTEN positivity and age at diagnosis (p=0.98), gender (p=0.16), primary tumor site (p=0.21), disease stage (p=0.61), mutation (p=0.17), histological grade (p=0.57) and p16 expression (p=0.74).

Positive PTEN protein expression was significantly increased in smoking patients when compared to the non-smoking group. Smoking patients had 2.5 times higher expression of PTEN than non-smoking patients (95%CI=1.156-5.549; p=0.03). Our results demonstrated a significant result when the disease stage was associated with mutation, showing that stage IV (65.2%) presented a higher number of mutated cases when compared with stage II (21.7%) and stage III (13%) (p=0.043).

PTEN FISH and molecular analysis. FISH detected loss of alleles in 23 tumors (19.3%), and sequencing of exons 1 to 9 of *PTEN* gene revealed point mutations in 16 samples. We considered that the *PTEN* allele was deleted when 25% or more of the cells in the FISH presented only one fluorescent signal. We were able to observe one fluorescent signal in 49-98% of the interphasic nuclei analyzed, which indicated a deletion of the PTEN gene in our samples (Figure 2).

Even with this high index (19.3% of the samples with more than 25% of the cells had deleted *PTEN* gene), we could not observe a significant association (p>0.05) between the deletion of the PTEN gene and any of the clinical, pathological, or genetic variables analyzed in the present study. In the other 96 OSCC samples (81, 7%), no alteration of the PTEN gene was observed, and the alleles losses occurred in less than 25% of nuclei. No correlation was found between the presence of *PTEN* mutations and the overall survival of the patients studied (p>0.05). However, when we examined the number of mutations in different

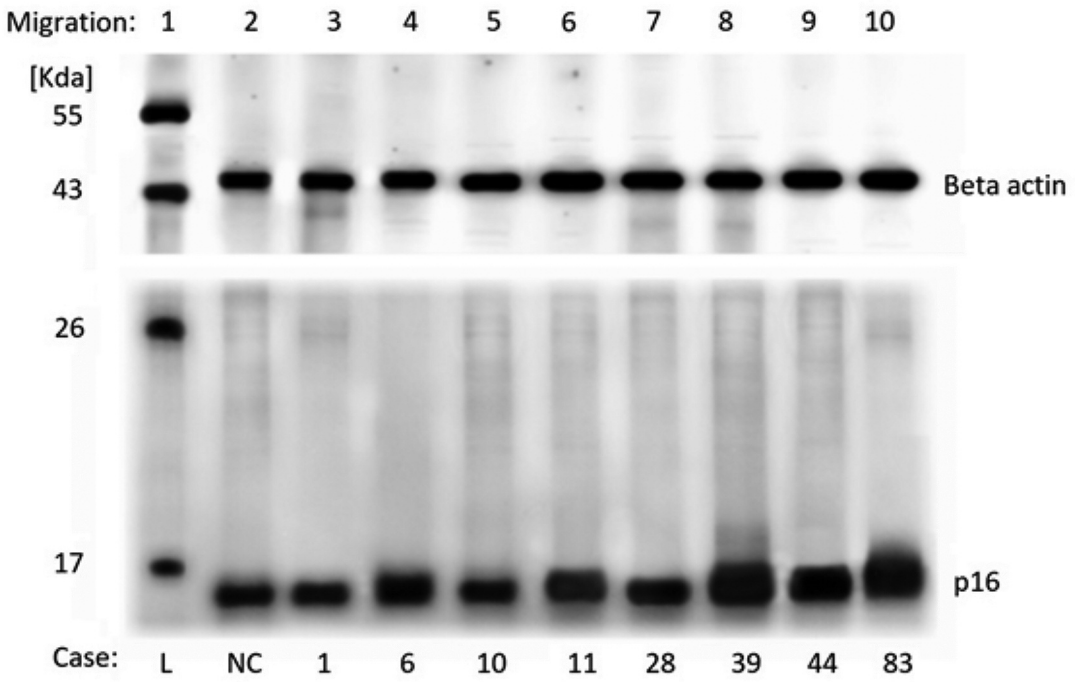

Figure 3. *Representative western blot of p16 (lower gel) and beta-actin (upper gel) that was used as an endogenous marker for normalization. Lanes are labeled on the top of the figure, and the analyzed patients' case numbers are shown at the bottom. Lane 1 L=ladder band pattern. Lane 2 NC=normal control (pool of p16 proteins extracted from 55 normal human mouth lining epithelium). Lanes 3, 5, and 7 correspond to cases negative for the HPV virus that do not overexpress p16 (p16 expression similar to the normal human mouth lining epithelium). Lanes 4, 6, 8, 9 and 10 correspond to HPV-positive cases [subtype 6 (lanes 4 and 6) 16 (line 8), 11 (line 9) and 18 (line 10)] with p16 overexpression. Lanes 3 and 5 correspond to samples with wild type p16 that are negative for HPV and do not overexpress p16. Lanes 4, 8, and 9 correspond to samples with wild type p16 that are positive for HPV and overexpress p16. Lanes 6 and 10 correspond to samples with mutated p16 that are positive for HPV and overexpress p16, and lane 7 corresponds to a sample with mutated p16 that is negative for HPV virus and does not overexpress p16. The relative quantification of OSCC tumor p16 protein in relation to the pool of p16 proteins extracted from 55 normal human mouth lining epithelium was: 0.98 (lane 3), 1.58 (lane 4), 0.96 (lane 5), 1.58 (lane 6), 1.17 (lane 7), 2.01 (lane 8), 1.59 (lane 9), 2.23 (lane 10).*

tumor stages, we could observe a statistically significant difference between stage IV (60% of them) and stages II (27% of them) and III (20% of them) (p=0.043). There is a seven times greater risk for advanced stages in the presence of mutation of *PTEN*. We did not detect mutations in stage I. The results of the molecular analyses and FISH of *the PTEN* gene are summarized in Table II.

Distribution of HPV status. In the analyzed samples, it was observed that 64 samples (53.8%) were positive for HPV, whereas 55 (46.2%) were negative for HPV. Among those positive, 15 samples demonstrated a positive reaction product for low-risk HPV-6 (23.5%), 9 for subtype 11 (14%), 25 subtype 16 (39%) and 15 subtype 18 (23.5%), totaling 40 cases with high risk for HPV(HR-HPV). HPV-positive tumors demonstrated a statistically significant result for tabagism (p<0.0001), evidencing an association between tobacco consumption and HPV positive samples. Furthermore, the results revealed a significant correlation between HPV-positive status, tumor size 3 and 4 (p<0.0001) and disease stage 3/4 (p<0.0001) when compared to HPV negative samples. Additionally, we observed a strong correlation between HPV positive status and lymph node metastasis (N1) (p<0.0001), as well as with poorly differentiated tumor samples (p<0.0001).

Distribution of p16 positive cases in all tumors. p16 immunoreaction demonstrated primarily a cytoplasmic pattern (82.3%), less frequently a nuclear pattern (7.8%) and concomitantly in the cytoplasm/nucleus (9.9%) (Figure 1B).

p16 expression was strongly associated with the presence of HPV (p<0.0001). However, there was no statistically significant correlation between the expression of p16 and some clinicopathological features, like age (p=0.10), gender (p=0.58), TNM, and mutational status of *PTEN* (p=0.52). It is worth emphasizing that fifty-eight percent of patients with p16-positive tumors were non-smokers, and 85.7% of those with p16-negative tumors had more than ten pack-years of exposure.

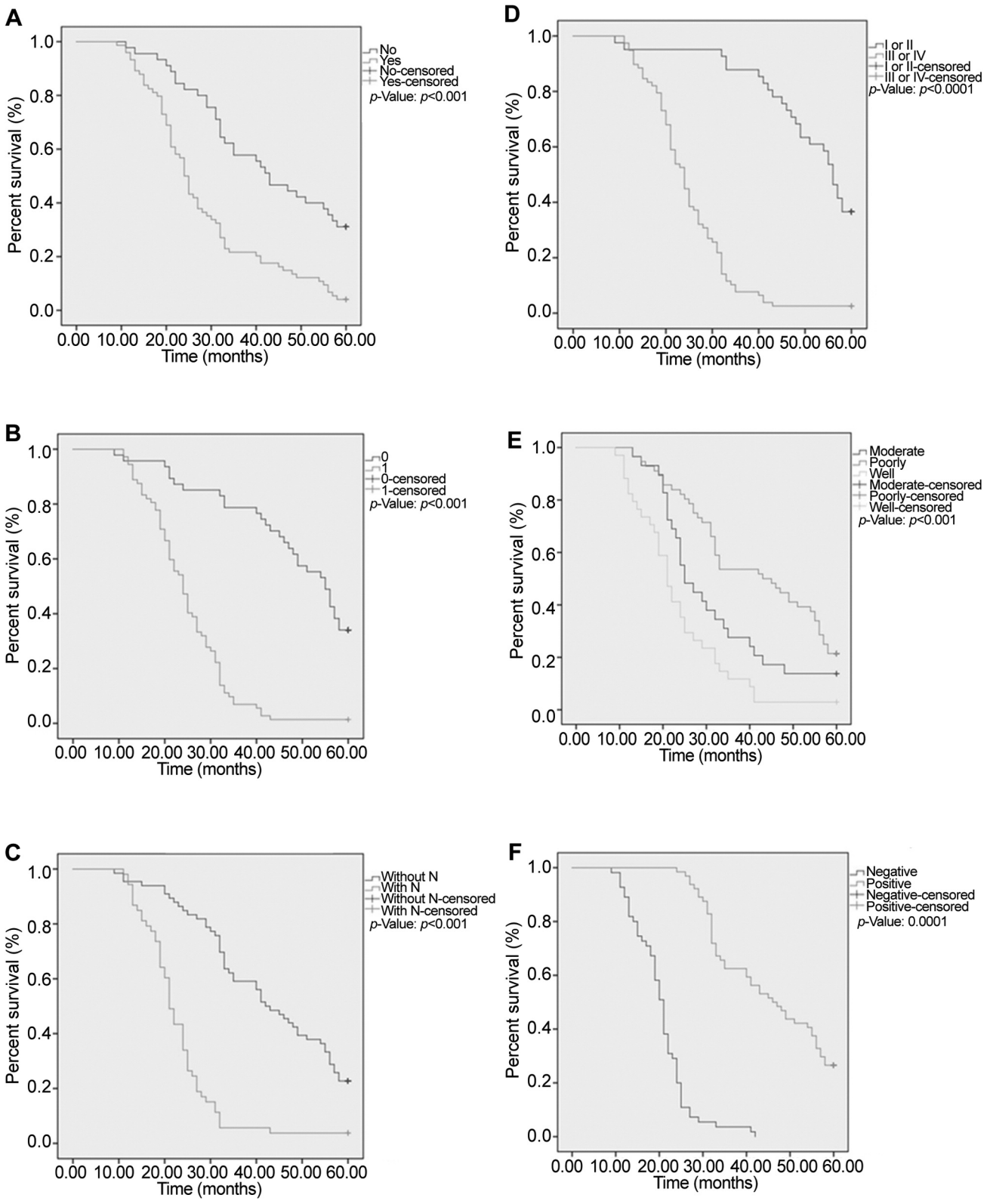

Figure 4. *Continued*

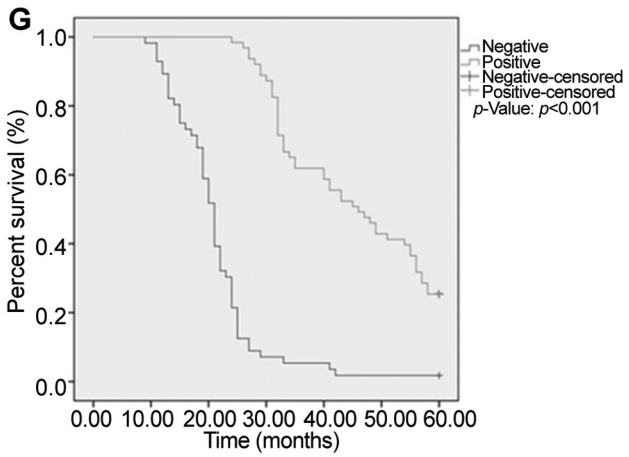

Figure 4. *Survival analysis and its association with clinicopathological factors. (A) Smoking patients demonstrated 14 months less survival than non-smoking patients (p<0.001). (B) Individuals who presented tumor sizes 3 and 4 demonstrated a 1.94 times higher risk of death when compared with tumor sizes 1 and 2 (p<0.001). (C) Patients diagnosed with 2 or 3 metastatic lymph nodes were 2.23 times more likely to die compared to patients without lymph node metastasis or with only one lymph node metastasis (p=0.001). (D) Individuals who demonstrated disease stage 3 or 4 showed 2.03 times higher risk of death than stage 1 and 2. (E) The odds of death among those who presented poorly differentiated histological grade were 1.76 times (p<0.001) higher than those classified as well-differentiated tumors. (F) Individuals who had no HPV had a 2.22 times greater chance of death than that seen for HPV-positive patients (p=0.0001). the odds of death among patients who were HPV -negative was 2.22 times (p=0.0001) greater than that observed for HPV-positive patients. (G) Patients who were p16 negative showed 2.14 times longer survival time than those who were p16 positive (p<0.001).*

Figure 3 is a representative western blot of p16 that lists OSCC HPV negative cases that do not overexpress p16 (p16 expression similar to the normal human mouth lining epithelium) and OSCC HPV-positive cases with p16 overexpression.

Survival outcomes. The follow-up time was 5 years (60 months). Overall, 102 patients (85.7%) deceased. Overall cumulative survival rates were 95% at one year, 33% at three years, and 14% at five years. Univariate analysis found prognosis to be significantly related to seven clinicopathological factors. These variables were: smoking, tumor size, lymph node metastasis, disease stage, histological grade, HPV status, and subtypes. Multivariate analysis of these six significant variables determined by univariate analysis identified that all six prognostic factors independently impacted on survival and one (p16 status) that did not independently impact on survival. The log-rank test showed that the odds ratios of death among smoking patients were 1.5 times higher, equivalent to 14 months less of survival (p<0.001), than non-smoking patients (Figure 4A). Patients who presented tumor sizes 3 and 4 demonstrated a 1.94 times higher risk of death (p<0.001) when compared with tumor sizes 1 and 2 (Figure 4B). The odds of death for patients who were diagnosed with lymph node metastasis 2 and 3 was 2.23 times. The risk of death was 2.23 times greater for patients with lymph node metastasis (N2 and N3) (p<0.001) than patients with no lymph node metastasis (0 and 1) (Figure 4C). Regarding the disease stage, our results demonstrated that the odds of death among those who presented disease stages 3 and 4 was 2.03 times (p<0.0001) greater than those staged as 1 and 2 (Figure 4D).

The odds of death among those who presented poorly differentiated histological grade were 1.76 times (p<0.001) higher than those classified as well-differentiated tumors (Figure 4E). Furthermore, the odds of death among patients who were HPV-negative was 2.22 times (p=0.0001) greater than those observed for HPV-positive patients (Figure 4F). We examined survival outcomes based on p16 status and observed that those patients who presented p16 positive immunostaining had 2.14 times longer survival time than those who were negative (p<0.001) (Figure 4G). There were also survival outcome differences between the p16-positive and p16-negative patients that had a smoking history. The patients who were smokers and had no p16 protein expression had two times fewer survival months compared with non-smokers that were p16 positive (p<0.001).

Discussion

OSCC is the most common malignant neoplasm of the oral cavity (31, 32). This pathological entity commonly affects male individuals, such as those in the present study, belonging to an age group above 40 years and is frequently diagnosed in the sixth decade of life, which is in accordance with our results (33-37). Furthermore, it has been shown that the tongue and the floor of the mouth are the lesion sites in the majority of cases (23, 31, 34, 38).

The tumor suppressor gene *PTEN* is also involved in oral tumorigenesis, as it has been demonstrated that *PTEN* inactivation or deletion mimics activation of the mTOR signaling pathway in the pathogenesis of OSCC. Moreover, *PTEN* LOH and reduced levels of the protein play an essential role in aggressive tumors and contribute to poor disease-free and overall survival (39, 40). In support, from 119 patients with OSCC analyzed in the present study, 40 samples were negative for PTEN immunoexpression.

Squarize *et al*. (38) have analyzed PTEN expression in OSCC by immunohistochemistry. They showed that protein expression was related to the degree of malignancy and that aggressive tumors with high malignancy score did not express PTEN, suggesting that it can be used as a prognostic marker.

Conversely, our study demonstrated a statistically significant association between increased PTEN expression and T4 tumors, lymph node metastasis, and smoking. This unexpected result may be explained by the fact that increased PTEN levels occur to compensate for the increased levels of Akt, since they directly influence the molecular pathways of progression of malignant neoplasms (17, 23). Additionally, Troeltzsch and colleagues (41) have shown that poorly differentiated tumors are associated with the occurrence of lymph node metastasis, which corroborates with our results since an increased number of poorly differentiated tumors was observed.

Mutations in the *PTEN* gene were also evaluated in the lesions, and we observed 16 point mutations and allelic deletions in 19.3% of the analyzed tumors. The results showed a statistically significant association between stage IV tumors and the presence of a mutation.

Previous studies that evaluated gene expression and copy number alterations in OSCC demonstrated loss of *PTEN* in 59.4% of cases (42). Indeed, somatic mutations or deletions of *PTEN* have been previously described in a wide variety of premalignant and malignant lesions, including breast, prostate, endometrial, and oral squamous cell carcinomas, head and neck cancer, glioblastoma and melanoma (43). In head and neck squamous cell carcinoma, loss of the *PTEN* gene was found in 8.16% of cases, and somatic mutations in 5.45% (44). Interestingly, protein expression was not correlated with the presence of mutations, indicating that another mechanism can alter PTEN function.

Another gene with suppressor function and a significant role in carcinogenesis is *p16*, a cyclin-dependent kinase inhibitor that controls tumor progression by inhibiting transition through the G1 phase of the cell cycle (45). In this study, we examined the correlation between HR-HPV infection and *P16* and *PTEN* LOH and observed that high expression of p16 and PTEN in OSCC was sometimes associated with clinicopathological data.

Recent studies have found that abnormal expression of the tumor suppressor gene *P16* was closely associated with HR-HPV infection during carcinogenesis in a subset of HNSCC. Multiple studies have found that p16 is an important prognostic biomarker in oropharyngeal squamous cell carcinoma (OPSCC) (46). The prognostic role of p16 in non-oropharyngeal HNSCC, including OSCC, however, is unclear. Several studies have concluded that p16 has no prognostic significance in non-OPSCC (14, 47, 48), whereas others have concluded the opposite (49).

HPV DNA and expression of p16 has been suggested as a gold standard marker for the detection of HPV infection in many cases of cancers (49, 50). The frequency of HPV infection is significantly higher in patients with OSCC, as identified through the detection of HPV DNA and p16 expression (51). Our results revealed that 64 of the 119 cases were HPV positive, with a high expression of p16. Among these positive samples, 40 showed the presence of the virus subtypes 16 or 18. Interestingly, a study that evaluated the expression of p16 in correlation with an HPV infection in HNSCC observed that the protein expression was higher in the oropharynx and p16 positive patients had better survival, demonstrating that it is a useful prognostic marker in combination with the status of the p16 HPV (52).

A recent study analyzed 174 samples of OSCC for p16 levels and the presence of HPV DNA and its genotypes. Of the total, 24 samples were found to overexpress p16 and in 13, HPV DNA was detected. In agreement, the current study demonstrated that HR-HPV (16 or 18) genotypes were the most prevalent, enhancing the hypothesis about p16 immunoreactivity and HPV genotyping as a useful marker of virus infection in OSCC (53).

Several studies have examined the relationship between smoking status and p16 expression mechanisms and reported that smoking was significantly associated with promoting p16 methylation (54). Corroboratively, a recent study from China has reported that smoking is positively correlated with p16 hypermethylation in NSCLC (55). However, their meta-analysis was limited to promoter methylation, which is not the most common mechanism of inactivation for p16. Another meta-analysis confirmed that all inactivation mechanisms are genuinely associated with loss of protein expression. There is also a study that identified specific associations between p16 inactivation mechanisms and other genetic changes and smoking status (54).

Regarding patient's survival, we observed that smoking patients presented 14 months shorter survival compared to non-smoking patients. Kawakita *et al*. have explained that smoking induces p53 mutations and may trigger many harmful cascades in the human body, leading to a poor prognosis (56). Increased tumor size (3 and 4) demonstrated a 1.94 times higher risk of death when compared with smaller tumor sizes, consistent with other previous studies (41, 57). Additionally, we showed that the odds of death for patients who were diagnosed with lymph node metastasis N2 or N3 were higher (2.23 times higher) than those with N0 or N1. Furthermore, we demonstrated that the odds of death among those who presented with disease stages 3 and 4 were two times greater than those staged as 1 and 2. Therefore, cancer staging based on the TNM stage was a significant prognostic variable (58).

Positive HPV samples were also significantly correlated with increased tumor size, which can be explained by the inactivation of the Rb protein through the E7 HPV protein. In this scenario, p16 overexpression may be an attempt to recover Rb normal function, thus allowing normal cellular progression from the G1 phase to the S phase of the cell cycle. Furthermore, similar to our results, it has been shown that advanced tumors also showed a significant association with p16 overexpression (59).

In addition, the possibility of death of patients with poorly differentiated histological grades was 1.76 times greater than those with well-differentiated tumors, which is compatible with previous studies (60). The tumor's aggressiveness may explain, for instance, the association of the histological grade with lymph node metastasis, recurrence index, and distant metastasis (56, 58).

Besides that, p16 has been shown to sensitize HPV-positive cells to ionizing radiation by inhibiting homologous recombination-mediated DNA damage response and down-regulating cyclin D1 expression. The inhibition of the DNA damage response by p16 is thought to be independent of its cell-cycle regulation–inhibition CDK4/6 activity (61).

Conclusion

In conclusion, *PTEN* and *p16* are suppressor genes that control tumor progression. In the current study, PTEN demonstrated a higher immunoreactivity in advanced disease stages (seven more times). p16 was strongly associated with HPV and did not demonstrate a significant association with any clinicopathological factor analyzed. Both proteins present great importance for the prognosis of patients. It was demonstrated that the presence of the virus decreases tumor aggressiveness. Also, advanced stages lesions demonstrated a lower survival rate. We observed that smoking and p16 absence were significantly associated with two times decreased survival rate.

Further understanding of the role of PTEN in the initiation and progression of cancer increases may be used for the design of novel therapeutic approaches, such as inhibition of Akt, which the protein involved in the most common signaling pathway associated with OSCC progression.

Conflicts of Interest

The Authors declare that they have no competing interests regarding this study.

Authors' Contributions

Study concepts: RMRB, VJOK, MCA, HARP; Study design: RMRB, VJOK, MCA, HARP; Data acquisition: VJOK, MCA, LLS, ASK, AMBK; Quality control of data and algorithms: AGJ, ASK, CCS, LLS, MCA, RMRB; Data analysis and interpretation: VJOK, AMBK, AGJ, ASK, CCS, LLS, MCA, RMRB; Statistical analysis: ASK, MCA, LLS, RMRB; Manuscript preparation: VJOK, MCA, LLS, RMRB, FSCP, HARP; Manuscript editing: VJOK, MCA, AMBK, LLS, ASK, CCS, FSCP, AGJ, HARP, RMRB; Manuscript review: VJOK, MCA, AMBK, LLS, ASK, CCS, FSCP, AGJ, HARP, RMRB.

Acknowledgements

This work was supported by the Coordination of Improvement of Higher Education –Brazil (CAPES, Finance Code 001 to V.J.O.K); National Counsel of Technological and Scientific Development - Brazil (CNPq, grants #301350/2019-1 to R.M.R.B.) and Dean of Research and Graduate Studies of Federal University of Pará – Brazil (PROPESP for payment of the publication fees).

References

1 Sasahira T and Kirita T: Hallmarks of cancer-related newly prognostic factors of oral squamous cell carcinoma. Int J Mol Sci *19(8)*, 2018. PMID: 30115834. DOI: 10.3390/ijms19082413

2 Bavle RM, Venugopal R, Konda P, Muniswamappa S and Makarla S: Molecular classification of oral squamous cell carcinoma. J Clin Diagn Res *10(9)*: 18-21, 2016. PMID: 27790599. DOI: 10.7860/JCDR/2016/19967.8565

3 Kumar M, Nanavati R, Modi TG and Dobariya C: Oral cancer: Etiology and risk factors: A review. J Cancer Res Ther *12(2)*: 458-463, 2016. PMID: 27461593. DOI: 10.4103/0973-1482.186696

4 Furniss CS, McClean MD, Smith JF, Bryan J, Applebaum KM, Nelson HH, Posner MR and Kelsev KT: Human papillomavirus 6 seropositivity is associated with risk of head and neck squamous cell carcinoma, independent of tobacco and alcohol use. Ann Oncol *20(3)*: 534-541, 2009. PMID: 19087986. DOI: 10.1093/annonc/mdn643

5 Ragin CC, Modugno F and Gollin SM: The epidemiology and risk factors of head and neck cancer: a focus on human papillomavirus. J Dent Res *86(2)*: 104-114, 2007. PMID: 17251508. DOI: 10.1177/154405910708600202

6 Husain N and Neyaz A: Human papillomavirus associated head and neck squamous cell carcinoma: Controversies and new concepts. J Oral Biol Craniofac Res *7(30)*: 198-205, 2017. PMID: 29124000. DOI: 10.1016/j.jobcr.2017.08.003

7 Bersani C, Haeggblom L, Ursu RG, Giusca SE, Marklund L, Ramqvist T, Näsman A and Daliani T: Overexpression of FGFR3 in HPV-positive tonsillar and base of tongue cancer is correlated to outcome. Anticancer Res *38(8)*: 4683-4690, 2018. PMID: 30061236. DOI: 10.21873/anticanres.12774

8 Molinolo AA, Marsh C, El Dinali M, Gangane N, Jennison K, Hewitt S, Patel V, Seiwert TY and Gutkind S: mTOR as a molecular target in HPV-associated oral and cervical squamous carcinomas. Clin Cancer Res 18(9): 2558-2568, 2012. PMID: 22409888. DOI: 10.1158/1078-0432.CCR-11-2824

9 Wasylyk B, Abecassis J and Jung AC: Identification of clinically relevant HPV-related HNSCC: in p16 should we trust? Oral Oncol *49(10)*: e33-e7, 2013. PMID: 23962789. DOI: 10.1016/j.oraloncology.2013.07.014

10 Nauta IH, Rietbergen MM, van Bokhoven AAJD, Bloemena E, Lissenberg-Witte BI, Heideman DAM, Baatenburg de Jong RJ, Brakenhoff RH and Leemans CR: Evaluation of the eighth TNM classification on p16-positive oropharyngeal squamous cell carcinomas in the Netherlands and the importance of additional HPV DNA testing. Ann Oncol *29(5)*: 1273-1279, 2018. PMID: 29438466. DOI: 10.1093/annonc/mdy060

11 Nikitakis NG, Pentenero M, Georgaki M, Poh CF, Peterson DE, Edwards P, Lingen M and Sauk JJ: Molecular markers associated with development and progression of potentially premalignant oral epithelial lesions: Current knowledge and future implications. Oral Surg Oral Med Oral Pathol Oral Radiol *125(6)*: 650-669, 2018. PMID: 29709496. DOI: 10.1016/j.oooo.2018.03.012

12 Jurel SK, Gupta DS, Singh RD, Singh M and Srivastava S: Genes and oral cancer. Indian J Hum Genet *20(1)*: 4-9, 2018. PMID: 24959008. DOI: 10.4103/0971-6866.132745

13 Deschuymer S, Dok R, Laenen A, Hauben E and Nuyts S: Patient selection in human papillomavirus related oropharyngeal cancer: The added value of prognostic models in the new TNM 8th Edition Era. Front Oncol *8*: 273, 2018. PMID: 30083517. DOI: 10.3389/fonc.2018.00273

14 Fakhry C, Westra WH, Wang SJ, van Zante A, MD, ZhangY,Rettig E, Yin LX, Tyan WR, Ha PK, Wentz A, Koch W, Richmon JD, Eisele DW and D'Soua G: The prognostic role of sex, race, and human papillomavirus in oropharyngeal and nonoropharyngeal head and neck squamous cell cancer. Cancer *123(9)*: 1566-1575, 2017. PMID: 28241096. DOI: 10.1002/cncr.30353

15 David Lu XJ, Liu KYP, Soares RC, Thomson T, Prisman E, Wu J and Poh CF: Potential clinical implications of HPV status and expressions of p53 and cyclin D1 among oropharyngeal cancer patients. J Oral Pathol Med *47(10)*: 945-953, 2018. PMID: 30191616. DOI: 10.1111/jop.12779

16 Jung SH, HJ Hwang, Kang D, Park HA, Lee HC, Jeong D, Lee K, Park HJ, Ko YG and Lee JS: mTOR kinase leads to PTEN-loss-induced cellular senescence by phosphorylating p53. Oncogene *38(10)*: 1639-1650, 2019. PMID: 30337688. DOI: 10.1038/s41388-018-0521-8

17 Pontes FSC, Pontes HAR, de Souza LL, de Jesus AS, Joaquim AMC, Miyahara LA, Fonseca FP and Pinto Júnior DS: Effect of 17-allylamino-17-demethoxygeldanamycin (17-AAG) on Akt protein expression is more effective in head and neck cancer cell lineages that retain PTEN protein expression. J Oral Pathol Med *47(3)*: 253-259, 2018. PMID: 29297949. DOI: 10.1111/jop.12676

18 Snietura M, Jaworska M, Mlynarczyk-Liszka J, Goraj-Zajac A, Piglowski W, Lange D, Wozniak G, Nowara E and Suwinski R: PTEN as a prognostic and predictive marker in postoperative radiotherapy for squamous cell cancer of the head and neck. PLoS One *7(3)*: e33396, 2012. PMID: 22413021. DOI: 10.1371/journal.pone.0033396

19 Zhao J, Chi J, Gao M, Zhi J, Li Y and Zheng X: Loss of PTEN expression is associated with high MicroRNA 24 level and poor prognosis in patients with tongue squamous cell carcinoma. J Oral Maxillofac Surg *75(7)*: 1449.e1-1449.e8, 2017. PMID: 28413152. DOI: 10.1016/j.joms.2017.03.025

20 Lee JI, Soria JC, Hassan KA, El-Naggar AK, Tang X, Liu DD, Hong WK and Mao L: Loss of PTEN expression as a prognostic marker for tongue cancer. Arch Otolaryngol Head Neck Surg *127(12)*: 1441-1445, 2001. PMID: 11735811. DOI: 10.1001/archotol.127.12.1441

21 Lydiatt W, O'Sullivan B and Patel S: Major changes in head and neck staging for 2018. Am Soc Clin Oncol Educ Book *38*: 505-514, 2018. PMID: 30231400. DOI: 10.1200/EDBK_199697

22 Tsurutani J, Fukuoka J, Tsurutani H, Shih JH, Hewitt SM, Travis WD, Jen J and Dennis PA: Evaluation of two phosphorylation sites improves the prognostic significance of Akt activation in non–small-cell lung cancer tumors. J Clin Oncol *24(2)*: 306-314, 2006. PMID: 16330671. DOI: 10.1200/JCO.2005.02.4133

23 Miyahara LAN, Pontes FSC, Burbano RMR, Conte Neto N, Guimarães DM, Fonseca FP and Pontes HAR: PTEN allelic loss is an important mechanism in the late stage of development of oral leucoplakia into oral squamous cell carcinoma. Histopathology *72(2)*: 330-338, 2018. PMID: 16330671. DOI: 10.1200/JCO.2005.02.4133

24 Lotan TL, Wei W, Ludkovski O, Morais CL, Guedes LB, Jamaspishvili Y, Lopez K, Hawley ST, Feng Z, Fazli L, Hurtado-Coll A, McKenney JK, Simko J, Carroll PR, Gleave M, Lin DW, Nelson OS, Thompson IM, True LD, Brooks JD, Lance RL, Troyer D and Squire JA: Analytic validation of a clinical-grade PTEN immunohistochemistry assay in prostate cancer by comparison to PTEN FISH. Mod Pathol *29(8)*: 904-914, 2016. PMID: 27174589. DOI: 10.1038/modpathol.2016.88

25 Carvalho RM, DE Castro Sant'Anna C, Pinto GR, Paschoal EHA, Tuji FM, Nascimento BB, Soares PC, Ferreira Júnior AG, Rey JA, Chaves LCL and Burbano RR: Frequency of the loss of heterozygosity of the NF2 gene in sporadic spinal schwannomas. Anticancer Res *38(4)*: 2149-2154, 2018. PMID: 29599333 DOI: 10.21873/anticanres.12455

26 Davies MP, Gibbs FE, Halliwell N, Joyce KA, Roebuck MM, Rossi ML, Salisbury J, Sibson DR, Tacconi L and Walker C: Mutation in the PTEN/MMAC1 gene in archival low grade and high-grade gliomas. Br J Cancer *79(9-10)*: 1542-1548, 1999. PMID: 10188904. DOI: 10.1038/sj.bjc.6690246

27 Holway AH, Rieger-Christ KM, Miner WR, Cain JW, Dugan JM, Pezza JA, Silverman ML, Shapter A, McLellan R and Summerhayes IC: Somatic mutation of PTEN in vulvar cancer. Clin Cancer Res *6(8)*: 3228-3235, 2000. PMID: 10955808.

28 Hühns M, Salem T, Schneider B, Krohn M, Linnebacher M and Prall F: PTEN mutation, loss of heterozygosity, promoter methylation and expression in colorectal carcinoma: two hits on the gene? Oncol Rep *31(5)*: 2236-2244, 2014. PMID: 24647592. DOI: 10.3892/or.2014.3097

29 Resnick RM, Cornelissen MT, Wright DK, Eichinger GH, Fox HS, Schegget J and Manos MM: Detection and typing of human papillomavirus in archival cervical cancer specimens by DNA amplification with consensus primers. J Natl Cancer Inst *82(18)*: 1477-1484, 1990. PMID: 2167986. DOI: 10.1093/jnci/82.18.1477

30 de RodaHusman AM, Walboomers JM, van den Brule AJ, Meijer CJ and Snijders PJ: The use of general primers GP5 and GP6 elongated at their 3' ends with adjacent highly conserved sequences improves human papillomavirus detection by PCR. J Gen Virol *76(4)*: 1057-1062, 1995. PMID: 9049358. DOI: 10.1099/0022-1317-76-4-1057

31 Bezerra GMDR, Pontes FSC, Conte Neto N, Nascimento LSD, Souza LL, Pinto Junior DDS and Pontes HAR: Nuclear metallothionein in oral squamous cell carcinoma: clinicopathological parameters and patient survival. Braz Oral Res *32*: e105, 2018. PMID: 30328895. DOI: 10.1590/1807-3107bor-2018.vol32.0105

32 Singh V, Husain N, Akhtar N, Khan MY, Sonkar AA and Kumar V: p16 and p53 in HPV-positive versus HPV-negative oral squamous cell carcinoma: do pathways differ? J Oral Pathol Me *46(90)*: 744-751, 2017. PMID: 28186650. DOI: 10.1111/jop.12562

33 Lopes VKM, Jesus AS, Souza LL, Miyahara LAN, Guimarães DM, Pontes HAR, Pontes FSC and Carvalho PL: Ki-67 protein predicts survival in oral squamous carcinoma cells: an immunohistochemical study. Braz Oral Res *31*: e66, 2017. PMID: 28832714. DOI: 10.1590/1807-3107BOR-2017.vol31.0066

34 Pontes HAR, Pontes FSC, de Jesus AS, Soares MCP, Gonçalves FLN, Botelho TL, Ribeiro JC and Pinto Júnior DS: p-Akt and its relationship with clinicopathological features and survival in oral squamous cell carcinoma: an immunohistochemical study. J Oral Pathol Med *44(7)*: 532-537, 2015. PMID: 25244056. DOI: 10.1111/jop.12268

35 Prasad K, Rao R, Augustine D, Sowmya SV, Haragannavar V, Sagar P and Sreedhar P: Pathway based prognostic gene expression profile of buccal and gingivo-buccal oral squamous

cell carcinoma in smokeless tobacco chewers. Head Neck *41(2)*: 388-397, 2019. PMID: 30536474. DOI: 10.1002/hed.25494

36 Howell RE, Wright BA and Dewar R: Trends in the incidence of oral cancer in Nova Scotia from 1983 to 1997. Oral Surg Oral Med Oral Pathol Oral Radiol Endod *95(2)*: 205-212, 2003. PMID: 12582362. DOI: 10.1067/moe.2003.49

37 Moustafa M, Thomas J, Jategaonkar AA, Moubayed S, Moshier E and Urken ML: Epidemiological trends of head and neck cancer in the United States: A SEER Population Study. J Oral Maxillofac Surg *75(12)*: 2562-2572, 2017. PMID: 28618252. DOI: 10.1016/j.joms.2017.05.008

38 Squarize CH, Castilho RM and Santos Pinto D Jr: Immunohistochemical evidence of PTEN in oral squamous cell carcinoma and its correlation with the histological malignancy grading system. J Oral Pathol Med *31(7)*: 379-384, 2002. PMID: 12224530. DOI: 10.1034/j.1600-0714.2002.00142.x

39 Di Cristofano A and Pandolfi PP: The multiple roles of PTEN in tumor suppression. Cell *100(4)*: 387-390, 2000. PMID: 10693755. DOI: 10.1016/s0092-8674(00)80674-1

40 Squarize CH, Castilho RM, Abrahao AC,Molinolo A, Lingen MW and Gutkind JS: PTEN deficiency contributes to the development and progression of head and neck cancer. Neoplasia 15(5): 461-471, 2013. PMID: 23633918. DOI: 10.1593/neo.121024

41 Troeltzsch M, Knösel T, Woodlock T, Troeltzsch M, Pianka A, Probst FA, Mast G, Ehrenfeld M and Otto S: Are there clinical or pathological parameters of maxillary oral squamous cell carcinoma with an influence on the occurrence of neck node metastasis? An appraisal of 92 patients. J Oral Maxillofac Surg *74(1)*: 9-86, 2016. DOI: 10.1016/j.joms.2015.07.011

42 Koncar RF, Feldman R, Bahassi EM and Hashemi Sadraei N: Comparative molecular profiling of HPV-induced squamous cell carcinomas. Cancer Med *6(7)*: 1673-1685, 2017. PMID: 28556593. DOI: 10.1002/cam4.1108

43 Lee JI, Soria JC, Hassan KA, El-Naggar AK, Tang X, Liu DD, Hong WK and Mao L: Loss of PTEN expression as a prognostic marker for tongue cancer. Arch Otolaryngol Head Neck Surg *127(12)*: 1441-1445, 2001. PMID: 11735811. DOI: 10.1001/archotol.127.12.1441

44 Lui VW, Hedberg ML, Li H, Vangara BS, Pendleton K, Zeng Y, Lu Y, Zhang Q, Du Y, Gilbert B, Freilino M, Sauerwein S, Peyser N, Xiao D, Diergaarde B, Wang L, Chiosea S, Seethala R, Johnson J, Kim S , Duvvuri U, Ferris RL, Romkes M, Nukui T, Kwok-Shing Ng P, Garraway LA, Hammerman PS, Mills GB and Grandis JR: Frequent mutation of the PI3K pathway in head and neck cancer defines predictive biomarkers. Cancer Discov *3(7)*: 761-769, 2013. PMID: 23619167. DOI: 10.1158/2159-8290.CD-13-0103

45 Sushma PS, Jamil K, Kumar PU, Satyanarayana U, Ramakrishna M and Triveni B: PTEN and p16 genes as epigenetic biomarkers in oral squamous cell carcinoma (OSCC): a study on south Indian population. Tumour Biol *37(6)*: 7625-732, 2016. PMID: 26687648. DOI: 10.1007/s13277-015-4648-8

46 Gillison ML, D'Souza G, Westra W, Sugar E, Xiao W, Begum S and Viscid R: Distinct risk factor profiles for human papillomavirus type 16-positive and human papillomavirus type 16-negative head and neck cancers. J Natl Cancer Inst *100(6)*: 407-420, 2008. PMID: 18334711. DOI: 10.1093/jnci/djn025

47 Combes JD and Franceschi S: Role of human papillomavirus in nonoropharyngeal head and neck cancers. Oral Oncol *50(5)*: 370-379, 2014. PMID: 24331868. DOI: 10.1016/j.oraloncology.2013.11.004

48 Lai K, Killingsworth M, Matthews S, Caixeiro N, Evangelista C, Wu X, Wykes J, Samakeh A, Forstner D, Niles N, Hong A and Lee CS: Differences in survival outcome between oropharyngeal and oral cavity squamous cell carcinoma in relation to HPV status. J Oral Pathol Med *46(8)*: 574-582, 2017. PMID: 27935119. DOI: 10.1111/jop.12535

49 Satgunaseelan L, Virk SA, Lum T, Gao K, Clark JR and Gupta R: p16 expression independent of human papillomavirus is associated with lower stage and longer disease-free survival in oral cavity squamous cell carcinoma. Pathology *48(5)*: 441-448, 2016. PMID: 27370365. DOI: 10.1016/j.pathol.2016.03.015

50 Soares PC, Abdelhay ES, Thuler LCS, Soares BM, Demachki S, Ferro GVR, Assumpção PP, Lamarão LM, Ribeiro Pinto LF and Burbano RMR: HPV positive, wild type TP53, and p16 overexpression correlate with the absence of residual tumors after chemoradiotherapy in anal squamous cell carcinoma. BMC Gastroenterol *18(1)*: 30, 2018. PMID: 29466950. DOI: 10.1186/s12876-018-0758-2

51 Smitha T, Mohan CV and Hemavathy S: Prevalence of human papillomavirus16 DNA and p16 protein in oral squamous cell carcinoma: A systematic review and meta-analysis. J Oral Maxillofac Pathol *21(1)*: 76-81, 2017. PMID: 28479691. DOI: 10.4103/jomfp.JOMFP_248_16

52 Stephen JK and Worsham MJ: Human papillomavirus (HPV) modulation of the HNSCC epigenome. Methods Mol Biol *1238*: 369-379, 2015. PMID: 25421671. DOI: 10.1007/978-1-4939-1804-1_20

53 Kouketsu A, Sato I, Abe S, Oikawa M, Shimizu Y, Takahashi T and Kumamoto H: Detection of human papillomavirus infection in oral squamous cell carcinoma: a cohort study of Japanese patients. J Oral Pathol Med *45(8)*: 565-572, 2016. PMID: 25421671. DOI: 10.1007/978-1-4939-1804-1_20

54 Tam KW,Zhang W, Soh J, Stastny V, Chen M, Sun H, Thu K, Rios JJ, Yang C, Marconett CN, Selamat SA, Laird-Offringa A, TaguchiA, HanashS, Shames D, Ma X, Zhang MQ and Gazdar WLL: CDKN2A/p16 inactivation mechanisms and their relationship to smoke exposure and molecular features in non–small-cell lung cancer. J Thorac Oncol *8(11)*: 1378-1388, 2013. PMID: 24077454. DOI: 10.1097/JTO.0b013e3182a46c0c

55 Zhang B, Zhu W, Yang P, Liu T, Jiang M, He ZN, Zhang SX, Chen WQ and Chen W: Cigarette smoking and p16INK4α gene promoter hypermethylation in non-small cell lung carcinoma patients: a meta-analysis. PLoS One *6(12)*: e28882, 2011. PMID: 22174919. DOI: 10.1371/journal.pone.0028882

56 Kawakita D, Hosono S, Ito H, Oze I, Watanabe M, Hanai N, Hasegawa Y, Tajima K, Murakami S, Tanaka H and Matsuo K: Impact of smoking status on clinical outcome in oral cavity cancer patients. Oral Oncol *48(2)*: 186-191, 2012. PMID: 21996543. DOI: 10.1016/j.oraloncology.2011.09.012

57 Mukoyama N, Suzuki H, Hanai N, Sone M and Hasegawa Y: Pathological tumor volume predicts survival outcomes in oral squamous cell carcinoma. Oncol Lett *16(2)*: 2471-2477, 2018. PMID: 30013639. DOI: 10.3892/ol.2018.8951

58 De Silva RK, Siriwardena BSMS, Samaranayaka A, Abeyasinghe W and Tilakaratne WM: A model to predict nodal metastasis in patients with oral squamous cell carcinoma. PLoS One *13(8)*: e0201755, 2018. PMID: 30091996. DOI: 10.1371/journal.pone.0201755

59 Fakhry C, Westra WH, Li S, Cmelak A, Ridge JA, Pinto H, Forastiere A and Gillison ML: Improved survival of patients with human papillomavirus-positive head and neck squamous cell carcinoma in a prospective clinical trial. J Natl Cancer Inst *100(4)*: 261-269, 2008. PMID: 18270337. DOI: 10.1093/jnci/djn011

60 Padma R, Kalaivani A, Sundaresan S and Sathish P: The relationship between histological differentiation and disease recurrence of primary oral squamous cell carcinoma. J Oral Maxillofac Pathol *21(3)*: 461, 2017. PMID: 29391735. DOI: 10.4103/jomfp.JOMFP_241_16

61 Harris SL, Thorne LB, Seaman WT, Hayes DN, Couch ME and Kimple RJ: Association of p16(INK4a) overexpression with improved outcomes in young patients with squamous cell cancers of the oral tongue. Head Neck *33(11)*: 1622-1627, 2011. PMID: 21990227. DOI: 10.1002/hed.21650

Received September 9, 2020
Revised October 5, 2020
Accepted October 8, 2020