

The Role of DNA Repair Glycosylase OGG1 in Intrahepatic Cholangiocarcinoma

KAZUHITO SAKATA, TOMOHARU YOSHIKAZUMI, TAKUMA IZUMI, MASAHIRO SHIMOKAWA, SHINJI ITOH,
TORU IKEGAMI, NOBORU HARADA, TAKEO TOSHIMA, YOHEI MANO and MASAKI MORI

Department of Surgery and Science, Graduate School of Medical Sciences, Kyushu University, Fukuoka, Japan

Abstract. *Background/Aim: The effects of oxidative stress on various carcinomas were reported in previous studies, but those in intrahepatic cholangiocarcinoma (ICC) have not been fully elucidated. The purpose of this study was, thus, to reveal the effects of oxidative DNA damage and repair enzymes on ICC. Materials and Methods: The levels of 8-hydroxydeoxyguanosine (8-OHdG) and 8-OHdG DNA glycosylase (OGG1) were immunohistochemically evaluated in specimens resected from 63 patients with ICC. Results: Low OGG1 expression was related to tumour depth T4 ($p=0.04$), venous invasion ($p=0.0005$), lymphatic vessel invasion ($p=0.03$), and perineural invasion ($p=0.03$). Compared to the high-OGG1-expression group, patients with low OGG1 expression had a significantly poorer prognosis (overall survival: $p=0.04$, recurrence-free survival: $p=0.02$). Unlike for OGG1, the expression levels of 8-OHdG showed no association with prognosis. Conclusion: Oxidative DNA damage and DNA repair enzymes may be closely related to ICC progression.*

Cholangiocarcinomas are diverse biliary epithelial tumours involving the intrahepatic perihilar and distal biliary tree (1). Next to hepatocellular carcinoma (HCC), intrahepatic cholangiocarcinoma (ICC) is the second most common primary hepatic malignancy, accounting for 10-20% of diagnosed liver cancers, and the overall incidence of ICC has increased progressively worldwide over the last few decades (2-5). The long-term survival of ICC patients is worse than that of HCC patients, which may be related to the high propensity for regional and distant metastases, and lack of effective therapy (6). Risk factors for ICC, such as

inflammation and bile duct injury have been identified, but the mechanism behind ICC development is still not clear.

Free radicals have been widely documented to play an important role in the development of different diseases (7, 8). Besides having specific cell functions, they are toxic to the cells that produce them, as well as to neighbouring cells. Reactive oxygen species (ROS) are inevitable by-products of the process of oxidative phosphorylation in aerobic metabolism and originate in the electron transport chain of mitochondria. An imbalance between the generation and ablation of ROS leads to oxidative stress and results in tissue damage by oxidizing vital cellular macromolecules such as DNA, proteins and lipids (9, 10). Cancers have been attributed to the direct or indirect effect of free-radical-induced oxidative stress (11, 12). DNA bases are readily oxidized or methylated by oxidative stress, which leads to genomic instability, in turn having serious phenotypic consequences (13). 8-Hydroxydeoxyguanosine (8-OHdG) is an oxidized form of deoxyguanosine nucleoside (14). Guanine is more sensitive to oxidative stress than other nucleic acids, being readily mutated; therefore, it is used as an indicator of such stress.

Oxidative DNA damage is mainly repaired by the enzymes of the base excision repair pathway. 8-OHdG glycosylase (OGG1), the major DNA glycosylase, causes the removal of 8-OHdG from damaged DNA bases (15). OGG1 has seven subtypes, which are localized in the nucleus or the cytoplasm. Nuclear OGG1 repairs nuclear DNA, while cytoplasmic OGG1 repairs mitochondrial DNA (mtDNA) (16). Through 8-OHdG-mediated DNA damage and Ras activation, OGG1 deficiency in mammals has been shown to result in transcriptional mutagenesis (17).

In previous studies, Kubo *et al.* showed a high rate of 8-OHdG accumulation and infrequent nuclear OGG1 expression in oesophageal squamous cell carcinomas, while Karihtala *et al.* showed an association between an absence of OGG1 expression and advanced breast cancer (18, 19). However, to the best of our knowledge, no reports have been published on the association between OGG1 and ICC. The aim of this study was to clarify the effects of oxidative stress and the DNA repair system on ICC, with a focus on 8-OHdG and OGG1.

This article is freely accessible online.

Correspondence to: Tomoharu Yoshizumi, MD, Ph.D., Department of Surgery and Science, Graduate School of Medical Sciences, Kyushu University, Fukuoka 812-8582, Japan. Tel: +81 926425466, Fax: +81 926425482, e-mail: yosizumi@surg2.med.kyushu-u.ac.jp

Key Words: OGG1, 8-OHdG, intrahepatic cholangiocarcinoma.

Materials and Methods

Patients. We analysed 63 consecutive patients with ICC who underwent surgical resection without any presurgical radiation from 1993 to 2015 at Kyushu University Hospital. Six patients were treated with neoadjuvant chemotherapy (GFP, GEM, GEM+CDDP, GEM+S-1). The samples consisted of resected liver specimens from these patients. Permission to use the excised tissue for research was obtained. Due to the retrospective design of the study using archival records, a notification of the study has been published on the webpage of our department. The study was approved by the ethics committee of our hospital, in accordance with ethical guidelines of the Japanese Government (approval number: 27-294).

Immunohistochemistry against 8-OHdG. Samples were obtained from the most invasive areas of the cancer. The specimens were fixed in 10% formalin solution, embedded in paraffin, and cut into 4- μ m-thick sections. The 4- μ m-thick sections were deparaffinized in xylene and rehydrated in a graded series of ethanols. The sections were incubated with 2% skim milk with 5% bovine serum albumin in phosphate-buffered saline to block nonspecific binding of the immunoreagents. Subsequently, they were reacted for 1 h at room temperature with a monoclonal anti-8-OHdG antibody (1:100; Japan Institute for the Control of Aging, Shizuoka, Japan) as the primary antibody. Then, they were treated with 0.3% H₂O₂ to inhibit the activity of endogenous peroxidase for 30 min, and were subjected to the labelled streptavidin-biotin technique. Colour was developed with 3,3'-diaminobenzidine (DAB) as chromogen (18, 20).

Immunohistochemistry against OGG1. The specimens were prepared as described above for 8-OHdG immunohistochemistry. The prepared specimens consisted of serial sections used for the detection of 8-OHdG, so the evaluation of the 8OHdG and OGG1 was made on adjacent sections. After deparaffinization and rehydration, the sections were heated (121°C) in citrate buffer (pH 6.0) for 15 min. Then, they were incubated with 10% normal goat serum to block any nonspecific binding of the immunoreagents and treated with 3% H₂O₂ with methanol. Incubation at 4°C overnight with the primary OGG1 antibody (EPR4664 (2), 1:100; Abcam, Cambridge, MA, USA) was carried out, followed by incubation with the secondary antibody. The sections were then subjected to the labelled streptavidin-biotin technique. DAB chromogen was used as described above.

Histological evaluation. 8-OHdG and OGG1 immunoreactivity grading was performed based on the German Immunoreactive Score (20). First, staining intensity was rated on a scale from 0 to 3, with 0, 1, 2 or 3 indicating no, weak, moderate or strong staining, respectively. Then, the percentage of positive cells was scored as follows: no staining as 0, 1-25% as 1, 26-50% as 2, 51-75% as 3 and 76-100% as 4. The final score was calculated by multiplying the score obtained with the staining intensity by that derived from the percentage of positive cells, with possible results ranging from 0 to 12. To compare the intensity score with clinicopathological factors, a final score of 0-5 was regarded as low expression and 6-12 as high expression of OGG1. The final multiplied score equated 0 as low and 1-12 as high for 8-OHdG (21). Histological and immunohistochemical evaluations were performed independently by two observers (KS and TI) who did not know the clinical characteristics of the patients. In case of low interobserver agreement, the evaluations were made by an extra observer.

Statistical analysis. All statistical analyses were performed using SAS software (JMP 13.0; SAS Institute Inc., Cary, NC, USA). Continuous variables were expressed as means \pm standard deviations. Univariate and multivariate analyses of risk factors for overall death as well as for liver-related and malignancy-related death were performed using Cox proportional hazard's model. Incidence of death by cause was determined using an extension of the Kaplan-Meier method accounting for these competing risks of death.

Results

Clinicopathological findings. The ICC patients were 41 men and 22 women, ranging in age from 33 to 82 years (mean=61.9). There was a high proportion of ICC cases graded as poorly differentiated (well-differentiated, n=11, 17.5%; moderately differentiated, n=19, 30.2%; poorly differentiated, n=32, 50.8%). According to the 6th edition of the General Rules for the Clinical and Pathological Study of Primary Liver Cancer, 24 patients were classified as being at an advanced stage (pT4).

There were 38 (60.3%) cases of serosal invasion, 19 (30.2%) of portal vein invasion, 30 (47.6%) of venous invasion, 25 (39.7%) of lymphatic vessel invasion, and 37 (57.8%) of perineural invasion. Moreover, 17 (27.0%) patients had lymph node metastasis, while no patients exhibited arterial invasion. The levels of OGG1 and 8-OHdG in ICC are presented in Figure 1. The staining of OGG1 and 8-OHdG was observed in both the nucleus and the cytoplasm.

Expression of OGG1 and 8-OHdG. High expression of OGG1 was observed in 17 patients (27.0%), while low in 46 (73.0%). In cancer cells, the expression of OGG1 was observed in both the nucleus and the cytoplasm. Concerning 8-OHdG staining, 31 patients (49.2%) showed high and 32 patients (50.8%) low expression, while cancer cells, the expression of 8-OHdG positive staining was localized mainly in the nucleus.

OGG1 and 8-OHdG expression and clinicopathological factors in patients with ICC. We evaluated the relationship among the OGG1 level, 8-OHdG level and clinicopathological factors in patients with ICC. There were no statistically significant differences in clinical background among the groups based on OGG1 and 8-OHdG expression levels. OGG1 expression and clinicopathological factors in patients with ICC are presented in Table I. Low OGG1 was frequently observed in more advanced tumours, such as those with greater depth (T4; $p=0.04$), venous invasion ($p=0.0005$), lymphatic vessel invasion ($p=0.03$) and perineural invasion ($p=0.03$). In addition, the low-OGG1-expression group had significantly poorer prognosis (overall survival: $p=0.04$, recurrence-free survival: $p=0.02$; Figure 2). Table II shows 8-OHdG expression and clinicopathological factors in patients with ICC. The high-8-OHdG-expression group had poorer differentiation ($p=0.02$) and more venous invasion

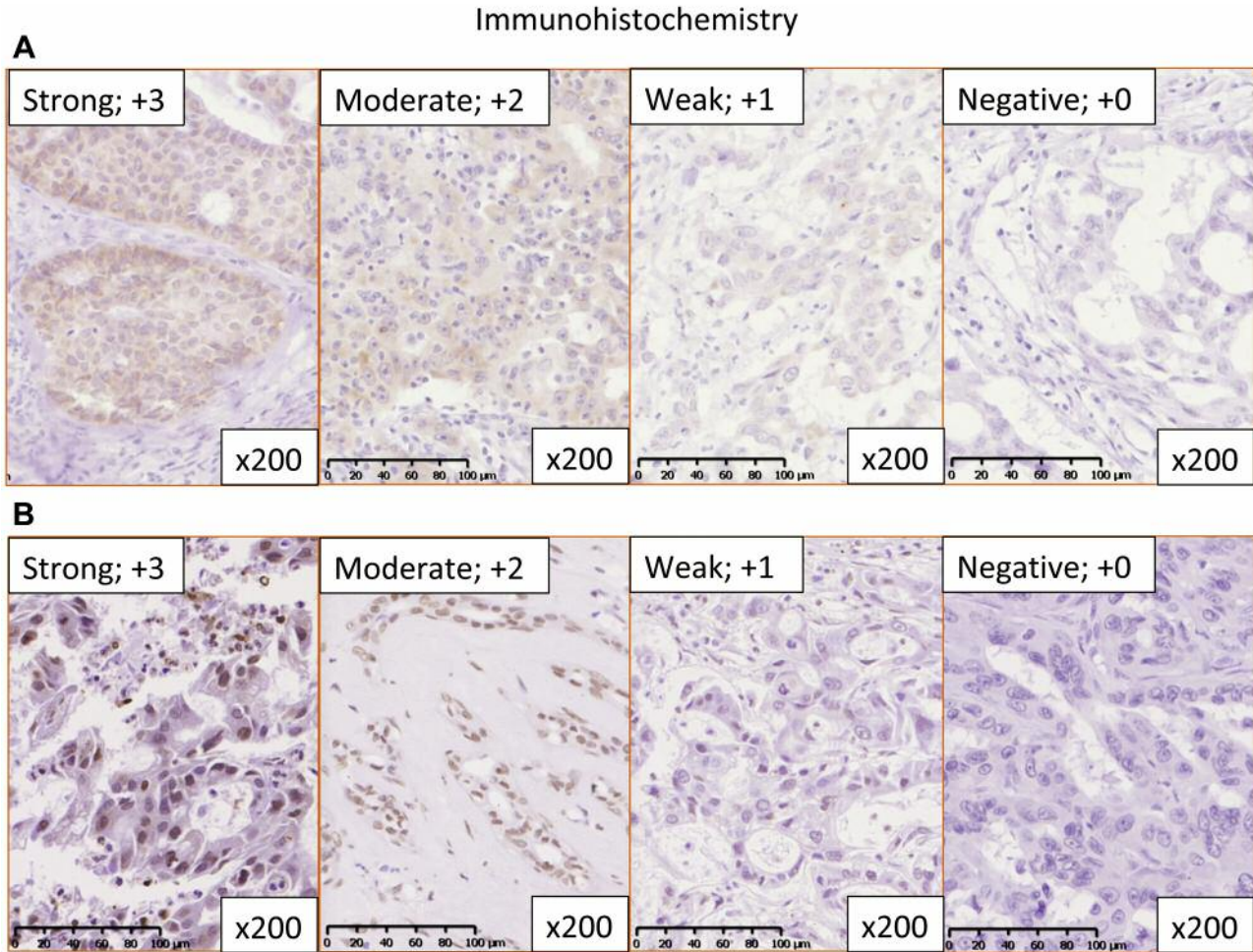


Figure 1. Typical staining intensity of OGG1 (A) and 8-hydroxydeoxyguanosine (8-OHdG) (B) in intrahepatic cholangiocarcinoma (ICC). OGG1 staining in ICC tissues was classified as +0, +1, +2 and +3 (magnification, $\times 200$) and 8-OHdG staining in ICC was classified as +0, +1, +2 and +3 (magnification, $\times 200$).

($p=0.008$). Unlike for OGG1, prognosis was not associated with the expression level of 8-OHdG (Figure 3).

Localization of OGG1 and 8-OHdG. Among 17 OGG1-positive cases, 13 were 8-OHdG-negative. Among the other 4 cases, the expression of 8-OHdG was low at the site of high OGG1 expression in 3 cases. In contrast, there was low expression of OGG1 in the area with high 8-OHdG expression (Figure 4). In addition, the score for 8-OHdG was significantly low in the group with high OGG1 expression ($p=0.01$) (Figure 5).

Discussion

To the best of our knowledge, this is the first report to reveal an association between high OGG1 expression and better prognosis in ICC patients. 8-OHdG is one of the main

oxidized forms of deoxyguanosine nucleosides and can be readily detected by immunohistochemical analysis (22). 8-OHdG has promutagenic potential by mispairing with A residues, thus resulting in an increased frequency of spontaneous G:C to T:A transversion mutations (23, 24). These mutations can be frequently observed in mutated proto-oncogenes and tumour suppressor genes (25). Elevated levels of 8-OHdG have been reported in various types of human tumour (26-28). Kubo *et al.* showed that, in oesophageal epithelium, 8-OHdG leads to OGG1 activation in normal cells, but 8-OHdG accumulation was shown to occur as a result of OGG1 functional disorder in cancer cells (18). In addition, Cao *et al.* reported a correlation between the expression of 8-OHdG and tumour depth in lung cancer (29). In this study, 8-OHdG did not influence the prognosis of ICC patients. However, in the group with high 8-OHdG

Table I. *OGG1* expression and clinicopathological factors in patients with intrahepatic cholangiocarcinoma.

Factors	OGG1 expression		
	High (n=17)	Low (n=46)	p-Value
Clinical factors			
Gender, male	12 (70.6)	29 (63.0)	0.58
Age in decades	65.5±8.7	60.5±11.7	0.13
NAC, yes (%)	3 (17.7)	3 (6.5)	0.18
HBsAg, positive (%)	2 (11.8)	6 (19.4)	0.50
HCVAb, positive (%)	2 (11.8)	2 (6.5)	0.52
Alb, g/dl	4.2±0.5	4.0±0.4	0.06
Plt, /10 ³ mm ³	202±102	227±71	0.14
T.Bil, mg/dl	0.7±0.3	1.1±1.3	0.20
AST, U/l	36.8±16.8	38.8±26.1	0.75
CEA, g/ml	3.5±2.8	6.2±17.9	0.42
CA19-9, U/ml	2177±8533	5192±17134	0.17
Pathological factors			
Cellular differentiation, poor (%)	8 (47.1)	24 (53.3)	0.66
Tumor size, cm	4.6±2.4	4.9±2.0	0.31
Tumor invasive depth, T4 (%)	3 (17.7)	21 (45.7)	0.04
Lymph node metastasis, N1 (%)	3 (17.7)	14 (30.4)	0.30
Serosal invasion, positive (%)	12 (70.6)	26 (56.5)	0.31
Portal vein invasion, positive (%)	5 (29.4)	14 (30.4)	0.93
Venous invasion, positive (%)	2 (11.8)	28 (60.9)	0.0005
Artery invasion, positive (%)	0 (0.0)	0 (0.0)	-
Lymphatic vessel invasion, positive (%)	3 (17.7)	22 (47.8)	0.03
Perineural invasion, positive (%)	6 (35.3)	31 (67.4)	0.02
Intrahepatic metastasis (%)	5 (29.4)	23 (50.0)	0.14

NAC, Neoadjuvant chemotherapy; HBsAg, hepatitis B surface antigen; HCVAb, hepatitis C virus antibody; Alb, albumin; Plt, platelet count; T.Bil, total bilirubin; AST, aspartate transaminase; CEA, carcinoembryonic antigen; CA19-9, carbohydrate antigen 19-9. Statistically significant values are shown in bold.

expression, there were poorer cellular differentiation and a higher rate of venous invasion than in the low-8-OHdG-expression group. This may have been due to 8-OHdG contributing to malignant transformation.

In this study, no significant difference in prognosis was identified in relation to OGG1 expression only in the nucleus or cytoplasm, but a meaningful difference appeared for OGG1 expression in whole cells. In the low-OGG1-expression group, tumour depth T4, venous invasion, lymphatic vessel invasion and perineural invasion were frequently observed. OGG1 can prevent not only mutation of nuclear DNA, but also increase of intracellular ROS by repairing mtDNA (30). For ICC patients, previous reports showed that lymph node metastasis was a significant prognostic factor (31-34), and Choi *et al.* reported that lymph node metastasis was related to vascular and perineural invasion (35). Guglielmi *et al.* found that microscopic tumour type, lymph node metastasis and vascular invasion

Table II. *8-OHdG* expression and clinicopathological factors in patients with intrahepatic cholangiocarcinoma.

Factors	8-OHdG expression		
	High (n=31)	Low (n=32)	p-Value
Clinical factors			
Gender, male	9 (29.0)	13 (40.6)	0.33
Age in decades	58.9±12.1	64.8±9.3	0.08
NAC, yes (%)	2 (6.5)	4 (12.5)	0.41
HBsAg, positive (%)	6 (20.7)	4 (12.5)	0.50
HCVAb, positive (%)	3 (10.3)	2 (6.3)	0.56
Alb, g/dl	4.0±0.4	4.1±0.4	0.52
Plt, /10 ³ mm ³	225±80	216±82	0.56
T.Bil, mg/dl	1.2±1.5	0.7±0.2	0.18
AST, U/l	41.8±30.0	34.9±15.8	0.73
CEA, g/ml	7.1±21.7	3.9±4.1	0.15
CA19-9, U/ml	7343±20909	1388±4198	0.91
Pathological factors			
Cellular differentiation, poor (%)	20 (66.7)	12 (37.5)	0.02
Tumor size, cm	5.1±2.1	4.6±2.2	0.28
Tumor invasive depth, T4 (%)	12 (38.7)	12 (37.5)	0.92
Lymph node metastasis, N1 (%)	10 (32.3)	7 (21.9)	0.35
Serosal invasion, positive (%)	17 (54.8)	21 (65.6)	0.38
Portal vein invasion, positive (%)	9 (29.0)	10 (31.3)	0.85
Venous invasion, positive (%)	20 (64.5)	10 (31.3)	0.0008
Artery invasion, positive (%)	0 (0.0)	0 (0.0)	-
Lymphatic vessel invasion, positive (%)	14 (45.2)	11 (34.4)	0.38
Perineural invasion, positive (%)	19 (61.3)	18 (56.3)	0.68
Intrahepatic metastasis (%)	15 (48.4)	13 (40.6)	0.54

NAC, Neoadjuvant chemotherapy; HBsAg, hepatitis B surface antigen; HCVAb, hepatitis C virus antibody; Alb, albumin; Plt, platelet count; T.Bil, total bilirubin; AST, aspartate transaminase; CEA, carcinoembryonic antigen; CA19-9, carbohydrate antigen 19-9. Statistically significant values are shown in bold.

were important predictive factors of poor survival in patients with ICC (36). In our study, it was regarded that poor prognosis in the group with low OGG1 expression arose from the significant increases in venous invasion and lymphatic vessel invasion.

The expression of 8-OHdG significantly decreased in the group with high OGG1 expression, but, unlike OGG1, there was no significant difference in prognosis with regard to the expression of 8-OHdG. OGG1 deficiency caused a significant increase in oxidative damage in mtDNA, leading to increased caspase 1 activation, most notably in macrophages, leading to greater IL-1 β production (37). Furthermore, it has been reported that mtDNA damage is significantly more abundant and persists longer than nuclear DNA damage after exposure to oxidative stress (38). In mice, hOGG1, one of the OGG1 subtypes protecting cells from mtDNA damage, resulted in the downregulation of HIF-1 α and attenuated the phosphorylation of Akt. This resulted in

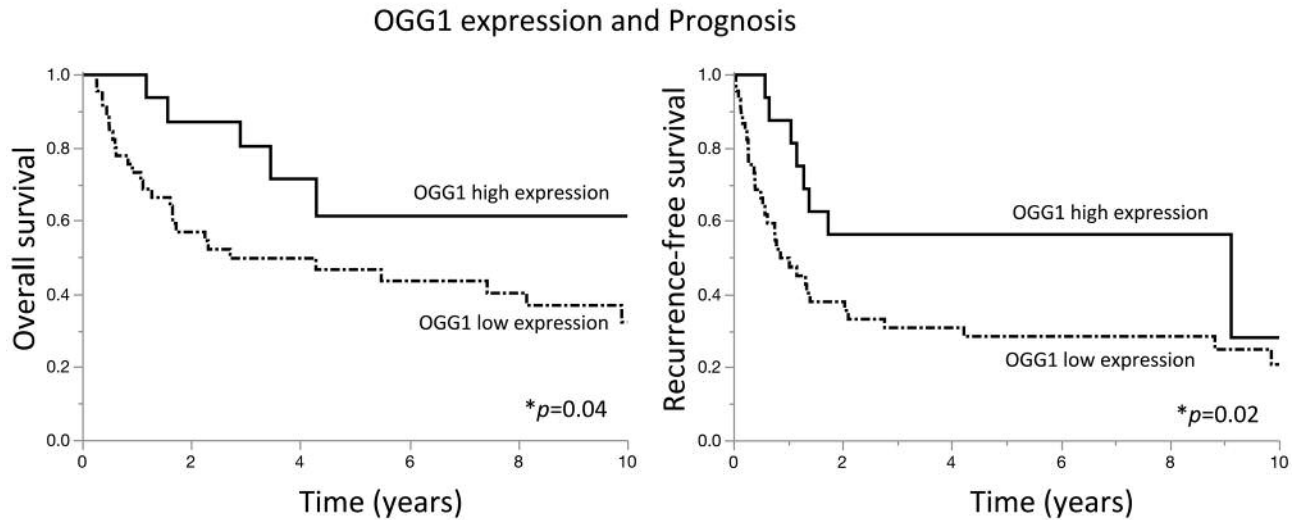


Figure 2. Kaplan-Meier survival curves for ICC-specific survival rates for both OGG1-positive and -negative cases. OGG1-negative cases had significantly shorter overall survival ($p=0.04$) and recurrence-free survival ($p=0.02$).

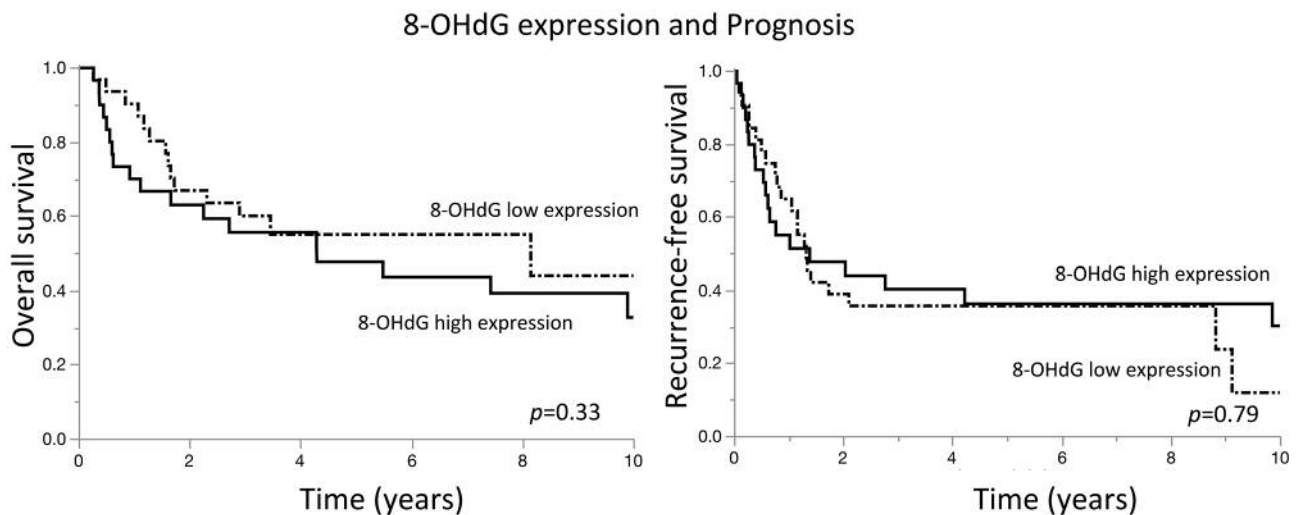


Figure 3. Kaplan-Meier survival curves for ICC-specific survival rates for both 8-OHdG-positive and -negative cases. 8-OHdG-positive cases did not have significantly shorter overall survival ($p=0.33$) or recurrence-free survival ($p=0.79$).

breast cancer progression and metastasis *in vivo* (30). In our study, the expression of 8-OHdG was only observed in the nucleus, but the expression of OGG1 was recognized in both nucleus and cytoplasm. It is possible that the lack of investigation of 8-OHdG expression in mtDNA caused this prognosis difference between with regard to the expression of OGG1 and 8-OHdG.

There are certain limitations in this study. First, the patients were from a single center, thus the study lacks heterogeneity of population, and moreover, the study population is relatively small. In addition, although

immunohistochemical staining was evaluated by trained pathologists, results are susceptible to bias and interobserver variability since they are based on subjective on visual assessment. Therefore, larger, multicenter studies are needed to elucidate the role and prognostic value of OGG1 in ICC.

In conclusion, it was suggested that high OGG1 expression is related with decreased expression of 8-OHdG and better prognosis in ICC patients. OGG1 was localized both in the nucleus and cytoplasm, suggesting that OGG1-mediated repair of not only nuclear, but also mitochondrial DNA may have a critical role in malignant transformation of cells. This is the

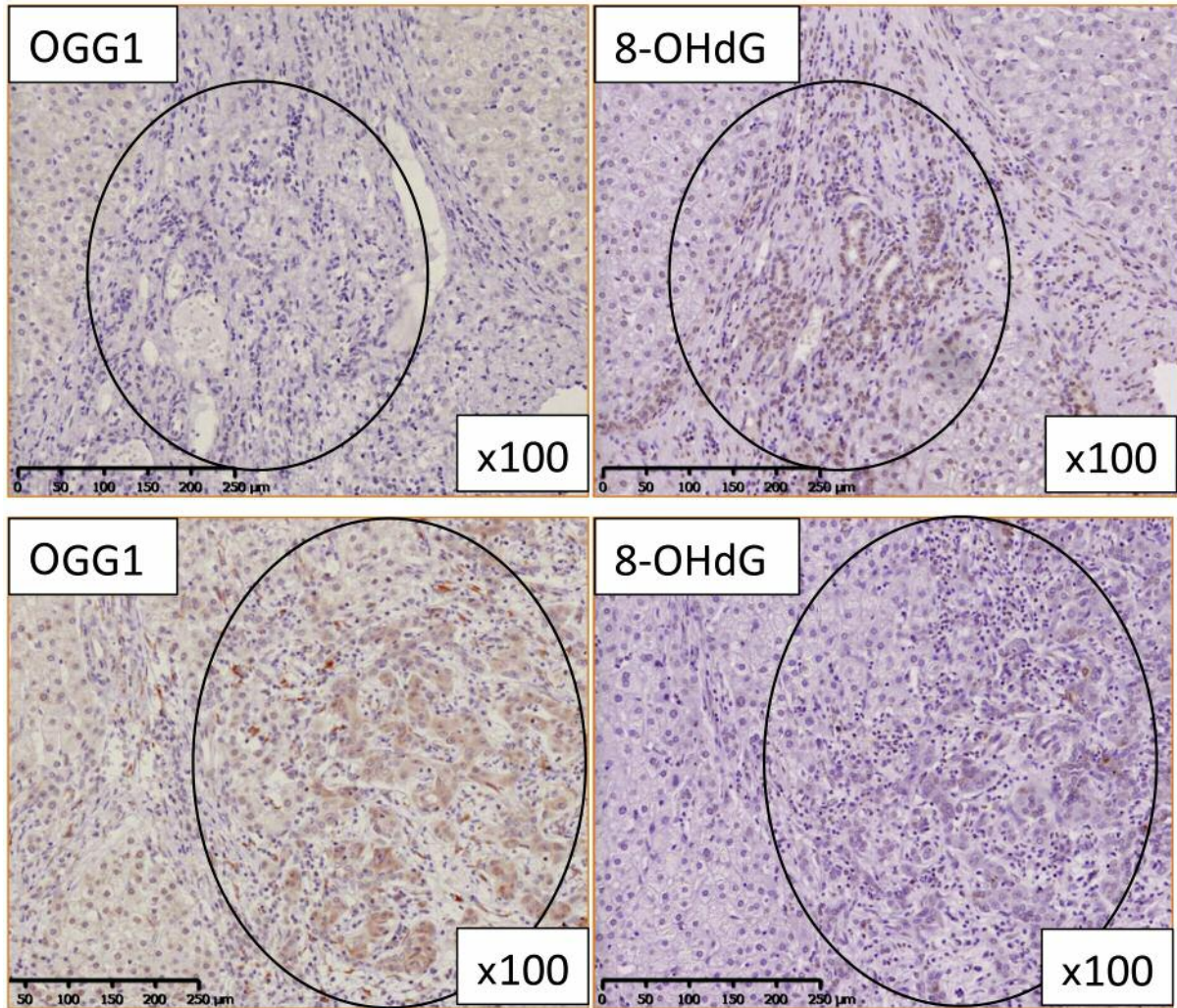


Figure 4. Typical staining of *OGG1* and *8-OHdG* in one ICC patient. The area with high *OGG1* expression had low *8-OHdG* expression, while the area with low *OGG1* expression had high *8-OHdG* expression (magnification, $\times 100$).

first study to demonstrate that oxidative stress and DNA repair enzymes play important roles in cancer progression in ICC.

Conflicts of Interest

The Authors declare no conflicts of interest.

Authors' Contributions

Kazuhiro Sakata conceived and designed the study, contributed to the immunohistochemistry experiments, to data collection, analysis and interpretation, as well as to drafting of manuscript. Tomoharu Yoshizumi contributed the immunohistochemistry experiments as well as to data collection, analysis, and interpretation. Masahiro Shimokawa, Toru Ikegami, Noboru Harada, Shinji Itoh, Takeo Toshima and Yohei Mano contributed to data collection. Masaki Mori revised the manuscript.

Acknowledgements

The Authors wish to thank Edanz Group Japan (www.edanzediting.co.jp) for editing in English a draft of this manuscript.

References

- 1 Rizvi S and Gores GJ: Pathogenesis, diagnosis, and management of cholangiocarcinoma. *Gastroenterology* 145(6): 1215-1229, 2013. PMID: 24140396. DOI: 10.1053/j.gastro.2013.10.013
- 2 Saha SK, Zhu AX, Fuchs CS and Brooks GA: Forty-year trends in cholangiocarcinoma incidence in the u.S.: Intrahepatic disease on the rise. *Oncologist* 21(5): 594-599, 2016. PMID: 27000463. DOI: 10.1634/theoncologist.2015-0446
- 3 Khan SA, Taylor-Robinson SD, Toledano MB, Beck A, Elliott P and Thomas HC: Changing international trends in mortality rates

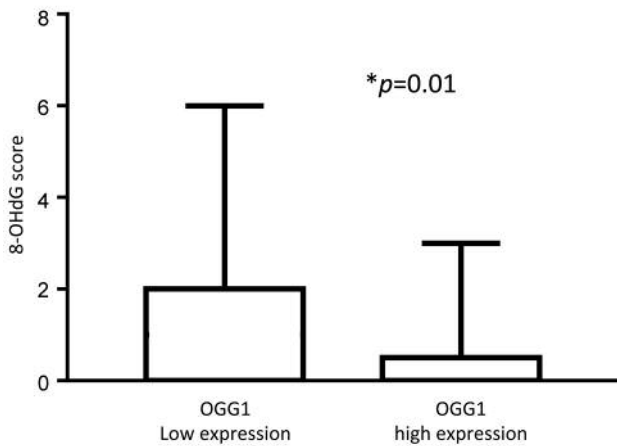


Figure 5. Comparison of immunohistochemical staining scores for 8-hydroxydeoxyguanosine (8-OHdG) between patients with high and low OGG1 expression. The expression of 8-OHdG in the low-OGG1-expression group was significantly higher than that in the high-OGG1-expression group ($p=0.01$). p -Value was calculated using Wilcoxon's signed-rank test.

for liver, biliary and pancreatic tumours. *J Hepatol* 37(6): 806-813, 2002. PMID: 12445422.

4 Taylor-Robinson SD, Toledano MB, Arora S, Keegan TJ, Hargreaves S, Beck A, Khan SA, Elliott P and Thomas HC: Increase in mortality rates from intrahepatic cholangiocarcinoma in England and Wales 1968-1998. *Gut* 48(6): 816-820, 2001. PMID: 11358902. DOI: 10.1136/gut.48.6.816

5 Altae MY, Johnson PJ, Farrant JM and Williams R: Etiologic and clinical characteristics of peripheral and hilar cholangiocarcinoma. *Cancer* 68(9): 2051-2055, 1991. PMID: 1717133.

6 Ribero D, Pinna AD, Guglielmi A, Ponti A, Nuzzo G, Giulini SM, Aldrighetti L, Calise F, Gerunda GE, Tomatis M, Amisano M, Berloco P, Torzilli G and Capussotti L: Surgical approach for long-term survival of patients with intrahepatic cholangiocarcinoma: A multi-institutional analysis of 434 patients. *Arch Surg* 147(12): 1107-1113, 2012. PMID: 22910846. DOI: 10.1001/archsurg.2012.1962

7 Polidori MC, Stahl W, Eichler O, Niestroj I and Sies H: Profiles of antioxidants in human plasma. *Free Radic Biol Med* 30(5): 456-462, 2001. PMID: 11182517.

8 Jomova K and Valko M: Importance of iron chelation in free radical-induced oxidative stress and human disease. *Curr Pharm Des* 17(31): 3460-3473, 2011. PMID: 21902663.

9 Barnes DE and Lindahl T: Repair and genetic consequences of endogenous DNA base damage in mammalian cells. *Annu Rev Genet* 38: 445-476, 2004. PMID: 15568983. DOI: 10.1146/annurev.genet.38.072902.092448

10 Monaghan P, Metcalfe NB and Torres R: Oxidative stress as a mediator of life history trade-offs: Mechanisms, measurements and interpretation. *Ecol Lett* 12(1): 75-92, 2009. PMID: 19016828. DOI: 10.1111/j.1461-0248.2008.01258.x

11 Turi JL, Jaspers I, Dailey LA, Madden MC, Brighton LE, Carter JD, Nozik-Grayck E, Piantadosi CA and Ghio AJ: Oxidative stress activates anion exchange protein 2 and ap-1 in airway epithelial cells. *Am J Physiol Lung Cell Mol Physiol* 283(4): L791-798, 2002. PMID: 12225956. DOI: 10.1152/ajplung.00398.2001

12 Wang C, Wang Z, Liu W and Ai Z: Ros-generating oxidase nox1 promotes the self-renewal activity of cd133+ thyroid cancer cells through activation of the akt signaling. *Cancer Lett* 447: 154-163, 2019. PMID: 30690057. DOI: 10.1016/j.canlet.2019.01.028

13 D'Errico M, Parlanti E and Dogliotti E: Mechanism of oxidative DNA damage repair and relevance to human pathology. *Mutat Res* 659(1-2): 4-14, 2008. PMID: 18083609. DOI: 10.1016/j.mrrev.2007.10.003

14 Nishimura S: 8-hydroxyguanine: From its discovery in 1983 to the present status. *Proc Jpn Acad Ser B Phys Biol Sci* 82(4): 127-141, 2006. PMID: 25792776.

15 Dianov G, Bischoff C, Piotrowski J and Bohr VA: Repair pathways for processing of 8-oxoguanine in DNA by mammalian cell extracts. *J Biol Chem* 273(50): 33811-33816, 1998. PMID: 9837971. DOI: 10.1074/jbc.273.50.33811

16 Nishioka K, Ohtsubo T, Oda H, Fujiwara T, Kang D, Sugimachi K and Nakabeppu Y: Expression and differential intracellular localization of two major forms of human 8-oxoguanine DNA glycosylase encoded by alternatively spliced ogg1 mRNAs. *Mol Biol Cell* 10(5): 1637-1652, 1999. PMID: 10233168. DOI: 10.1091/mbc.10.5.1637

17 Saxowsky TT, Meadows KL, Klungland A and Doetsch PW: 8-oxoguanine-mediated transcriptional mutagenesis causes ras activation in mammalian cells. *Proc Natl Acad Sci USA* 105(48): 18877-18882, 2008. PMID: 19020090. DOI: 10.1073/pnas.0806464105

18 Kubo N, Morita M, Nakashima Y, Kitao H, Egashira A, Saeki H, Oki E, Kakeji Y, Oda Y and Maehara Y: Oxidative DNA damage in human esophageal cancer: Clinicopathological analysis of 8-hydroxydeoxyguanosine and its repair enzyme. *Dis Esophagus* 27(3): 285-293, 2014. PMID: 23902537. DOI: 10.1111/dote.12107

19 Karihtala P, Kauppila S, Puistola U and Jukkola-Vuorinen A: Absence of the DNA repair enzyme human 8-oxoguanine glycosylase is associated with an aggressive breast cancer phenotype. *Br J Cancer* 106(2): 344-347, 2012. PMID: 22108520. DOI: 10.1038/bjc.2011.518

20 Tsuruya K, Furuichi M, Tominaga Y, Shinozaki M, Tokumoto M, Yoshimitsu T, Fukuda K, Kanai H, Hirakata H, Iida M and Nakabeppu Y: Accumulation of 8-oxoguanine in the cellular DNA and the alteration of the ogg1 expression during ischemia-reperfusion injury in the rat kidney. *DNA Repair (Amst)* 2(2): 211-229, 2003. PMID: 12531391.

21 Sarian LO, Derchain SF, Yoshida A, Vassallo J, Pignataro F and De Angelo Andrade LA: Expression of cyclooxygenase-2 (cox-2) and ki67 as related to disease severity and hpv detection in squamous lesions of the cervix. *Gynecol Oncol* 102(3): 537-541, 2006. PMID: 16537091. DOI: 10.1016/j.ygyno.2006.01.052

22 Hirano T: Repair system of 7, 8-dihydro-8-oxoguanine as a defense line against carcinogenesis. *J Radiat Res* 49(4): 329-340, 2008. PMID: 18596371. DOI: 10.1269/jrr.08049

23 Valavanidis A, Vlachogianni T and Fiotakis C: 8-hydroxy-2'-deoxyguanosine (8-ohdg): A critical biomarker of oxidative stress and carcinogenesis. *J Environ Sci Health C Environ Carcinog Ecotoxicol Rev* 27(2): 120-139, 2009. PMID: 19412858. DOI: 10.1080/10590500902885684

24 Ock CY, Kim EH, Choi DJ, Lee HJ, Hahm KB and Chung MH: 8-hydroxydeoxyguanosine: Not mere biomarker for oxidative stress, but remedy for oxidative stress-implicated gastrointestinal diseases. *World J Gastroenterol* 18(4): 302-308, 2012. PMID: 22294836. DOI: 10.3748/wjg.v18.i4.302

- 25 Yasaei H, Gilham E, Pickles JC, Roberts TP, O'Donovan M and Newbold RF: Carcinogen-specific mutational and epigenetic alterations in ink4a, ink4b and p53 tumour-suppressor genes drive induced senescence bypass in normal diploid mammalian cells. *Oncogene* 32(2): 171-179, 2013. PMID: 22410783. DOI: 10.1038/onc.2012.45
- 26 Sanchez M, Torres JV, Tormos C, Iradi A, Muniz P, Espinosa O, Salvador A, Rodriguez-Delgado J, Fandos M and Saez GT: Impairment of antioxidant enzymes, lipid peroxidation and 8-oxo-2'-deoxyguanosine in advanced epithelial ovarian carcinoma of a spanish community. *Cancer Lett* 233(1): 28-35, 2006. PMID: 15899547. DOI: 10.1016/j.canlet.2005.02.036
- 27 Oltra AM, Carbonell F, Tormos C, Iradi A and Saez GT: Antioxidant enzyme activities and the production of mda and 8-oxo-dg in chronic lymphocytic leukemia. *Free Radic Biol Med* 30(11): 1286-1292, 2001. PMID: 11368926
- 28 Nour Eldin EEM, El-Readi MZ, Nour Eldein MM, Alfalki AA, Althubiti MA, Mohamed Kamel HF, Eid SY, Al-Amodi HS and Mirza AA: 8-hydroxy-2'-deoxyguanosine as a discriminatory biomarker for early detection of breast cancer. *Clin Breast Cancer* 19(2): e385-e393, 2019. PMID: 30683611. DOI: 10.1016/j.clbc.2018.12.013
- 29 Cao C, Lai T, Li M, Zhou H, Lv D, Deng Z, Ying S, Chen Z, Li W and Shen H: Smoking-promoted oxidative DNA damage response is highly correlated to lung carcinogenesis. *Oncotarget* 7(14): 18919-18926, 2016. PMID: 26942876. DOI: 10.18632/oncotarget.7810
- 30 Yuzefovych LV, Kahn AG, Schuler MA, Eide L, Arora R, Wilson GL, Tan M and Rachek LI: Mitochondrial DNA repair through ogg1 activity attenuates breast cancer progression and metastasis. *Cancer Res* 76(1): 30-34, 2016. PMID: 26586787. DOI: 10.1158/0008-5472.CAN-15-0692
- 31 Saiura A, Yamamoto J, Kokudo N, Koga R, Seki M, Hiki N, Yamada K, Natori T and Yamaguchi T: Intrahepatic cholangiocarcinoma: Analysis of 44 consecutive resected cases including 5 cases with repeat resections. *Am J Surg* 201(2): 203-208, 2011. PMID: 19427630. DOI: 10.1016/j.amjsurg.2008.12.035
- 32 Valverde A, Bonhomme N, Farges O, Sauvanet A, Flejou JF and Belghiti J: Resection of intrahepatic cholangiocarcinoma: A western experience. *J Hepatobiliary Pancreat Surg* 6(2): 122-127, 1999. PMID: 10398898.
- 33 Ercolani G, Vetrone G, Grazi GL, Aramaki O, Cescon M, Ravaioli M, Serra C, Brandi G and Pinna AD: Intrahepatic cholangiocarcinoma: Primary liver resection and aggressive multimodal treatment of recurrence significantly prolong survival. *Ann Surg* 252(1): 107-114, 2010. PMID: 20531002. DOI: 10.1097/SLA.0b013e3181e462e6
- 34 Lurje G, Bednarsch J, Czigany Z, Lurje I, Schlebusch IK, Boecker J, Meister FA, Tacke F, Roderburg C, Den Dulk M, Gaisa NT, Bruners P and Neumann UP: The prognostic role of lymphovascular invasion and lymph node metastasis in perihilar and intrahepatic cholangiocarcinoma. *Eur J Surg Oncol*, 2019. PMID: 31053477. DOI: 10.1016/j.ejso.2019.04.019
- 35 Choi SB, Kim KS, Choi JY, Park SW, Choi JS, Lee WJ and Chung JB: The prognosis and survival outcome of intrahepatic cholangiocarcinoma following surgical resection: Association of lymph node metastasis and lymph node dissection with survival. *Ann Surg Oncol* 16(11): 3048-3056, 2009. PMID: 19626372. DOI: 10.1245/s10434-009-0631-1
- 36 Guglielmi A, Ruzzenente A, Campagnaro T, Pachera S, Valdegamberi A, Nicoli P, Cappellani A, Malfermoni G and Iacono C: Intrahepatic cholangiocarcinoma: Prognostic factors after surgical resection. *World J Surg* 33(6): 1247-1254, 2009. PMID: 19294467. DOI: 10.1007/s00268-009-9970-0
- 37 Tumurkhuu G, Shimada K, Dagvadorj J, Crother TR, Zhang W, Luthringer D, Gottlieb RA, Chen S and Arditi M: Ogg1-dependent DNA repair regulates nlrp3 inflammasome and prevents atherosclerosis. *Circ Res* 119(6): e76-90, 2016. PMID: 27384322. DOI: 10.1161/CIRCRESAHA.116.308362
- 38 Yakes FM and Van Houten B: Mitochondrial DNA damage is more extensive and persists longer than nuclear DNA damage in human cells following oxidative stress. *Proc Natl Acad Sci USA* 94(2): 514-519, 1997. PMID: 9012815. DOI: 10.1073/pnas.94.2.514

Received April 1, 2019

Revised May 18, 2019

Accepted May 23, 2019