Periapical Cemento-osseous Dysplasia: Clinicopathological Features

MARCO ROGHI[1], CHIARA SCAPPARONE[1], ROLANDO CRIPPA[1], ARMANDO SILVESTRINI-BIAVATI[2] and FRANCESCA ANGIERO[2]

[1]*Department of Oral Pathology, Italian Stomatological Institute, Milan, Italy;*
[2]*Department of Surgical Sciences and Integrated Diagnostics, University of Genoa, Genova, Italy*

Abstract. *Periapical cemento-osseous dysplasia (PCOD) is a rare benign lesion, often asymptomatic, in which fibrous tissue replaces the normal bone tissue, with metaplasic bone and neo-formed cement. We present a rare case of mandibular PCOD in a woman of 55 years, who presented with moderate swelling and mobility of teeth 32-33-34. Endoral radiography showed that these teeth had been devitalized; they had deep periodontal pockets and marked radicular radiotransparency; the root apices exhibited mixed radiotransparency and radio-opacity. Clinical and radiographical findings led to a diagnosis of periapical rarefying osteitis, and the three teeth were thus extracted. Due to the persistence of swelling and slight pain post-extraction, a cone-beam computed tomographic scan was taken; this showed a mixed radiotransparent and radio-opaque lesion in the area of the extracted teeth. A bone biopsy of the affected area was taken for histopathological evaluation; a diagnosis of PCOD was rendered. This case demonstrates the importance of a full investigation when a patient presents after tooth extraction with non-healing socket, pain, and swelling. A multidisciplinary approach is required to manage these rare cases.*

Periapical cemento-osseous dysplasia (COD) is a very rare benign lesion arising from a group of disorders which are known to originate from undifferentiated cells of the periodontal ligament tissue. Essentially, these underlying disorders all involve the same pathological process. The classification of cemento-osseous lesions remains problematic, and there is divergence of opinion among pathologists (1-3). According to the classification system introduced by the 1992 Revised World Health Organization (WHO) Guidelines, Cemento-Osseous Dysplasia is categorized as a form of neoplasm or other bone-related lesion; it can be sub-divided into periapical cemental dysplasia (PCD), also known as periapical fibrous dysplasia, florid COD (also known as gigantiform cementoma or familial multiple cementoma) and other types of COD (2, 3). COD more usually occurs in the mandible, both in tooth-bearing and edentulous areas, but may occasionally occur in the maxilla. PCD is a relatively common type of COD that predominantly involves the anterior mandible, and affects single or multiple teeth. Florid COD is characterized by multifocal involvement of the jaw. Summerlin and Tomich proposed introducing a separate category of COD, namely focal COD, with mixed and distinguishing features of peri-cemental dysplasia and florid COD (6). Su *et al*. modified the WHO Guidelines and proposed the term FCOD for lesions involving the lower anterior teeth and other areas (7).

Periapical COD occurs more frequently in women of black race (8, 9), and above 40 years of age. The lesions may be single or multiple, asymptomatic and do not involve alterations to the periodontal tissue. The prevalent lesion site is the anterior region of the mandible, in the vicinity of the root apex of the mandibular incisors and canines, and the teeth involved remain vital (4, 5). Typically, the lesion develops through three phases: osteolytic; cementoblastic; and mature. Radiologically, the appearance of the lesion thus depends on the moment of observation. In the first or osteolytic phase, a circular radiolucent lesion is visible at the apex of the root; in the second or cementoblastic stage, cementoblastic activity increases and, consequently, spicules of cement begin to form, so that the radiolucent lesion assumes a mixed appearance. The final or mature stage gives rise to a completely radiopaque lesion (5, 6, 10, 11). The lesion becomes a calcified mass that can reach 10 cm in diameter, and is often surrounded by a radiolucent halo. This evolution may take months or years, and during its development, the diameter of the lesion increases from 0.2 cm

Correspondence to: Francesca Angiero, Department of Surgical Sciences and Integrated Diagnostics, University of Genoa, Largo Rosanna Benzi 10, Pad IV, 16132, Genova, Italy. Tel: +39 0103537309, Mob: +39 3356310060, e-mail: f.angiero@teos.it

Key Words: Cemento-osseous dysplasia, cementoma, jaw neoplasms, mandible.

to 10 cm or more. The average diameter at the time of first radiological examination has been given as 1.8 cm (3, 4).

Diagnosis of periapical COD can be formulated on the basis of the lesion's typical histopathological and clinical characteristics. Commonly, no treatment is required and only regular follow-up examinations are advised (7). This report describes a case of periapical COD and discusses differential diagnosis.

Case Report

A 55-year-old white Caucasian woman was referred for evaluation of the mobility of teeth 32-33-34. Intraoral examination showed that the maxilla was completely edentulous; the mandible contained only six teeth: 42 to 34.

The intraoral radiograph of the area 32-33-34 showed deep periodontal pockets and mobility; it was thus decided to extract these three teeth (Figure 1). Depending on the patient's preference, a mandibular overdenture could later be provided.

Post-extraction healing was particularly slow, with slight but persistent swelling, limited to the area around 32-33-34. Further investigations were decided: Ortopantomography (Figure 2), followed by cone-beam computed tomography; these revealed a large area of calcified dysplasia, oval in shape, the longer axis being 3 cm, extending from the root-apex of the teeth to the inferior underlying mandibular cortical bone. A targeted bone biopsy was thus planned, at the Department of Oral Pathology. A bone 'carrot' of uniform tissue was extracted from the area and sent for histopathogical evaluation; a diagnosis of periapical COD was rendered: The patient entered a six-monthly follow-up program, later reduced to annual checkups. At the 12-month checkup, a computed tomographic scan showed the lesion was unchanged in size. The remaining teeth in the adjacent region had meanwhile fractured. However, since the condition of the roots was good it was decided to maintain them, and construct an overdenture supported by ball-attachments.

Histopathology. Biopsy specimens were sent to the Department of Oral Pathology, where sections were cut and prepared conventionally, and stained with hematoxylin and eosin. Histological examination revealed multiple small fragments of cementum-like substances characterized by islands of calcified deposits and areas of loose fibro-collagenous stroma (Figure 3); the latter showed evidence of proliferation. The cementum-like substances were mainly acellular in structure; there were no signs of free hemorrhage or osteoclastic activity. A definitive diagnosis of COD was established by means of histopathological examination combined with the radiographic findings, which showed multiple radiolucent and radiopaque lesions in the mandibular teeth. The definitive diagnosis for this case was periapical COD.

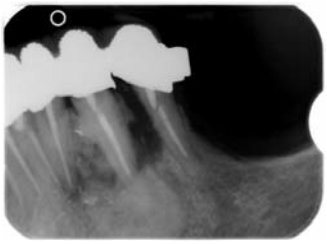

Figure 1. *Periapical radiograph showing multiple and radiopaque radiolucent pattern at the apices of mandibular teeth.*

Discussion

Cemento-osseous lesions are a complex group of lesions of similar histological appearance. They often pose a diagnostic challenge, and diagnosis must be based on clinical, radiographic, and histological features. The lesions differ in their clinical manifestations and biological behavior, and should, thus, be managed by different approaches. This makes differential diagnosis especially important, and in our view it should also include other bone diseases having similar features but requiring completely different treatment. Periapical COD must be differentiated from Paget's disease (12), chronic diffuse osteomyelitis (13), and cementoma (14). Paget's disease is polyostotic, and is associated with raised alkaline phosphatase levels, which are not a consistent feature of periapical COD. Chronic diffuse sclerosing osteomyelitis is not confined to tooth-bearing areas; it is a primary inflammatory condition of the mandible, with cyclic episodes of unilateral pain and swelling. The affected lesion of the mandible exhibits a diffuse opacity with poorly-defined borders (13). The cementoma presents radiographically as a well-defined radiopaque dense mass, with a radiolucent margin, enveloping the root of a tooth that usually shows signs of resorption and fusion with the lesion.

In some cases, the radiographic image can be misinterpreted as an infection of endodontic origin, and thus mismanaged (15). In their early stages, lesions may be misidentified as a form of periapical rarefying osteitis, for example as a periapical abscess, granuloma, or cyst, and in these cases unnecessary endodontic treatment may be performed (15). Vitality tests are thus especially important for differential diagnosis, to clarify any possible doubt.

The therapeutic approach to periapical COD is conservative, and consists of periodic clinical and radiographic check-ups (16); it has been suggested that resection of the lesion may be reserved for cases with an obvious state of chronic inflammation, or those that are characterized by repeated abscesses, which may involve the risk of developing chronic sclerosing osteomyelitis.

The symptoms usually start with signs of inflammation; in these cases, the tooth can be managed endodontically.

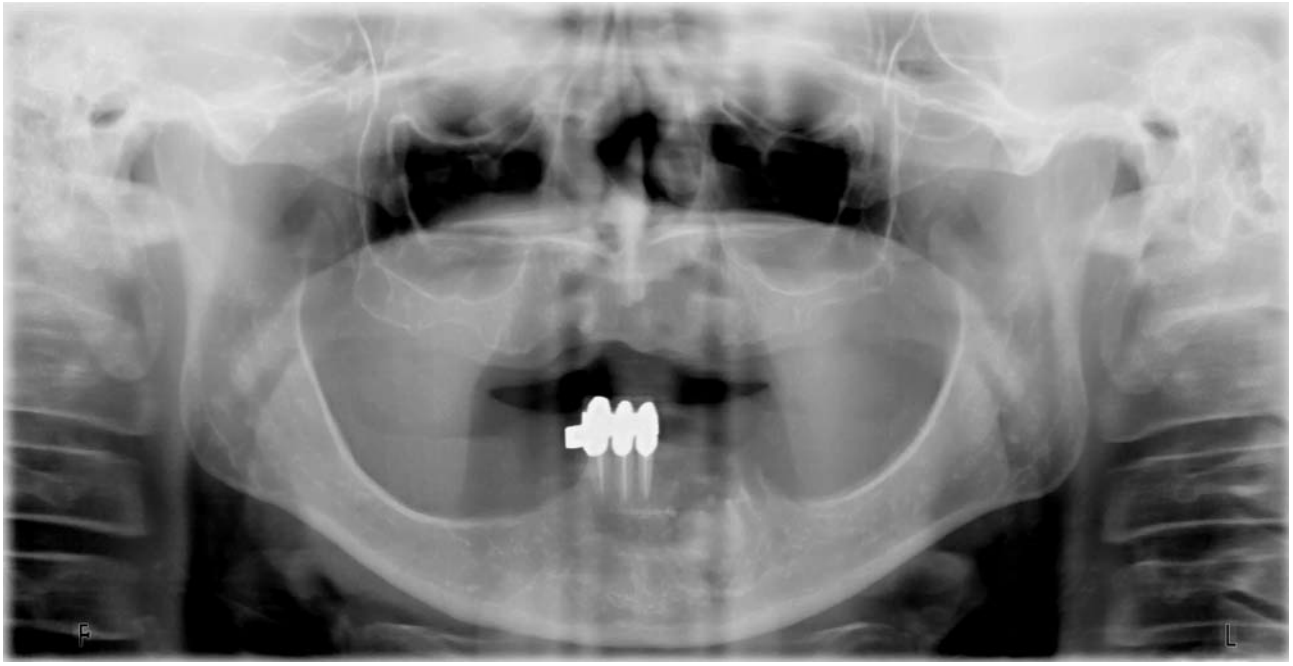

Figure 2. *Later stage of the lesion exhibiting significant mineralization.*

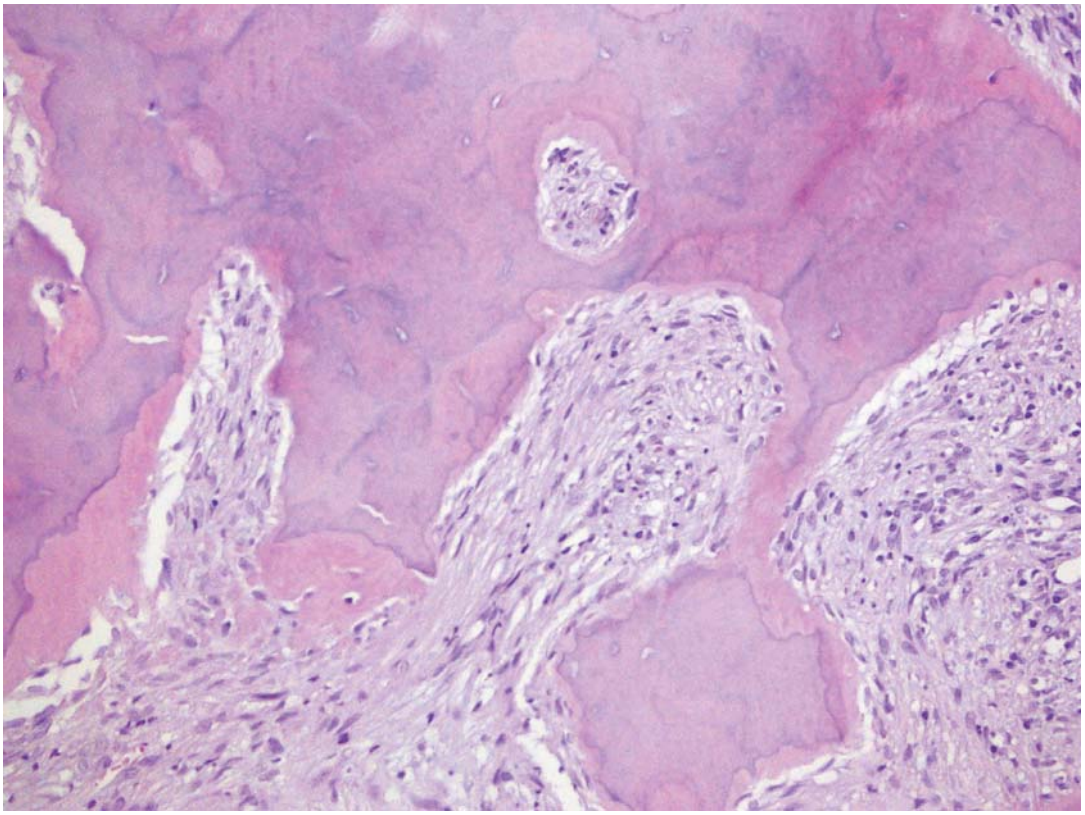

Figure 3. *Histology at a later stage of the lesion showing sclerotic mass of cemento-osseous material (hematoxylin-eosin stain, original magnification,×100).*

Extraction is usually not recommended, due to poor socket healing because of impaired blood circulation in the affected bone area. Extensive surgical resection and saucerization have been proposed as treatment options when lesions become extensive and symptomatic (11). In the case reported here, the approach taken was surgical. The mobility of teeth, the severe periodontitis, the persistence of signs of inflammation, and the slight pain reported by the patient, lead us to extract the three teeth involved; the subsequent persistence of swelling then indicated a biopsy should be taken, and this established the diagnosis.

Diagnosis was challenging, both because the teeth had been devitalized, and thus the vitality test was inapplicable, and because the apical lesions presented signs of apicopathy, and were undistinguishable from other types of apical lesion. Diagnosis was established on the basis of persistence of swelling, as well as radiographic and microscopic appearance. With regard to prosthetic rehabilitation, in areas affected by periapical COD, the bone quality is generally insufficient for implant insertion. High bone density combined with poor bone vascularization makes even the slightest surgical maneuver inappropriate, because of the risk of delayed healing or even necrosis (theoretically this also applies to bone biopsy; it certainly does to implant insertion). It was, thus, decided to construct an overdenture supported by ball-attachments.

In conclusion, the combined analysis of clinical, radiological, and histological features, in the framework of correct differential diagnosis, enabled a diagnosis of periapical COD to be formulated.

References

1 Beylouni I, Farge P, Mazoyer JF and Coudert JL: Florid cemento-osseous dysplasia: report of a case documented with computed tomography and 3D imaging. Oral Surg Oral Med Oral Pathol Oral Radiol Endod *85*: 707-711, 1998.

2 Kramer IR, Pindborg JJ and Shear M: The WHO histological typing of odontogenic tumours. A commentary on the second edition. Cancer *70*: 2988-2994, 1992.

3 MacDonald-Jankowski DS: Florid cemento-osseous dysplasia: A systematic review. Dentomaxillofac Radiol *32*: 141-149, 2003.

4 Kawai T, Hiranuma H, Kishino M, Jikko A, Sakuda M: Cemento-osseous dysplasia of the jaws in 54 Japanese patients: a radiographic study. Oral Surg Oral Med Oral Pathol Oral Radiol Endod *87*: 107-114, 1999.

5 Komabayashi T and Zhu Q: Cemento-osseous dysplasia in an elderly Asian male: a case report. J Oral Sci *53*: 117-120, 2011.

6 Summerlin DJ and Tomich CE: Focal cemento-osseous dysplasia: a clinicopathologic study of 221 cases. Oral Surg Oral Med Oral Pathol *78*: 611-620, 1994.

7 Su L, Weathers DR and Waldron CA: Distinguishing features of focal cemento-osseous dysplasia and cemento-ossifying fibromas. II. A clinical and radiologic spectrum of 316 cases. Oral Surg Oral Med Oral Pathol Oral Radiol Endod *84*: 540-549, 1997.

8 Manganaro AM and Millett GV: Periapical cemental dysplasia. Gen Dent *44(4)*: 336-339, 1996.

9 Eskandarloo A and Yousefi F: CBCT findings of periapical cemento-osseous dysplasia: A case report. Imaging Sci Dent *43(3)*: 215-218, 2013.

10 Scholl RJ, Kellett HM, Neumann DP and Lurie AG: Radiographics. Cysts and cystic lesions of the mandible: clinical and radiologic-histopathologic review. Radiographics *19(5)*: 1107-1124, 1999.

11 Ariji Y, Ariji E, Higuchi Y, Kubo S, Nakayama E and Kanda S: Florid cemento-osseous dysplasia. Radiographic study with special emphasis on computed tomography. Oral Surg Oral Med Oral Pathol *78*: 391-396, 1994.

12 Loh FC and Yeo JF: Florid cemento-osseous dysplasia in Orientals. Oral Surg Oral Med Oral Pathol *68*: 748-753, 1989.

13 Alawi F: Benign fibro-osseous diseases of the maxillofacial bones. Am J Clin Pathol *118(Suppl)*: S50-70, 2002.

14 Konopka W, Smiechura M, Strużycka M, Kozakiewicz M and Dzieniecka M: Ossifying fibroma-cementoma of jaw. Differences in histopathological nomenclature. Otolaryngol Pol *66(5)*: 359-362, 2012.

15 Kutluay Köklü H, Cankal DA, Bozkaya S, Ergün G and Bar E: Florid cemento-osseous dysplasia: Report of a case documented with clinical, radiographic, biochemical and histological findings. J Clin Exp Dent *1;5(1)*: e58-61, 2013.

16 DiFiore PM and Bowen SE: Cemento-osseous dysplasia in African-American men: a report of two clinical cases. J Tenn Dent Assoc *90*: 26-29, 2010.

Received February 17, 2014
Revised March 11, 2014
Accepted March 12, 2014