# Accumulation of FGF9 in Prostate Cancer Correlates with Epithelial-to-Mesenchymal Transition and Induction of VEGF-A Expression

JUN TEISHIMA, SHIGEKI YANO, KOICHI SHOJI, TETSUTARO HAYASHI, KEISUKE GOTO, HIROYUKI KITANO, KIYOTAKA OKA, HIROTAKA NAGAMATSU and AKIO MATSUBARA

*Department of Urology, Institute of Biomedical & Health Sciences, Integrated Health Sciences, Hiroshima University, Hiroshima, Japan*

**Abstract.** *Aim: The aim of the present study was to investigate the molecular mechanism of fibroblast growth factor (FGF)-9 in prostate cancer cells. Materials and Methods: Expression of vascular endothelial growth factor (VEGF)s and cadherins in LNCaP cells by incubation with FGF9 was assessed by western blot analysis. Tissues obtained during a radical prostatectomy in 88 patients were immunohistochemically-stained using anti-FGF9, anti-cadherin, and anti-VEGF antibodies. Results: Expression of N-cadherin and VEGF-A were induced in LNCaP cells incubated in FGF9-containing medium. The biochemical relapse-free survival rate in cases with FGF9, N-cadherin and VEGF-A-positive cells was significantly lower than the rate in cases where positive cells were not detectable. The prevalence of both VEGF-A- and N-cadherin-positive cells in the sample with FGF9-positive cells were significantly higher in comparison to FGF9-negative cases. Conclusion: FGF9 can be associated with epithelial-to-mesenchymal transition and invasion by inducing VEGF-A expression in prostate cancer cells.*

Epithelial-stromal interaction through fibroblast growth factor (FGF)s signaling has been reported to be a crucial molecular mechanism for homeostasis in prostate tissue, and its disruption causes cancer development (1, 2). Among these factors, FGF9 has been reported to enhance proliferation of prostate epithelial cells (3). FGF9 has been also shown to be involved in the progression of several malignant diseases (4-7). The current study demonstrates that in prostate cancer, FGF9 plays an important role in the progression of androgen receptor-negative cancer cells beyond the formation of bone metastasis (8). Furthermore, we previously demonstrated that FGF9 enhances proliferation and invasiveness in prostate cancer cells *in vitro* and the presence of FGF9-positive cancer cells shows a positive correlation with postoperative recurrence in prostate cancer (9). Although the data of this study indicated that FGF9 might have a crucial role for the components of cancer cells in tissues of localized prostate cancer, the molecular mechanism of FGF9 in such conditions has been scarcely investigated.

Prostate cancer is one of the most common malignant neoplasms among men, and is the second leading cause of male death from cancer in the United States (10). Although radical prostatectomy is the standard treatment option for clinically-localized prostate cancer worldwide, including Japan, postoperative recurrence is not uncommon. Elucidating the molecular mechanism and thus identifying novel predictive factors for postoperative recurrence is a key issue in prostate cancer research. The objectives of our study were to clarify the molecular mechanism of FGF9 involvement on the progression of prostate cancer cells both *in vitro* and *in vivo*.

## Materials and Methods

*Cell culture.* LNCaP cells were purchased from the American Type Culture Collection (Manassas, VA, USA), and maintained in RPMI1640 medium supplemented with 10% heat-inactivated FBS (Life Technologies, NY, USA). The cells were maintained at 37˚C in a humidified atmosphere of 5% $CO_2$/95% air. Media were changed every 48 h.

*Western blot analysis.* Western blot analysis was performed as described previously (9, 11). To examine whether FGF9 induces vascular endothelial growth factors (VEGFs) and cadherins, cells were cultured RPMI1640 medium containing 0.2% charcoal-

*Correspondence to:* Jun Teishima, Department of Urology, Institute of Biomedical & Health Sciences, Integrated Health Sciences, Hiroshima University 1-2-3 Kasumi, Minamiku, Hiroshima 734-8551, Japan. Tel: +81 822575242, Fax: +81 822575244, e-mail: teishima@hiroshima-u.ac.jp

*Key Words:* FGF9, prostate cancer, VEGF-A, N-cadherin, epithelial-mesenchymal transition, biochemical recurrence, radical prostatectomy.

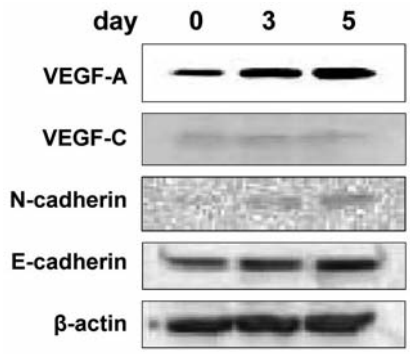


Figure 1. *Vascular endothelial growth factors (VEGFs) and cadherin expression were determined by western blotting. Expression of VEGF-A and N-cadherin were enhanced in LNCaP cells after treatment with fibroblast growth factor 9 (FGF9) for 3 and 5 days.*

stripped FBS for 24 h and were incubated in media containing or in absence of FGF9 (100 ng/ml), for 3 and 5 days. Cells were scraped in a Tris-Glysine SDS sample buffer (Invitrogen, Carlsbad, CA, USA). Supernatant protein was electrophoresed on sodium dodecylsulfate-polyacrylamide gel electrophoresis (SDS-PAGE) gels and electrotransferred on nitrocellulose filter. Filters were incubated for 1 h at room temperature with anti-VEGF-A, anti-VEGF-C, anti-E-cadherin, and anti-N-cadherin antibodies (Santa Cruz Biotechnology, Santa Cruz, CA, USA), and peroxidase-conjugated anti-mouse or anti-rabbit IgG (Santa Cruz Biotechnology, Santa Cruz, CA, USA) were used in the secondary reaction. Immunocomplexes were visualized with an ECL western blot detection system (Amersham Biosciences, Piscataway, NJ), and β-actin (SIGMA, St. Louis, MO) was also stained as a loading control.

*Immunohistochemistry staining*. Samples were obtained from tissue resected during radical prostatectomy due to a diagnosis of prostate cancer with no prior therapy. All human tissues have been used after obtaining consent from each patient, and we followed the relevant ethics procedures of our institute. All sections were from formalin-fixed, paraffin-embedded tissue specimens. Samples derived from one representative section in every tissue were stained with anti-N-cadherin, anti-VEGF-A, or anti-FGF9 antibody (R&D Systems, Minneapolis, MN, USA).

Immunohistochemical analysis was performed with a Dako Envision+ Mouse Peroxidase Detection System (Dako Cytomation, Carpinteria, CA), as described previously (7-9). The sections were de-paraffinized in xylene prior to rehydration in 100, 70 and 50% ethanol and finally water. Endogenous peroxidase activity was blocked with 3% hydrogen peroxide-methanol, and the slides were placed in water prior to antigen retrieval using a microwave in a 0.01-M citrate buffer (pH 6) for 20 min. The sections were placed in normal goat serum (Dako Cytomation) for 1 h to block non-specific antibody binding sites. The primary antibodies were diluted to a ratio of 1:200 then applied to the sections and incubated at 4˚C overnight. The sections were then washed in PBS before incubation with peroxidase-labeled anti-goat or mouse IgG (Dako Cytomation, Carpinteria, CA, USA) for 1 h at room temperature. The sections were washed in PBS, immunoreactivity was visualized using a Dako Envision kit (Dako Cytomation, Carpinteria, CA, USA) in accordance with the manufacturer's instructions, and then counterstained with Harris hematoxylin, before dehydration with graded ethanol and xylene prior to being mounted to a cover slide. When cancer cells with an accumulation of N-cadherin, VEGF-A or FGF9 in cytoplasm were detected, the cases were defined as 'positive'. All slides were read independently by two investigators and classified in accordance with the presence of N-cadherin-, VEGF-A- or FGF9- positive cells. The relationships between the positivity of these molecules and pathological features or clinical course were elucidated.

*Definition of biochemical relapse*. The ECLIA method (Roche Diagnostics, Tokyo, Japan) was used to test for serum PSA in every patient who had a radical prostatectomy, and biochemical relapse was defined when serum PSA elevated to higher than 0.2 ng/ml. If serum PSA did not decline to lower than 0.2 ng/ml, the time of biochemical relapse was defined as the day of operation.

*Statistical analysis*. The involvement of N-cadherin immunohistochemical staining of FGF9, N-cadherin, and VEGF-A with clinicopathological findings or biochemical relapse-free survival rate were analyzed using the Chi-squared test and Log-rank test, respectively. All statistical analyses were conducted using the StatView 5.0 software package. A $p$-value of less than 0.05 was considered statistically significant.

## Results

*FGF9 Induces VEGF-A and N-cadherin expression in androgen-dependent prostate cancer cells*. Previous studies have demonstrated the involvement of FGF9 to invasiveness in several cancers and the expression of FGF9 in mesenchymal tissues (6, 7-9). Thus, we investigated the effects of FGF9 on molecules related to cell invasion, metastasis, and epithelial-to-mesenchymal transition (EMT). Immunoblotting studies were conducted using LNCaP cells incubated in medium including FGF9 with high concentration for 3 and 5 days, respectively. The results showed that expression of VEGF-A and N-cadherin were induced by treatment with recombinant FGF9 for 3 and 5 days while there was no change in the expression of VEGF-C and E-cadherin (Figure 1).

*Presence of FGF9-positive cells correlated with positive immunostaining with VEGF-A and N-Cadherin in prostate cancer tissues*. Eighty-eight samples from patients with no prior therapy, who had undergone radical prostatectomy due to diagnosis of prostate cancer were examined by immunohistochemical staining for FGF9, VEGF-A and N-cadherin. Representative findings are presented in Figure 2. The immunoreactivity of FGF9, N-cadherin, and VEGF-A were detected in the cytoplasm in 16 (18.2%), 32 (36.4%) and 41 (46.6%) samples, respectively. The relationship between clinicopathological findings and the positivity of N-cadherin and VEGF-A is shown in Table I. The prevalence

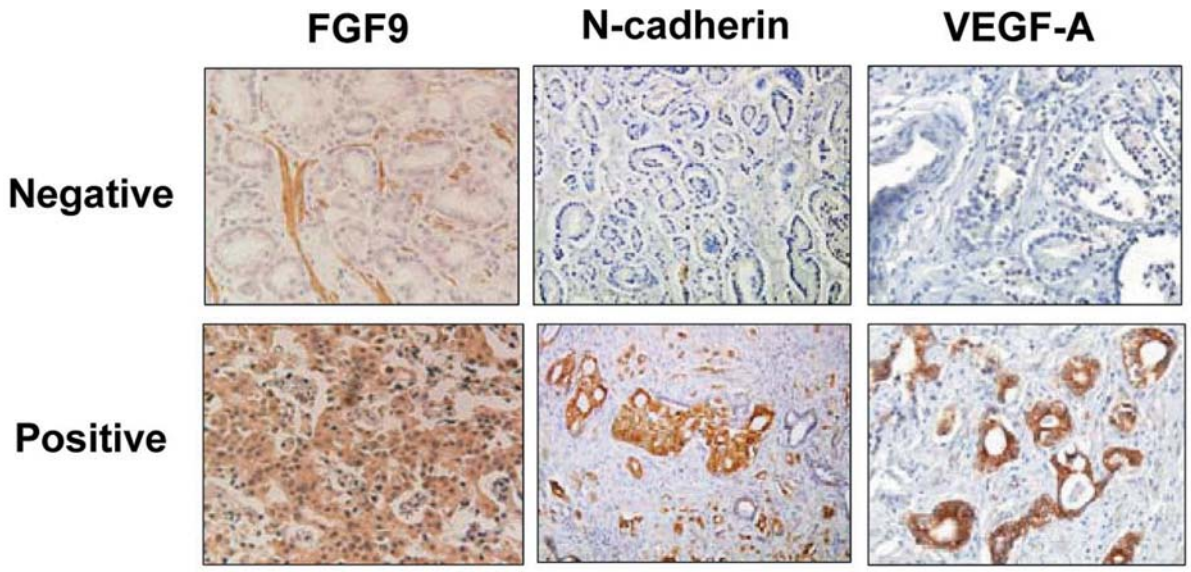


Figure 2. *Representative findings of immunohistochemical staining with anti-FGF9, anti-N-cadherin and anti-VEGF-A antibody in human prostate specimen obtained from radical prostatectomies. Upper and lower panels show negative and positive findings, respectively. Original magnification, ×200.*

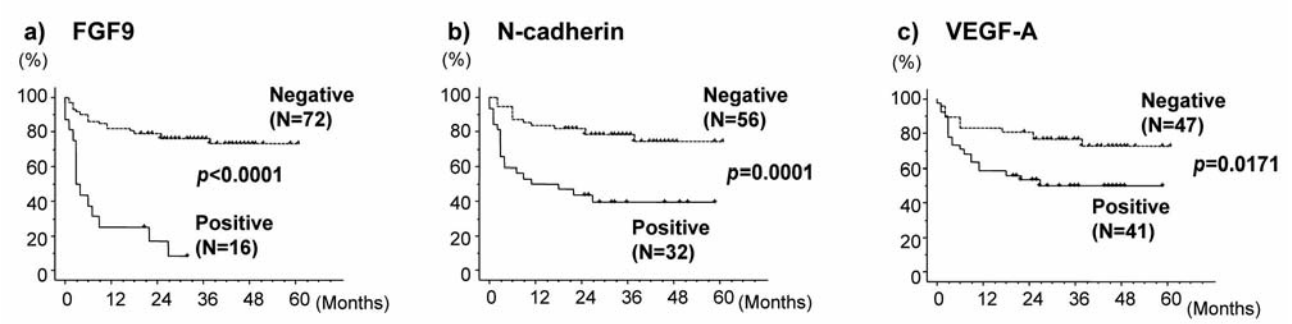


Figure 3. *Prognostic value of FGF9, N-cadherin and VEGF-A staining. Biochemical relapse-free survival (PFS) of 88 patients with prostate cancer who underwent radical prostatectomy based on the existence of a) FGF9-positive tissues, b) N-cadherin-positive tissues, and c) VEGF-A-positive tissues, respectively. p-values were determined by the log-rank test.*

of FGF9-positive cells were significantly higher in cases diagnosed with a high Gleason score, with seminal vesicle invasion or those with high serum PSA levels in comparison to other cases. We detected VEGF-A-positive cells in cases with positive surgical margins or with seminal vesicle invasion, and N-cadherin-positive cells were detected in cases with high serum PSA levels, with a high Gleason score, capsular invasion, or with seminal vesicle invasion that was significantly more frequent than the other cases, respectively. The 2-year biochemical relapse-free survival rate was 16.7%, 43.8% and 53.4% in cases with FGF9, N-cadherin, and VEGF-A-positive cells, which was significantly lower than that in cases in which positive cells were not detectable (79.2%, $p<0.0001$, 82.1%, $p=0.0001$, and 80.9%, $p=0.0171$, respectively) (Figure 3).

The relationship between the positivity of VEGF-A or N-cadherin and that of FGF9-positive cells in prostate tissue is shown in Table II. The prevalence of FGF9-positive cells was significantly higher in VEGF-A-, or N-cadherin- positive cases than in the cases where VEGF-A or N-cadherin were negative.

## Discussion

Several studies have investigated on the molecular mechanism of FGF9 in cancer cells. FGF9 is a downstream target of the Wnt signaling pathway in ovarian endometrioid adenocarcinoma (5). Lung cancer shows acceleration of tumor growth by aryl hydrocarbon receptor through up-regulation of the FGF9 expression aryl hydrocarbon receptor (6). Besides these reports, our study

Table I. *Relationship between clinicopathological findings and rates of FGF9, N-cadherin and VEGF-A-positive tissues.*

| Variables | n | NCad-positive (%) | *p*-Value | VEGF-A-positive (%) | *p*-Value |
|---|---|---|---|---|---|
| Age | | | 0.9352 | | 0.5762 |
| 70> | 50 | 18 (36.0) | | 22 (44.0) | |
| 70≤ | 38 | 14 (36.8) | | 19 (50.0) | |
| PSA (ng/mL) | | | 0.0074 | | 0.2257 |
| ≤20 | 77 | 24 (31.2) | | 34 (44.2) | |
| 20< | 11 | 8 (72.7) | | 7 (63.6) | |
| Gleason score | | | 0.0335 | | 0.0669 |
| 7≥ | 64 | 19 (29.7) | | 26 (40.6) | |
| 8≤ | 24 | 13 (54.2) | | 15 (62.5) | |
| Capsular invasion | | | 0.0431 | | 0.2579 |
| Negative | 40 | 10 (25.0) | | 16 (40.0) | |
| Positive | 48 | 22 (45.8) | | 25 (52.1) | |
| Margin status | | | 0.1836 | | 0.0187 |
| Negative | 44 | 13 (29.5) | | 15 (34.1) | |
| Positive | 44 | 19 (43.2) | | 26 (59.1) | |
| Venous invasion | | | 0.4719 | | 0.3071 |
| Negative | 82 | 3 (3.7) | | 37 (45.1) | |
| Positive | 6 | 3 (50.0) | | 4 (66.7) | |
| Lymphovascular invasion | | | 0.7721 | | 0.7121 |
| Negative | 54 | 19 (35.2) | | 26 (48.1) | |
| Positive | 34 | 13 (38.2) | | 15 (44.1) | |
| Perineural invasion | | | 0.7470 | | 0.5401 |
| Negative | 46 | 16 (34.8) | | 20 (43.5) | |
| Positive | 42 | 16 (38.1) | | 21 (50.0) | |
| Seminal vesicle invasion | | | 0.0023 | | 0.0245 |
| Negative | 78 | 24 (30.8) | | 33 (42.3) | |
| Positive | 10 | 8 (80.0) | | 8 (80.0) | |

showed that FGF9 induces N-cadherin and VEGF-A expression in prostate cancer cell lines, and the prevalence of both N-cadherin and VEGF-A-positive cells were significantly higher in FGF9-positive cases. This indicates that FGF9 can be associated with EMT, proliferation and invasion by inducing VEGF-A expression in prostate cancer cells. To the best of our knowledge, the present study is the first report to show that FGF9 is associated with the expression of N-cadherin and VEGF-A in prostate cancer both *in vitro* and *in vivo*.

The relationship between increased expression of N-cadherin, a mesenchymal cadherin associated with EMT, and prostate cancer progression has been demonstrated. The expression of N-cadherin in human prostate cancer was associated with pelvic lymph node and bone metastasis (12), and it was also shown in castration-resistant prostate cancer (CRPC) cell lines and in clinical samples and CRPC (13, 14). Up-regulation of N-cadherin has been shown in prostate cancer tissues with a high Gleason score (15) and with poorly differentiated components (16, 17). A previous study has shown that measurement of expression levels of molecular markers implicated in EMT enabled more accurate prediction of the biochemical recurrence after radical prostatectomy (18).

Table II. *Relationship between positivity of VEGF-A or N-cadherin and prevalence of FGF9-positive tissues*

| Variables | n | FGF9-positive (%) | *p*-Value |
|---|---|---|---|
| VEGF-A | | | <0.0001 |
| Negative | 47 | 2 (4.3) | |
| Positive | 41 | 14 (34.1) | |
| N-cadherin | | | <0.0001 |
| Negative | 56 | 2 (3.6) | |
| Positive | 32 | 14 (43.8) | |

The finding of these reports were consistent with our present data that the rate of the cases with high PSA, with a high Gleason score or with seminal vesicle invasion were significantly higher than those in the other cases (Table I) and that in the previous study reported the expression of FGF9 as a predictive factor for postoperative recurrence (9). N-cadherin caused invasion, metastasis and castration resistance, and monoclonal antibody for N-cadherin suppressed these effects (14). This report suggests the possibility of the clinical benefit from therapeutic targeting of N-cadherin. From these reports,

EMT, including increased expression of N-cadherin is thought to be one of the most crucial molecular mechanisms in the progression of prostate cancer. In the present study, after incubation in a medium with FGF9, expression of N-cadherin was induced in LNCaP cells, and the rate of N-cadherin-positive tissues were significantly higher in patients with FGF9-positive tissues in immunohistochemical staining for prostate cancer tissues. These data indicate the possibility that FGF9 might promote cell proliferation and invasiveness through EMT in prostate cancer cells.

EMT enhances the potential of invasion and metastasis in cancer cells, and N-cadherin promotes angiogenesis through enhancement of P13K/Akt signaling in prostate cancer cells (19). The VEGF family is one of the most representative families involved in invasion through promoting angiogenesis. Previous studies have demonstrated on crucial roles of VEGF-axis in progression of prostate cancer. Up-regulation of VEGF-A and the involvement of VEGF-A with angiogenesis in prostate cancer cells have been shown (20, 21). Activation of VEGF receptor (VEGFR)-1 by VEGF-A in cancer cells and activation of VEGFR-3 by VEGF-D in lymphatic endothelial cells were reported as important signaling mechanisms involved in the progression and metastasis of prostate cancer (22). Prostate cancer growth is required for sufficient blood supply which is controlled by VEGFs, and VEGF expression and tumor angiogenesis are regulated by androgens in human hormone-naïve prostate cancer (23). In addition, increased expression of VEGF and its polymorphism as a predictive factor for progression-free survival has been shown in castration-resistant prostate cancer (CRPC) (24, 25).

As shown in Figure 1, VEGF-A expression was induced in prostate cancer cell lines after incubation in medium with FGF9, and FGF9 has been reported as a regulator of VEGF-A expression in the development of the pulmonary capillary network (26), and as a key molecule for angiogenesis in long bone repair. Our data was consistent with these results, which indicates that FGF9 might also be associated with VEGF-A expression in the prostate cancer.

Immunohistochemical staining of FGF9, N-cadherin, and VEGF-A in prostate cancer cells, as determined in clinical samples obtained from radical prostatectomy, revealed that the detective rates of N-cadherin and VEGF-A-positive cells in FGF9-positive cases were significantly higher than those in FGF9-negative cases (Table II). Cases with components positively-stained to these three molecules showed higher rates of biochemical relapse compared to other cases (Figure 3). Previous studies have shown that the existence of small components with tertiary Gleason grade 5 patterns in radical prostatectomy specimens with Gleason score 7 is a powerful predictive factor of postoperative recurrence (27, 28). Another study (11) has indicated that a small population of cells with aggressive pathological feature plays a crucial role in the postoperative recurrence of prostate cancer. According to our previous data, the presence of the small area consisted of FGF9-positive cells is an independent prognostic marker for postoperative recurrence. Our current data indicate that the components consisted of FGF9-positive cells which induced EMT and the expression of VEGF-A might promote recurrence after radical prostatectomy.

There are some limitations to the present study. Firstly, several studies have demonstrated significant differences between Japanese and Western populations regarding the characteristics of prostate cancer. Secondly, only 2 molecules, N-cadherin and VEGF-A, were investigated although the association of a lot of molecules has been reported in EMT or angiogenesis. Further experiments to clarify the molecular mechanism of FGF9 accumulated in prostate cancer cells for EMT and prospective studies with higher-number population are required to determine the best clinical applications for FGF9 and its related molecules.

In summary, the accumulation of FGF9 in prostate cancer cells was associated with EMT and the induction of VEGF-A, and these led to post-operative recurrence promotion. The present study presented crucial information on the molecular mechanisms of FGF9 involvement in prostate cancer cells for biochemical recurrence after radical prostatectomy.

## Conflicts of Interest

The Authors declare no conflict of interest.

## Acknowledgements

This work was carried out at the Analysis Center of Life Science, Hiroshima University.

## References

1 Wu X, Jin C, Wang F, Yu C and McKeehan WL: Stromal cell heterogeneity in fibroblast growth factor-mediated stromal-epithelial cell cross-talk in premalignant prostate tumors. Cancer Res *63*: 4936-4944, 2003.

2 Jin C, Wang F, Wu X, Yu C, Luo Y and McKeehan WL: Directionally specific paracrine communication mediated by epithelial FGF9 to stromal FGFR3 in two-compartment premalignant prostate tumors. Cancer Res *64*: 4555-4562, 2007.

3 Giri D, Ropiquet F and Ittmann M: FGF9 is an autocrine and paracrine prostatic growth factor expressed by prostatic stromal cells. J Cell Physiol *180*: 53-60, 1999.

4 Todo T, Kondo T, Kirino T, Asai A, Adams EF, Nakamura S, Ikeda K and Kurokawa T: Expression and growth stimulatory effect of fibroblast growth factor 9 in human brain tumors. Neurosurgery *43*: 337-346, 1998.

5 Hendrix ND, Wu R, Kuick R, Schwartz DR, Fearon ER and Cho KR: Ovarian ca wnt Fibroblast growth factor 9 has oncogenic activity and is a downstream target of Wnt signaling in ovarian endometrioid adenocarcinomas. Cancer Res *66*: 1354-1362, 2006.

6 Wang CK, Chang H, Chen PH, Chang JT, Kuo YC, Ko JL and Lin P: Aryl hydrocarbon receptor activation and overexpression upregulated fibroblast growth factor-9 in human lung adenocarcinomas. Int J Cancer *125*: 807-815, 2009.

7 Ueng TH, Chang YL, Tsai YY, Su JL, Chan PK, Shih JY, Lee YC, Ma YC and Kuo ML: Potential roles of fibroblast growth factor-9 in the benzo(a)pyrene-induced invasion *in vitro* and the metastasis of human lung adenocarcinoma. Arch Toxicol *84*: 651-660, 2010.

8 Li ZG, Mathew P, Yang J, Starbuck MW, Zurita AJ, Liu J, Sikes C, Multani AS, Efstathiou E, Lopez A, Wang J, Fanning TV, Prieto VG, Kundra V, Vazquez ES, Troncoso P, Raymond AK, Logothetis CJ, Lin SH, Maity S and Navone NM: Androgen receptor-negative human prostate cancer cells induce osteogenesis in mice through FGF9-mediated mechanisms. J Clin Invest *118*: 2697-2710, 2008.

9 Teishima J, Shoji K, Hayashi T, Miyamoto K, Ohara S and Matsubara A: Relationship between the localization of fibroblast growth factor 9 in prostate cancer cells and postoperative recurrence. Prostate Cancer Prostatic Dis *15*: 8-14, 2012.

10 Siegel R, Naishadham D and Jemal A: Cancer statistics, 2013. CA Cancer J Clin *63*: 11-30, 2013.

11 Ohara S, Oue N, Matsubara A, Mita K, Hasegawa Y, Hayashi T, Usui T, Amatya VJ, Takeshima Y, Kuniyasu H and Yasui W: Reg IV is an independent prognostic factor for relapse in patients with clinically localized prostate cancer. Cancer Sci *99*: 1570-1577, 2008.

12 Gravdal K, Halvorsen OJ, Haukaas SA and Akslen LA: A switch from E-cadherin to N-cadherin expression indicates epithelial to mesenchymal transition and is of strong and independent importance for the progress of prostate cancer. Clin Cancer Res *13*: 7003-7011, 2007.

13 Jennbacken K, Gustavsson H, Welén K, Vallbo C and Damber JE: Prostate cancer progression into androgen independency is associated with alterations in cell adhesion and invasivity. Prostate *66*: 1631-1640, 2006.

14 Tanaka H, Kono E, Tran CP, Miyazaki H, Yamashiro J, Shimomura T, Fazli L, Wada R, Huang J, Vessella RL, An J, Horvath S, Gleave M, Rettig MB, Wainberg ZA and Reiter RE: Monoclonal antibody targeting of N-cadherin inhibits prostate cancer growth, metastasis and castration resistance. Nat Med *16*: 1414-1420, 2010.

15 Jaggi M, Nazemi T, Abrahams NA, Baker JJ, Galich A, Smith LM and Balaji KC: N-cadherin switching occurs in high Gleason grade prostate cancer. Prostate *66*: 193-199, 2006.

16 Bussemakers MJ, van Moorselaar RJ, Giroldi LA, Ichikawa T, Isaacs JT, Takeichi M, Debruyne FM and Schalken JA: Decreased expression of E-cadherin in the progression of rat prostatic cancer. Cancer Res *52*: 2916-2922, 1992.

17 Tomita K, van Bokhoven A, van Leenders GJ, Ruijter ET, Jansen CF, Bussemakers MJ and Schalken JA: Cadherin switching in human prostate cancer progression. Cancer Res *60*: 3650-3654, 2000.

18 Derycke L, De Wever O, Stove V, Vanhoecke B, Delanghe J, Depypere H and Bracke M: Soluble N-cadherin in human biological fluids. Int J Cancer *119*: 2895-2900, 2006.

19 Nalla AK, Estes N, Patel J and Rao JS. N-cadherin mediates angiogenesis by regulating monocyte chemoattractant protein-1 expression *via* PI3K/Akt signaling in prostate cancer cells. Exp Cell Res *317*: 2512-2521, 2011.

20 Jackson MW, Bentel JM and Tilley WD: Vascular endothelial growth factor (VEGF) expression in prostate cancer and benign prostatic hyperplasia. J Urol *157*: 2323-2328, 1997.

21 Borgström P, Bourdon MA, Hillan KJ, Sriramarao P and Ferrara N: Neutralizing anti-vascular endothelial growth factor antibody completely inhibits angiogenesis and growth of human prostate carcinoma micro tumors *in vivo*. Prostate *35*: 1-10, 1998.

22 Woollard DJ, Opeskin K, Coso S, Wu D, Baldwin ME and Williams ED: Differential expression of VEGF ligands and receptors in prostate cancer. Prostate *73*: 563-572, 2013.

23 Stewart RJ, Panigrahy D, Flynn E and Folkman J: Vascular endothelial growth factor expression and tumor angiogenesis are regulated by androgens in hormone responsive human prostate carcinoma: evidence for androgen dependent destabilization of vascular endothelial growth factor transcripts. J Urol *165*: 688-693, 2001.

24 Tomić TT, Gustavsson H, Wang W, Jennbacken K, Welén K and Damber JE: Castration resistant prostate cancer is associated with increased blood vessel stabilization and elevated levels of VEGF and Ang-2. Prostate *72*: 705-712, 2012.

25 Orlandi P, Fontana A, Fioravanti A, Di Desidero T, Galli L, Derosa L, Canu B, Marconcini R, Biasco E, Solini A, Francia G, Danesi R, Falcone A and Bocci G: VEGF-A polymorphisms predict progression-free survival among advanced castration-resistant prostate cancer patients treated with metronomic cyclophosphamide. Br J Cancer *109*: 957-964, 2013.

26 White AC, Lavine KJ and Ornitz DM: FGF9 and SHH regulate mesenchymal Vegfa expression and development of the pulmonary capillary network. Development *134*: 3743-3752, 2007.

27 Trock BJ, Guo CC, Gonzalgo ML, Magheli A, Loeb S and Epstein JI: Tertiary Gleason patterns and biochemical recurrence after prostatectomy: proposal for a modified Gleason scoring system. J Urol *182*: 1364-1370, 2009.

28 Hattab EM, Koch MO, Eble JN, Lin H and Cheng L: Tertiary Gleason pattern 5 is a powerful predictor of biochemical relapse in patients with Gleason score 7 prostatic adenocarcinoma. J Urol *175*: 1695-1699, 2006.


*Received December 30, 2013*
*Revised January 16, 2014*
*Accepted January 17, 2014*