Estrogen and Androgen Receptors in Inflammatory Fibroid Polyp (Vanek's Tumor): Case Report

ZORAN JUKIC[1], ZELJKO FERENCIC[2], PETRA RADULOVIC[3], AUGUST MIJIC[3] and ALEKSANDRA FUCIC[4]

[1]*General Hospital "Nova Gradiska", Nova Gradiska, Croatia;*
[2]*Children's Hospital "Srebrnjak", Zagreb, Croatia;*
[3]*Clinical Hospital Center "Sestre Milosrdnice", Zagreb, Croatia;*
[4]*Institute for Medical Research and Occupational Health, Zagreb, Croatia*

Abstract. *Background/Aim: Vanek's tumor is an inflammatory fibroid polyp (IFP) of very low incidence, which originates in the submucosa of the stomach, duodenum, jejunum and ileum. The etiology of this tumor is still unknown. Histologically, IFP is characterized by submucosal spindle cell proliferation in fibromyxoid stroma with inflammatory infiltrate. The aim of the present study was to investigate the presence of estrogen and androgen receptors in IFP and compare it with its proliferative loci. Patients and Methods: The study analyzed a 79-year-old patient suffering from IFP. Analyses were performed by immunohistochemistry. Results: Androgen-positive spindle cells were detected at the periphery of onion skin-like formations. Estrogen receptor-positive cells were not detected and Ki67 showed low proliferative activity. Conclusion: This case report shows for the first time the presence of androgen receptor-positive cells whose location corresponds with the distribution of Ki67-positive cells in IFP.*

Vanek's tumor is an inflammatory fibroid polyp (IFP) with a very low incidence of approximately 4.5% among all diagnosed stomach polyps (1, 2). It originates in the submucosa of the stomach, duodenum, jejunum and ileum (3, 4). It was first described in the stomach by Vanek in 1949 (5). The tumor has low mitotic activity and an absence of necrosis and metastasis (6). The most frequent symptoms are abdominal pain, weight loss, nausea, vomiting and upper gastrointestinal hemorrhage. The etiology of this tumor is still unknown. The incidence of Vanek's tumor with regard to gender differences seems to be similar. The majority of described cases include patients over the age of 50 (7, 8).

Histologically, Vanek's tumor is characterized by submucosal spindle cell proliferation in fibromyxoid stroma with inflammatory infiltrate. Spindle cells frequently form onion skin-like formations but this phenomenon only relates to the evolutional stage of the tumor (9). In some cases, multi-nucleated giant cells are also observed. The proliferating cells are immunohistochemically $CD34^-$ $CD35^-$, cyclin D- and vimentin-positive (6, 10, 11). However, the cell types and immunostaining vary. Treatment of Vanek's tumor is usually by means of surgical resection.

There is increased interest in the role of estrogen and testosterone in the physiology and pathology of the gastrointestinal system, which includes both genders. The significance of endocrine hormones in the pathology of the gastrointestinal system can also be seen in gender difference of gastric and colon cancer, as well as gastric and duodenal ulcer (12, 13). Estrogen and androgen-positive cells have been described in gastric and duodenal ulcer (14). Despite the fact that Vanek's tumor is a benign tumor, the aim of this case report was to determine the presence of estrogen and androgen receptor-positive cells and compare results with levels of Ki-67.

Patients and Methods

A 79-year-old man with a two-year history of epigastric pain followed by nausea without vomiting was admitted. He was suffering from inappetence and was quickly getting tired. During this period, he did not vary in weight, had regular bowel movements without pathological tinge and denied alcohol abuse and smoking. Two years earlier, he underwent surgery for prostate adenoma. Physical examination was unremarkable, as well as abdominal ultrasound, except for a thickened gallbladder wall with hyperechogenic luminal shadows that matched concretions. Due to the observed symptoms, gastroduodenal endoscopy was

Correspondence to: Aleksandra Fucic, Institute for Medical Research and Occupational Health, Ksaverska c 2, 10 000 Zagreb, Croatia. Tel: +385 14682500, Fax: +385 14673303, e-mail: afucic@imi.hr

Key Words: Vanek's tumor, inflammatory fibroid polyp, androgen receptor, estrogen receptor.

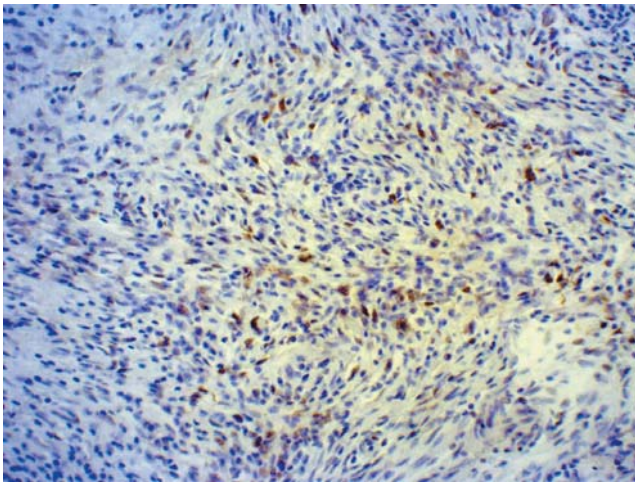

Figure 1. *Androgen receptor-positive cells in IFP (magnification, ×200).*

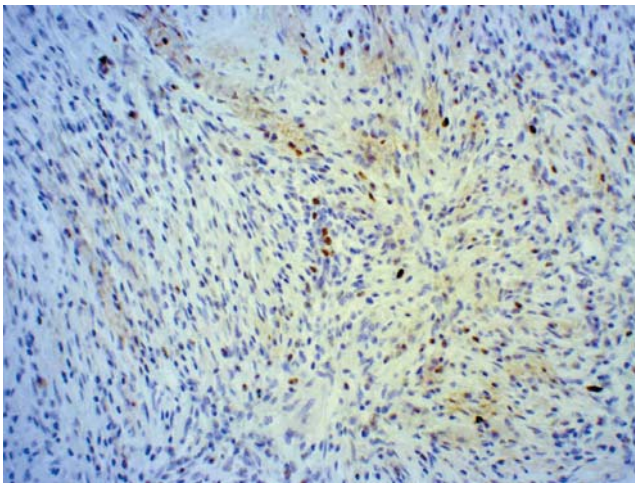

Figure 2. *Ki67-positive cells in IFP.*

performed. Insufficient closure of the cardia was found. The Z line was visible with clean surrounding mucosa. The lumen of the stomach was normal up to the antrum, where a prepiloric larger polyp was found on the stalk with a head diameter of about 2 cm which, during peristalsis, was pulled into the pylorus. Wrinkles were of orderly appearance. Mucosa was atrophic and hyperemic. Adrenaline in the amount of 1.5 ml was applied to the base of the polyp, which was then removed by diathermic loop and sent for histopathological analysis.

The resected tissue specimen was formalin-fixed, paraffin-embedded and cut on a microtome to form tissue sections (thickness 5 μm) that were stained with hematoxylin and eosin dye after deparaffinization. Immunohistochemical analyses were performed after tissue section deparaffinization following the microwave streptavidin immunoperoxidase (MSIP) protocol and using the labeled streptavidin-biotin (LSAB) method on a DAKO TechMate™ Horizon automated immunostainer (Dako, Denmark). Monoclonal antibodies raised against the estrogen receptor, androgen receptor and Ki67 (Dako, Denmark) were used. Immunoreactivity reactions were determined in stromal components at the site of strongest activity («hot spot») under magnification of ×400 for a total of 1,000 tumor cells. The «hot spot» was established upon the whole section inspection (magnification, ×40).

Results

Histological examination revealed a polypoid structure covered by gastric mucosa. The submucosal lesion was composed of concentric formations of proliferating spindle cells in fibromyxoid stroma with inflammatory infiltrate dominated by eosinophils and a few lymphoid follicles. Spindle cells were concentrically arranged around vessels. Immunohistochemically, stromal cells stained focally positive for androgen receptors and were negative for estrogen receptors (Figure 1). The proliferation index, measured by Ki67, was low (Figure 2).

Discussion

Vanek's tumor is a rare benign pseudotumoral formation similar to submucosal mesenchymal tumors that consists of fibroblast-like cells, inflammatory eosinophilic infiltrate, collagenous fibrils and abundant vasculature (6). The tumor varies in both cellularity and degree of vascularity. However, its characteristic features are perivascular onion skin-like forms, as well as the presence of eosinophils (15). It is a benign tumor that has been associated with gastric cancer only in rare instances (16). It is also characterized by cells with an over-expression of cyclin D1, dependent on testosterone levels, suggesting that a defect in cell-cycle regulation may be involved in its growth (17, 18).

In our case, androgen receptor-positive cells were found on the peripheral part of onion skin-like formations and corresponded with Ki67-positive cell distribution. Androgen receptor-positive spindle cells were suggested to be fibroblasts. Estrogen receptor-positive cells were not found in the tumor.

The etiology of Vanek's tumor is suggested to be vascular inflammation by proliferation of CD34-positive cells (9), which are also androgen-positive (19, 20).Another hypothesis is that Vanek's tumor is not reactive lesion but true benign neoplasm which has origin in the mutation of platelet-derived growth factor receptor α (*PDGFRα*) gene (21), and which has a role in fibroblast-like progenitor Leydig cell differentiation (22) up-regulating androgen receptor mRNA levels (23). In Vanek's tumour, *PDGFRa* exon 12 mutations are predominant in the small intestine, while exon 18 mutations occur frequently in the stomach (24, 25). Thus, the progression of Vanek's tumor shows similarities with progression of androgen sensitive prostate cancer dependent

on PDGF (26). Additionally, it is shown that PDGFR has role in the complex signalling pathways important in cancer pathogenesis and related with steroid hormones (27).

Estrogen and androgen receptors in gastric cancer correlate to the tumor expression profile, clinical and pathological parameters, as well as overall survival of patients (28). Estrogen is suggested to be a protective factor against gastric adenocarcinoma in women before their menopausal period (29). As Vanek's tumor seems to have a similar incidence in both genders and has been reported most frequently in the menopausal period, it could be speculated that its etiology may be related to a disturbance in testosterone levels, same as gastrointestinal malignancies are related to low testosterone levels (30).

Acknowledgements

This study was funded by the Croatian Ministry of Science, Education and Sports.

References

1 Stolte M and Finkenzeller G: Inflammatory fibroid polyp of the stomach. Endoscopy *22(5)*: 203-207, 1990.
2 Godey SK and Diggory RT: Inflammatory fibroid polyp of the oesophagus. World J Surg Onc *3*: 30, 2005.
3 Kordzadeh A: Vanek's tumour mimicking an acute appendicitis. Int J Surg Case Rep *2(8)*: 264-266, 2011.
4 Neishaboori H, Maleki I and Emadian O: Jejunal intussusception caused by a huge Vaneks' tumor: a case report. Gastroenterol Hepatol *6(4)*: 210-213, 2013.
5 Vanek J: Gastric submucosal granuloma with eosinophilic infiltration. Am J Pathol *25*: 397-411, 1949.
6 De Petris G, Leung ST: Pseudoneoplasms of the gastrointestinal tract. Arch Pathol Lab Med *134*: 378-391, 2010.
7 Yoon J-H: An inflammatory fibroid polyp (Vanek's tumor) of the ileum that presented as intussusception. Adv Comp Tomog *2*: 140-144, 2013.
8 Akbulut S: (2012) Intussusception due to inflammatory fibroid polyp: a case report and comprehensive literature review. World J Gastroenterol *18(40)*: 5745-5752, 2012.
9 Daum O, Hes O, Vanecek T, Benes Z, Sima R, Zamecnik M, Mukensnabl P, Hadravska S, Curik R and Michal M: Vanek's tumor (inflammatory fibroid polyp). Report of 18 cases and comparison with three cases of original Vanek's series Ann Diagn Pathol *7(6)*: 337-347, 2003.
10 Kolodziejczyk P, Yao T and Tsuneyoshi M: Inflammatory fibroid polyp of the stomach. A special reference to an immuno-histochemical profile of 42 cases. Am J Surg Pathol *17*: 1159-1168, 1993.
11 Wysocki AP, Taylor G and Windsor JA: Inflammatory fibroid polyps of the duodenum: a review of the literature. Dig Surg *24(3)*: 162-168, 2007.
12 Gavril L, Cotîrleţ A and Azoicai D: Clinical epidemiological characteristics of patients with gastric cancer in emergency Municipal Hospital Moinesti. Rev Med Chir Soc Med Nat Iasi *116(1)*: 2482-2453, 2012.
13 Eliakim R, Abulafia O and Sherer DM: Estrogen, progesterone and the gastrointestinal tract. J Reprod Med *45(10)*: 781-788, 2000.
14 Radulovic P, Fucic A, Mijic A and Kruslin B: Estrogen Receptor Positive Cells in Gastric and Duodenal Ulcer: a Pilot Study. Acta Clin Croat *51(1)*: 187-188, 2012.
15 Liu TC, Lin MT, Montgomery EA and Singhi AD: Inflammatory fibroid polyps of the gastrointestinal tract: spectrum of clinical, morphologic, and immunohistochemistry features. Am J Surg Pathol *37(4)*: 586-592, 2013.
16 Mucientes P, Mucientes F and Klaassen R: Inflammatory fibroid polyp associated with early gastric carcinoma: a case report. Ann Diagn Pathol *16(2)*: 148-151, 2012.
17 Pantanowitz L, Antonioli DA, Pinkus GS, Shahsafaei A and Odze RD: Inflammatory fibroid polyps of the gastrointestinal tract: evidence for a dendritic cell origin. Am J Surg Pathol *28(1)*: 107-114, 2004.
18 Gregory CW, Johnson RT Jr., Presnell SC, Mohler JL and French FS: Androgen receptor regulation of G1 cyclin and cyclin-dependent kinase function in the CWR22 human prostate cancer xenograft. J Androl *22(4)*: 537-548, 2001.
19 Khetawat G, Faraday N, Nealen ML, Vijayan KV, Bolton E, Noga SJ and Bray PF: Human megakaryocytes and platelets contain the estrogen receptor beta and androgen receptor (AR): testosterone regulates AR expression. Blood *95(7)*: 2289-2296, 2000.
20 Sinha-Hikim I, Taylor WE, Gonzalez-Cadavid NF, Zheng W and Bhasin S: Androgen receptor in human skeletal muscle and cultured muscle satellite cells: up-regulation by androgen treatment. J Clin Endocrinol Metab *89(10)*: 5245-5255, 2004.
21 Schildhaus H-U, Cavlar T, Binot E, Buttner R, Wardelmann E and Merkelbach-Bruse S: Inflammatory fibroid polyps harbour mutations in the platelet-derived growth factor receptor alpha (PDGFRA) gene. J Pathol *216(2)*: 176-182, 2008.
22 Landreh L, Stukenborg JB, Söder O and Svechnikov K: Phenotype and steroidogenic potential of PDGFRα-positive rat neonatal peritubular cells. Mol Cell Endocrinol *372(1-2)*: 96-104, 2013.
23 Lin MC, Rajfer J, Swerdloff RS and González-Cadavid NF: Testosterone down-regulates the levels of androgen receptor mRNA in smooth muscle cells from the rat corpora cavernosa via aromatization to estrogens. J Steroid Biochem Mol Biol *45(5)*: 333-343, 1993.
24 Huss S, Wardelmann E, Goltz D, Binot E, Hartmann W, Merkelbach-Bruse S, Büttner R and Schildhaus HU: Activating PDGFRA mutations in inflammatory fibroid polyps occur in exons 12, 14 and 18 and are associated with tumour localization. Histopathology 61(1): 59-68, 2012.
25 Lasota J, Wang ZF, Sobin LH and Miettinen M: Gain-of-function PDGFRA mutations, earlier reported in gastrointestinal stromal tumors, are common in small intestinal inflammatory fibroid polyps. A study of 60 cases. Mod Pathol *22(8)*: 1049-1056, 2009.
26 Rao K, Goodin S, Levitt MJ, Dave N, Shih WJ, Lin Y, Capanna T, Doyle-Lindrud S, Juvidian P and DiPaola RS: A phase II trial of imatinib mesylate in patients with prostate specific antigen progression after local therapy for prostate cancer. Prostate *62(2)*: 115-122, 2005.
27 Liu C, Zhang Z, Tang H, Jiang Z, You L and Liao Y: Cross-talk between IGF-IR and other tumor promoting pathways Curr Pharm Des *20(17)*: 2912-2921, 2014.

28 Kominea A, Konstantinopoulos PA, Kapranos N, Vandoros G, Gkermpesi M, Andricopoulos P, Artelaris S, Savva S, Varakis I, Sotiropoulou-Bonikou G and Papavassiliou AG: Androgen receptor (AR) expression is an independent unfavorable prognostic factor in gastric cancer. J Cancer Res Clin Oncol *130(5)*: 253-258, 2004.

29 Nylander-Koski O, Kiviluoto T, Puolakkainen P, Kivilaakso E and Mustonen H: The effect of nitric oxide, growth factors and estrogen on gastric cell migration. J Surg Res *143(2)*: 230-237, 2007.

30 Sperti C, Bonadimani B, Guolo P, Militello C, Cappellazzo F, Pasquali C and Pedrazzoli S: Androgen profile in patients with pancreatic carcinoma. Italian J Gastroenterol *24(6)*: 328-331, 1992.

Received August 11, 2014
Revised September 10, 2014
Accepted September 16, 2014