Radiotherapy for Early-stage Primary Ocular Adnexal Mucosa-associated Lymphoid Tissue Lymphoma

SAIJI OHGA[1], KATSUMASA NAKAMURA[1], YOSHIYUKI SHIOYAMA[1], TOMONARI SASAKI[1], TADAMASA YOSHITAKE[1], KAZUSHIGE ATSUMI[1], KOTARO TERASHIMA[1], KAORI ASAI[1], KEIJI MATSUMOTO[1], HIROSHI YOSHIKAWA[2], YO-ICHI KAWANO[3] and HIROSHI HONDA[1]

Departments of [1]Clinical Radiology, and [2]Ophthalmology, Graduate School of Medical Sciences, Kyushu University, Fukuoka, Japan; [3]Department of Ophthalmology, Faculty of Medicine, Fukuoka Dental College, Fukuoka, Japan

Abstract. *Background: Primary ocular adnexal mucosa-associated lymphoid tissue lymphoma (POAML) is a rare disease. The purpose of this study was to evaluate the treatment outcome and patterns of failure of patients with early-stage POAML treated with radiotherapy. Patients and Methods: From 1995 to 2008, 53 patients with early-stage POAML were reviewed. Tumors were categorized as either superficial or mass-forming type. In principle, superficial lesions (n=11) were treated with 24 Gy, while the mass-forming lesions (n=42) were irradiated with 30 Gy. The median follow-up period was 3.9 years. Results: All four cases of relapse had mass-forming lesions. The 5-year overall and progression-free survival rates were 100% and 91.5%, respectively. Although 30 patients experienced grade 2 or 3 late adverse events, no patients had radiation-related retinopathy. Conclusion: Early-stage POAML can be well-controlled with radiotherapy. However, the risk of distant relapse should be noted, in particular, for mass-forming tumors.*

Lymphoma of the ocular adnexa is a relatively rare clinical entity, and accounts for approximately 8% of extranodal non-Hodgkin's lymphoma (1). Since mucosa-associated lymphoid tissue (MALT) lymphoma was described in 1983 by Issacson and Wright (2), it has been reported that the majority of lymphomas in the ocular adnexa are of the MALT type (3). MALT lymphoma is classified as an indolent group and exhibits a favorable prognosis. Because an indolent lymphoma is less sensitive to chemotherapy than an aggressive one, radiotherapy is recognized as a choice of treatment for early-stage primary ocular adnexal MALT lymphoma (POAML).

As shown in several reports (4-7), radiotherapy alone leads to excellent local control. However, distant relapses occur in a certain number of patients. Although there have been a few analyses of disease progression and prognosis in patients with POAML (5, 6, 8), the patterns of relapse remain unclear.

Therefore, we conducted a retrospective analysis of 53 patients with early-stage POAML treated with radiotherapy alone. The purpose of the present study was to evaluate clinical outcomes and patterns of failure of patients with early-stage POAML treated with radiotherapy, in particular, focusing on tumor volume and location.

Patients and Materials

Patients' characteristics. From 1995 to 2008, 53 patients with localized primary ocular adnexal MALT lymphoma were treated with radiotherapy alone at Kyushu University Hospital with a follow-up period of at least six months. All 53 patients were histopathologically diagnosed as having MALT lymphoma, based on the characteristic morphological and immunophenotypic features of MALT lymphoma.

The patients' characteristics are shown in Table I. The median follow-up period was 3.9 years (range: 1 –13.5 years). All patients were staged according to the Ann Arbor classification system (9). Seven patients who were classified as having stage I disease had bilateral ocular adnexal lesions. The one patient with stage II disease had palpebral conjunctival and ipsilateral lymph node lesions. Performance status (PS) was determined according to the Eastern Cooperative Oncology Group (ECOG) (10).

In the present study, the tumors were categorized as either superficial lesion or mass-forming lesion, according to the tumor volume. Tumors undetectable on computed tomographic (CT) images, and which were located in the palpebral and/or bulbar conjunctiva, were classified as superficial lesions. The tumors which occurred in the ocular adnexa including the conjunctiva and had a visible mass on CT images were defined as mass-forming lesions. Of the 53 patients, 11 had superficial lesions, and 42 had mass-forming lesions.

This article is freely accessible online.

Correspondence to: Katsumasa Nakamura, Department of Clinical Radiology, Graduate School of Medical Sciences, Kyushu University, Maidashi 3-1-1, Higashi-ku, Fukuoka 812-8582, Japan. Tel: +81 926425695, Fax: +81 926425708, e-mail: nakam@radiol.med.kyushu-u.ac.jp

Key Words: Radiotherapy, ocular adnexal, MALT lymphoma.

Table I. *Patients' characteristics*.

Characteristic	Number of patients (n=53)
Age, years	
Median	62
Range	22-87
Gender	
Male	19
Female	34
Stage	
I	52
II	1
Primary site	
Orbita	28
Palpebral/bulbar conjunctiva	19
Lacrimal gland	6
Performance status	
0	35
1	18
Tumor type	
Superficial	11
Mass-forming	42

Treatment. The radiation field encompassed the extent of tumor with 10-15 mm margin. In the case of superficial lesions, a 4-6 MeV electron beam was used. In the case of mass-forming lesions, 4-6 MV X-rays were used. A single anterior field, a lateral opposite field, and a wedged pair of anterior fields were applied in 50 patients, two patients, and one patient, respectively. Lens shielding or lacrimal gland shielding was performed, provided the shielding did not reduce the dosage to the tumor. Lens shielding was performed in all 11 patients with superficial lesion, and lacrimal shielding was performed in eight patients with mass-forming lesion. In principle, the prescribed dose was 24 Gy in 12 fractions for superficial lesions, and 30 Gy in 20 fractions for mass-forming lesions. Only one patient with a mass-forming lesion of the lacrimal gland was treated with a dose of 24 Gy in 12 fractions.

Follow-up and statistical analysis. The follow-up evaluations were performed by the ophthalmologist/radiation oncologist at 3 to 6 month intervals, with or without CT or magnetic resonance imaging. The initial response was evaluated by Cheson *et al's* criteria (11, 12) at three months after the administration of radiotherapy. Acute and late adverse events were evaluated according to the Common Terminology Criteria for Adverse Events (version 3.0) (13). Overall survival (OS) and progression-free survival (PFS) rates were calculated using the Kaplan-Meiers method. Differences in PFS between superficial and mass-forming lesion groups were assessed using the log-rank test. A p-value less than 0.05 was considered to indicate a statistically significant difference.

Results

Response rate and local control. A complete response was achieved in 21 patients, and 31 patients responded partially to treatment. Only one patient had stable disease. No irradiated tumor progressed except for one patient with a mass-forming lesion who had local progression at 13 months after irradiation of 24 Gy. No patients with lens shielding or lacrimal gland shielding experienced local recurrence.

Relapse patterns and survival. Distant relapses were observed in only four patients (Table II), all of whom had mass-forming tumors. Out of these, three were treated with a total dose of 30 Gy, and one was treated with 24 Gy. None of the 11 patients with superficial lesions experienced disease relapse. All patients were still alive following salvage chemotherapy including rituximab. The 5-year OS and PFS rates of all 53 patients were 100% and 91.5%, respectively (Figure 1). Although there was no statistically significant difference, patients with superficial lesions had better PFS than those with mass-forming lesions (Figure 2). During the follow-up period, only one patient died, of other causes (acute myelogenic leukemia) at 63 months after radiotherapy.

Adverse events. With regard to acute adverse events related to initial radiation therapy, the majority of patients had grade 1 dermatitis or conjunctivitis. No patients exhibited greater than grade 2 acute toxicity.

There were 30 patients who experienced grade 2 or 3 late adverse events (cataract in 14, dry eye in 16). No patients had grade 4 or 5 adverse events. Out of 42 patients without lens shielding, 12 (28.8%) had grade 2 or greater cataract. In particular, grade 3 cataract formation requiring surgery was found in 10 patients (23.8%). Of 11 patients treated with lens shielding, one had grade 2 cataract (9.1%) and one had grade 3 cataract (9.1%).

Discussion

For early-stage ocular adnexal MALT lymphoma, despite therapy offering excellent local control rates, the risk of distant relapse is a significant problem. In the present study, radiotherapy led to excellent local control in patients with superficial lesions of POAML, while distant relapses were observed in some patients with mass-forming tumors. Goda *et al*. demonstrated that, in the retrospective analysis of 89 patients with POAML, the cumulative distant relapse rate was higher in patients with lacrimal and soft tissue disease than in those with conjunctival disease (5). Hashimoto *et al*. evaluated the treatment results of 78 patients with POAML, and showed that most distant relapses were observed in patients with POAML arising from the orbit or lacrimal grand (6). Bayraktar *et al*. showed that, among 69 patients with stage I POAML, tumors with orbital involvement conferred a poorer prognosis than those involving the conjunctiva alone (8). In this study, the superficial lesions of POAML, which arose from the conjunctiva, had no distant relapse. Therefore, it seems that the risk of distant relapse

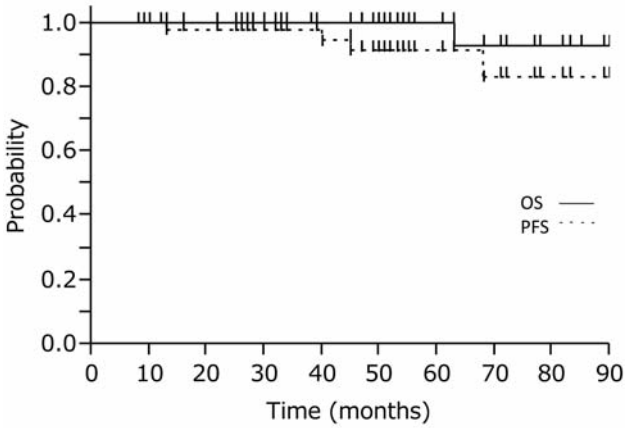

Figure 1. *Overall (OS) and progression-free (PFS) survival curves.*

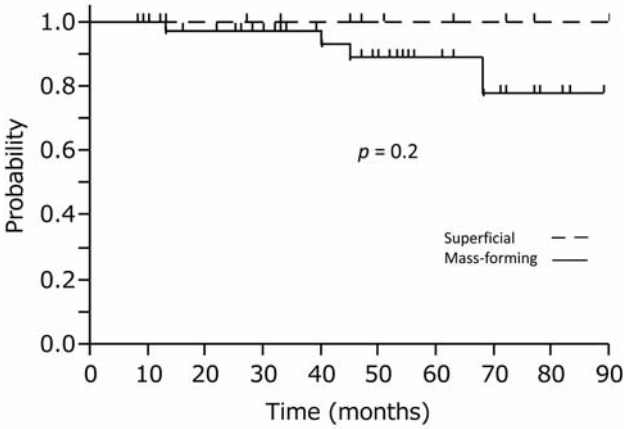

Figure 2. *Comparison of progression-free survival curves according to superficial and mass-forming type of lesion.*

Table II. *Clinical data of the patients with relapse after radiotherapy.*

Case (years)	Age	Gender	Site/tumor type	Dose (Gy)	Response	Site of relapse	Time-to-relapse (months)	Treatment after relapse	Status at last follow-up
1	59	F	Orbit/mass-forming	30	CR	Mesenterium	68	Op, CTx	Alive, NED
2	56	F	Orbit/mass-forming	30	PR	Buccal region and kidney	40	CTx	Alive, NED
3	64	F	Orbit/mass-forming	30	CR	Neck	45	CTx	Alive with lymphoma
4	62	M	Lacrimal/mass-forming	24	PR	Local and neck	13	Op, CTx, RT	Alive with lymphoma

Op: Operation, CTx: chemotherapy; RT: radiotherapy; NED: no evidence of disease; M: male; F: female.

should be carefully considered, especially in patients with the mass-forming type of tumor which mainly arises from the orbit or lacrimal gland.

Rituximab is known to be an effective and well-tolerated treatment for orbital MALT lymphoma (14). Therefore, rituximab as a sequential treatment may be promising to reduce the risk of a distant relapse in patients with POAML. Hashimoto *et al*. treated 20 patients with stage I POAML with radiotherapy in combination with rituximab (6). They concluded that radiotherapy combined with rituximab successfully reduced the risk of systemic relapse. However, considering that the incidence rate of distant relapse is still low and that relapse-associated lesions may be controllable by salvage chemotherapy combined with rituximab, the treatment strategy for early-stage POAML, in particular with superficial lesions, should be carefully considered to avoid overtreatment.

Generally, MALT lymphoma responds well to radiotherapy. However, an optimal dose for the treatment of localized ocular adnexal MALT lymphoma has not yet been established. Several authors have recommended radiotherapy with 25 Gy or lower (5, 15). In the present study, the superficial type of lesion was well-controlled with a dose of 24 Gy. By contrast, several reports have found that the use of lower doses might be a risk factor for local relapse. Tsang *et al*. reported two local relapses in 29 patients with orbital MALT lymphoma who received 25 Gy (16). Suh *et al*. also reported cases of local relapse within a shielded area (17). Bayraktar *et al*. advocated that radiation doses of at least 30.6 Gy should be given in stage I disease, since lower doses may be more frequently associated with relapses (8). In the present study, only one patient with a tumor of the mass-forming type had a local relapse after 24 Gy of irradiation, while none of the patients with the mass-forming lesions, who were irradiated with 30 Gy, had a local relapse. Although the number of patients is small in the present study, our results suggest that 30 Gy may be necessary to obtain sufficient local control for mass-forming lesions of ocular adnexal MALT lymphoma, while a radiation dose of 24 Gy seems to be sufficient to control tumors of the superficial type.

Several investigators have suggested lens shielding as a useful technique for preventing radiation-induced cataract formation (5, 17). Goda *et al*. showed that the risk of grade 3 cataract was greatly reduced by customized lens shielding, from 41% without lens shielding to 15% with shielding (5). In the present study, the incidence of grade 3 cataracts was also found to be lower in patients who received lens shielding (9.1%) than in those without (23.8%). Lens shielding should be provided, unless doing so would lead to a decrease in tumor dose.

In conclusion, the preliminary findings of this study suggest that radiotherapy leads to excellent local control without distant relapse in patients with superficial lesions of POAML, while distant relapses were observed in some patients with mass-forming tumors. Although a radiation dose of 24 Gy seems to be sufficient to control superficial tumors, the optimal dose remains unclear. The exact optimal doses for patients with ocular adnexal MALT lymphoma can be determined by larger prospective observational studies.

Acknowledgements

This study was partly supported by Grant-in-Aid for Scientific Research (KAKENHI 23390302 and 23659589).

References

1 Fung CY, Tarbell NJ, Lucarelli MJ, Goldberg SI, Linggood, RM, Harris NL, and Ferry JA: Ocular adnexal lymphoma: Clinical behavior of distinct World Health Organization classification subtypes. Int J Radiat Oncol Biol Phys *57*: 1382-1391, 2003.

2 Isaacson P and Wright DH: Malignant lymphoma of mucosa-associated lymphoid tissue. A distinctive type of B-cell lymphoma. Cancer *52*: 1410-1416, 1983.

3 White WL, Ferry JA, Harris NL and Grove AS Jr.: Ocular adnexal lymphoma. A clinicopathologic study with identification of lymphomas of mucosa-associated lymphoid tissue type. Ophthalmology *102*: 1994-2006, 1995.

4 De Cicco L, Cella L, Liuzzi R, Solla R, Farella A, Punzo G, Tranfa F, Strianese D, Conson M and Bonavolontà G: Radiation therapy in primary orbital lymphoma: A single institution retrospective analysis. Radiat Oncol *4*: 60, 2009.

5 Goda JS, Le LW, Lapperriere NJ, Millar B, Payne D, Gospodarowicz MK, Wells W, Hodgson DC, Sun A and Simpson R: Localized orbital mucosa-associated lymphoma tissue lymphoma managed with primary radiation therapy: Efficacy and toxicity. Int J Radiat Oncol Biol Phys *81*: e659-e666, 2011.

6 Hashimoto N, Sasaki R, Nishimura H, Yoshida K, Miyawaki D, Nakayama M, Uehara K, Okamoto Y, Ejima Y and Azumi A: Long-term outcome and patterns of failure in primary ocularadnexal mucosa-associated lymphoid tissue lymphoma treated with radiotherapy. Int J Radiat Oncol Biol Phys *82*: 1509-1514, 2012.

7 Hata M, Omura M, Koike I, Tomita N, Iijima Y, Tayama Y, Odagiri K, Minagawa Y, Ogino I and Inoue T: Treatment effects and sequelae of radiation therapy for orbital mucosa-associated lymphoid tissue lymphoma. Int J Radiat Oncol Biol Phys *81*: 1387-1393, 2011.

8 Bayraktar S, Bayraktar UD, Stefanovic A and Lossos IS: Primary ocular adnexal mucosa-associated lymphoid tissue lymphoma (MALT): single institution experience in a large cohort of patients. Br J Haematol *152*: 72-80, 2011.

9 Carbone PP., Kaplan HS, Musshoff K, Smithers DW and Tubiana M: Report of the Committee on Hodgkin's Disease Staging Classification. Cancer Res *31*: 1860-1861, 1971.

10 Oken MM, Creech RH, Tormey DC, Horton J, Davis TE, McFadden ET and Carbone PP: Toxicity And Response Criteria Of The Eastern Cooperative Oncology Group. Am J Clin Oncol *5*: 649-655, 1982.

11 Cheson BD, Horning SJ, Coiffier B, Shipp MA, Fisher RI, Connors JM, Lister TA, Vose J, Grillo-López A and Hagenbeek A: Report of an international workshop to standardize response criteria for non-Hodgkin's lymphomas. J Clin Oncol *17*: 1244-1244, 1999.

12 Cheson BD, Pfistner B, Juweid ME, Gascoyne RD, Specht L, Horning SJ, Coiffier B, Fisher RI, Hagenbeek A and Zucca E: Revised response criteria for malignant lymphoma. J Clin Oncol *25*: 579-586, 2007.

13 Trotti A, Colevas AD, Setser A, Rusch V, Jaques D, Budach V, Langer C, Murphy B, Cumberlin R, Coleman CN and Rubin P: CTCAE v3.0: Development of a comprehensive grading system for the adverse effects of cancer treatment. Semin Radiat Oncol *13*: 176-181, 2003.

14 Eckardt AM, Lemound J, Rana M and Gellrich N: Orbital lymphoma: diagnostic approach and treatment outcome. World J Surg Oncol *11*: 73, 2013.

15 Stafford SL, Kozelsky TF, Garrity JA, Kurtin PJ, Leavitt JA, Martenson JA and Habermann TM: Orbital lymphoma: Radiotherapy outcome and complications. Radiother Oncol *59*: 139-144, 2001.

16 Tsang RW, Gospodarowicz MK, Pintilie M, Wells W, Hodgson DC, Sun A, Crump M and Patterson BJ: Localized mucosa-associated lymphoid tissue lymphoma treated with radiation therapy has excellent clinical outcome. J Clin Oncol *21*: 4157-4164, 2003.

17 Suh C, Shim SJ, Lee S, Yang WI, Lee SY and Hahn JS: Orbital marginal zone B-cell lymphoma of MALT: Radiotherapy results and clinical behavior. Int J Radiat Oncol Biol Phys *65*: 228-233, 2006.

Received October 4, 2013
Revised November 7, 2013
Accepted November 8, 2013