Instillation of Mitomycin C after Transurethral Resection of Bladder Cancer Impairs Wound Healing: An Animal Model

JACK CHENG-TSUNG HOU[1], STEVE LANDAS[2], CHING Y. WANG[1] and OLEG SHAPIRO[1]

Departments of [1]Urology and [2]Pathology, SUNY Upstate Medical University, Syracuse, NY 13210, U.S.A.

Abstract. *Background: Mitomycin C is used in the immediate post-operative period to prevent tumor re-implantation, but it has adverse effects on the bladder. This study devised an animal model to investigate the effects of intravesical mitomycin C on wound healing. Methods and materials: A cystotomy was made in the dome of the bladder of female rats. The mucosa of the posterior wall was scratch with closed forceps. The bladder was closed and 0.2 ml of saline with or without 0.4 mg mitomycin C was instilled into the bladder transurethrally. The rats were sacrificed 30 and 60 days after the treatment and the bladder was examined grossly and microscopically. Results: The most frequent histological findings in the bladder were chronic inflammation and fibrosis. Fibrosis but not chronic inflammation was significantly associated with the exposure to MMC and it persisted even 60 days after the exposure to mitomycin C. Conclusion: Mitomycin C produces chronic fibrosis in rat bladder that is often seen in patients receiving prophylactic treatment with this drug.*

Transitional cell carcinoma of the bladder is the sixth most common cancer in the United States with 14,680 people expected to die of the disease in 2010 (1). Seventy to 80% of patients with bladder cancer present with superficial disease (stages Ta, T1 and carcinoma *in situ, CIS*). The treatment of choice for this group of patients is a transurethral resection of bladder tumor (2). Unfortunately, without an adjuvant therapy, 50%-70% of patients will recur with 20% progressing to muscle-invasive disease. Intravesical chemotherapy is used to treat T1 cancers, multifocal and high grade tumors including CIS, and recurrent TCC (3). The role of this treatment in patients with low-risk solitary tumors remains open to debate (4). Multiple agents are available to treat superficial bladder cancer. Intravesical chemotherapy is also used to decrease the rate of tumor cell implantation after transurethral resection of bladder tumor (5). Instillation of mitomycin C (MMC) has been shown to decrease the rate of tumor recurrence (6-8). Serious side-effects of this treatment have been described in the literature (9-11). However, this is an underreported problem which requires further investigation. This study designed an animal model to study the adverse effects of MMC on healing properties of an injured urothelium.

Correspondence to: Jack Cheng-Tsung Hou, Departments of Urology, SUNY Upstate Medical University, 750 East Adams Street, Syracuse, NY 13210, U.S.A. Tel: +1 3153233300, Fax: +1 3154646117, e-mail: houj@upstate.edu

Key Words: Mitomycin C, intravesical chemotherapy, bladder cancer.

Materials and Methods

A total of 48 female Sprague-Dawley rats, 250 to 300 g, were obtained from Charles River Breeding Co., Wilmington, MA, USA. They were anesthetized with ketamine/bipuvicaine, *i.p.* An incision was made at the midline of the lower abdomen and the bladder was exposed. The bladder was cut open longitudinally at the ventral wall to expose the lumen at the dome area. The mucosa was pinched ten times with a toothed forceps and then scratched ten times with closed forceps. No animals exhibited immediate evidence of gross hemorrhage of the bladder. The bladder was closed with 6-0 monocryl sutures in a running fashion, and immediately treated with MMC. Thirty rats were then randomly selected to be in the treatment group. For the treatment group rats, 0.2 ml saline containing 0.4 mg MMC was instilled into the bladder transurethrally. The urethra was tied off with 2-0 silk suture in order to keep the solution in the bladder and the abdomen was closed with sutures. The animals were kept under anesthesia for 2 h before the suture was removed. Eighteen rats were similarly treated with saline only to serve as controls. The animals were maintained in a room at 25˚C and 50% humidity. Food and water were provided *ad lib*.

Rats were randomly selected in each group and sacrificed at 30 days after the treatment. The remaining rats were sacrificed at 60 days. Bladders were inflated with approximately 0.5 ml buffered formalin fixative, tied and fixed in the fixative solution. They were dissected longitudinally 24 h later and examined grossly. Paraffin blocks of the tissue were processed and sections were stained with hematoxylin/eosin and trichrome stain. Histological examination was performed by a single pathologist who was not aware of the treatment the rat had received. Ulceration, chronic inflammation, necrosis, edema and fibrosis were found in the tissues and these changes were graded from

Table I. *Histological findings of the urinary bladder.*

		Total no.	Fibrosis					Chronic inflammation					Necrosis*	Ulcer*
			Grade					Grade						
			0	1	2	3	*P*-value	0	1	2	3	*P*-value		
30 Days	Control	6	0	1	3	2		0	3	2	1		0	0
	MMC	14	0	0	4	10	<0.01	0	6	6	2	>0.40	4	4
60 Days	Control	11	1	3	4	3		1	7	1	2		0	0
	MMC	15	1	2	2	10	<0.02	0	9	4	2	>0.25	1	0

*The difference is not significant.

0 to 3 according to their severity, with grade 0 being healthy. The histological changes were treated as ordinal parameters and the Mann-Whitney *U*-test was performed for statistical analyses. Sites of foreign body reaction (*i.e.*, suture material) were excluded from analysis. This animal protocol has been reviewed and approved by the local institutional Committee for the Humane Use of Animals.

Results

Two rats were sacrificed during the experiment due to abdominal infection caused by biting at the suture area by the animal and they were therefore excluded from the study. The most frequent histological findings in the bladder were chronic inflammation and fibrosis (Table I). Fibrosis and lymphocytic infiltration in the submucosal layer were observed in most of the bladders regardless of the treatment with MMC (Figure 1). Fibrosis, but not chronic inflammation, was significantly associated with the exposure to MMC and it persisted even 60 days after the exposure to MMC. Necrosis and ulceration were also found in a few animals, but they were not associated with MMC exposure. The posterior wall histopathological findings suggest an exaggerated phase of chronic inflammation, associated mural fibrosis and edema which do not subside even after 60 days.

Discussion

Intravesical chemotherapy instillation after transurethral resection is used to reduce recurrence rates of bladder cancer (5). MMC has become the agent of choice for an immediate post-operative instillation in many centers. However, there are serious detrimental side-effects of adjuvant MMC intravesical therapy after transurethral resection (10). In this animal study, the adverse effects of MMC on healing properties of injured urothelium were demonstrated.

Examination of rat bladder mucosa after this experiment demonstrated characteristics suggestive of a chronic inflammatory process which overlaps interstitial cystitis. This probably represents a nonspecific stereotypic pattern of injury and response. Histopathological findings showed edema, necrosis, acute and sub-acute inflammation of the bladder mucosa, which did not subside after 60 days.

There was also prominence of eosinophils, granulation tissue and fibrosis, chronic inflammatory elements including plasma cell and lymphocytes. MMC produces chronic fibrosis in rat bladder that is often seen in patients receiving prophylactic treatment with this drug (3). These histological findings and their resemblance to chronic cystitis may suggest a common mechanism of injury to the bladder by the MMC and the inflammatory disease. Immune complexes are likely formed by MMC cross-linking DNA and proteins (12, 13). Although chronic inflammation was not associated with MMC treatment in the rat model, the possibility of an autoimmune reaction cannot be ruled out as the cause of the current findings of non-healing ulcer in the bladder after tumor resection and immediate MMC instillation.

References

1 Jemal A, Siegel R, Xu J and Ward E: Cancer Statistics, 2010. CA Cancer J Clin *60*: 277-300, 2010.

2 Carmack AJ and Soloway MS: The diagnosis and staging of bladder cancer from RBCs to TURs. Urology *67(3 suppl 1)*: 3-8, 2006.

3 Shapiro O, Jones K, Wang C, Landas S and Haas GP: Risk of post-operative intravesical mitomycin C instillation following transurethral bladder resection. Can J Urol *13*: 3317-3320, 2006.

4 Sylvester RJ, Oosterlinck W and van der Meijden AP: A single immediate postoperative instillation of chemotherapy decreases the risk of recurrence in patients with stage Ta T1 bladder cancer: a meta-analysis of published results of randomized clinical trials. J Urol *171*: 2186-2190, 2004.

5 Rajala P, Kaasinen E, Raitanen M, Liukkonen T, Rintala E and Finn Bladder Group: Perioperative single dose instillation of epirubicin or interferon-alpha after transurethral resection for the prophylaxis of primary superficial bladder cancer recurrence: a prospective randomized multicenter study–Finn Bladder III long-term results. J Urol *168*: 981-985, 2002.

6 Solsona E, Iborra I, Ricos JV, Monros JL, Casanova J and Dumont R: Effectiveness of a single immediate mitomycin C instillation in patients with low risk superficial bladder cancer: short and long-term follow-up. J Urol *161*: 1120-1123, 1999.

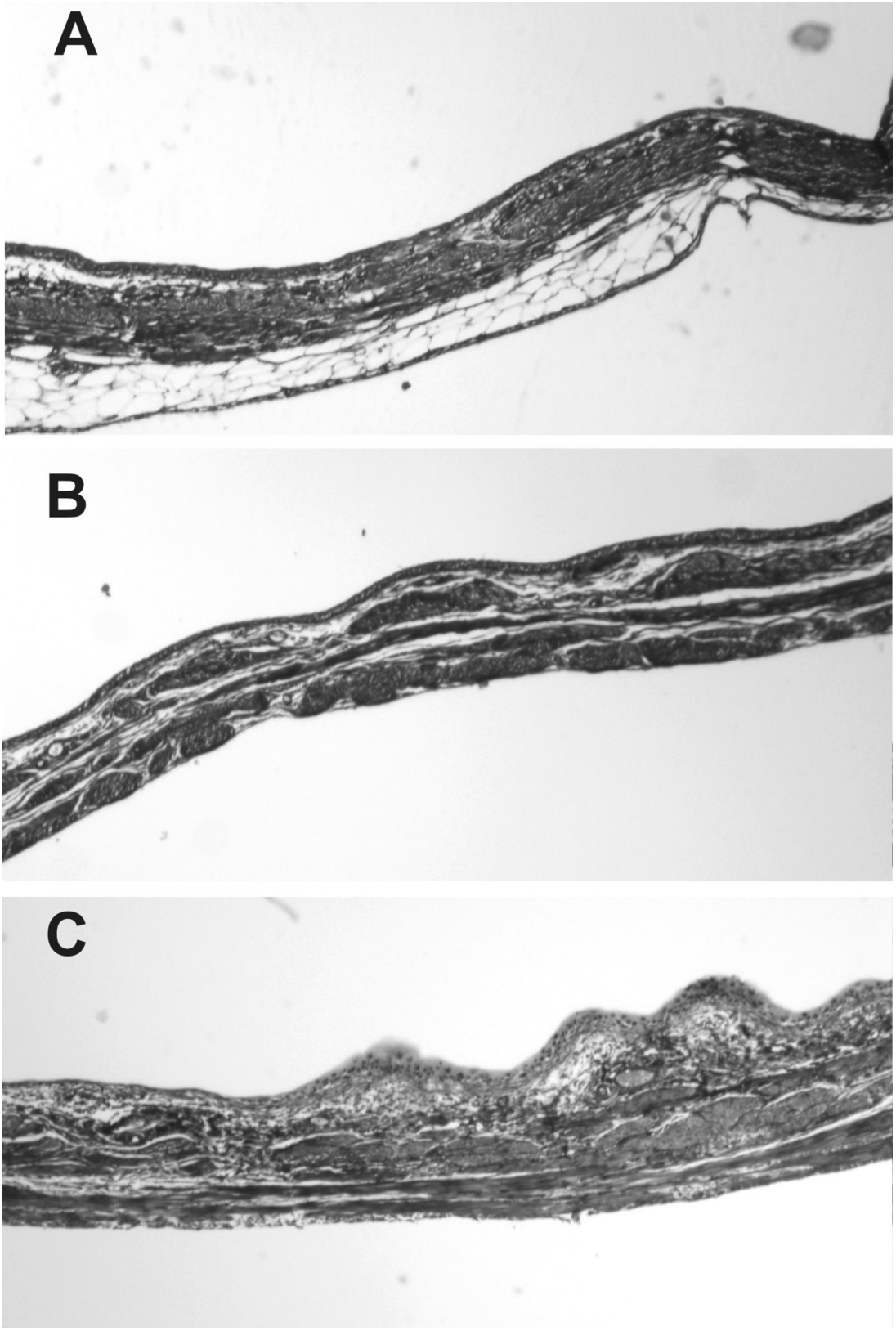

Figure 1. *Histology of the urinary bladder stained with trichrome stain. A: A normal bladder. B: An injured bladder treated with saline which appeared normal. C: An injured bladder treated with MMC which had fibrosis and severe lymphocytic infiltration in the submucosal layer.*

7 Tolley DA, Hargreave TB, Smith PH, Williams JL, Grigor KM, Parmar MK, Freedman LS and Uscinska BM: The effect of intravesical mitomycin C on recurrence of newly diagnosed superficial bladder cancer: a further report with 7 years of follow-up. J Urol *155*: 1233-1238, 1996.
8 Bouffioux C, Kurth KH, Bono A, Oosterlinck W, Kruger CB, De Pauw M and Sylvester R: Intravesical adjuvant chemotherapy for superficial transitional cell bladder carcinoma: results of 2 European Organization for Research and Treatment of Cancer randomized trials with mitomycin C and doxorubicin comparing early *versus* delayed instillations and short-term *versus* long-term treatment. European Organization for Research and Treatment of Cancer Genitourinary Group. J Urol *153*: 934-941, 1995.
9 Cliff AM, Romaniuk CS and Parr NJ: Perivesical inflammation after early mitomycin C instillation. BJU Int *85*: 556-557, 2000.
10 Nieuwenhuijzen JA, Bex A, Horenblas S, Nieuwenhuijzen JA, Bex A and Horenblas S: Unusual complication after immediate postoperative intravesical mitomycin C instillation. Eur Urol *43*: 711-712, 2003.
11 Racioppi M, Porreca A, Foschi N, Delicato G, Destito A and D'Addessi A: Bladder perforation: a potential risk of early endovesical chemotherapy with mitomycin C. Urol Int *75*: 373-375, 2005.
12 He M, Sheldon PJ and Sherman DH: Characterization of a quinone reductase activity for the mitomycin C binding protein (MRD): Functional switching from a drug-activating enzyme to a drug-binding protein. Proc Natl Acad Sci USA *98*: 926-931, 2001.
13 Joseph P, Xu Y and Jaiswal AK: Non-enzymatic and enzymatic activation of mitomycin C: identification of a unique cytosolic activity. Int J Cancer *65*: 263-271, 1996.

Received December 15, 2010
Revised February 6, 2011
Accepted February 8, 2011