

Fibromatosis of the Head and Neck: Morphological, Immunohistochemical and Clinical Features

FRANCESCA ANGIERO¹, STEFANO BENEDICENTI² and MICHELE STEFANI³

¹Facoltà di Medicina e Chirurgia, Sezione Anatomia Patologica,

Università degli Studi di Milano-Bicocca, Ospedale San Gerardo, Monza (Mi);

²Dipartimento di Scienze e Tecnologie Biofisiche Mediche e Odontostomatologiche, Università di Genova, Genova;

³Istituto di Anatomia Patologica, Sezione Patologia Orale, Università degli Studi di Milano Statale, Milano, Italy

Abstract. *The term fibromatosis indicates a proliferation of well-differentiated fibroblasts and myofibroblasts that develops in the soft tissue. This tumor has been considered locally aggressive because of the infiltrative growth pattern, but does not metastasize. Its occurrence in the head and neck region is not common, and very sporadically it may occur in the oral cavity or jaw bones. Two cases of adult fibromatosis are described here; one involving the submucosa of the middle hard palate and the other the subcutaneous area of the frontal bone. Tumor growth was rapid and bone involvement occurred in one case. Biopsies were taken and in both cases histological examination showed a tumor consisting of fibroblasts within a collagenous stroma, with rare atypia and mitoses. The patients underwent surgical resection with wide surgical margins; excised material was analyzed microscopically and a diagnosis of fibromatosis was rendered. Immunohistochemistry was positive for actin, vimentin and desmin, and negative for S-100, CD34, the progesterone receptors (PR)-A and PR-B and the estrogen receptors (ER) α and ER β . Follow-up at 5 years after surgery found both patients to be progression free. The clinical, histological and immunohistochemical features were analyzed to better characterize this form of the disease, that very rarely involves the oral cavity.*

The classification of fibromatosis has not yet been standardized, and some forms derive their names from their particular locations. The terminology of the WHO classification was employed, using the term extra-abdominal fibromatosis, however, other terms exist, including extra-

abdominal desmoid tumor, desmoid tumor, well-differentiated non-metastasizing fibrosarcoma, grade I fibrosarcoma and aggressive fibromatosis. The latter term emphasizes the clinical nature of the disease process, indicating the aggressive behavior it may sometimes show. The lesion usually arises from the connective tissue of the muscle, the overlying fascia or aponeurosis and two principal forms are recognized: juvenile fibromatosis and adult fibromatosis.

Adult extra-abdominal fibromatosis is an uncommon soft-tissue tumor that can occur at any anatomic site, the commonest being the limbs, shoulder, thigh, buttock and trunk (1, 2) and accounts for 6.9% of all soft-tissue tumors (3). Occurrence in the head and neck region is not common (5-10%) (3-5) and only sporadically does it occur in the oral cavity or maxillary bones. Clinically, in the oral cavity it usually presents as a painless mass or swelling in the region involved. Less commonly, the patient shows ulceration, trismus, intraoral bleeding, otalgia, dysphagia, dyspnea, and loose teeth (6). The peak of incidence is between the ages of 25 and 35 (7), both genders being equally affected. The etiology of fibromatosis is still controversial. Genetic (7), endocrine (8, 9), and physical factors including surgery, trauma (10) and irradiation (11) may play roles in causing or precipitating fibromatosis, although Morioka *et al.* (12) found no evidence of trauma or familial predisposition in relation with the disease. A viral theory has also been proposed, but no virus has been isolated (13).

Macroscopically, fibromatosis traditionally appears as an ill-defined and firm grayish-white mass. Histologically, it is composed of well-differentiated fibroblasts, fibrocytes and myofibroblasts within a collagenous to myxoid stroma. No atypical mitosis or anaplastic elements are seen. However, it resembles a 'borderline' lesion, with an infiltrative growth pattern that makes complete excision difficult, and it has a propensity for recurrence, however, it does not metastasize. Diagnosis of this entity should include panoramic tomography, ultrasonography and MRI. CT and MRI show

Correspondence to: Prof. Francesca Angiero, MD, Anatomia Patologica, Ospedale San Gerardo, Via Pergolesi 33, Monza (Mi) Italy. Tel: +39 039 2332556, Fax: +3902799007, e-mail: f.angiero@teos.it

Key Words: Fibromatosis, desmoid tumor, oral cavity.

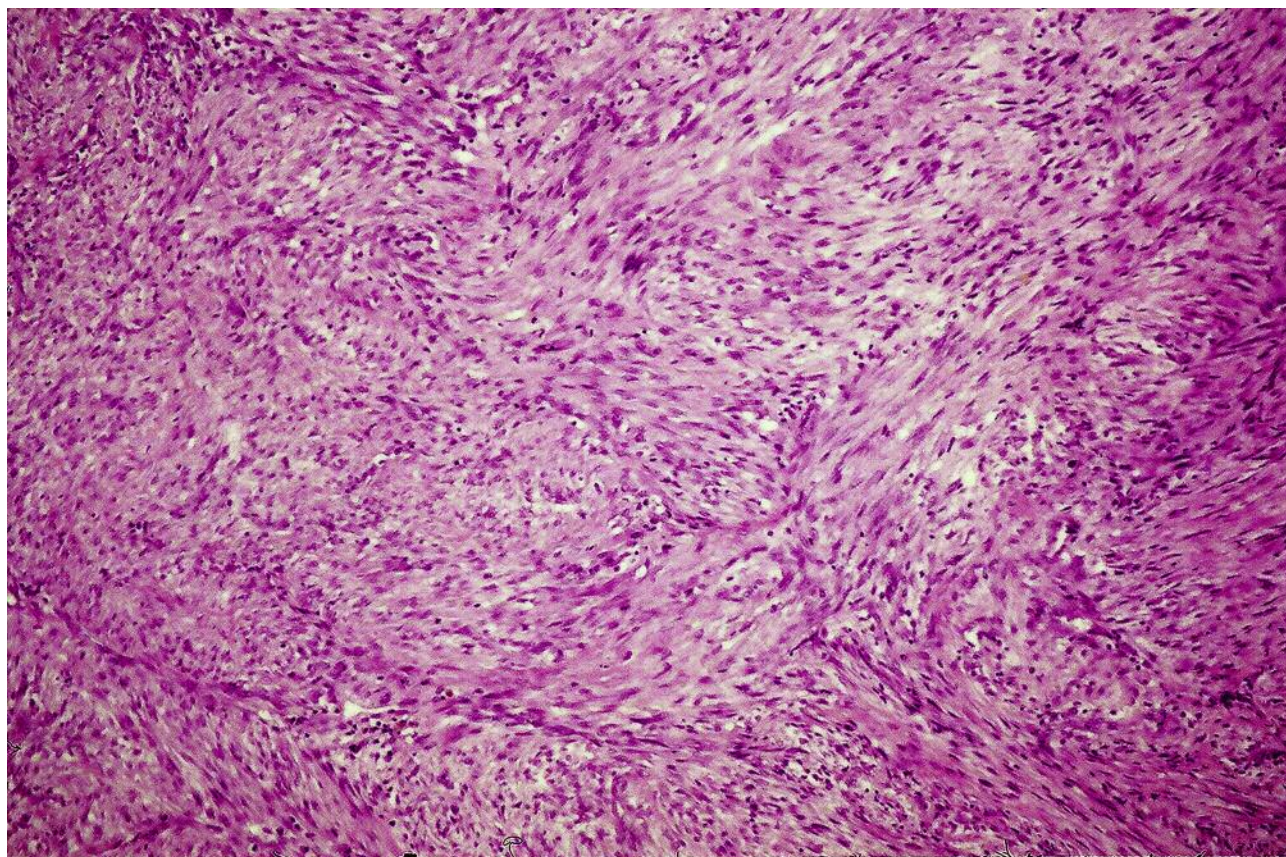


Figure 1. Photomicrograph shows proliferation of spindle cells with bland nuclei and the fascicular arrangement (Hematoxylin and eosin; original magnification $\times 150$).

the extension of the lesion and any infiltration of the surrounding tissues and in planning surgical excision (13, 14). Fibromatosis may attain a large size and cause compression, infiltration, and destruction of adjacent structures. Such growth behavior presents severe management problems, especially in the head and neck region, where the presence of many vital structures within a small space makes the patient susceptible to the effects of the fibromatosis, likewise making complete excision difficult.

Two rare cases of fibromatosis are reported, one involving the frontal bone and the other the hard palate, diagnostic imaging is provided, the histological and immunohistochemical features are discussed, together with the therapeutic approach.

Case Reports

Case 1. A 39-year-old woman was admitted to our department with a one-year history of small growth in the center of the hard palate. Oral examination showed a growth in the hard palate that did not pulsate and was not painful on palpation. An incisional biopsy revealed a lesion consisting

of fibroblasts with rare atypical aspects and mitotic activity. CT scanning revealed a soft-tissue mass around the mid-palate with predominately homogenous attenuation and mild enhancement. The tumor (a 2.0 \times 2.5 \times 2.0 cm grey-white lobulated mass) was excised with wide surgical margins. Recovery was uneventful and CT 5 years later showed no sign of recurrence.

Case 2. A 29-year-old man presented with a frontal mass that had been present for two years. CT scanning revealed a 2-cm mass extending superiorly to the frontal region, inferiorly to the orbital area. Family medical history was negative for neoplastic diseases. A general physical examination showed no abnormalities. An incisional biopsy revealed fibromatosis. The gray-white mass was then excised with wide surgical margins, the patient was followed-up and showed no signs of recurrence 5 years post-surgery.

Materials and Methods

The excised surgical specimens were fixed in 10% buffered-formalin and paraffin embedded, 5 μ sections were stained with

A

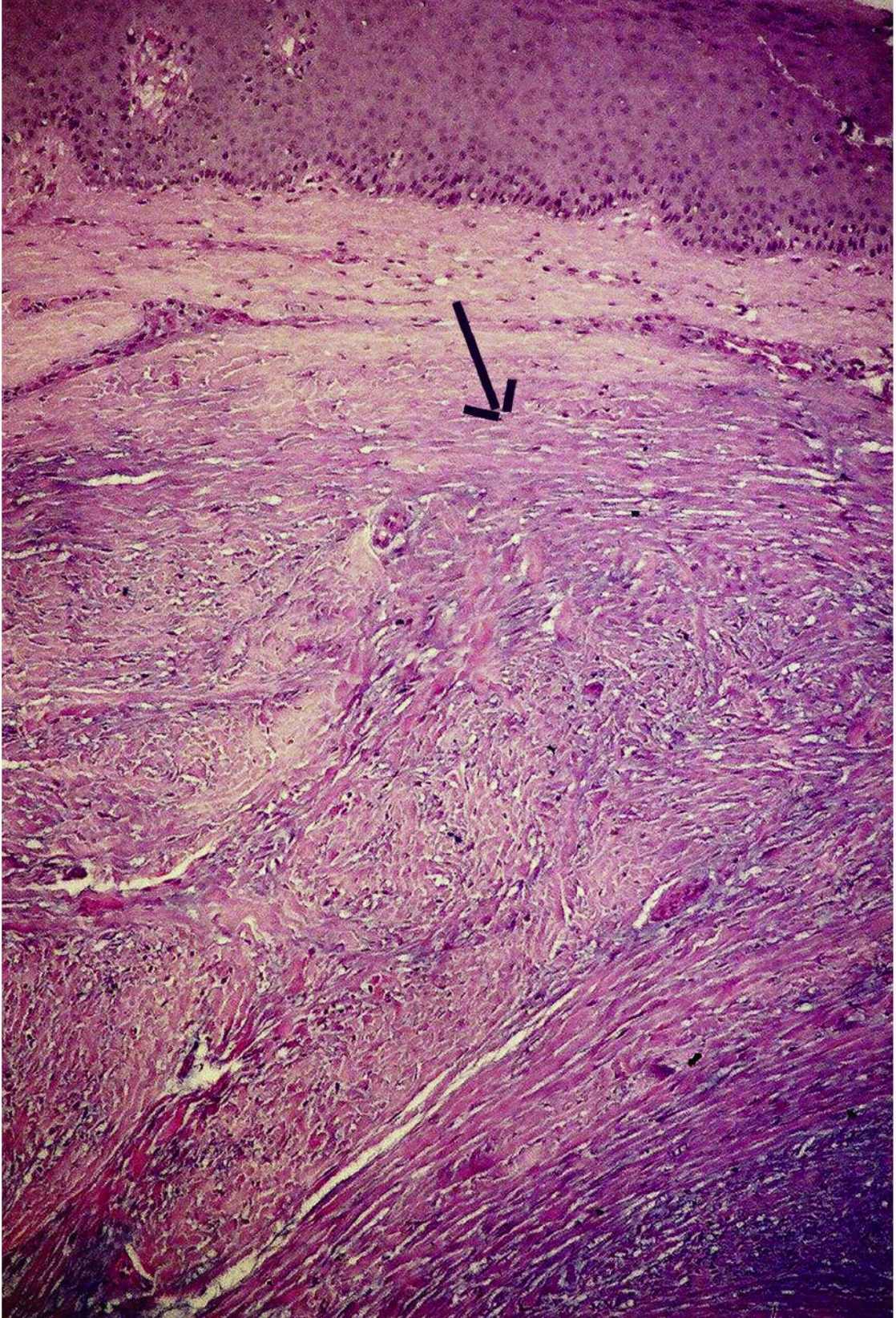


Figure 2. *continued*

B

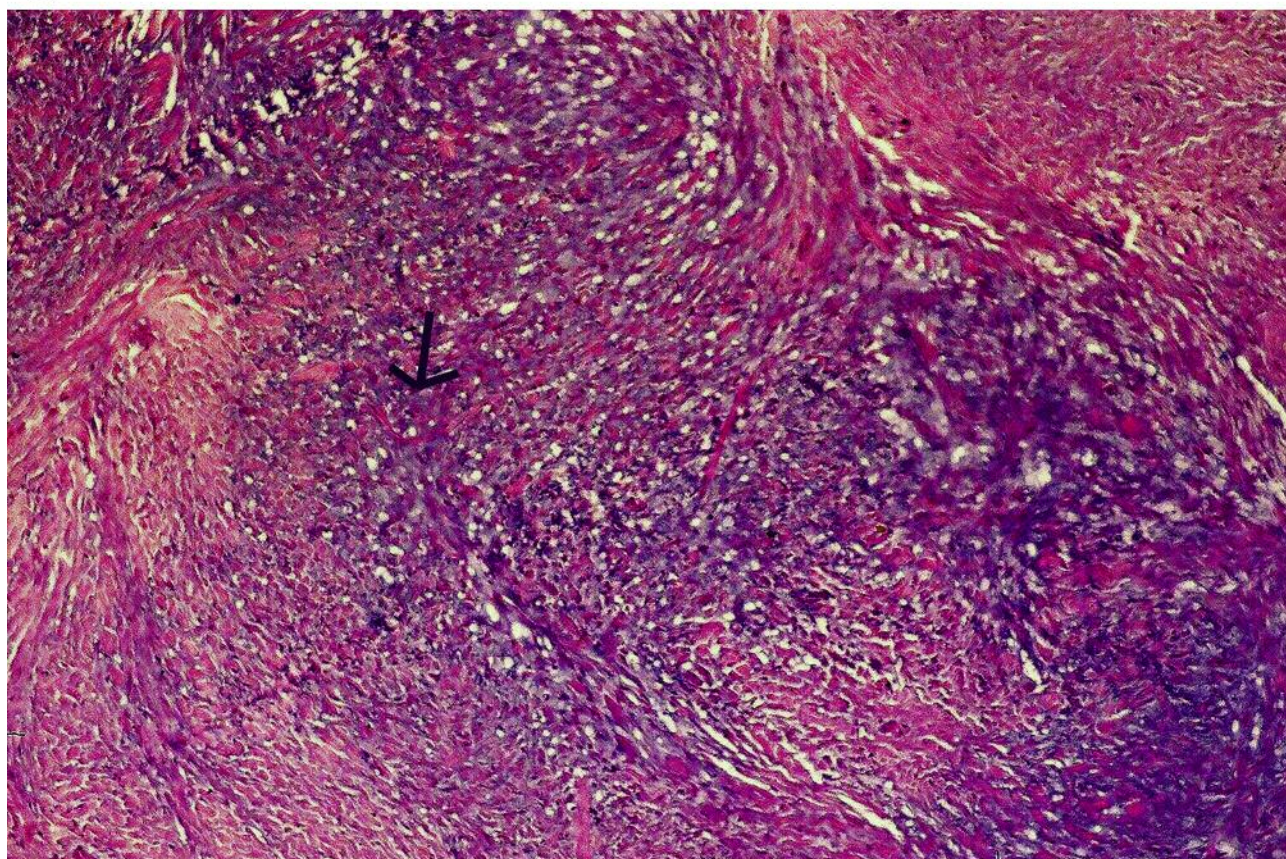


Figure 2. A. Photomicrograph shows (arrow) the characteristic nodular growth pattern (Hematoxylin and eosin; original magnification $\times 100$). B. Note the characteristic interlacing bundles of fibroblasts separated by collagen (arrow) (Hematoxylin and eosin stain; original magnification $\times 200$).

Table I. Immunohistochemical findings of the current cases.

Antibody	Supplier	Dilution	Reactivity case (1)	Reactivity case (2)	Antigen retrieval
Actin	Dako	1:100	+	+	Np
Desmin	Neomarkers	Prediluted	+	+	Citrate pH6
Pancytokeratin (A1-A3)	Ylem	1:50	-	-	Citrate
EmA	Dako	1:50	-	-	Np
S-100	Dako	Prediluted	-	-	Np
CD34	Ylem	Prediluted	-	-	Np
Oestrogen receptor α - β	Dako	1:100	-	-	Citrate pH6
Progesterone receptor A-B	Dako	1:400	-	-	Citrate pH6
Vimentin	Dako	1:400	+	+	Np

+: positive for a limited number of cells; Np: not performed.

hematoxylin-eosin, and with PAS (Periodic Acid-Schiff). For immunohistochemistry, the avidin-biotin complex (ABC) method was applied. All the tissue sections were dewaxed and rehydrated following standard protocols. Table I provides the details of the antibodies used. A panel of monoclonal antibodies was used for the

following markers (Table I): actin (1:100, Dako), vimentin (1:400, Dako), desmin (Prediluted, Neomarkers), pancytokeratins (1:50, Ylem), EMA (Epithelial membrane antigen) (1:50, Dako), CD34 (prediluted, Ylem), S-100 (Kit Dako, prediluted), estrogen receptors (ER) α - β (1:100, Dako), and the progesterone receptor (PR) (1:400,

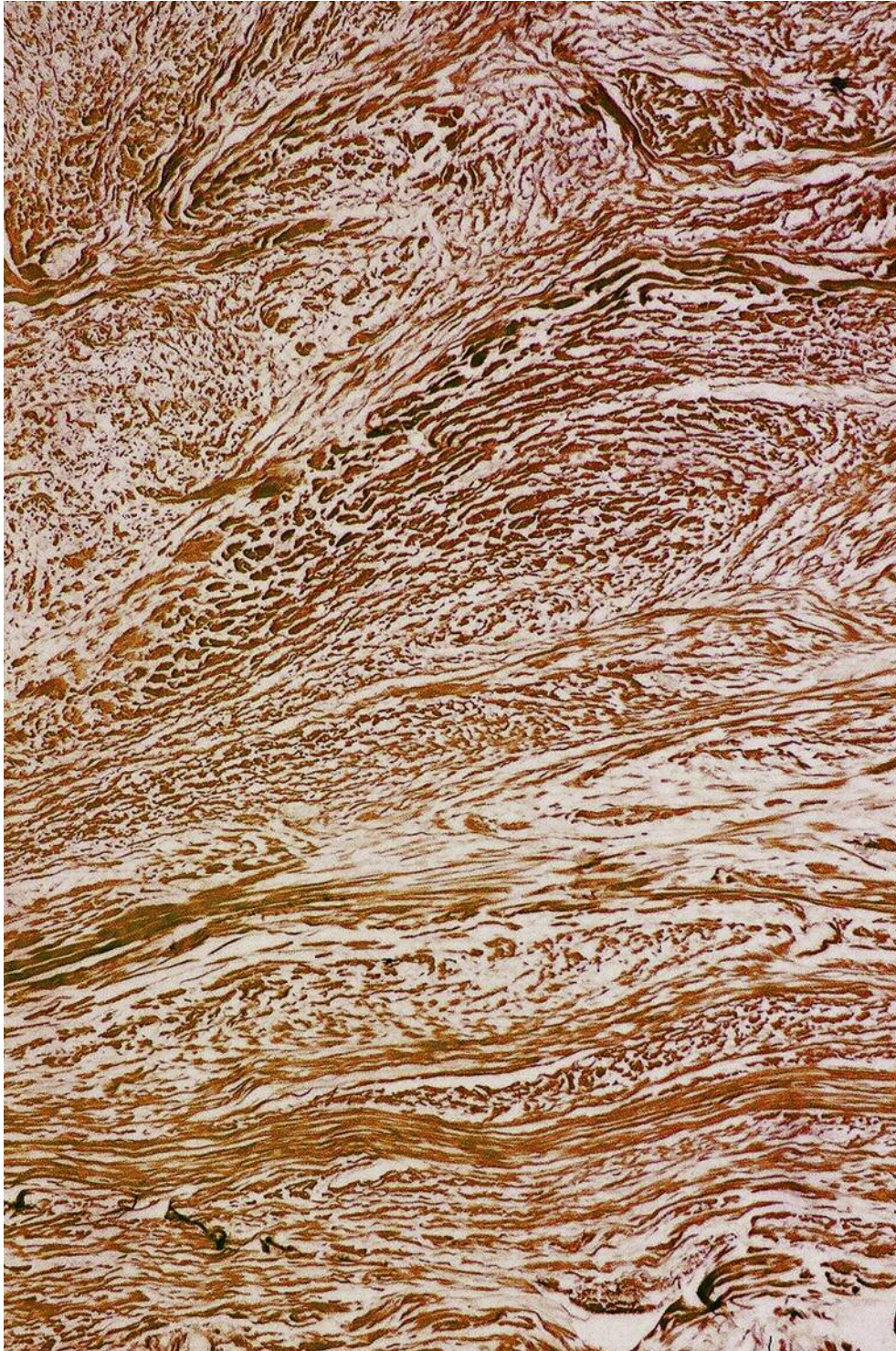


Figure 3. Immunohistochemically the spindle cells in Case 1 showed strong reactivity for vimentin (original magnification $\times 200$).

Dako). The tissue sections were processed following the manufacturers' guidelines or standard protocols. All the slides were evaluated independently by light microscopy by two pathologists. Classification as positive either followed manufacturers' guidelines

or institutional standard protocols for positive controls: a minimum of 10% of the tumor cells had to be positive for the ER α and β , and the PR-A and B. The immunohistochemical reactivity for EMA, S100, CD34, vimentin, desmin and actin, was evaluated and graded

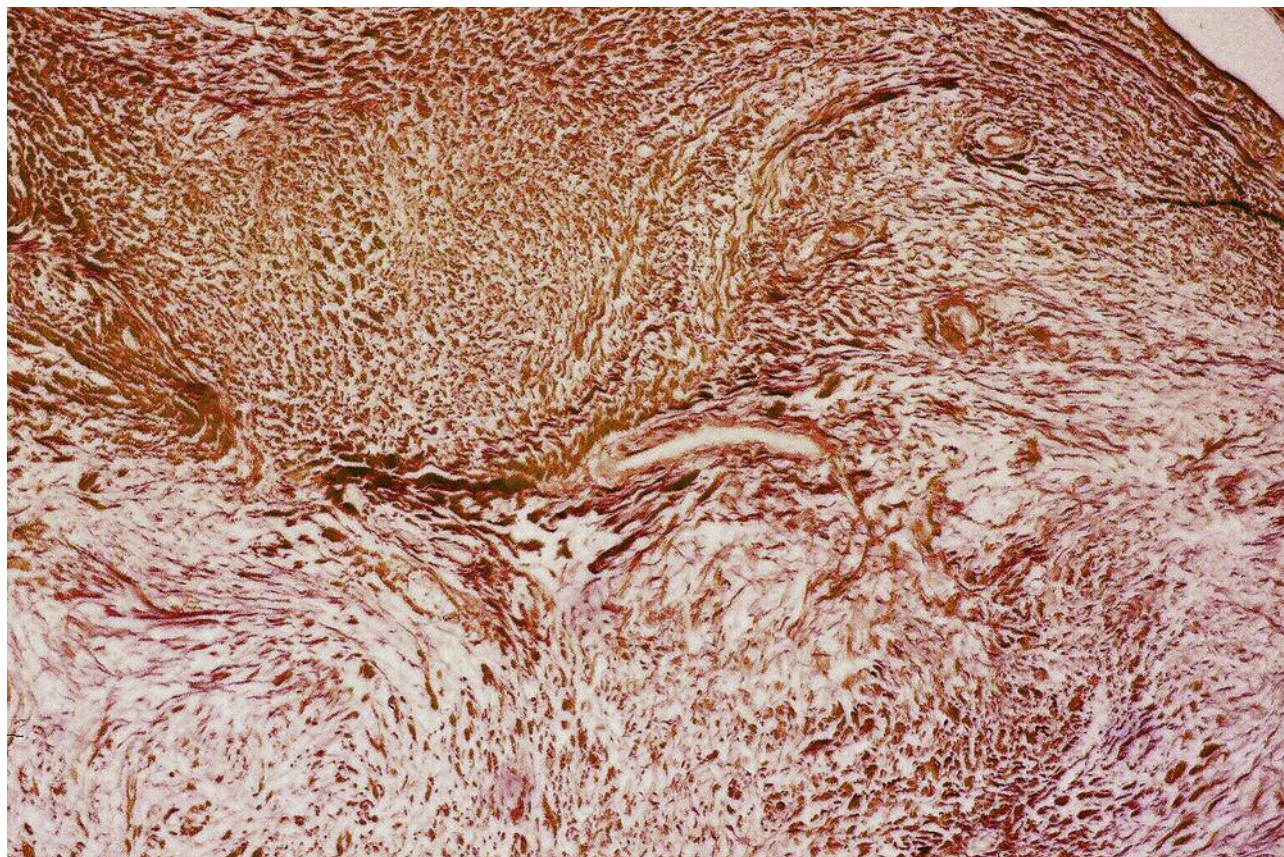


Figure 4. Immunohistochemically in Case 2 strong reactivity for vimentin (original magnification $\times 200$).

as follows: – (negative), no staining; + (positive), focally positive for a limited number of cells and ++ (intensely positive), focally or diffusely positive for numerous cells.

Results

Microscopic examination in case 1 showed that, beneath the squamous epithelium, which was covered by a thin layer of anucleate corneous lamellae, the lesion was composed of some nodules of connective elements arranged in a vortex of interlacing bundles of fibroblasts separated by collagen, immersed in a mixed stroma, which was lightly basophilic and moderately alcian positive (Figure 1).

The histology showed in case 2 showed a nodule of fibrous tissue with poor cellularity, consisting of thin mature spindle-shaped fibrocytes, interspersed with islands of connective tissue containing capillaries, whose walls were delimited by enlarged and thickened endothelial cells mixed with small nerve branches, arranged irregularly. Along one side in the fibrous tissue there was an area of osteoid aspect, forming at its edges bone tissue of normal appearance (Figure 2A-B).

Table I shows the results of the immunohistochemical staining. Immunohistochemical reactivity for vimentin, actin, desmin, ER α - β , and PR A-B was detected.

Both cases were negative for EMA, S-100, CD34, cytokeratins, PR-A and PR-B, and for ER α and ER β and positive for actin, vimentin and desmin (Table I and Figures 3 and 4).

Discussion

Biopsy was essential, because only histological examination can distinguish between the various forms, of the disease and above all it is important for differential diagnosis. Several diseases should be included in differential diagnosis since desmoplastic fibroma, the osseous counterpart of fibromatosis, presents a fairly similar appearance, but is less cellular and does not infiltrate as widely as fibromatosis. Clinical and radiological aspects also help in defining the lesion. Neurofibroma should also be considered in the differential diagnosis, but it is always S-100 positive, while fibromatosis is not, likewise malignant peripheral nerve-

sheath tumor, which is more cellular and presents greater mitotic activity, and in which about half of the cases are S-100 positive.

The most significant differential diagnosis is *versus* fibrosarcoma, which is diagnosed when the tumor cells show atypical cytological features and/or a significant number of mitotic figures (more than 1 per high-power microscopic field) (15). This differentiation may be difficult, but it is essential since fibromatosis does not possess the metastasizing potential of fibrosarcoma.

In cases located in the bone, there are problems of differential diagnosis *versus* the monostotic form of fibrous dysplasia (Jaffe Lichtenstein Syndrome), in which high activities of alkaline phosphatase are detectable. Other diseases must also be considered, such as Albright's syndrome, cherubism (in which however the age and presence of giant cells are indicative for diagnosis) or tumors such as neurofibroma (in which negativity for S100 is diagnostic) and also proliferative myositis (an intramuscular reactive process in which the hallmark is the ganglion-like cells, absent in fibromatosis). With regard to histopathology, no atypia was detected in the proliferating fibroblasts in our cases, and mitoses were also completely absent in one case and very rare in the other case.

Both of our cases were positive for actin, desmin and vimentin, but negative for pancytokeratin, EMA, S-100, CD34, PR-A, PR-B and ER α and Er β . The sex hormones receptors were tested because fibromatosis in general is thought to be hormonally sensitive, and because young fertile women are often affected, and anti-estrogens have been used as adjuvant treatment, either successfully (16) or without benefit (17, 18).

The treatment of choice for fibromatosis is complete surgical resection with wide margins (9, 19). In head-and-neck cases the vital and complex anatomy of the area (5) and similarly the occurrence of fibromatosis in this area can lead to loss of function associated with the destruction of these vital structures. The recommended margins are 2 and 4 cm respectively in the transverse plane and along the longitudinal axis, and less than 3 cm in the case of small tumors (20). Thus, many patients with large fibromatosis of the head and neck region must be treated with non-surgical options, such as radiotherapy and chemotherapy. The use of adjuvant therapy remains controversial. External radiotherapy or interstitial brachytherapy have been recommended as a substitute for radical surgery to avoid severe disability when limbs are affected (*e.g.* amputation) (21-23) while other studies (20, 24) have failed to demonstrate the value of additional radiotherapy. Zelefsky *et al.* (22) reported good results with brachytherapy for recurrent fibromatosis after surgical resection and achieved local control in 70% of patients. Irradiation may play a role in inoperable cases. In some inoperable cases radiotherapy is preferred, and if radiotherapy is contraindicated, chemotherapy is a valid alternative (25). An experimental protocol based on a

combination of three drugs (vincristine, actinomycin D and cyclophosphamide) can be used and must be combined with continuous follow-up with MRI. If the patient is estrogen-receptor positive, anti-estrogen drugs can be used with fairly satisfactory results. Alternatively, a combination of testolactone, sulindac, warfarin and vitamin K1 can be given (26).

Other therapies have been proposed, in particular with the availability of anti-estrogen drugs (tamoxifen), on the grounds that the speed of growth of fibromatosis is regulated especially by the female sex hormones (1, 27). However, the results of this type of treatment have not yet been fully clarified (1, 5, 10, 18, 21, 28).

Adult fibromatosis is characterized by a local recurrence rate of 35-65%. Hoos *et al.* (10) have reported a local recurrence rate in extra-abdominal desmoids of between 20-77%, 46-62% in the head and neck region, whereas Morioka *et al.* (12) reported a recurrence rate of 40-70%. Enzinger and Shiraki (24) report that younger patients and larger tumors have a higher propensity to recur. This behavior is slightly different in extraabdominal fibromatosis compared to the abdominal fibromatosis (desmoid tumor), in which the recurrence rate is lower (15-30%).

In summary although our series was small, the behavior of fibromatosis in the oral cavity does not appear to be very different from that of the systemic disease. Problems of differential diagnosis concern a wide range of other diseases and immunohistochemical analysis may be helpful in diagnosis. Our limited experience was characterized by a long follow-up period (5-6 years) and shows that in the management of head and neck fibromatosis a careful surgical excision with wide margins is of value for small lesions, to avoid possible recurrence.

References

- 1 Shields CJ, Winter DC, Kirwan WO and Redmond HP: Desmoid tumours. *Eur J Surg Oncol* 27: 701-706, 2001.
- 2 Shpitz B, Siegal A, Witz M, Kaufman Z and Dinbar A: Desmoid tumor: review and follow up of ten cases. *J Surg Oncol* 28: 67-71, 1985.
- 3 Kransdorf MJ: Benign soft tissue tumors in a large referral population: distribution of specific diagnoses by age, sex, and location. *AJR* 164: 395-402, 1995.
- 4 Rock MG, Pritchard DJ, Reiman HM, Soule EH and Brewster RC: Extraabdominal desmoid tumors. *J Bone Joint Surg* 66: 1369-1374, 1984.
- 5 Tse GM, Chan KF, Ahuja AT, King AD, Pang PC and To EW: Fibromatosis of the head and neck region. *Otolaryngol Head Neck Surg* 125: 516-519, 2001.
- 6 Fowler CB, Hartman KS and Brannon RB: Fibromatosis of the oral and paraoral region. *Oral Surg Oral Med Oral Pathol Oral Radiol Endod* 77: 373-388, 1994.
- 7 Enzinger FM and Weiss SW: *Soft Tissue Tumors*. 3rd ed. St Louis (MO): Mosby-Year book, pp. 210-229, 1995.
- 8 McDougall A and McGarrity G: Extraabdominal desmoid tumors. *J Bone Joint Surg* 61: 373-377, 1979.

- 9 Schwartz HE and Ward PH: Aggressive fibromatosis of the tongue. *Ann Otol Rhinol Laryngol* 88: 12-15, 1979.
- 10 Hoos A, Lewis JJ, Urist MJ, Shaha AR, Hawkins WG, Shah JP and Brennan MF: Desmoid tumors of the head and neck-a clinical study of a rare entity. *Head Neck* 22: 814-821, 2000.
- 11 Ben-Izak O, Kuten A, Pery M, Quitt M, Guilbord J and Weyl-Ben-Arush M: Fibromatosis (desmoid tumor) following radiation therapy for Hodgkin's disease. *Arch Pathol Lab Med* 118: 815-818, 1994.
- 12 Morioka WT, Heath VC and Cantrell RW: Juvenile fibromatosis. *Ann Otol Rhinol Laryngol* 88: 324-326, 1979.
- 13 De Santis D: Fibromatosis of the mandible: case report and review of previous publications. *Br J Oral Maxillofac Surg* 36: 384-388, 1998.
- 14 Lee JC, Thomas JM, Phillips S, Fisher C and Moskovic E: Aggressive fibromatosis: MRI features with pathologic correlation. *AJR Am J Roentgenol* 186: 247-54, 2006.
- 15 Rosai J: *Ackerman's Surgical Pathology*. 8th ed. Mosby, St Louis, pp. 2031-2036, 1995.
- 16 Hansmann A, Adolph C, Vogel T, Unger A and Moeslein G: High-dose tamoxifen and sulindac as first-line treatment for desmoid tumors. *Cancer* 100: 612-620, 2004.
- 17 Easter DW and Halasz NA: Recent trends in the management of desmoid tumors. Summary of 19 cases and review of the literature. *Ann Surg* 210: 765-769, 1989.
- 18 Pignatti G, Barbanti-Brodano G, Ferrari D, Gherlinzoni F, Bertoni F, Bacchini P, Barbieri E, Giunti A and Campanacci M: Extraabdominal desmoid tumor. A study of 83 cases. *Clin Orthop* 375: 207-213, 2000.
- 19 Wang CP, Chang YL, Ko JY, Cheng CH, Yeh CF and Lou PJ: Desmoid tumor of the head and neck. *Head Neck* 28: 1008-1013, 2006.
- 20 Hunt RTN, Morgan HC and Ackerman LV: Principles in the management of extra-abdominal desmoids. *Cancer* 13: 825-836, 1960.
- 21 Kiel KD and Suit HD: Radiation therapy in the treatment of aggressive fibromatosis (desmoid tumors). *Cancer* 54: 2051-2055, 1984.
- 22 Zelefsky MJ, Harrison LB, Shiu MH, Armstrong JG, Hajdu SI and Brennan MF: Combined surgical resection and iridium 192 implantation of locally advanced and recurrent desmoid tumors. *Cancer* 67: 380-384, 1991.
- 23 Bataini JP, Belloir C, Mazabraud A, Pilleron JP, Cartigny A, Jaulerry C and Ghossein NA: Desmoid tumors in adults: the role of radiotherapy in their management. *Am J Surg* 155: 754-760, 1988.
- 24 Enzinger FM and Shiraki M: Musculo-aponeurotic fibromatosis of the shoulder girdle (extra-abdominal desmoid). Analysis of thirty cases followed up for ten or more years. *Cancer* 20(7): 1131-1134, 1967.
- 25 Schmitt G, Mills EE, Levin V, Smit BJ, Borcker H and Pape H: Radiotherapy of aggressive fibromatosis. *Eur J Cancer* 28: 832-835, 1992.
- 26 Wilken N and Tattersall MH: Endocrine therapy for desmoids tumors. *Cancer* 68: 1384-1388, 1991.
- 27 Reitamo JJ, Scheinin TM and Hayry P: The desmoid syndrome: new aspect in the cause, pathogenesis and treatment of the desmoid tumor. *Am J Surg* 151: 230-237, 1986.
- 28 West CB Jr, Shagets FW and Mansfield MJ: Nonsurgical treatment of aggressive fibromatosis in the head and neck. *Otolaryngol Head Neck Surg* 101: 338-343, 1989.

Received December 27, 2007

Revised March 4, 2008

Accepted March 14, 2008