Human Papillomavirus (HPV), DNA Aberrations and Cell Cycle Progression in Anal Squamous Cell Carcinoma Patients

NONGNIT LAYTRAGOON-LEWIN[1], PER J. NILSSON[2], JUAN CASTRO[3], BABACK GHARIZADEH[4], PÅL NYREN[5], BENGT GLIMELIUS[1], GÖRAN ELMBERGER[6], INGELA TURESSON[1] and CHRISTER SVENSSON[6]

[1]*Department of Oncology, Uppsala University Hospital;*
[2]*Centre of Gastrointestinal Disease, Ersta Hospital;*
[3]*CCK and* [6]*Department of Oncology-Pathology, Karolinska University Hospital, Sweden;*
[4]*Stanford Genome Technology Centre, Stanford University, U.S.A.;*
[5]*Department Biotechnology, Royal Institute of Technology, Sweden*

Abstract. *Human papillomavirus (HPV) infections of the genital tract are sexually transmitted and prevalent worldwide. In this study, the role of HPV in 72 patients with anal squamous cell carcinoma was investigated. Patients and Methods: Polymerase chain reaction (PCR) in combination with in situ hybridization was used to identify HPV-DNA in the patients' biopsies. The HPV typing was conducted by pyrosequencing. Cell cycle and DNA content were analysed by cytometry. Results: Ninety percent of the carcinoma biopsies carried high-risk oncogenic HPV in their malignant cells. Eighty-one percent of these demonstrated a single infection with HPV16, 18 or 33 and 19% were double infected with HPV16 and HPV18. Accumulations of viral genes were seen at the necrotic area of the tumours. The HPV genome in the tumour cell influenced significantly the host cell cycle progression, but not DNA aberrations. Within these patients, HPV status in the malignant cells was not found to be associated with patient survival time. Conclusion: High-risk oncogenic HPV may play an important role in the initiation of host cell proliferation in anal squamous cell carcinoma. However, infection with HPV may not have any direct influence itself on the clinical outcome of these patients considering the treatments currently available.*

Anal squamous cell carcinoma is a locally aggressive neoplasm that tends to engage locoregional lymph nodes, but its metastasis to distant tissues is uncommon (1). Within Scandinavia, a high proportion of anal cancer cases have been suggested to be related to human papillomavirus (HPV) both by means of serology and detection of HPV-DNA (2-4). In contrast, HPV infection was not found to be associated with anal cancer in the Chinese population on the basis of HPV-DNA detection (5).

More than 120 HPV genotypes have been fully characterized and broadly subdivided into low-risk non-oncogenic and high-risk oncogenic groups (6). The prototypes of the low-risk group are HPV 6 and HPV 11, which cause warts or benign squamous epithelial tumours (7). Within the high-risk oncogenic group, HPV16, HPV18 and HPV33 are associated with cervical malignancies (6, 8).

It has been demonstrated that the viral oncogenes E6 and E7 are required for the initiation and maintenance of the malignant phenotype in HPV positive carcinomas (6, 9-11). Viral oncoproteins coded by these genes are multifunctional and interfere with cell cycle regulatory proteins (12, 13). Replicate alteration by viral oncoproteins leads to malignant transformation and conditions of gross genetic instability such as DNA aneuploidy (14, 15).

Most HPV infections in healthy individuals are transient events (16). In addition, failure to detect HPV specific antibodies in patients whose cervical lesions contained HPV-DNA has been reported (17, 18).

Our investigation focused on the prevalence of HPV-DNA in anal squamous cell carcinoma biopsies, the influence of HPV on host cell cycle progression and the correlation with patient survival time were analysed.

Patients and Methods

Patients. A population-based series of anal cancer patients between 1987-2000 (19) was used for this study. All of the patients' records were collected from the files of the South Stockholm General Hospital and Ersta Hospital, Stockholm, Sweden. Ethical approval was obtained from the ethical committee at Karolinska University Hospital.

Correspondence to: Nongnit Laytragoon-Lewin, Department of Oncology, Rudbeck Laboratory, Uppsala University Hospital, SE-751 85 Uppsala, Sweden. Tel: +46 18 6110210 Fax: +46 18 4713432, e-mail: nongnit.laytragoon-lewin@onkologi.uu.se

Key Words: HPV, DNA content, cell cycle, anal carcinoma, HPV and anal carcinoma.

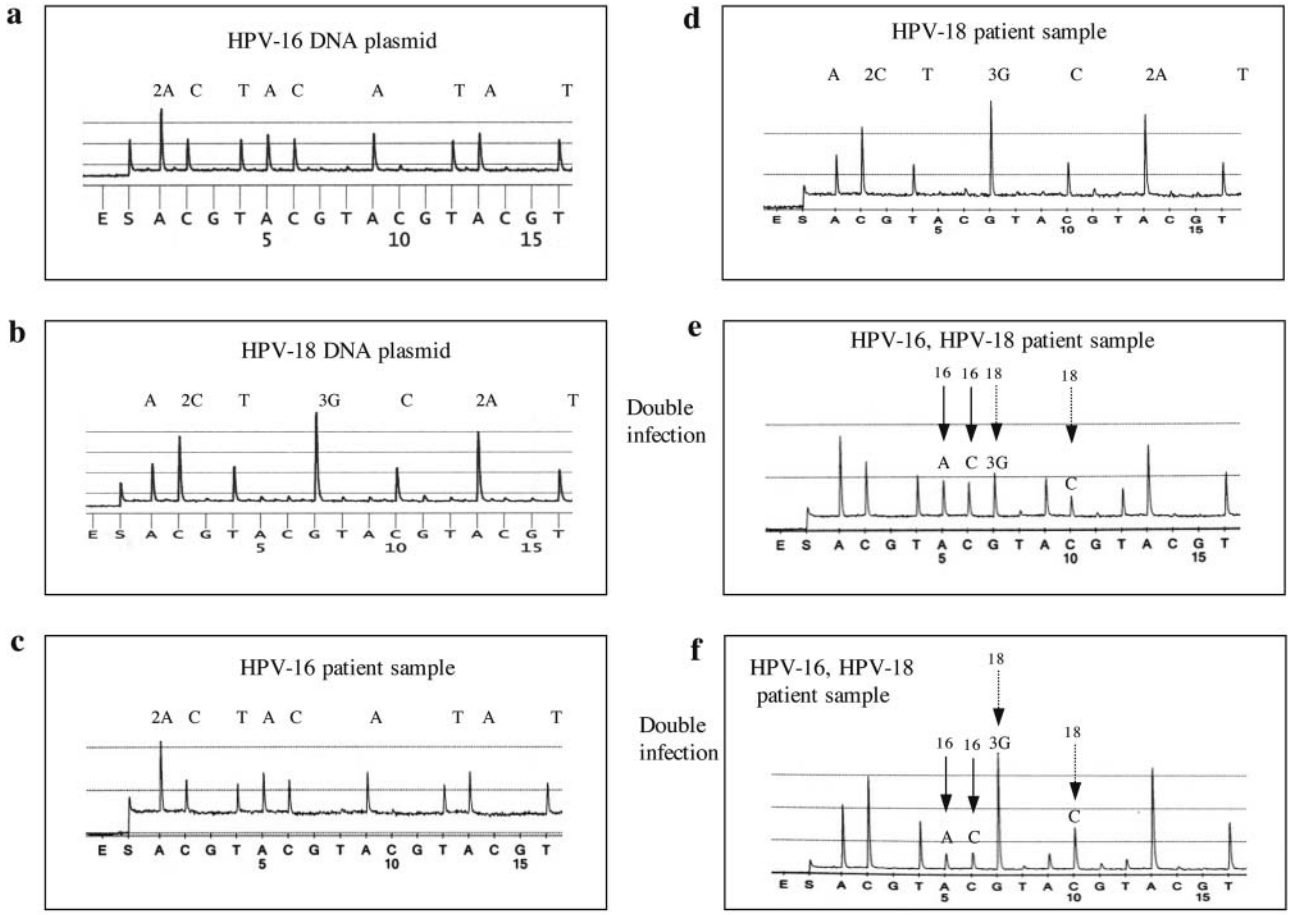

Figure 1. *HPV typing by pyrosequencing method. (A) The HPV16 plasmid sequence. (B) The HPV18-plasmid sequence. (C) and (D) The only HPV16 or HPV18 sequence from one representative tumour biopsy, respectively. (E) and (F) The sequence of HPV16 and HPV18 in 2 representative tumour biopsies.*

Pre-treatment tumour biopsies from 72 anal canal squamous cell carcinoma patients were included in the study. The histological categories of these biopsies were re-evaluated by an independent pathologist. Of these patients, 56 patients were women (median age 72 years) and 16 patients were men (median age 68 years).

HPV-DNA detection and typing. Patient genomic DNA was extracted from paraffin-embedded pre-treatment malignant biopsies. To prevent experimental contamination, the microtome was carefully cleaned after each sample and 10 sections of empty paraffin block were cut between each sample. A nested polymerase chain reaction (PCR) for detection of HPV was performed using the consensus primers My09/My11 and Gp5+/Gp6+ (20-22). Approximately 0.5 μg of extracted DNA was used as the template over 30 PCR cycles.

In order to determine the HPV genotype and type of infection (*i.e.* single/double infection), pyrosequencing technology, in combination with a multiple-sequencing-primer approach, was used with these PCR products (23). This approach accommodated the possibility of simultaneous detection of single or multiple HPV types in a single sample.

Table I. *HPV status in 72 anal squamous cell carcinoma biopsies.*

HPV positive[a]	HPV negative[a]
65 (90%)	7 (10%)
Single HPV sequence (81%)	
HPV16	38 (58 %)
HPV18	13 (20%)
HPV33	2 (3%)
Double HPV sequences (19%)	
HPV16+HPV18	12 (19%)

[a]Number of biopsies and % from total tested biopsies.

Location of oncogenic HPV-DNA in anal cancer samples. Localisation of high risk HPV in the biopsies was performed with standard *in situ* hybridization after HPV-DNA analysis. A commercial high risk HPV probe cocktail and reagent kit were used on the Benchmark T Autostainer (Ventana Medical System

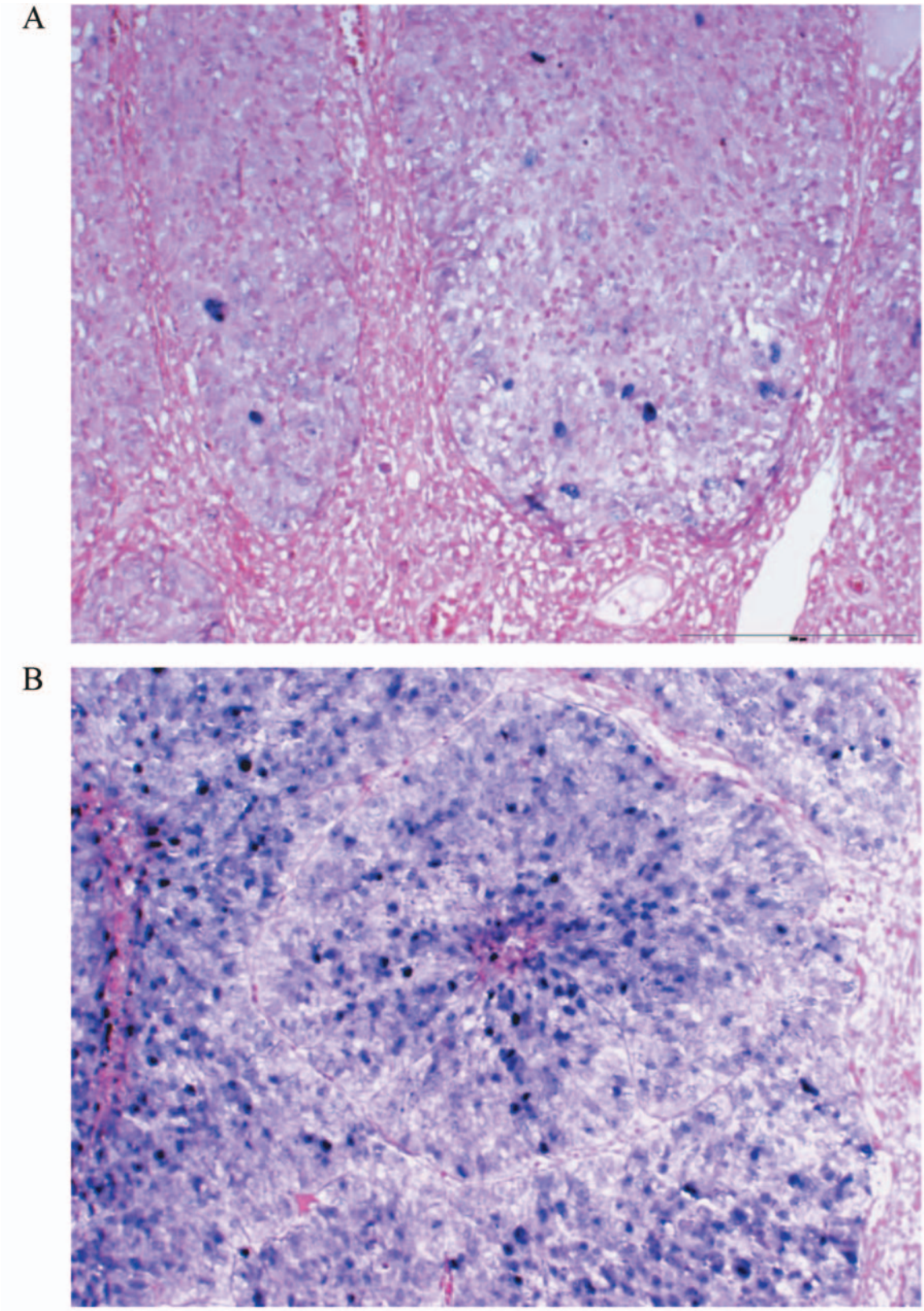

Figure 2. *High risk HPV in situ hybridization (x20) with low number of positive nuclei (A) or high number of positive nuclei (B) in the tumour biopsies. Observe frequency of positive nuclei towards necrotic centre of the tumour.*

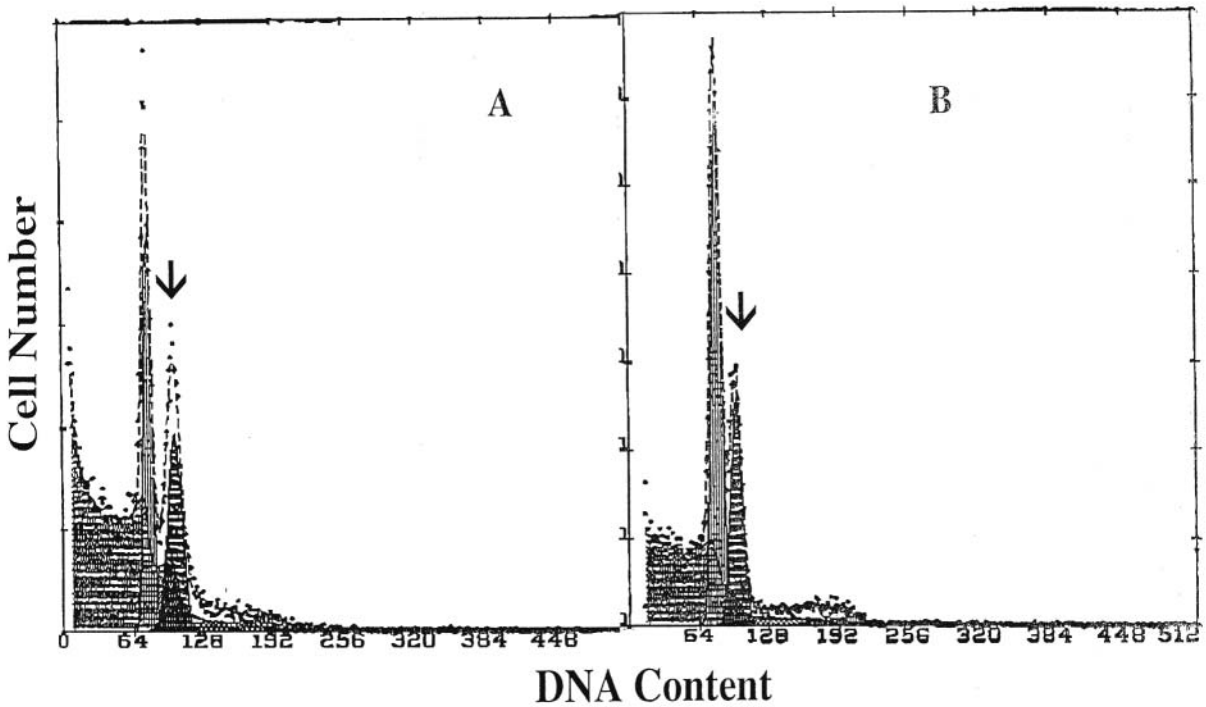

Figure 3. *Aneuploid DNA and diploid DNA histograms of one representative, HPV positive (A) and one representative HPV negative (B) anal cancer biopsy. Arrow indicates the G0/G1 cells with aneuploid DNA. The histograms were generated by flow cytometry from paraffin embedded biopsies.*

Inc., Tucson, USA). This test produces positive signals when cells contain at least 30 HPV genomes per cell.

DNA aberration and cell cycle analysis. DNA aberration and cell cycle stage were analysed as previously described (24). At least 40,000 cell nuclei were analysed per histogram. Comparison of cell cycle phase between HPV- positive and negative groups was performed using the two-sample Wilcoxon rank-sum (Mann-Whitney) test. Significance was defined at $p<0.05$ using a two-tailed test.

Patient survival time. The patients were treated in accordance with prospective protocols described elsewhere (19). In brief, radiotherapy alone was used for node-negative tumours with a maximum diameter of 4 cm or less. Patients with more advanced tumours received neoadjuvant or concomitant chemotherapy and radiotherapy. Radical surgery was reserved for poor responders to chemo/radiotherapy. Survival time of these 72 patients was calculated from the date of diagnosis until death or time of last follow-up. Comparison between HPV-positive and negative groups was done by the log rank test. Survival time estimation was performed using the method of Kaplan and Meier.

Results

HPV status and typing. With nested PCR analysis and pyrosequencing, high-risk oncogenic HPV genomes could be detected in 65 out of 72 (90%) biopsies (Table I). Sixty (81%) biopsies harboured single and 12 (19%) biopsies harboured double HPV-DNA. The single HPV types were HPV16 (58%), HPV 18 (20%) and HPV 33 (3%). The double HPV types were HPV 16 and HPV18 in all 12 (19%) biopsies. Representative plasmid and biopsy HPV sequences are shown in Figure 1.

Localisation of oncogenic HPV in the tumour biopsies. Positive oncogenic viral genome signals were exclusively detected in the nuclei of malignant cells with PCR-positive HPV biopsies. The frequency of positive cells and signal intensity were heterogeneous in each tumour biopsy. It is important to note that accumulations of strongly positive oncogenic HPV signal were detected in the necrotic area of the tumours (Figure 2).

DNA aberration and cell cycle distribution. Aneuploid DNA content was observed in 9 out of 70 (13%) patients. Within this group, one patient was HPV-negative and the remainder were HPV-positive (Figure 3). Sixty-one (87%) of the biopsies consisted of cells with only diploid DNA content. When HPV-positive and HPV-negative biopsies were compared, a statistically significant difference ($p=0.04$, Mann-Whitney test) was detected in the proportion of cells in the G2 phase of the cell cycle in the biopsies with diploid DNA content (Figure 4).

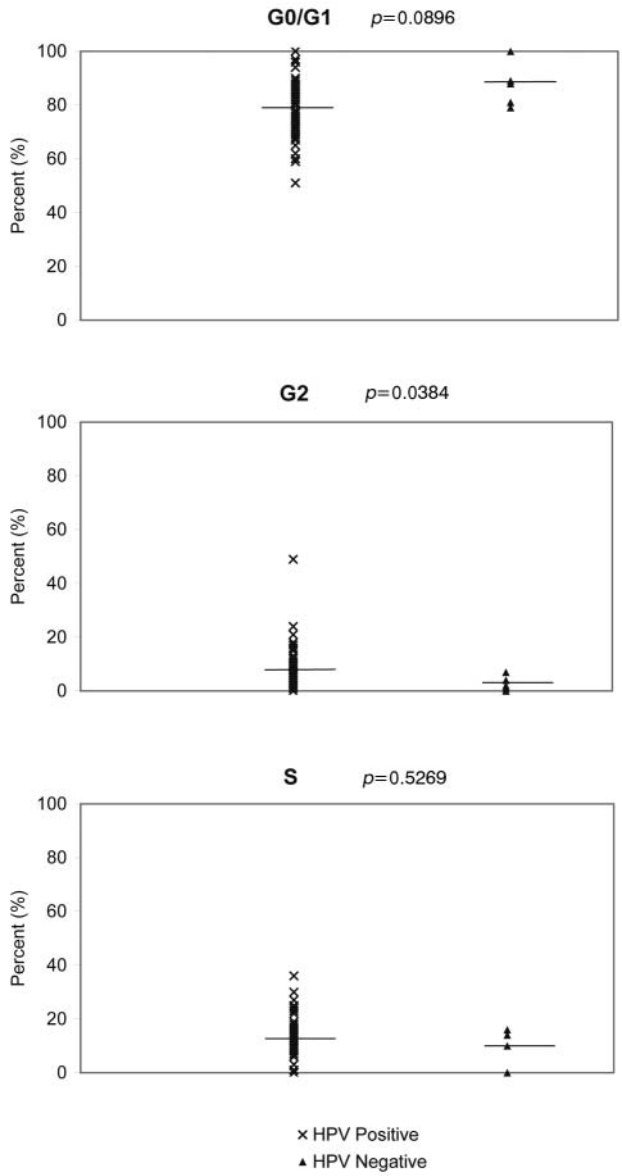

Figure 4. *Cell cycle distribution from diploid DNA of the anal cancer biopsies.*

Survival time of the anal cancer patients (Figure 5). Overall survival time of the 72 patients was 63% at 5 years. No statistically significant difference was detected between HPV- positive and HPV-negative anal cancer patients ($p=0.18$, log rank).

Discussion

The limitations of all prospective studies of HPV infection and malignancy must be highlighted. In particular, while PCR analysis is very sensitive, it does not distinguish between HPV-DNA in malignant or normal adjacent cells. The location of the HPV genomes can be detected with a relatively low degree of sensitivity by *in situ* hybridization.

Employing PCR analysis, HPV-DNA was found in 90% of the samples. With *in situ* hybridization, the signal intensity of viral DNA was heterogeneous and located only in the nucleus of some malignant cells within the tumour population. The accumulation of strongly positive cells in the necrosis area suggests the possibility of viral replication *in vivo*. This reproductive viral cycle *in vivo* may possibly provoke the immune response as indicated by the specific antibodies against HPV antigens in anal cancer patients (2, 3). The inability to detect HPV genomes in the bystander malignant or normal cells may result from the low HPV copy numbers and the low sensitivity of the *in situ* hybridization method.

As in cervical cancer, a high proportion of HPV16-carrying tumours were detected in our anal cancer patients. Double infection with HPV 16 and HPV18 in some of these biopsies suggested the possibility of more than one malignant progenitor cell in the given anal cancer biopsy. Alternatively, one malignant progenitor cell may harbour more than one virus (25).

It has been shown that HPV oncoproteins inhibit the host cell cycle control genes (6, 9, 10, 26). This could explain the significantly increased proportion of cells in the G2 phase of the cell cycle in HPV-positive anal cancer biopsies compared to their HPV-negative counterparts.

A high incidence of DNA aberrations was observed, yet no statistically significant effect on survival time in the anal cancer patients was reported (27). In our study, a low prevalence of DNA aberrations was detected by flow cytometry. The discrepancy in the number of DNA aberrations could be explained by the different methods of analysis. DAPI staining of at least 40,000 single nuclei for each sample was included in the flow cytometry analysis in the present study. Alternatively, error from the glare and shading may have occurred in the earlier generation of non-standardized microphotography analysis method used in the previous investigation (28).

The evolution of HPV related cancer is a complex, multistep process. In tonsil cancer, patients with oncogenic HPV-positive tumours had a better prognosis than their HPV-negative counterparts (29). In contrast, neither HPV status nor DNA aneuploidy were related to the survival of cervical cancer patients (30).

Although high-risk oncogenic HPV was detected in 90% of the anal tumour biopsies, neither HPV status nor DNA alteration were related to survival time in the present study. There may be several explanations for this. One important point could be the low statistical power of detecting such a difference, if it indeed exists. This could possibly be due to the fact that the curability of the disease

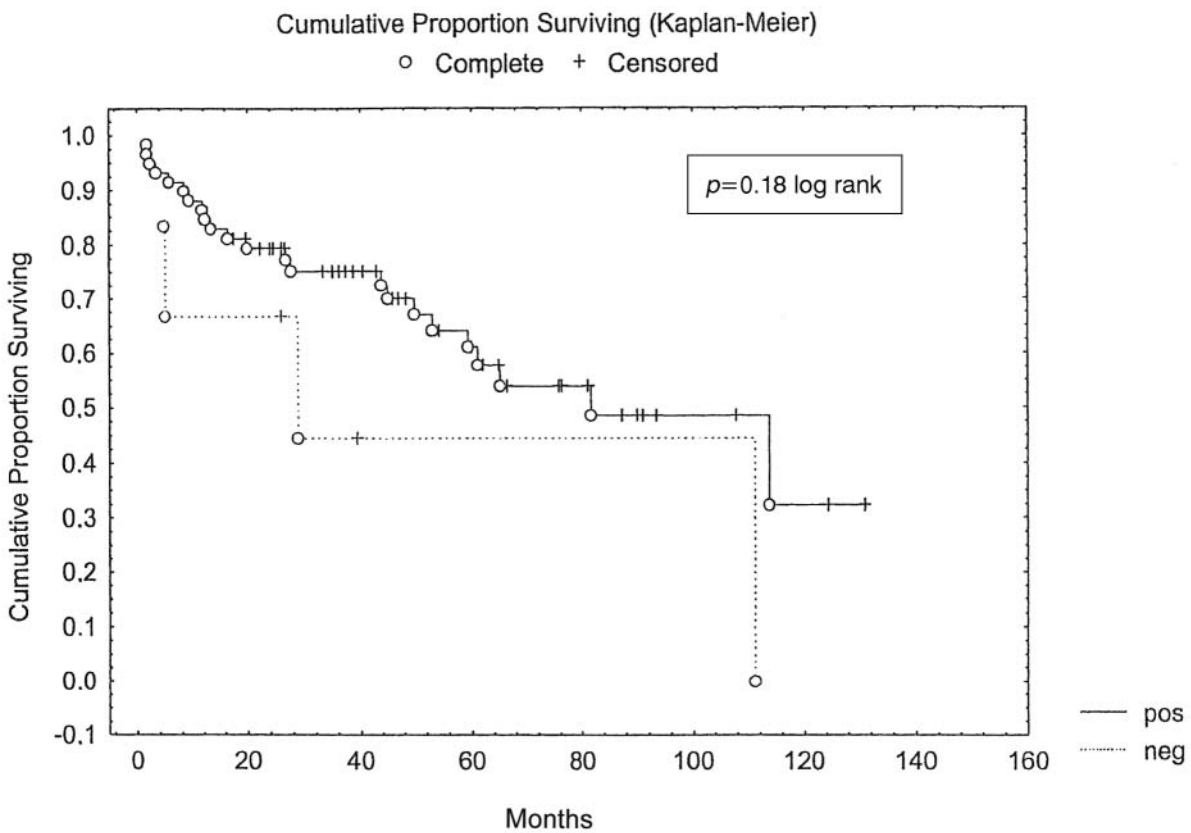

Figure 5. *Survival time of the anal cancer patients.*

is comparatively high. The low number of HPV-negative cases in anal cancer patients could have influenced the statistical outcome. Such a combination may result in a low number of disease-related events. Patient age may also have influenced the clinical outcome, since the median age of our patient population was rather high. As a consequence, a fairly high number of deaths by competing causes should be considered.

Conclusion

The vast majority of anal squamous cell carcinoma biopsies obtained from Scandinavian patients in the present study contained high-risk oncogenic HPV. These were either derived from single infection with HPV 16, 18 or 33, or with double infection with HPV16 and HPV18. The viral reproductive cycle might occur spontaneously *in vivo* as indicated by the accumulation of HPV genome in necrotic areas of the tumours. HPV may be essential for the initiation of host cell proliferation but patient survival time might depend on treatment and age more than infection with a high-risk oncogenic HPV.

Acknowledgements

This study was supported by grants from the Karolinska Institut, Tore Nilsson foundation, Cancer Society in Stockholm and the Cancer Foundation. We wish to thank H. Johansson, C. Lagerros, and T. Södergren for their statistical analysis, technical help and comments. The manuscript was proof-read by English native speakers, J. Erickson and F. Murray.

References

1 Myerson RJ, Karnell LH and Menck HR: The National Cancer Data Base report on carcinoma of the anus. Cancer *80(4)*: 805-815, 1997.
2 Frisch M *et al*: Variants of squamous cell carcinoma of the anal canal and perianal skin and their relation to human papillomaviruses. Cancer Res *59(3)*: 753-757, 1999.
3 Frisch M: On the etiology of anal squamous carcinoma. Dan Med Bull *49(3)*: 194-209, 2002.
4 Bjorge T *et al*: Human papillomavirus infection as a risk factor for anal and perianal skin cancer in a prospective study. Br J Cancer *87(1)*: 61-64, 2002.
5 Lai MD *et al*: Anal cancer in Chinese: human papillomavirus infection and altered expression of p53. World J Gastroenterol *4(4)*: 298-302, 1998.

6 zur Hausen H: Papillomaviruses in human cancers. Proc Assoc Am Physicians *111(6)*: 581-587, 1999.
7 Pfister H: Human papillomaviruses and genital cancer. Adv Cancer Res *48*: 113-147, 1987.
8 zur Hausen H and de Villiers EM: Human papillomaviruses. Annu Rev Microbiol *48*: 427-447, 1994.
9 Syrjanen SM and Syrjanen KJ: New concepts on the role of human papillomavirus in cell cycle regulation. Ann Med *31(3)*: 175-187, 1999.
10 zur Hausen H: Viruses in human cancers. Eur J Cancer *35(8)*: 1174-1181, 1999.
11 Klingelhutz AJ, Foster SA and McDougall JK: Telomerase activation by the E6 gene product of human papillomavirus type 16. Nature *380(6569)*: 79-82, 1996.
12 Cuschieri KS *et al*: Human Papillomavirus testing for the management of low-grade cervical abnormalities in the UK--Influence of age and testing strategy. J Clin Virol *38(1)*: 14-18, 2007.
13 Camus S *et al*: Ubiquitin-independent degradation of p53 mediated by high-risk human papillomavirus protein E6. Oncogene *26(28)*: 4059-4070, 2007.
14 Hanselaar AG *et al*: DNA changes in progressive cervical intraepithelial neoplasia. Anal Cell Pathol *4(4)*: 315-324, 1992.
15 Bollmann R *et al*: Human papillomavirus typing and DNA ploidy determination of squamous intraepithelial lesions in liquid-based cytologic samples. Cancer *99(1)*: 57-62, 2003.
16 Franco EL *et al*: Epidemiology of acquisition and clearance of cervical human papillomavirus infection in women from a high-risk area for cervical cancer. J Infect Dis *180(5)*: 1415-1423, 1999.
17 Carter JJ *et al*: The natural history of human papillomavirus type 16 capsid antibodies among a cohort of university women. J Infect Dis *174(5)*: 927-936, 1996.
18 Hagensee ME *et al*: Detection of cervical antibodies to human papillomavirus type 16 (HPV-16) capsid antigens in relation to detection of HPV-16 DNA and cervical lesions. J Infect Dis *181(4)*: 1234-1239, 2000.
19 Nilsson PJ *et al*: Epidermoid anal cancer: a review of a population-based series of 308 consecutive patients treated according to prospective protocols. Int J Radiat Oncol Biol Phys *61(1)*: 92-102, 2005.
20 de Roda Husman AM *et al*: The use of general primers GP5 and GP6 elongated at their 3' ends with adjacent highly conserved sequences improves human papillomavirus detection by PCR. J Gen Virol *76(Pt 4)*: 1057-1062, 1995.
21 Snijders PJ *et al*: The use of general primers in the polymerase chain reaction permits the detection of a broad spectrum of human papillomavirus genotypes. J Gen Virol *71(Pt 1)*: 173-181, 1990.
22 Strauss S, Desselberger U and Gray JJ: Detection of genital and cutaneous human papillomavirus types: differences in the sensitivity of generic PCRs, and consequences for clinical virological diagnosis. Br J Biomed Sci *57(3)*: 221-225, 2000.
23 Gharizadeh B *et al*: Type-specific multiple sequencing primers: a novel strategy for reliable and rapid genotyping of human papillomaviruses by pyrosequencing technology. J Mol Diagn *7(2)*: 198-205, 2005.
24 Castro J *et al*: Preparation of cell nuclei from fresh tissues for high-quality DNA flow cytometry. Cytometry *14(7)*: 793-804, 1993.
25 Zhang X *et al*: Apoptosis modulation of Epstein-Barr virus-encoded latent membrane protein 1 in the epithelial cell line HeLa is stimulus-dependent. Virology *304(2)*: 330-341, 2002.
26 Friesland S *et al*: Human papilloma virus (HPV) and p53 immunostaining in advanced tonsillar carcinoma – relation to radiotherapy response and survival. Anticancer Res *21(1B)*: 529-534, 2001.
27 Goldman S *et al*: Prognostic significance of clinical stage, histologic grade, and nuclear DNA content in squamous-cell carcinoma of the anus. Dis Colon Rectum *30(6)*: 444-448, 1987.
28 Böcking A and Nguyen V: Diagnostic and prognostic used of DNA image cytometry in cervical squamous intraepithelial lesions and invasive carcinoma. Cancer Cytopathology *102*: 41-54, 2004.
29 Mellin H *et al*: Human papillomavirus (HPV) DNA in tonsillar cancer: clinical correlates, risk of relapse, and survival. Int J Cancer *89(3)*: 300-304, 2000.
30 Jarrell MA *et al*: Squamous cell carcinoma of the cervix: HPV 16 and DNA ploidy as predictors of survival. Gynecol Oncol *46(3)*: 361-366, 1992.

Received June 15, 2007
Revised August 24, 2007
Accepted October 4, 2007