Surgical Management in Lung Metastases from Colorectal Cancer

J. DAHABRE[1], M. VASILAKI[2], G.P. STATHOPOULOS[3], A. KONDAXIS[4], K. ILIADIS[4], G. PAPADOPOULOS[3], J. STATHOPOULOS[3], S. RIGATOS[3], K. VASILIKOS[1] and J. KOUTANTOS[3]

[1]*Thoracic Surgery Clinic, Iatriko Center of Athens, Athens;*
[2]*Oncology Clinic, Iaso General Hospital, Athens;*
[3]*First Oncology Clinic, Errikos Dunant Hospital, Athens;*
[4]*Thoracic Surgery Clinic, Hygeia Hospital, Athens, Greece*

Abstract. *Background: Colorectal cancer is a non-aggressive slow-growing disease. Surgery is often considered for the management of metastases. Chemotherapeutical agents may offer tumor reduction but radical tumor remission can only be achieved by surgery. The aim of the present study was to show the evolution of patients with lung metastases from colorectal cancer, treated with surgery. Patients and Methods: Five hundred and seventy-nine (male 327, female 252, median age 60 years [range 30-87 years], disease stage IV) patients with colorectal cancer were evaluated. Histology showed adenocarcinoma with 94% moderate differentiation. Sixty-six patients (11.40%) had only lung metastasis (single or multiple deposits). Of these 66 patients, 57 were treated with surgery (pneumonectomy, lobectomy or nodule excision) and in 52/57 (91.23%) the tumor was removed. Results: In 29 patients (50.88%) the disease recurred 8 months after surgery, at the earliest; however, no recurrence was observed in 28 patients (49.12%) during 2-8 years of follow-up after the operation. Five-year survival was 32.69%. Conclusion: Metastectomy of lung metastasis from primary colorectal cancer may achieve long-term survival without recurrence in a large percentage of patients.*

One of the metastatic sites of colorectal cancer is the lung, although most commonly, metastases appear in the liver. Multiple organ metastases may also be detected. Chemotherapy is the treatment of choice in advanced colorectal cancer (1-4). Chemotherapy may offer a response rate in a percentage of patients which varies from trial to trial and is usually less than 50%. Median and overall survival is prolonged by chemotherapy, particularly with the addition of newer cytotoxic agents (5-8). Patients with metastatic disease may have a long survival (9-11). Chemotherapy does not cure these patients but, given their long survival, there is time for other treatment management such as surgery. Surgical treatment is radical and can be performed when metastatic lesions are considered operable.

Metastatic disease in the liver is often managed by surgery and there are adequate data that show a prolongation of life in these patients (12-21). Lung metastases can also be treated with surgical excision, but data in the literature are sparse (22, 23). Certain criteria should be taken into account for surgical treatment, the most important of which is the nonexistence of metastatic disease in other organs. Other criteria are the number of metastatic nodules and unilateral or bilateral disease. The age of the patients and the respiratory condition (sufficient respiratory reserve) are also criteria for surgery.

In approximately 10-15% of cases, patients with colorectal cancer may have synchronous metastatic cancer at diagnosis, and in some, recurrence will be in the lungs. It has been pointed out that <10% of patients with lung metastases fulfill selection criteria and are amenable to surgery (23). Treatment for advanced colorectal cancer has improved during the last 10 years and patient survival has been prolonged (24). However, the cure rate and 5-year survival remain very low. Long-term survival of advanced colorectal cancer without recurrence can only be achieved by successful metastasectomy. To proceed in metastasectomy for lung metastases there are certain criteria which are mentioned below (preoperative assessment) (24). The data have shown successful and unsuccessful attempts in sarcomas, soft tissues or osteogenic sarcomas, in head and neck, renal, melanomas and colorectal cancers, with lung metastases (25-31). The first lung metastasectomy, which involved a patient who had two metastatic lesions originating from a chest wall sarcoma, was carried out by Weinlechner in 1882 (32). In 1994, Blalock first reported the surgical resection of pulmonary metastasis from colorectal cancer (33).

In the present study, patients with advanced colorectal cancer and lung metastases were reviewed. The material was collected from four hospitals in Athens over a period of twelve years.

Correspondence to: G.P. Stathopoulos, MD, Semitelou 2A, 115 28 Athens, Greece. Tel: +30 210 7752600, Fax: +30 210 7251736, e-mail: dr-gps@ath.forthnet.gr

Key Words: Colorectal cancer, lung metastasectomy.

Table I. *Patient characteristics.*

	n (%)
Patients accrued	579 (100)
With lung metastases and other sites	127 (21.93)
With only lung metastases	66 (11.40)
Operable	57 (44.88)
Histology: adenocarcinoma	
with moderate differentiation	54/57 (94.73)
Gender	
Male	34/57 (56.65)
Female	23/57 (40.35)
Age (years)	
Median	60
Range	30-87

Table II. *Distribution of lung metastases n=57.*

	n (%)
Unilateral	41 (71.93)
Bilateral	16 (28.07)
Single	34 (59.65)
Multiple	23 (40.35)

Table III. *Surgical results.*

	n (%)
Total number of operations	57 (100)
Successful excision	52 (91.23)
Disease recurrence in lungs	29 (50.88)
No recurrence	28 (49.12)
5-year survival	17 (32.69)

Patients and Methods

Eligibility criteria. Patients with histologically-confirmed advanced colorectal cancer were reviewed. Staging by objective imaging methods was performed. Bidimensionally measurable disease was required. Patients who had lung metastases in one or both lungs were eligible. The size of metastatic disease had to be detectable (preferably 1-5 cm in diameter) and the number of lesions to be reasonably small (up to 10, and occasionally more if concentrated in one lung or one lobe). Patients with a secondary malignancy were excluded. Patients who had had prior chemotherapy treatment were included in the study.

Preoperative assessment. The preoperative assessment included precise radiographic assessment of the primary site and a thorough metastatic assessment and CT scan of the chest. A single metastasis revealed by CT scan, in fact, will be the sole lesion encountered during surgery in 60% to 75% of cases (34). According to existing data, CT scans under-predict the number of lesions in 27-40% of cases and over-predict in 3% (35, 36). Before any decision was made concerning surgical management, an MRI of the brain, CT scan of the abdomen and a bone scan were performed. Pulmonary function studies, FEV1, and occasionally mediastinoscopy or bronchoscopy were evaluated. These examinations confirm that no mediastinal disease, which occasionally occurs, is found.

Further evaluation of the patients included a detailed medical and physical examination, electrocardiogram (ECG) and cardiac ultrasound.

Surgical procedure. Resections after general anesthesia should be performed conservatively, leaving as much of the lung intact as possible: this enables the patient to undergo subsequent resections in case of recurrence, and also to permit the patient to have a reasonable quality of life. Multiple procedures are recommended for patients who develop further metastases provided that the criteria for surgery continue to be fulfilled. Sternotomy was performed in patients with bilateral disease, as recommended.

A follow-up examination including a CT scan after surgery was carried out after 6-8 weeks and then every 6 to 12 months and pulmonary function tests and clinical examination every 2-3 months during the first year. The cancer markers, carcinoembryonic antigen (CEA) and CA-19-9 were examined every 2-3 months.

Patients' characteristics. In the present study, the patients reviewed were accrued over the past 12 years. Lung cancer patients may have a long survival after the appearance of metastatic disease, particularly when the metastasis is only at one site. In order to evaluate survival after metastasectomy, a long follow-up period is necessary. The patients' characteristics are shown in Table I. The number of reviewed patients was 579 from 4 institutions. One hundred and twenty-seven patients had lung metastasis, 66 (51.97%) of whom had no metastatic disease elsewhere. Fifty-seven of the 66 patients had been treated with chemotherapy before any decision was taken for surgery. No patient proceeded to surgical management before a median duration period of 6 months (range 3-12 months) from the time the metastatic lung disease appeared. This was considered necessary in order to confirm that the primary disease was under control and to be sure that no other metastatic disease had, in the meantime, appeared elsewhere.

Chemotherapy given before surgery was initially leucovorin/5-fluorouracil and during the last 8 years irinotecan and/or oxaliplatin were added to the previous regimen.

Patients eligible for surgery. Fifty-seven patients were eligible for surgical excision of the lung deposits. The distribution of lung deposits (unilateral or bilateral [both lungs], single or multiple) is shown in Table II. In the majority of cases, the deposits were single and unilateral. The surgical excision performed in most cases was a lumpectomy. A pneumonectomy was performed in 7% of the patients, bilobectomy in 7%, lobectomy in 41% of the patients and wedge resection or segmentectomy in the remaining 45%.

Statistical analysis. The primary end-point of the study was overall survival which was calculated from the day of the surgical excision for lung deposits until death or the end of the study. The median probability of survival was estimated by the Kaplan-Meier method.

Results

The vast majority of the patients underwent successful surgery with excision of the lung deposits. In Table III, which shows the surgical results, recurrence and 5-year survival are presented: 91.23% of the patients who had surgery had a complete excision of the metastatic nodules. Only in 5 patients was the disease found to be inoperable during the surgery. No operative or postoperative events were observed. In 29 (50.88%) patients, the disease recurred at the earliest, 8 months after the surgery. No recurrence was observed in 28 (49.12%) patients during the 2-8 years of follow-up post surgery. Five-year survival was 32.69%; patients who underwent surgery in less than 5 years (until the end of the study) and who were still without recurrence were considered. Figure 1 shows the Kaplan Meier survival curve. Median survival was 42 months (95% confidence interval (CI) 8-76 months). The great majority of patients (70.58%) who had recurrent disease, presented with it within the first 2 years.

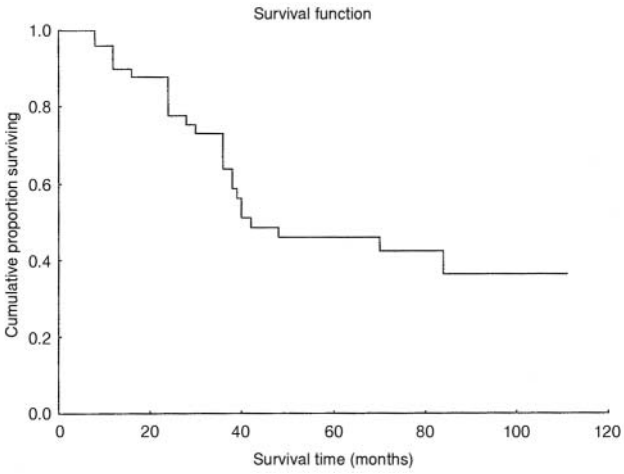

Figure 1. *Kaplan Meier survival distribution estimation.*

Discussion

The improvement in survival of patients with metastatic colorectal cancer is due to better treatment related to chemotherapy with new cytotoxic agents. Furthermore, survival prolongation has been achieved by the administration of antiangiogenic drugs (bevacizumab) (37). However, the cure rate and 5-year survival have only been affected in a limited number of patients with metastatic operable disease. In our study, 52 out of the 57 patients with lung metastases who underwent surgery had a successful surgical outcome and the 5-year survival was 32.69%. These patients could be considered cured despite the advanced disease.

Several other studies have shown similar results. A trial involving 62 patients operated on for lung metastatic disease from colorectal cancer was published nearly 20 years ago. The cumulative 5-year survival was 42% (31). A more recently published study reviewed 80 patients over 20 years and showed a 41% 5-year survival (38). A higher percentage of 5-year survival, 48%, was documented in another review concerning 47 patients treated with lung metastasectomy over 15 years (39). Four other review studies also dealing with lung metastases excision from colorectal cancer were based on groups of 38 to 159 patients and showed that the 5-year survival was: 31% (40), 43% (41), 40% (42) and 41% (43). Therefore, the 5-year survival in all these studies, including ours, ranges from 31% to 48%. The results of our study show the necessity for metastasectomy of lung deposits from colorectal cancer, as previous studies have also indicated.

Colorectal cancer is a non-aggressive slow-growing disease and the one-organ site of metastases is often not followed by metastases in other organs. This fact allows surgical management to be carried out if necessary.

References

1. Moertel CG: Chemotherapy for colorectal cancer. N Engl J Med *330*: 1136-1142, 1994.
2 Francini GP and Lorenzini L: Folinic acid and 5-fluorouracil as adjuvant chemotherapy in colon cancer. Gastroenterology *106*: 899-904, 1994.
3 Sargent DJ, Niedzwiecki D, O'Conell MJ and Schilsky RL: Recommendation for caution with irinotecan, fluorouracil and leucovorin for colorectal cancer. N Engl J Med *345*: 144-1445, 2001.
4 Cunningham D, Pyrhonene S, James RD, Punt CTA, Hickish TF and Heikkila R: Randomized trial of irinotecan plus supportive care *versus* supportive care alone after fluorouracil failure for patients with metastatic colorectal cancer. Lancet *352*: 1413-1418, 1998.
5 De Gramont A, Figer A, Seymour M, Homerin M, Hmissi A and Cassidy J: Leucovorin and fluorouracil with or without oxaliplatin as first-line treatment in advanced colorectal cancer. J Clin Oncol *18*: 2938-2947, 2000.
6 Douillard JY, Sobrero A, Carnaghi C, Comella P, Diaz-Rubio E, Santoro A and Van Cutsen E: Metastatic colorectal cancer: Integrating irinotecan into combination and sequential chemotherapy. Ann Oncol *14*: ii7-ii12, 2003.
7 Sorbye H, Glimelius B, Berglund A, Fokstuen T, Tueit KM and Broendengen M: Multicenter phase II study of Nordic fluorouracil and folinic acid bolus schedule combined with oxaliplatin as a first-line treatment of metastatic colorectal cancer. J Clin Oncol *22*: 31-38, 2004.
8 Goldberg RM, Sargent DJ, Morton RF, Fuchs CS, Ramanathan RK and Williamson SK: A randomized controlled trial of fluorouracil plus leucovorin, irinotecan, and oxaliplatin combinations in patients with previously untreated metastatic colorectal cancer. J Clin Oncol *22*: 23-30, 2004.
9 Tournigand C, André T, Achille E, Lledo G, Flesh M and Mery-Mignard D: FOLFIRI followed by FOLFOX6 or the reverse sequence in advanced colorectal cancer: a randomized GERCOR study. J Clin Oncol *22*: 229-237, 2004.

10 Stathopoulos GP, Rigatos SK, Malamos NA, Stathopoulos J, Thallassinou P, Papazachariou E *et al*: Long-term survival of patients with advanced colorectal cancer may not be due to the response to chemotherapy. Oncology Reports *12*: 1295-1300, 2004.
11 Stathopoulos GP, Rigatos SK, Stathopoulos JG, Xynotroulas JP and Dimou E: Efficacy and tolerability of oxaliplatin plus irinotecan, 5-fluorouracil and leucovorin regimen in advanced stage colorectal cancer patients pretreated with irinotecan, 5-fluorouracil and leucovorin. Am J Clin Oncol *28*: 565-569, 2005.
12 Rivoire M, De Cian F, Meeus P, Negrier S, Seban H and Kaemmerlen P: Combination of neoadjuvant chemotherapy with cryotherapy and surgical resection for the treatment of unresectable liver metastases from colorectal carcinoma. Cancer *95*: 2283-2292, 2002.
13 Poston GJ, Adam R, Alberts S, Curley S, Figueras J and Haller D: OncoSurge: A strategy for improving resectability with curative intent in metastatic colorectal cancer. J Clin Oncol *23*: 7125-7134, 2005.
14 Fong Y, Cohen AM, Fortner JG, Enker WE, Turnbull AD and Coit DG: Liver resection for colorectal metastases. J Clin Oncol *15*: 938-946, 1997.
15 Rees M and John TG: Current status of surgery in colorectal metastases to the liver. Hepatogastroenterology *48*: 341-344, 2001.
16 Malafosse R, Penna C, Sa Cunha A and Nordlinger B: Surgical management of hepatic metastases from colorectal malignancies. Ann Oncol *12*: 887-894, 2001.
17 Bismuth H, Adam R, Levi F, Farabos C, Waechter F and Castaing D: Resection of nonresectable liver metastases from colorectal cancer after neoadjuvant chemotherapy. Ann Surg *224*: 509-520, 1996.
18 Adam R, Avisar E, Ariche A, Giachetti S, Azoulay D and Castaing D: Five year survival following hepatic resection after neoadjuvant therapy for nonresectable colorectal. Ann Surg Oncol *8*: 347-353, 2001.
19 Adam R: Chemotherapy and surgery. New perspectives on the treatment of unresectable liver metastases. Ann Oncol *14*: ii13-ii16, 2003.
20 Pozzo C, Basso M, Cassano A, Quirino M, Schinzari G and Trigila M: Neoadjuvant treatment of unresectable liver disease with irinotecan and 5-fluorouracil plus folinic acid in colorectal cancer patients. Ann Oncol *15*: 933-939, 2004.
21 Heriot AG, Reynolds J, Marks CG and Karanjia N: Hepatic resection for colorectal metastases: A national perspective. Ann Royal Coll Surg Eng *86*: 420-424, 2004.
22 Todd TR: Pulmonary metastasectomy. Current indications for removing lung metastases. Chest *103*: 401s-403s, 1993.
23 Negri F, Musolino A, Cunningham D, Pastorino U, Ladas G and Norman RA: A retrospective study of resection of pulmonary metastases in patients with advanced colorectal cancer: The development of a preoprative chemotherapy strategy. Clinical Colorectal Cancer *2*: 101-106, 2004.
24 Patterson GA, Todd TRJ. Ilves R, Pearson FG and Cooper JD: Surgical management of pulmonary metastases. Can J Surg *25*: 102-105, 1982.
25 Mountain CF, Mc Murtry MJ and Hermes KE: Surgery for pulmonary metastases: a 20 year experience. Ann Thor Surg *38*: 323-330, 1984.
26 McCormack P: Surgical resection of pulmonary metastases. Semin Surg Oncol *6*: 297-302, 1990.
27 Harpole DH, Johnson CM, Wolfe WG, George SL and Seigler HF: Analysis of 940 cases of pulmonary metastatic melanoma. J Thorac Cardiovasc Surg *103*: 743-750, 1992.
28 Brister SJ, De Varennes B, Gordon PH, Sheiner NM and Pym J: Contemporary operative management of pulmonary metastases of colorectal origin. Dis Colon Rectum *31*: 786-792, 1988.
29 Putnam JB, Roth JA, Wesley WN, Johnston MR and Rosenberg SA: Analysis of prognostic factors in patients undergoing resection of pulmonary metastases from soft tissue sarcomas. J Thorac Cardivasc Surg *87*: 260-268, 1984.
30 Mori M, Tomoda H, Ishida R, Kido A, Shimono R and Matsushima T: Surgical resection of pulmonary metastases from colorectal adenocarcinoma. Arch Surg *126*: 1297-1301, 1991.
31 Goya T, Miyazawa N, Kondo M, Tsuchiva R and Naruke T: Surgical resection of pulmonary metastases from colorectal cancer: 10 years follow up. Cancer *64*: 1418-1421, 1989.
32 Weinlechner JW: Kasuistik der Tumoren an der Brustwand und deren Behandlung (Resektion der Rippen, Eroffncing der Brusthonle, Partielle, Partille Entfernung der lunge). Wein Med Wochenschr *32*: 589-591, 624-628, 1882.
33 Blalock A: Recent advances in Surgery. N Engl Med *231*: 261-267, 1994.
34 Goldstraw P: The surgical treatment of pulmonary metastases. Helv Chir Acta *56*: 791-797, 1989.
35 Swoboda L and Tomes H: Results of surgical treatment for pulmonary metastases. J Thorac Cardivasc Surg *34*: 149-152, 1986.
36 Freidman B, Bohndorf K and Kruga J: Radiology of pulmonary metastases: comparison of imaging techniques with operative findings. Thorac Cardiovasc Surg *34*: 120-124, 1986.
37 Giantonio BJ, Catalano PJ, Meropol NJ, O'Dwyer PJ, Mitchell EP and Alberts SR: High-dose bevacizumab improves survival when combined with FOLFOX4 in previously treated advanced colorectal cancer: results from Eastern Coopertaive Oncology Group (ECOG) study E 3200. J Clin Oncol *23*: Suppl. 16s [abstract], 2005.
38 Rena O, Casadio C, Viano F, Cristofori R, Ruffini E and Filloso PL: Pulmonary resection for metastases from colorectal cancer: factors influencing prognosis. Twenty years experience. Eur J Cardiothorac Surg *21*: 906-912, 2002.
39 Sakamoto T, Tsubota N, Iwanaga K, Yuki T, Matsuoka H and Yoshimura M: Pulmonary resection for metastases from colorectal cancer. Chest *119*: 1069-1072, 2001.
40 McAfee MK, Allen MS, Trastek VF, Ilstrup DM, Deschamps C and Pairolero PC: Colorectal lung metastases: results of surgical excision. Ann Thorac Surg *53*: 780-786, 1992.
41 Headrick JR, Miller DL, Nagorney DM, Allen MS, Deschamps C, Trastek VF and Pairolero PC: Surgical treatment of hepatic and pulmonary metastases from colon cancer. Ann Thorac Surg *71*: 979-980, 2001.
42 McCormack PM and Ginsberg RJ: Current management of colorectal metastases to lung. Chest Surg Clin North Am *8*: 119-126, 1998.
43 Okomura S, Kondo H, Tsuboi M, Nakayama D, Asamura H, Tsuchiya R and Naruke T: Pulmonary resection for metastatic colorectal cancer: experiences with 159 patients. J Thorac Cardiovasc Surg *112*: 857-874, 1996.

Received May 11, 2007
Accepted August 30, 2007