Hepatic Intra-arterial Interferon Alpha 2b-based Immunotherapy Combined with 5-Fluorouracil (5-FU)-based Systemic Chemotherapy for Patients with Hepatocellular Carcinoma (HCC) not Responsive and/or not Eligible for Conventional Treatments: A Pilot Study

FELICE VITO VITALE[1], PLACIDO ROMEO[2], FABIO VASTA[3], VINCENZO PANEBIANCO[3], STEFANIA CALÌ[1], STEFANO ROTONDO[4], FRANCESCO FERRAÙ[1] and MICHELE LA GRECA[1]

[1]*Division of Medical Oncology,* [2]*Interventional Radiology Operative Unit and* [3]*Division of Surgical Oncology, San Vincenzo Hospital Taormina;* [4]*Internal Medicine Service Centro Studi Neurolesi, "IRCCS" "Bonino Pulejo" Messina, Italy*

Abstract. *Background: Surgery (partial hepatic resection or orthotopic liver transplantation) remains the mainstay for treatment of hepatocellular carcinoma (HCC). Unfortunately, most patients have HCC that cannot be removed either as a result of its size, multiple tumors, location, proximity to major vessels or ducts within the liver, and comorbidity, such as a not well-compensated cirrhosis. For patients who cannot be treated surgically, systemic chemotherapy is frequently limited by unacceptable toxicity, poor response and low survival rates, so that locoregional approaches may be considered as alternatives. Patients and Methods: Nine patients with HCC, not eligible for conventional treatments, were treated with interferon alpha 2b-based locoregional, hepatic intra-arterial, immunotherapy and concomitant 5-fluorouracil (5-FU)-based systemic chemotherapy. Interferon was administered at a starting dose of 2,000,000 IU, which could be escalated to 9,000,000 IU, adding 1,000,000 IU weekly, depending on toxicity. 5-Fluorouracil was infused continuously over 28 days, administered as an endovenous protracted infusion weekly at a dose of 250 mg/m^2/day for 4 weeks followed by a 2-week break. Eight out of nine patients were evaluable for response and toxicity. The median patient age was 68 years (range 51-77 years). All patients were suffering from cirrhosis. Results: A total of 29 cycles of treatment were administered with a median of 3.6 per patient (range 1-11 per patients). A partial response was observed in 3 out of 8 patients; 1 had stable and 4 progressive disease. The main toxicities were: grade 3 hepatic toxicity (1 patient), grade 3 flu-like syndrome (1 patient) and grade 3 abdominal pain (1 patient). Moreover, one patient developed fatal ischemic stroke and another a fatal central venous catheter infection. Conclusion: The preliminary data, show that an interferon-based hepatic intra-arterial immunotherapy combined with low doses of 5-fluorouracil (5-FU)-based systemic chemotherapy, can represent a tolerable combination to apply in the palliative treatment of patients with hepatocellular carcinoma.*

Correspondence to: Felice Vito Vitale, MD, Division of Medical Oncology, Ospedale San Vincenzo, Contrada Sirina 98039 Taormina (ME), Italy. Tel: +39 0942 579420, Fax: +39 0942 52215, e-mail: vitale.dr.felice@tiscali.it

Key Words: Hepatocellular carcinoma, hepatic intra-arterial immunotherapy, interferon alpha 2b, non resectable.

Regional therapies based on transarterial chemoembolization (TACE), radiofrequency ablation, percutaneous ethanol injection (PEI) and hepatic intra-arterial chemotherapy, have an undisputed place in the therapeutic armamentarium for hepatocellular carcinoma. Many patients with unresectable HCC are not chemoembolization candidates, either because of extensive disease or severely impaired hepatic function. On the other hand, systemic aggressive chemotherapy leads to poor therapeutic results and often significant toxicity (1). Several papers concerning biological response modifier (BRM) intra-arterial (*i.a.*) administration in patients carrying intrahepatic carcinomas have drawn intriguing scenario. There is evidence that interferons and interleukin-2 are able to activate the tumor infiltrating lymphocytes and their intrahepatic arterial administration may be beneficial to cancer patients (2-5). Furthermore, there is substantial evidence that the liver is a large immunological organ harboring a large amount of lymphocytes and macrophages such as hepatic sinusoidal lymphocytes (HSL) (known as liver-associated natural killer (NK) cells), Kuppfer cells and cytotoxic T cells. (6-8). Interferon (IFN)-alfa and 5-FU

Table I. *Characteristics of the eligible patients.*

Characteristics	No. of patients
Total	8
Age (years)	
median	68
range	51-77
ECOG performance status	
0	1
1	2
2	2
3	3
Extent of liver involvement	
A few (1-3) lesions	2
Several (4-10) lesions	3
Diffuse (>10) lesions/>50% of the total liver	3
Comorbidities	
Hepatitis virus infection evidence	6
HCV	5
HBV+ HCV	1
Cirrhosis	8
Child-Pugh cirrhosis score	
A	3
B	4
C	1
Partial portal vein thrombosis	3
Diabetes	2

Table II. *Previous treatments.*

Type	No. of patients
Systemic chemotherapy	0
Hepatic intraarterial chemoembolization	4
Partial hepatic resection	1
Interferon	3

synergism against cancer is well recognized. More importantly, their combination has shown activity against HCC (9-11). Here we aimed to determine the feasibility and toxicity of interferon alpha 2b given *i.a.*, combined with systemic endovenous 5-FU, in patients with HCC not responsive and/or not eligible for conventional treatments.

Patients and Methods

Eligibility for the study was defined by any of the following criteria: a) patients not eligible for conventional treatments; b) liver as the only disease site; c) an adequate baseline bone marrow reserve defined as neutrophil count ≥1,500 per mm^3; platelet count ≥50,000 μL; haemoglobin level >9.5 g/dL; d) an adequate baseline hepatic function defined as a total bilirubin level ≤3 mg/dL, AST (aspartate transaminase) and ALT (alanine transaminase) ≤4 x the upper limits of normal, serum albumin level >2 g/dl; e) adequate renal function defined as serum creatinine concentration <1.5 mg/dL. Patients were excluded when they had one or more of the following: a) evidence of complete portal vein thrombosis; b) refractory ascites; c) extensive liver involvement >60%; d) prothrombin time (PT) more than 5 s longer than the normal control; e) fibrinogenemia <100 mg/dL; e) previous esophageal varices bleeding. Baseline fetoprotein (AFP) levels and ferritin levels were measured. Tumors were assessed by computed tomography (CT) and/or magnetic resonance (MR) scans. IFN alpha 2b was administered into the hepatic artery as a 48-h continuous infusion, weekly for 5 weeks followed by one week break. This study adopted an interferon dose-escalating protocol: interferon was administered at a starting dose of 2,000,000 IU, which could be escalated to 9,000,000 IU, adding 1,000,000 IU weekly, depending on toxicity. 5-Fluorouracil was infused continuously over 28 days administered as an endovenous protracted infusion weekly at a dose of 250 mg/m^2/day for 4 weeks followed by a 2-week break.

Intra-arterial IFN and 5-FU endovenous infusion were performed using an elastomeric balloon reservoir (balloon pump). The catheters were percutaneously placed through a transaxillary access into the hepatic artery and subclavean vein; each proximal ending was connected to a subclavear port-a-cath. Informed consent according to institutional regulations was obtained from all patients prior to study entry. Serum biochemistry studies were performed before every course of chemo-immunotherapy, and during the course if clinically indicated. Regarding the dose modifications within a cycle, the dose of interferon alpha 2b and 5-FU was omitted if the absolute neutrophil count was less than $1.0x10^9$/l, the platelet count was less than $50x10^9$/l, the total bilirubin level was >3 mg/dL or AST and ALT were >4x the upper limits of normal. For dose adjustments in the subsequent administration, the dose of interferon was reduced to the starting level of 2,000,000 IU.

Subsequent dose escalation to the original dosage was allowed, provided that the patient had tolerated the lower doses given. An evaluation of response was performed after the first two cycles of chemotherapy (three months), and every two cycles thereafter. Types of response were also assessed according to established Eastern Cooperative Oncology Group (ECOG) criteria (11).

Responding patients and those with stable disease continued treatment until progression or the completion of at least six courses. Survival was measured from administration of the first dose until the date of death or last follow-up. Study drug-related adverse events and toxicities were recorded following established ECOG criteria (12).

Results

Patients characteristics. From August 2004 to September 2006, nine patients were entered on the study. One was unevaluable for response and toxicity due to a worsening clinical picture and death before the evaluation of response. Eight patients were evaluable for response and toxicity. Tables I and II show the main characteristics and baseline parameters, respectively, of the eight eligible patients, most of whom had both poor performance status (range, 1-3; median 2) and high Child-Pugh score. The median age was 68 years (range, 51-77 years). With regard to gender, 1

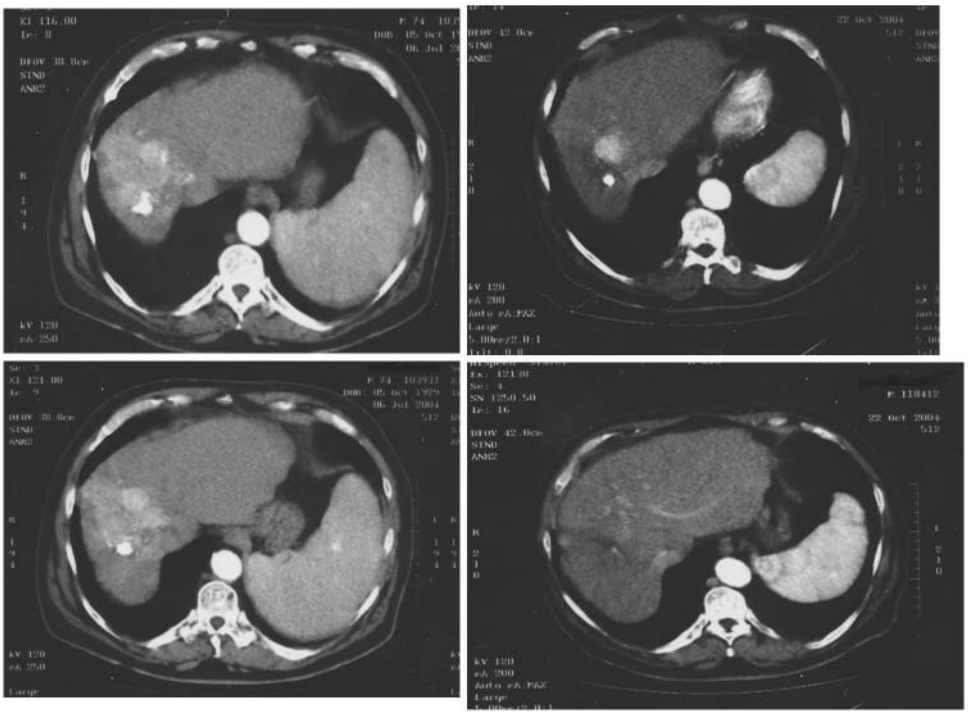

Figure 1. *CT scan of the liver at baseline (left) and after 2 cycles of therapy (right) in patient A.*

patient was female and 7 were male. All the patients were suffering from cirrhosis. Furthermore, six out of eight showed evidence of hepatitis virus infection: 5 had hepatitis C virus and 1 had concomitant hepatitis B virus and hepatitis C virus-related disease. CT scan revealed 3 patients with partial portal vein thrombosis. Two patients showed baseline platelets count <100,000/μL (minimum 65,000/μL). Most patients had baseline total bilirubin in excess of the normal limit: median 0.8 mg/dL (range 0-1.9 mg/dL).

Previous treatments. None of the patients had undergone systemic chemotherapy. Four patients had been administered hepatic intra-arterial chemoembolization; 1 patient had undergone partial hepatic resection. Moreover, it should be noted that 3 patients had alredy received systemic interferon-based treatments (Table II).

Response to treatment and survival. The objective responses included partial response in 3 out of 8 patients, stable disease in 1 and progressive disease in 4. The median survival was 11.5 months (range 2-26+ months) and the 2-year survival rate was 25%. Figures 1 and 2 show the objective response in patients A and C, respectively. The final date of updating the survival parameters was April 2007. Six patients have died and 2 are alive to date, with individual outcomes of 26+ and 24+ months (Table III).

Therapy-related toxicities and complications. None of the patients developed G3-G4 thrombocytopenia. No febrile grade 3 neutropenia was seen in one patient; grade 3 hepatic toxicity was observed in two patients; 1 patient experienced G3 flu-like syndrome and another one grade 3 abdominal pain. Two patients who were included in the present study developed ischemic stroke (1 fatal) and another a central venous catheter infection with subsequent fatal endocarditis.

Compliance with treatment. A total of 29 treatment cycles were administered with a median of 3.6 per patient (range 1-11 per patient). Dose reductions or omissions for myelosuppresion and/or other toxicities were required for 5 out of 8 patients. Five patients received at least one cycle with the highest interferon planned dose (9,000,000 IU). For three pts the interferon dose escalation was stopped at doses ranging from 2,000,000 IU to 3,000,000 IU because of G3 flu-like syndrome (1 patient) and a significant increase in the bilirubinemia level (>4 mg/dL, 2 pts). With regard to systemic 5-fluorouracil administration, no dose reduction was required.

Discussion

The hepatic intra-arterial administration of BRMs would in theory be better able to activate cellular components of the immune system, such as tumour-infiltrating lymphocytes

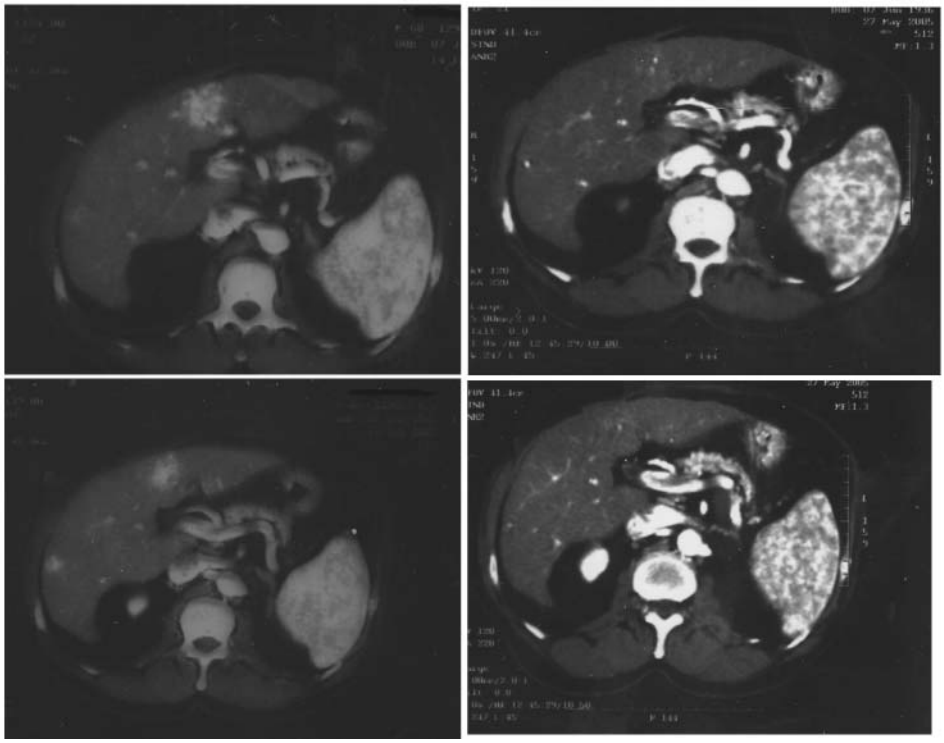

Figure 2. *CT scan of the liver at baseline (left) and after 2 cycles of therapy (right) in patient C.*

Table III. *Baseline parameters, treatment and results in individual patients.*

Patient	Baseline laboratory values				No. of cycles	Final IFN dose	Response	Present status	Survival (months)
	AST[1]	ALT[1]	TB[1]	PLT					
A	36	6	0,8	65,000/μl	11	9x10^6 IU	PR	Dead	16
B	0	0	0	>100,000/μl	2	9x10^6 IU	PD	Alive	26+
C	0	0	0	>100,000/μl	2	9x10^6 IU	PR	Dead	4
D	12	14	0	>100,000/μl	5	9x10^6 IU	SD	Alive	24+
E	108	52	1,8	>100000/μl	5	9x10^6 IU	PR	Dead	11
F	70	86	1,9	>100000/μl	1	3x10^6 IU	PD	Dead	4
G	43	11	1,6	72000/μl	1	3x10^6 IU	PD	Dead	2
H	143	162	0,3	>100000/μl	2	4x10^6 IU	PD	Dead	8

[1]Upper normal limit, 50 U/L; 72 U/L; 1.1 mg/dL respectively). AST: aspartate transaminase; ALT: alanine transaminase; TB: total bilirubin. PLT: platelets. PR: partial response; SD: stable disease; PD: progressive disease; CR: complete response.

(TIL), located in the liver and in hold proximity to the cancer cells. The immunomodulatory and cytotoxic effect of several BRMs, such as interleukin-2 (IL2), interferons (IFNs) and granulocyte-monocyte colony stimulating factor (GM-CSF), administered through the hepatic artery, have been tested by various physicians in the past decade (3, 13-16). With regard to interferon, it is known that concomitant IFN alpha and 5-FU administration leads to thymidine phosphorylase gene expression up-regulation and subsequent increased level of the 5-FU active metabolite

Table IV. *Main therapy-related toxicities and complications.*

Type	No. of patients
Thrombocytopenia G3-4	0
Neutropenia G3-4	1
Flu-like syndrome G3-4	1
Ischemic stroke	2 (1 fatal)
Central venous catheter-related endocarditis	1 (fatal)
Hepatic G3-4	2
Abdominal pain G3-4	1

fluorodeoxyuridine monophosphate (FdUMP) (17). Moreover, combination of IFN-alpha and 5-fluorouracil is able to increase apoptosis through IFN-alpha/beta receptor in human hepatocellular carcinoma cells (18-20).

Furthermore, IFN may enhance the activity of cytotoxic T cells and natural killer lymphocytes (21, 22). The preliminary data here show that an IFN-alpha 2b based hepatic intra-arterial treatment combined with low doses of 5-FU based systemic chemotherapy is a well-tolerated therapy for patients suffering from hepatocellular carcinoma who have compromised liver function. Our innovative experience seems to be a therapeutically promising option for patients not eligible for conventional treatments.

References

1 Aguayo A and Patt YZ: Non surgical treatment of hepatocellular carcinoma. Sem Oncol *28(5)*: 503-515, 2001.

2 Yuen MF, Ooi CG, Hui CK, Wong WM, Wong BC, Chan AO and Lai CL al: A Pilot Study of Transcatheter Arterial Interferon Embolization for Patients with Hepatocellular Carcinoma. Cancer *97(11)*: 2776-2782, 2003.

3 Okuno K and Yasutomi K: Locoregional immunochemotherapy in liver carcinoma present and future. Hepatogastroenterology *42*: 578-586, 1995.

4 Baba H, Matsumoto G and Truta K: Successful hepatic arterial infusion therapy of CDDP/5-FU/IFN-beta3 for recurrent hepatocellular carcinoma. Gan To Kagaku Ryoho *31(11)*: 1705-1707, 2004 (in Japanese).

5 Takami Sato: Locoregional immuno(bio)therapy for liver metastases. Sem Oncol *29(2)*: 160-167, 2002.

6 Bouwens L and Wisse E: Tissue localization and kinetics of pit cells or large granular lymphocytes in the liver of rats treated with biological response modifiers. Hepatology *8*: 46-52, 1988.

7 Yuh K, Shimizu M, Aoyama S, Ichinara I, Watanabe H, Okumura M and Kikuchi M: Immunological analysis and characterization of lymphocytes subsets in specimens of human hepatocellular carcinomas and metastatic liver cancer. Cancer Immunol Immunother *28*: 1-8, 1989.

8 Bouwens L and Wisse E: Hepatic pit cells have natural cytotoxic (NC) activity against solid tumor-derived target cells. *In*: Cells of the Hepatic Sinusoid. Wisse E, Knook DL and Decker K (eds.). Rijswijk: Kupffer Cell Foundation, pp. 215-220, 1989.

9 Patt YZ. Yoffe B, Charnsangavej C, Pazdur R, Fischer H, Cleary K, Roh M, Smith R, Noonan CA and Levin B: Low serum alpha-fetoproteinlevel in patients with hepatocellular carcinoma as a predictor of response to 5-FU and interferon-alpha 2b. Cancer *72*: 2574-2582, 1993.

10 Patt YZ, Hassan MM, Lozano RD, Brown TD, Vauthey J, Curley SA and Elis LM: Phase II Trial of systemic continous fluorouracil and subcutaneous recombinant interferon alpha-2b for treatment of hepatocellular carcinoma. J Clinical Oncol *21(3)*: 421-427, 2003.

11 Yin XY, Lü MD, Liang LJ, Lai JM, Li DM and Kuang M: Systemic chemo-immunotherapy for advanced-stage hepatocellular carcinoma. World J Gastroenterol *11(16)*: 2526-2529, 2005.

12 Oken MM, Creech RH, Tormey DC, Horton J, Davis TE, McFadden ET and Carbone PP: Toxicity and response criteria of the Eastern Cooperative Oncology Group. Am J Clin Oncol *5*: 649-655, 1982.

13 Oka M, Hazama S, Suzuki M, Ogura Y, Kobayashi N and Suzuki T: Histological analysis of hepatocellular carcinoma treated by intraarterial combined immunochemotherapy. Hepatogastroenterology *42*: 561-566, 1995.

14 Lygidakis N J, Konstantinidou T and Pothoulakis J: Pre and post-operative adjuvant targeting locoregional chemotherapy combined with locoregional targeting immunostimulation and surgical resection for hepatocellular carcinoma. A new promising alternative. Anticancer Research *14(3B)*: 1351-1355, 1994.

15 Muller H: Immunochemoembolization as induction chemotherapy of unresectable colorectal liver metastasis. Focus on locoregional cancer therapy: from neoadjuvant to palliative treatments. International Congress, Ravenna (Italy) March 12-15, 2000. Abstracts book: 70, 2000.

16 Oka M, Hazama S, Suzuki M, OguraY, Kobayashi N and Suzuki T: Histological analysis of hepatocellular carcinoma treated by intraarterial combined immunochemotherapy. Hepatogastroenterology *42*: 561-566, 1995.

17 Braybrooke JP, Propper DJ, O'Byrne KJ, Koukourakis MI, Patterson AV, Houlbrook S, Love SD, Varcoe S, Taylor M, Ganesan TS, Talbot DC and Harris AL: Induction of thymidine phosphorylase as a pharmacodynamic end point in patients with advanced carcinoma treated with 5-fluorouracil, folinic acid and interferon alfa. Br J Cancer *83*: 219-224, 2000.

18 Kondo M, Nagano H, Wada H, Damdinsuren B, Yamamoto H, Hiraoka N, Eguchi H, Miyamoto A, Yamamoto T, Ota H, Nakamura M, Marubashi S, Dono K, Umeshita K, Nakamori S, Sakon M and Monden M: Combination of IFN-alpha and 5-fluorouracil induces apoptosis through IFN-alpha/beta receptor in human hepatocellular carcinoma cells. Clin Cancer Res *11(3)*: 1277-1286, 2005.

19 Oie S, Ono M, Yano H, Maruyama Y, Terada T, Yamada Y, Ueno T, Kojiro M, Hirano K and Kuwano M: The up-regulation of type I interferon receptor gene plays a key role in hepatocellular carcinoma cells in the synergistic antiproliferative effect by 5-fluorouracil and interferon-alpha.Int J Oncol *29(6)*: 1469-1478, 2006.

20 Damdinsuren B, Nagano H, Wada H, Noda T, Natsag J, Marubashi S, Miyamoto A, Takeda Y, Umeshita K, Doki Y, Dono K and Monden M: Interferon alpha receptors are important for antiproliferative effect of interferon-alpha against human hepatocellular carcinoma cells. Hepatol Res *37(1)*: 77-83, 2007.

21 von Hoegen P: Synergistic role of type I interferons in the induction of protective cytotoxic T lymphocytes. Immunol Lett *47*: 157-162, 1995.

22 Zarling JM, Eskra L, Borden EC, Horoszewicz J and Carter WA: Activation of human natural killer cells cytotoxic for human leukemia cells by purified interferon. J Immunol *126*: 203-209, 1979.

Received June 11, 2007
Revised September 25, 2007
Accepted October 2, 2007