

## Pleomorphic Adenoma of the Salivary Glands: Analysis of 94 Patients

REINHARD E. FRIEDRICH, LEI LI, JOERG KNOP, MANFRED GIESE and RAINER SCHMELZLE

*Maxillofacial Surgery Clinic, Eppendorf University Hospital, University of Hamburg, Hamburg, Germany*

**Abstracts.** *Pleomorphic adenoma is a benign epithelial tumor of adenoid structure preferentially arising from the parotid gland. It was shown that complete tumor excision is a curative measure and recurrence is likely in incompletely excised tumors. The aim of this study was to analyse the outcome of patients with pleomorphic adenoma from salivary glands in order to evaluate the surgical strategy of a single institution. Materials and Methods: The files of 94 patients were evaluated. Special attention was given to the development of malignancy in pleomorphic adenoma. Results: The pleomorphic adenoma preferentially originated in the parotid gland (n=73; right 48, left: 25), and rarely in other glands. The tumor occurred more often in females than in males (45:28, parotid). In 73 patients a slowly growing swelling of the parotid was first noted, which was located at different sites within the gland. At least one recurrence was noted in 18 patients, the majority of them aged 50 to 70 years (n=12). Malignant transformation to carcinoma was found in 8.5%. Conclusion: Pleomorphic adenoma from salivary glands is a benign tumor. However, in a noteworthy number of patients, inside the benign tumor a phenotype develops with distinct properties of malignancy. Surgery with safety margins is the therapy of choice. Multinodular tumors are prone to recurrent disease.*

Pleomorphic adenoma (PA) is the most frequent benign salivary gland tumor, preferentially diagnosed in the parotid gland: about 85% of PA originate from the parotid (8). PA constitutes about 75% of parotid tumors (9). Ablative surgery is the therapy of choice (4). Local recurrence after surgery has been attributed to different factors: the type of surgery

(i.e. enucleation or lateral parotidectomy), lesions of the pseudocapsule due to intraoperative maneuvers, and insufficient preoperative diagnostics leading to an understimation of tumor extension, in particular in cases with multifocal origin of the tumor (5). Recurrences following primary surgery are difficult to treat and a course of several recurrences has to be expected during a long-term follow-up (6, 9). Recurrence of PA following surgery was recorded in 0.5 to 10%, in some reports rising to 48% (4, 9, 11).

The mixed aspect of PA is constituted by two tissue-specific findings: the sub-differentiation of epithelia and modified myoepithelia and the amount and constitution of the stroma. Two subtypes are distinguished on routinely processed slices, i.e. the stroma-rich and the stroma-poor. (2, 7 - 10).

Pleomorphic adenoma can give rise to malignant tumors, in particular carcinoma (1), both in minor (3) and major (12) salivary glands. The risk for malignant transformation of PA was calculated to be 3 - 4% (9).

The aim of this study was to evaluate the therapy for PA of a single surgical institution with particular reference to carcinoma arising from this salivary gland tumor.

### Materials and Methods

This study comprises data from 94 patients with pleomorphic adenoma (7), who were surgically treated at a single clinic between 1972 and 2000 (females: 57, males: 35; mean age 57.6 years, minimum: 19 years, maximum: 83 years) (Figure 1).

### Results

The primary tumors were predominantly located in the parotid gland (n=73), followed in frequency by pleomorphic adenoma arising from the minor salivary glands of the palate (n=15), the submandibular gland (n=3) and the lacrimal gland (n=2), leaving one case with a primary of the lips. Females were more often affected than males. Laterality of tumor growth was conspicuous for parotid gland tumors, the right side being affected in 48 individuals and only 25 patients found with left-sided PA.

*Correspondence to:* Prof. Dr R. E. Friedrich, Maxillofacial Surgery Clinic, Eppendorf University Hospital, University of Hamburg, Martinistr. 52, D-20246 Hamburg, Germany. Tel: ++49-40-42803-3259, Fax: ++49-40-42803-8120, e-mail: rfriedri@uke.uni-hamburg.de

*Key Words:* Pleomorphic adenoma, salivary glands, head and neck tumors, parotid, salivary gland carcinoma, clinical study.

## age distribution at time of diagnosis

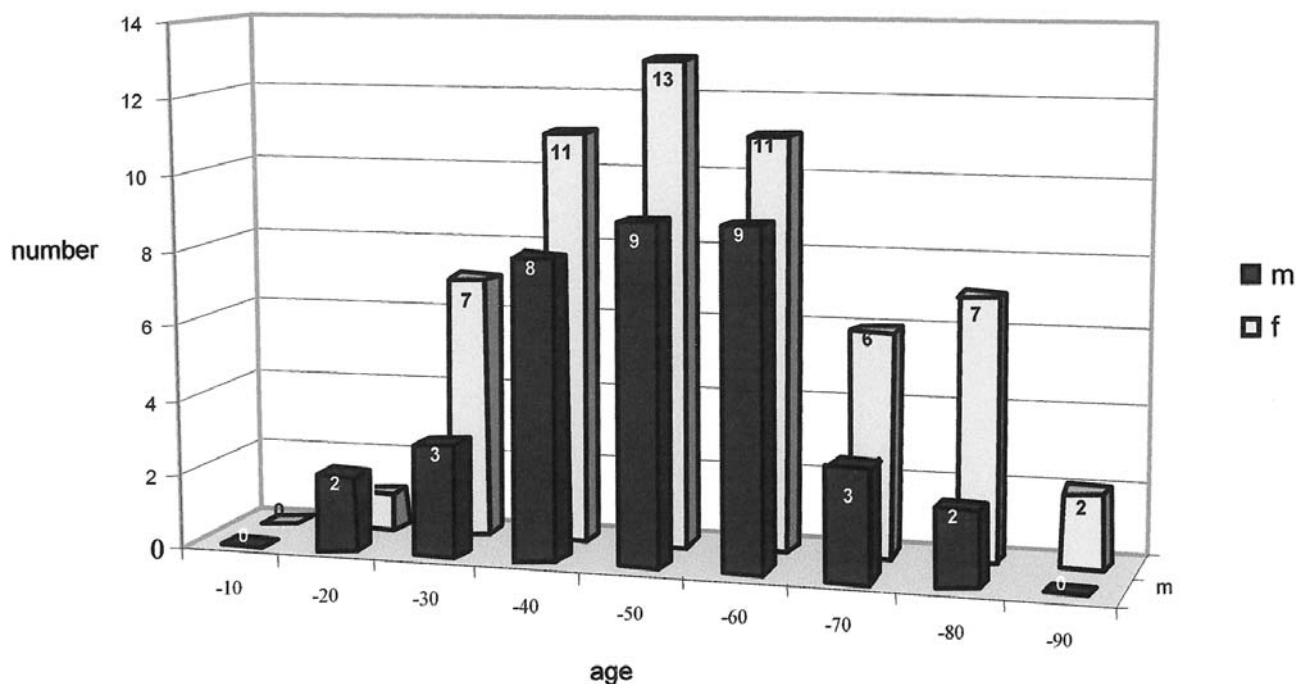


Figure 1. Age distribution of patients with pleomorphic adenoma at the time of diagnosis.

Painless swelling was the first finding in 80%, followed by pressure sensation in 14% and pain in 6% (all sites). Swelling of the parotid region and cheek was the most frequent finding (90%), associated with symptoms like pain in 7% and a feeling of pressure in 3%. Swelling was located pre-auricular in 26, sub-auricular in 19, around the outer mandibular angle in 11 and in the anterior parts of the cheek in 6 patients, extended to the sub- and pre-auricular parts of the parotid in 7, to the temporal region in 1 and was in close approximation to the infra-orbital rim in 2 patients.

**Recurrence.** Recurrent tumor was recorded in 18 patients, predominantly in patients aged 50 to 69 years (12 patients). A second relapse was recorded for 4 and a third relapse for 3 patients.

**Carcinoma and pleomorphic adenoma.** A carcinoma inside a pleomorphic adenoma was diagnosed in 8 patients (8.6%). Primary therapy of these patients was local resection in 8, conservative parotidectomy in 2 and partial resection of the soft palate in 1. Second interventions included further local resections and dissection of efferent lymphatics of the neck in all cases. Reconstruction was done with 4 palatine flaps,

1 pharyngo-palatine-flap, a microvascular radial forearm flap and 1 latissimus dorsi-flap. In 2 patients the facial nerve was adhering to the tumor and was sacrificed. Reanimation of the face was carried out with sural nerve interposition grafts.

No patient was postoperatively irradiated.

### Discussion

This study shows that pleomorphic adenoma can give rise to a carcinoma in more than 8%. In earlier reports from this hospital (9), the risk of carcinoma originating from pleomorphic adenoma was calculated to be 4% and attributed to tumor extension. Giant pleomorphic adenoma, with a long history of tumor growth and weighing some kilograms, were judged to bear a risk of malignancy of about 10% (8). According to our evaluation, tumor size has no apparent effect on malignant transformation of pleomorphic adenoma.

In rare cases, pleomorphic adenoma can develop simultaneously with other salivary gland tumors (6, 8) or can develop at different sites simultaneously (13). Surgical therapy should address the possible multifocal origin of PA and the risk of a transformed phenotype.

## Conclusion

Pleomorphic adenoma is a benign epithelial tumor arising from the salivary glands. Complete tumor excision is mandatory, otherwise there is a considerable risk of local recurrence. In this series, 8.6% of patients had developed a carcinoma arising from a pleomorphic adenoma. This ratio is about twice as high as previously estimated. Surgical treatment planning has to consider the risk of a carcinoma arising in a pleomorphic adenoma.

## References

- 1 Batsakis JG: Recurrent mixed tumors. *Ann Otol Rhinol Laryngol* 95: 543-544, 1986.
- 2 Caselitz J, Schmitt P and Seifert G: Basal membrane associated substances in human salivary glands and salivary gland tumors. *Pathol Res Preat* 183: 386-394, 1988.
- 3 Freeman SR, Sloan P and de Carpentier J: Carcinoma ex pleomorphic adenoma of the nasal septum with adenoid cystic and squamous carcinomatous differentiation. *Rhinology* 41: 118-121, 2003.
- 4 von Glass W, Pesch HJ, Braun R and Krause J: Zur Chirurgie des pleomorphen Adenoms der Ohrspeicheldrüse. *HNO* 37: 426-431, 1989.
- 5 Maran AGD, Mackenzie IJ and Stanley RE: Recurrent pleomorphic adenomas of the parotid gland. *Arch Otolaryngol* 110: 167-171, 1984.
- 6 Pires FR, Alves Fde A, de Almeida OP, Lopes MA and Kowalski LP: Synchronous mucoepidermoid carcinoma of tongue and pleomorphic adenoma of submandibular gland. *Oral Surg Oral Med Oral Pathol* 95: 328-331, 2003.
- 7 Seifert G: *Histological Typing of Salivary Gland Tumours*, 2nd edition, Springer, Berlin-Heidelberg-New York, 1991.
- 8 Seifert G: *Oralpathologie I. Pathologie der Speicheldrüsen. In: Doerr/Seifert/Uehlinger Spezielle Pathologische Anatomie, Vol I/1*, 2nd edition, Springer, Heidelberg, 1996, p.374-417 (pleomorphic adenoma).
- 9 Seifert G and Donath K: Die Morphologie der Speicheldrüsenerkrankungen. *Arch Otorhinolaryngol* 213: 111-208, 1976.
- 10 Seifert G and Sobin LH: The World Health Organization's histological classification of salivary gland tumours: a commentary on the second edition. *Cancer* 70: 1013-1016, 1992.
- 11 Tischendorf L, Luttermann T and Hermann PK: Entartungswahrscheinlichkeit des operativ behandelten pleomorphen Adenoms. *Dtsch Z Mund Kiefer Gesichtschir* 16: 10-12, 1992.
- 12 To EW, Tsang WM and Tse GM: Mucoepidermoid carcinoma ex pleomorphic adenoma of the submandibular gland. *Am J Otolaryngol* 24: 253-257, 2003.
- 13 Zeebregts CJ, Mastboom WJB, van Noort G and van Det RB: Synchronous tumours of the unilateral parotid: rare or undetected? *J Craniomaxillofac Surg* 31: 62-66, 2003.

*Received October 26, 2004  
Accepted January 28, 2005*