

## A Case of Endobronchial NUT Midline Carcinoma with Intraluminal Growth

SHO WATANABE<sup>1</sup>, SATOSHI HIRANO<sup>1</sup>, SOHTARO MINE<sup>2</sup>, AKIHIKO YOSHIDA<sup>3</sup>,  
TORU MOTOI<sup>4</sup>, SATOSHI ISHII<sup>1</sup>, GO NAKA<sup>1</sup>, YUICHIRO TAKEDA<sup>1</sup>,  
TORU IGARI<sup>2</sup>, HARUHITO SUGIYAMA<sup>1</sup> and NOBUYUKI KOBAYASHI<sup>1</sup>

Departments of <sup>1</sup>Respiratory Medicine and <sup>2</sup>Pathology,  
National Center for Global Health and Medicine, Tokyo, Japan;

<sup>3</sup>Department of Pathology, National Cancer Center Hospital, Tokyo, Japan;

<sup>4</sup>Department of Pathology, Tokyo Metropolitan Cancer and  
Infectious Diseases Center Komagome Hospital, Tokyo, Japan

**Abstract.** *Background:* NUT midline carcinoma (NMC) is a rare, lethal form of differentiated squamous cell carcinoma characterized by chromosomal rearrangement of the NUT gene. Its highly aggressive nature commonly leads to unresectable and metastatic lesions. *Case Report:* We report on a case of endobronchial NMC in a middle-aged man who was treated by bronchoscopic electrocautery followed by Ewing sarcoma-based chemotherapy with concurrent chemoradiotherapy. The patient's disease continued to be stable 31 months after diagnosis. *Review:* NMC is a challenging disease entity, which is difficult to diagnose and treat, and has a dismal overall survival. Most cases of NMC are widely metastatic or unresectable when diagnosed. *Discussion:* This is the first reported case that involves intraluminal tumour growth of NMC and demonstrates the effectiveness of early intensive local therapy aided by bronchoscopic techniques.

NUT midline carcinoma (NMC) is an extremely aggressive form of squamous cell carcinoma defined by the presence of acquired chromosomal rearrangements involving the NUT gene, usually resulting in *BRD4-NUT* fusion genes and, less commonly, *NUT*-variant fusion genes involving *BRD3*, *NSD3*, or other uncharacterized genes (1, 2). The NUT gene encodes nuclear protein in testis (NUT), which is normally expressed in the nucleus of germline cells (3). NMC typically arises

from organs located along the central body axis (midline), most commonly the upper aerodigestive tract and mediastinum. An early report of NMC in 1991 described a clinically distinct subtype of poorly differentiated carcinoma associated with a (15;19) (q13;p13.1) translocation in young individuals (4, 5). Although initially recognized as a childhood disease (6), NMCs have also been reported in adults up to 78 years of age (7). NMC is commonly under-diagnosed since it is rare and lacks distinct histological features. There has been a rise in the number of cases of NMC because of increased awareness and the commercially availability of an immunohistochemical test using a monoclonal antibody that detects aberrant NUT expression (8). Novel treatment options, such as bromodomain and extra-terminal domain (BET) inhibitors or histone deacetylase (HDAC) inhibitors, have been developed based on the epigenetic pathogenesis of the BRD4-NUT oncoprotein (9) but, despite this, the prognosis of NMC patients remains extremely poor with a median survival of 6.7 months (7). Herein, we describe a case of endobronchial NMC that was directly visualized and treated by bronchoscopic techniques and chemoradiotherapy.

### Case report

A 51-year-old man with an unremarkable medical history was referred to our Hospital for examination as he presented with haemoptysis, cough and dyspnoea. He had a history of smoking a few cigarettes per day. Chest radiography showed a tumor in the right main bronchus and computed tomography (CT) of the thorax revealed a polyp at the right second carina and mediastinal adenopathy (Figure 1A). Positron emission tomography/CT revealed intense fluorine-18-deoxyglucose accumulation in the tumor and lymph nodes (Figure 1B). Laboratory tests showed elevated levels of alpha-fetoprotein (32 ng/ml).

*Correspondence to:* Sho Watanabe, MD, Department of Respiratory Medicine, Jikei University School of Medicine Third Hospital, 11-1, Izumihoncho 4, Komae City, Tokyo, Japan. Tel: +81 334801151, Fax: +81 334801151, e-mail: sh.watanabe02@gmail.com

*Key Words:* Nuclear protein in testis, NUT midline carcinoma, Ewing sarcoma, endobronchial tumour, electrocautery.

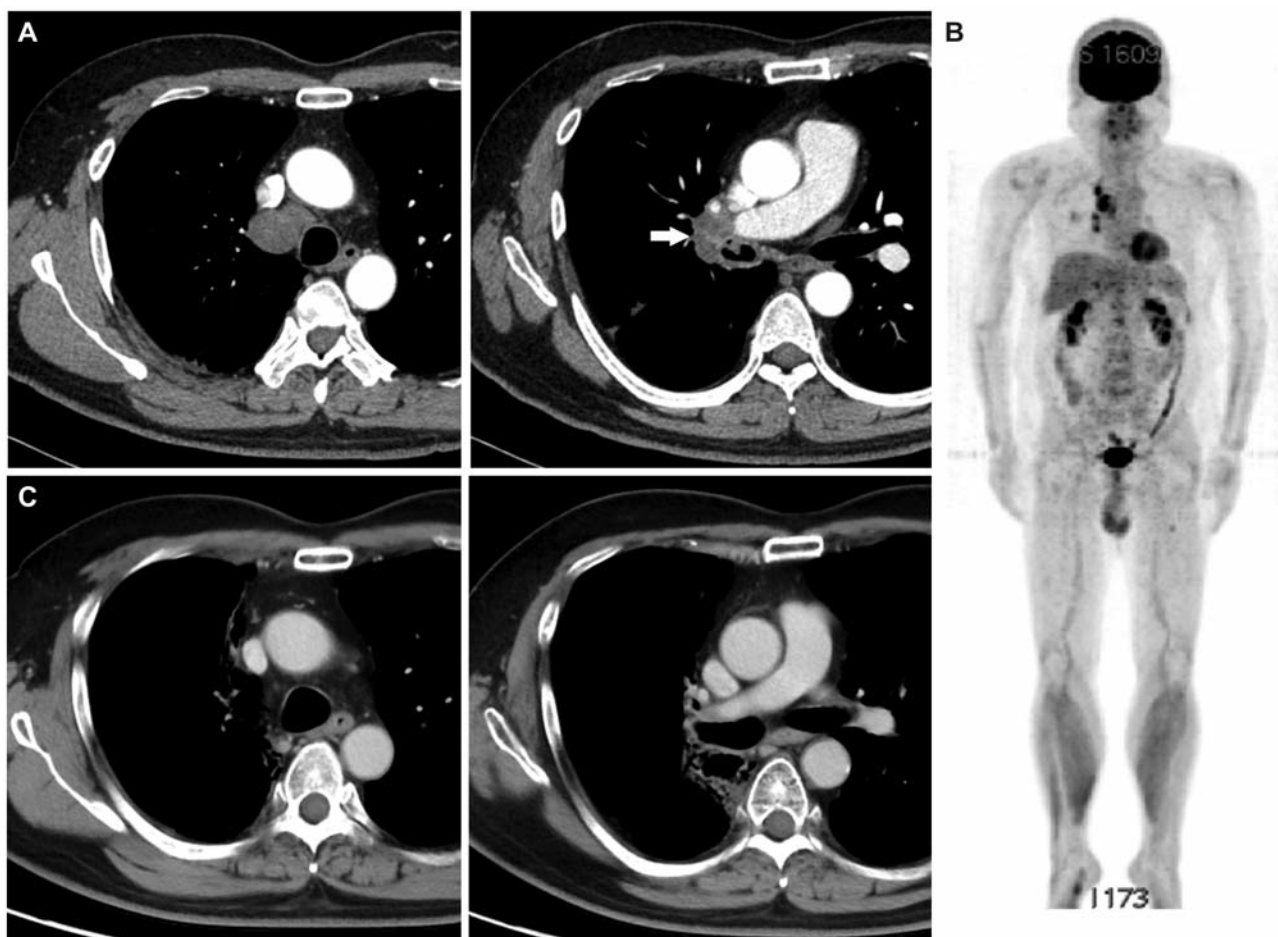


Figure 1. (A) Computed tomography (CT) scan of the thorax at initial presentation showing a tumor at the right second carina (arrow) and mediastinal adenopathy. (B) Positron emission tomography/CT scans showing fluorine-18-deoxyglucose accumulation in the tumour and mediastinal lymph nodes. (C) CT scan of the thorax after chemoradiotherapy showing marked tumor shrinkage.

Fibre-optic bronchoscopy revealed polypoid tumours in the right second carina and right B2 (Figure 2A, 2B). The tumors were removed *via* bronchoscopic electrocautery using a snare device followed by argon plasma coagulation (APC) for haemostasis. Hematoxylin and eosin staining of both the intermediate bronchus and right B2 samples showed a diffuse proliferation of uniform, undifferentiated small cells with enlarged nuclei, coarse chromatin and prominent nucleoli (Figure 3A). Immunohistochemically, the tumor cells were positive for CD99 (MIC2), bcl-2 and cyclin D1 and negative for S100, desmin, MyoD1, smooth muscle actin, melanA, AE1/AE3, CAM5.2, LCA, CD3, CD20, CD30 and TdT. Ewing sarcoma (ES) was suspected; however, dual-colour chromogenic *in situ* hybridization using break-apart probes for *EWSR1* did not indicate gene rearrangement. Therefore, the tumour was tentatively diagnosed as undifferentiated small round cell sarcoma.

The patient received five cycles of ES-based chemotherapy with vincristine, doxorubicin and cyclophosphamide, alternating with ifosfamide and etoposide. Following treatment, the patient exhibited a partial response and no local recurrence (Figure 2C, 2D).

Further specimen analysis three months after the initial diagnosis revealed immunoreactivity for NUT (Figure 3B) and *NUT* rearrangement with dual-colour break-apart fluorescence *in situ* hybridization (FISH) (Figure 3C). On the basis of these new findings, the diagnosis was changed to NMC.

The patient was subsequently administered one chemotherapy cycle consisting of tegafur/gimeracil/oteracil potassium and cisplatin along with concurrent thoracic radiotherapy (60 Gy / 30 fr), inducing further tumour shrinkage (Figure 1C). At the time of reporting, the patient is alive and has been in remission for 31 months after the diagnosis.

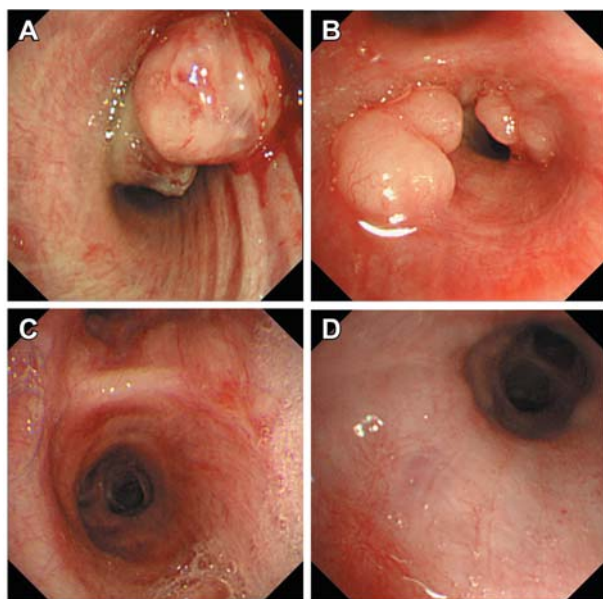


Figure 2. Endobronchial pedunculated tumor with partial necrosis and a narrow base at the right second carina (A) and polypoid tumors at the orifice of right B2 (B). Fibre-optic bronchoscopy after front-line chemotherapy revealing no recurrence at the right second carina (C) or the right B2 (D).

## Discussion

NMC is a challenging disease entity, which is difficult to diagnose and treat, and has a dismal overall survival. Most cases of NMC are widely metastatic or unresectable when diagnosed. To date, one case of NUT-variant carcinoma arising from the trachea in a 16-year-old woman has been reported, although not in detail. She was treated with chemoradiotherapy and was still alive 100 weeks after diagnosis (6). Our case demonstrated a unique intraluminal growth of NMC, which, to the best of our knowledge, was the first to be observed and treated using bronchoscopic techniques.

NMC has been frequently misdiagnosed. Initial diagnoses in cases of NMC include squamous cell carcinoma, poorly differentiated or undifferentiated carcinoma, sinonasal carcinoma, nasopharyngeal carcinoma, thymic carcinoma, leukaemia and lung cancer (1, 10). The polypoid growth and results of the imaging study in this case initially led to an incorrect diagnosis of lung cancer. A recent retrospective study led to the discovery of NUT rearrangements using immunohistochemistry staining and FISH analysis in 2 cases among 747 young patients initially diagnosed with small-cell lung cancer (11). Primary pulmonary ES is also extremely rare but a few cases have been reported (12), which have highlighted the necessity of immunohistochemical and molecular techniques for its accurate diagnosis, especially in young patients with thoracic tumours.

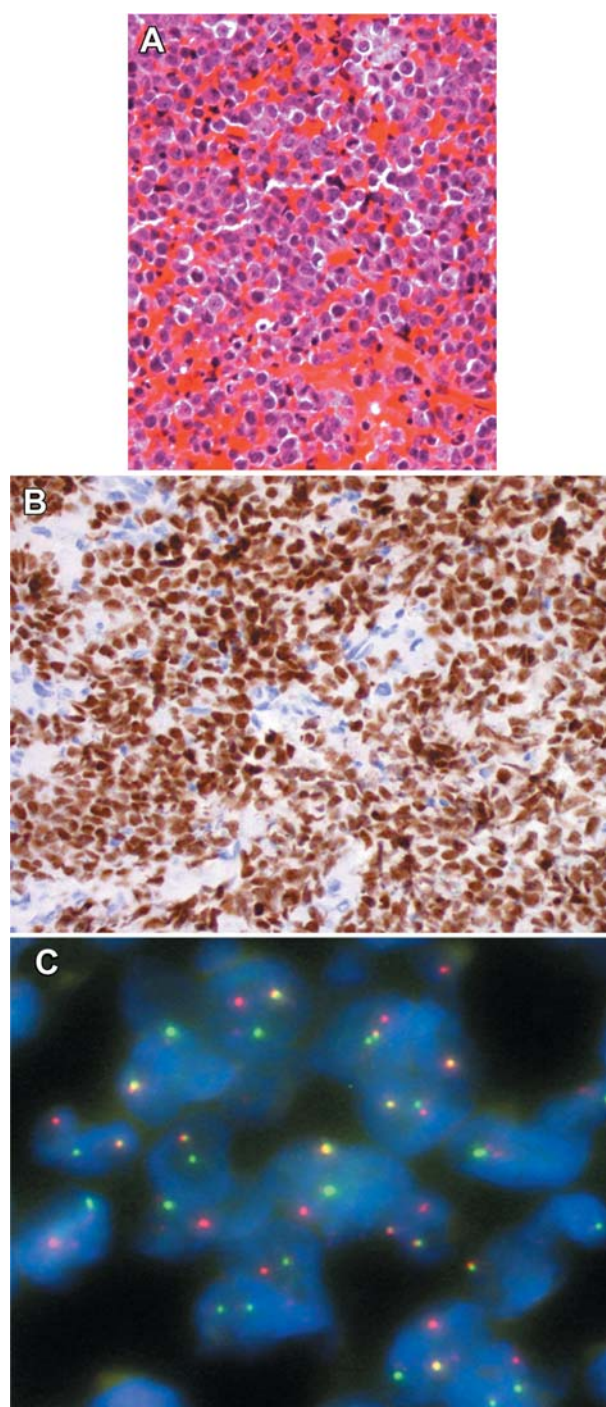


Figure 3. (A) The resected specimen showing diffuse proliferation of undifferentiated small cells against a haemorrhagic background (hematoxylin and eosin staining). (B) Tumor cells showing diffuse, strong nuclear immunoreactivity for nuclear protein in testis (brown). (C) Dual-colour break-apart fluorescence in situ hybridization of tumor cells. The probe specific for the telomeric end of NUT (RP11-1H8) was labelled with Spectrum Orange and the probe specific for the centromeric end of NUT (RP11-412E10) was labelled with Spectrum Green. Most tumor cells harboured split orange and green signals, indicating NUT gene rearrangement.

In contrast to recent promising advances in the delineation of oncogenic processes in NMC, the origin of NMC cells remains obscure. NMCs were initially thought to be derived from primitive neural crest-derived cells because of the frequent involvement of midline structures and the similarity of their genomic profile to that of adult ciliary ganglion (13). Subsequently, the lobectomy specimen of a paediatric case with NMC arising from the hilum of the left lung demonstrated that NMC cells were derived from basal cells of the bronchiolar epithelia indicating a continuum between nests of tumor cells and the bronchiolar epithelium (10). The polypoid growth of the tumor and the imaging results in the case we describe here suggest that a subset of NMC might originate in the lower respiratory tract.

Obstruction of the central airways, trachea and main stem bronchi can result from a variety of diseases and lead to significant morbidity and mortality (14). Although bronchoscopy is an essential tool for assessing airway obstruction, no cases of NMC have been reported with direct visualization or treatment *via* bronchoscopy, possibly due to the rapid growth of these tumours.

Among various bronchoscopic techniques available for tumor debulking in patients with central airway obstruction, electrocautery using a snare device is especially suitable for the removal of pedunculated lesions. Cauterizing the stalk enables the removal of tumour without tissue destruction and provides sufficient material for pathological examination (14). Bronchoscopic electrocautery in combination with other modalities can also be curative in patients with early stage intraluminal squamous cell lung cancer and advanced malignancies (15). Bleeding is a side-effect of electrocautery that reduces its effectiveness due to the diffusion of the current across a larger surface area (14). Argon plasma coagulation (APC) is a non-contact electrocoagulation technique. It allows rapid coagulation with minimal manipulation of, and mechanical trauma to, the target lesion and facilitates effective haemostasis and debulking of endobronchial lesions through a bronchoscope (16). Electrocautery combined with APC was also highly effective and safe for the accurate diagnosis and treatment of NMC in our case.

The optimal treatment for NMC has not been established. The rarity of the disease and its aggressive behaviour has resulted in a median survival of less than 7 months (7) and there is only one case of a patient surviving NMC arising in the iliac bone (17). Patients with NMC have been treated with a variety of systemic therapies, including intensive chemotherapy regimens using anthracyclines, topoisomerase inhibitors, microtubule antagonists, alkylating agents and aromatase inhibitors. However, no specific regimen has shown significant efficacy for NMC (1). The largest cohort of NMC patients studied to date failed to show any improvement in progression-free survival after chemo-

therapy (7). This study suggested that curative surgery and initial radiotherapy were independent and significant predictors of survival.

The failure of most NMC patients to benefit from early multimodality treatment is due to its aggressive behaviour and heterogeneity of response. Every effort to ensure prompt diagnosis of NMC and the adaptation of novel targeted-agents into clinical practice will be necessary to treat this lethal carcinoma effectively. Since the efficacy of classic combined therapy used for NMC patients has been limited, novel, targeted small-molecule agents have been developed that target the epigenetic changes that underlie the pathogenesis of this disease. The chromosomal rearrangement of the *NUT* gene defines NMC and commonly causes fusions to *BET* family genes, *BRD3* and *BRD4*, which regulate gene expression through their ability to bind to acetylated chromatin and subsequently activate transcriptional elongation (18). The BRD-NUT oncoproteins block differentiation and maintain tumour cells in a highly proliferative state through activation of *SOX2* expression (19) and dysregulation of the *MYC* gene (20).

Based on these findings, novel targeted-therapies have been developed to induce differentiation of NMC cells. These include the use of vorinostat, a clinically approved HDAC inhibitor that restores chromatin acetylation and has proven anti-proliferative activity both *in vitro* and *in vivo*. One patient with NMC was treated with vorinostat and exhibited a clinical response (21).

One BET inhibitor, JQ1, competitively inhibits the binding of BRD-NUT complexes to acetylated histones on the *MYC* promoter and prevents the binding of wild-type BET proteins to chromatin (20). This inhibition leads to squamous differentiation and specific anti-proliferative effects in patient-derived xenograft models of NMC (22). Another BET inhibitor, GSK525762 (I-BET762), has entered an ongoing phase I clinical trial in the United States (NCT01587703). However, difficulty in assessing the novel agent after washout periods from initial therapy often resulted in the rapid progression of NMC (23). The significant variability of response to these targeted-agents among different NMC cell lines is also of concern. Neither a BET inhibitor (JQ1) nor a HDAC inhibitor (vorinostat) showed superior efficacy in a subset of NMC cell lines *in vitro* compared to cytotoxic agents, including vincristine, anthracyclines and etoposide (24). To improve the limited efficacy of monotherapy for NMC patients, combination therapy with targeted-agents has been proposed (1, 23). Indeed, a synergistic effect of treatment with a combination of BET and HDAC inhibitors was shown in a study using a MYC-induced lymphoma mouse model (25).

Another potential therapeutic target is cyclin-dependent kinase 9 (CDK9), which is part of the positive transcri-

ptional elongation factor b (P-TEFb) (26). A CDK9 inhibitor, flavopiridol, has been tested in clinical trials for the treatment of leukaemia (27) and had an anti-proliferative effect in a NMC xenograft model (24).

In summary, we describe a case of endobronchial NMC that was directly visualized and treated through fibre-optic bronchoscopy. This case demonstrates the effectiveness and safety of intensive local control using bronchoscopic techniques followed by chemoradiotherapy.

## Acknowledgements

Dr. Watanabe, Dr. Hirano and Dr. Naka were involved in the clinical care of the patient. Dr. Mine and Dr. Igari performed the histopathological review. Dr. Yoshida carried out FISH analysis and reviewed the immunohistochemical staining. Dr. Motoi performed chromogenic *in situ* hybridization analysis. Dr. Ishii and Dr. Takeda assisted in the patient's care. Dr. Sugiyama and Dr. Kobayashi proofread the final manuscript.

## References

- French CA: Pathogenesis of NUT midline carcinoma. *Annu Rev Pathol* 7: 247-265, 2012.
- French CA, Rahman S, Walsh EM, Kuhnle S, Grayson AR, Lemieux ME, Grunfeld N, Rubin BP, Antonescu CR, Zhang S, Venkatramani R, Dal Cin P and Howley PM: NSD3-NUT fusion oncoprotein in NUT midline carcinoma: implications for a novel oncogenic mechanism. *Cancer Discov* 4: 1-14, 2014.
- French CA, Miyoshi I, Kubonishi I, Grier HE, Perez-Atayde AR and Fletcher JA: BRD-NUT fusion oncogene: a novel mechanism in aggressive carcinoma. *Cancer Res* 63: 304-307, 2003.
- Kees UR, Mulcahy MT and Willoughby ML: Intrathoracic carcinoma in an 11-year-old girl showing a translocation t(15;19). *Am J Pediatr Hematol Oncol* 13: 459-464, 1991.
- Kubonishi I, Takehara N, Iwata J, Sonobe H, Ohtsuki Y, Abe T and Miyoshi I: Novel t(15;19)(q15;p13) chromosome abnormality in a thymic carcinoma. *Cancer Res* 51: 3327-3328, 1991.
- French CA, Kutok JL, Faquin WC, Toretsky JA, Antonescu CR, Griffin CA, Nose V, Vargas SO, Moschovi M, Tzortzatou-Stathopoulou F, Miyoshi I, Perez-Atayde AR, Aster JC and Fletcher JA: Midline carcinoma of children and young adults with NUT rearrangement. *J Clin Oncol* 22: 4135-4139, 2004.
- Bauer DE, Mitchell CM, Strait KM, Lathan CS, Stelow EB, Luer SC, Muhammed S, Evans AG, Sholl LM, Rosai J, Giraldo E, Oakley RP, Rodriguez-Galindo C, London WB, Sallan SE, Bradner JE and French CA: Clinicopathologic features and long-term outcomes of NUT midline carcinoma. *Clin Cancer Res* 18: 5773-5779, 2012.
- Haack H, Johnson LA, Fry CJ, Crosby K, Polakiewicz RD, Stelow EB, Hong SM, Schwartz BE, Cameron MJ, Rubin MA, Chang MC, Aster JC and French CA: Diagnosis of NUT midline carcinoma using a NUT-specific monoclonal antibody. *Am J Surg Pathol* 33: 984-991, 2009.
- Mirguet O, Gosmini R, Toun J, Clement CA, Barnathan M, Brusq JM, Mordaunt JE, Grimes RM, Crowe M, Pineau O, Ajakane M, Daugan A, Jeffrey P, Cutler L, Haynes AC, Smithers NN, Chung CW, Bamborough P, Uings IJ, Lewis A, Witherington J, Parr N, Prinjha RK and Nicodème E: Discovery of epigenetic regulator I-BET762: lead optimization to afford a clinical candidate inhibitor of the BET bromodomains. *J Med Chem* 56: 7501-7515, 2013.
- Tanaka M, Kato K, Gomi K, Yoshida M, Niwa T, Aida N, Kigasawa H, Ohama Y and Tanaka Y: NUT midline carcinoma: report of 2 cases suggestive of pulmonary origin. *Am J Surg Pathol* 36: 381-383, 2012.
- Taniyama T, Nokihara H, Tsuta K, Horinouchi H, Kanda S, Fujiwara Y, Yamamoto N, Koizumi F, Yunokawa M and Tamura T: Clinicopathological features in young patients treated for small-cell lung cancer: significance of immunohistological and molecular analyses. *Clin Lung Cancer* 15: 244-247, 2014.
- Antelo JS, Garcia CR, Marinez CM and Hernando HV: Pulmonary Ewing sarcoma/primitive neuroectodermal tumor: A case report and a review of the literature. *Arch Bronconeumol* 46: 44-46, 2010.
- French CA: Demystified molecular pathology of NUT midline carcinomas. *J Clin Pathol* 63: 492-496, 2010.
- Ernst A, Feller-Kopman D, Becker HD and Mehta AC: Central airway obstruction. *Am J Respir Crit Care Med* 169: 1278-1297, 2004.
- van Boxem TJ, Venmans BJ, Schramel FM, van Mourik JC, Golding RP, Postmus PE and Sutedja TG: Radiographically occult lung cancer treated with fiberoptic bronchoscopic electrocautery: a pilot study of a simple and inexpensive technique. *Eur Respir J* 11: 169-172, 1998.
- Morice RC, Ece T, Ece F and Keus L: Endobronchial argon plasma coagulation for treatment of hemoptysis and neoplastic airway obstruction. *Chest* 119: 781-787, 2001.
- Mertens F, Wiebe T, Adlercreutz C, Mandahl N and French CA: Successful treatment of a child with t(15;19)-positive tumor. *Pediatr Blood Cancer* 49: 1015-1017, 2007.
- French CA, Ramirez CL, Kolmakova J, Hickman TT, Cameron MJ, Thyne ME, Kutok JL, Toretsky JA, Tadavarthy AK, Kees UR, Fletcher JA and Aster JC: BRD-NUT oncoproteins: a family of closely related nuclear proteins that block epithelial differentiation and maintain the growth of carcinoma cells. *Oncogene* 27: 2237-2242, 2008.
- Wang R, Liu W, Helfer CM, Bradner JE, Hornick JL, Janicki SM, French CA and You J: Activation of SOX2 expression by BRD4-NUT oncogenic fusion drives neoplastic transformation in NUT midline carcinoma. *Cancer Res* 74: 3332-3343, 2014.
- Grayson AR, Walsh EM, Cameron MJ, Godec J, Ashworth T, Ambrose T, Aserlind AB, Wang H, Evan GI, Kluk MJ, Bradner JE, Aster JC and French CA: MYC, a downstream target of BRD-NUT, is necessary and sufficient for the blockade of differentiation in NUT midline carcinoma. *Oncogene* 33: 1736-1742, 2014.
- Schwartz BE, Hofer MD, Lemieux ME, Bauer DE, Cameron MJ, West NH, Agoston ES, Reynoird N, Khochbin S, Ince TA, Christie A, Janeway KA, Vargas SO, Perez-Atayde AR, Aster JC, Sallan SE, Kung AL, Bradner JE and French CA: Differentiation of NUT midline carcinoma by epigenomic reprogramming. *Cancer Res* 71: 2686-2696, 2011.
- Filippakopoulos P, Qi J, Picard S, Shen Y, Smith WB, Federov O, Morse EM, Keates T, Hickman TT, Felletar I, Philpott M,

- Munro S, McKeown MR, Wang Y, Christie AL, West N, Cameron MJ, Schwartz B, Heightman TD, La Thangue N, French CA, Wiest O, Kung AL, Knapp S and Bradner JE: Selective inhibition of BET bromodomains. *Nature* 468: 1067-1073, 2010.
- 23 Sameer AP, French CA, Costello BA, Marks RS, Dronca RS, Nerby CL, Roden AC, Peddareddigari VG, Hilton J, Shapiro GI and Molina JR: NUT midline carcinoma an aggressive intrathoracic neoplasm. *J Thorac Oncol* 8: 1335-1338, 2013.
- 24 Beesley AH, Stirnweiss A, Ferrari E, Endersby R, Howlett M, Failes TW, Arndt GM, Charles AK, Cole CH and Kees UR: Comparative drug screening in NUT midline carcinoma. *Br J Cancer* 110: 1189-1198, 2014.
- 25 Bhadury J, Nilsson LM, Muralidharan SV, Green LC, Li Z, Gesner EM, Hansen HC, Keller UB, McLure KG and Nilsson JA: BET and HDAC inhibitors induce similar genes and biological effects and synergize to kill in Myc-induced murine lymphoma. *Proc Natl Acad Sci USA* 111: e2721-2730, 2014.
- 26 Garcia-Cuellar MP, Füller E, Mäthner E, Breitingner C, Hetzner K, Zeitlmann L, Borkhardt A and Slany RK: Efficacy of cyclin-dependent-kinase 9 inhibitors in a murine model of mixed-lineage leukemia. *Leukemia* 28: 1427-1435, 2014.
- 27 Karp JE, Garrett-Mayer E, Estey EH, Rudek MA, Smith BD, Greer JM, Drye DM, Mackey K, Dorcy KS, Gore SD, Levis MJ, McDevitt MA, Carraway HE, Pratz KW, Gladstone DE, Showel MM, Othus M, Doyle LA, Wright JJ and Pagel JM: Randomized phase II study of two schedules of flavopiridol given as timed sequential therapy with cytosine arabinoside and mitoxantrone for adults with newly diagnosed, poor-risk acute myelogenous leukemia. *Haematologica* 97: 1736-1742, 2012.

*Received November 3, 2014*

*Revised November 10, 2014*

*Accepted November 14, 2014*