

Review

Current Approaches to Managing Partial Breast Defects: The Role of Conservative Breast Surgery Reconstruction

ALEXANDRE MENDONÇA MUNHOZ¹, EDUARDO MONTAG²,
JOSÉ ROBERTO FILASSI³ and ROLF GEMPERLI²

¹Plastic Surgery Division, Hospital Sírio-Libanês, São Paulo, Brazil;

²Plastic Surgery, University of São Paulo School of Medicine, São Paulo, Brazil;

³Breast Surgery – Cancer Institute of São Paulo, São Paulo, Brazil

Abstract. Recently breast surgeons can offer patients a variety of treatment and reconstructive alternatives when early breast cancer is diagnosed. In fact, advances in reconstructive techniques have reduced surgical trauma and thus are capable of preserving the breast form as well as quality of life. Depending on a variety of different factors, including stage, tumor size, location, histological type, but also breast volume, a reconstructive schedule is established. The main techniques are related to volume displacement or replacement procedures including local flaps, latissimus dorsi myocutaneous flap and reduction mammoplasty/ masthoplexy. Regardless of the fact that there is no consensus over the best approach, the criteria are determined by the surgeon's experience and the size of the defect in relation to the size of the remaining breast. Aim of every reconstructive procedure decision should be breast preservation and an adequate aesthetic outcome. Additionally, reconstruction permits wider excision of the tumor, with a superior mean volume of the specimen and potentially reducing the incidence of margin involvement. The objective of this review is to give an overview of reconstructive modalities for conservative breast surgery, based not only on traditional but also on the latest studies regarding the outcome of the main techniques employed. Surgical approaches, as well as conservative treatment options, such as lumpectomy and quadrantectomy, are further discussed. Surgical planning should include the

patients' preferences, while chiefly addressing individual reconstructive requirements, and enabling each patient to receive an individual "custom-made" reconstruction.

The treatment concepts of early breast cancer have greatly changed throughout recent years (1, 2). In fact, surgical decisions depend on the stage of disease, tumor size and preferred local treatment approaches. Depending on breast volume and ptosis, consideration of partial breast preservation are usually treated with breast-conservation surgery (BCS) (3, 4). In fact, BCS maintains the overall breast shape, with functional and psycho-social advantages (4, 5).

Several clinical studies have compared the efficacy of mastectomy to BCS followed by radiotherapy and observed that disease-free and overall survival are equivalent (1, 2). Additionally, total breast reconstruction, mostly necessary in patients after mastectomy, involve extensive procedures with increased surgical time, morbidity and costs. Thus, BCS can be advantageous for certain groups of patients and has become the treatment approach for early breast cancer preferred by both surgeons and patients.

Normally, BCS procedures include quadrantectomy and lumpectomy. In quadrantectomy, a wide excision is usually performed, including skin and underlying muscle fascia. In lumpectomy, the objective is tumor excision without skin resection and with negative surgical margins (3).

Despite of the acceptance that most BCS defects can be managed with primary closure, the aesthetic outcome may be unpredictable and frequently an unsatisfactory outcome is achieved (3-11). Initial attempts at BCS concentrated on removing the tumor with an adequate margin and little attention was paid to the long-term aesthetic results. This resulted in prominent unaesthetic scars and significant volume defects and severe asymmetry. In fact, approximately 10% to 30% of patients submitted to BCS are not satisfied

Correspondence to: Alexandre Mendonça Munhoz, MD, Division of Plastic Surgery – Hospital Sírio-Libanês Rua Mato Grosso, 306 cj.1706 Higienópolis ZIP: 01239-040, Sao Paulo, SP – Brazil. Tel/Fax: +55 1132551760, e-mail: alexandremunhoz@hotmail.com

Key Words: Breast reconstruction, conservative breast surgery, partial mastectomy, oncoplastic, reduction mammoplasty, local flaps, outcome, complications.

with their aesthetic outcome (12). The main reasons are related to tumor resection which can produce retraction and volume changes in the glandular tissue. In addition, radiation can also have a negative effect on the native breast. The main clinical aspects are related to skin pigmentation changes, telangiectasia, and skin fibrosis. In the glandular tissue, local radiation causes fibrosis and retraction (8, 11). Treatment strategies today are focused on surgical procedures that aim at not only preserving the breast, but more importantly, at the aesthetic outcome.

Reconstructive approaches have changed as the focus on quality of life has increased. Before making a BCS reconstructive decision, a clear analysis for the breast defect and surgical margins as well as the clinical condition of each patient needs to be made and the aim should be a highly individualized treatment for each patient. Thus, by means of customized reconstructive techniques the surgeon ensures that oncological principles are not jeopardized while meeting the needs of the patient from the aesthetic point of view (3, 4, 8).

In general, BCS reconstructive techniques are related to volume displacement or replacement procedures and sometimes include contra-lateral breast surgery. Among the procedures available, local flaps, distant flaps and reduction mammoplasty/mastopexy techniques are the ones most commonly employed (11, 13, 14). Regardless of the fact that there is no consensus over the best approach, the criteria are determined by the surgeon's experience and the size of the defect in relation to the size of the remaining breast (8, 11-14). The main advantages of the technique utilized should include reproducibility, low interference with the oncological treatment and long-term results. Probably, all these goals are not achieved by any single procedure and each technique has advantages and limitations (14). In the present review, the possible reconstructive modalities for BCS are described and discussed.

Literature Search/Data Acquisition

Two independent reviewers have evaluated titles and abstracts without language restrictions to assess eligibility in terms of study design. A literature search was carried-out up to October 2013 to identify studies of breast cancer patients submitted to NSM and determine if any technique of immediate reconstruction was recorded. In an attempt to minimize the omission of potentially relevant clinical studies, we also reviewed the reference lists of included studies and relevant reviews for additional eligible articles. Potential studies were identified by searches in MEDLINE and PubMed databases using the terms "Partial Mastectomy Reconstruction", "Conservative Breast Surgery Reconstruction", "Conservation Breast Surgery Reconstruction" and "Oncoplastic Surgery". Studies identified were screened for those that focused on techniques, surgical and oncological outcomes after BCS

reconstruction and references of each study were further investigated to include all relevant published data. All types of reconstruction techniques were included.

A total of 1,386 potential articles were identified during the primary evaluation. After evaluation of the inclusion criteria, 317 articles were identified for potential inclusion and reviewed in detail. A total of 245 articles were excluded, leaving 72 articles to form the basis of this review.

Indications of Breast Conservative Surgery and Reconstruction

The indication criteria for BCS is relative and based on several factors. The size of the tumor relative to the breast volume and presence of ptosis is the deciding factor in determining the appropriateness of BCS (3, 8, 11, 14). It may even be adequate for patients with large breasts in whom the tumor is up to 3-4 cm or even when large breast tumors have been down-staged by neoadjuvant chemotherapy. The use of reconstructive techniques not only ensures a satisfactory outcome, but also allows the breast surgeon to resect the tumor with greater volume of surrounding tissue, thus extending the boundaries of BCS. However, the absolute contraindications to BCS are related to multifocal disease, with chest-wall involvement, significant skin involvement, and patients with either extensive malignant microcalcifications or inflammatory carcinoma.

Conservative breast surgery defects classification. Several classification schemes have been developed to define breast deformity and proposed reconstructive techniques (3, 7, 8, 12, 14, 15-18). Primary closure, breast re-shaping, local and distant flaps were previously described, yet some of these techniques address late repair and are based on tissue deficiency and the presence of radiotherapy effects. Additionally, most clinical studies include them within a broader category of complex breast defects and until now, there are few clinical series that describe a systematic approach or propose an algorithm for reconstruction on an immediate basis.

In delayed reconstructions, Clough *et al.* classified the breast defects and oncoplastic procedures according to the response to reconstruction (9). Berrino *et al.* emphasized the importance of analyzing the etiology of the breast defect (15). Recently, Hamdi *et al.* proposed a classification based on the size and location of the expected tumor resection and the ratio of breast volume to resection volume (3). Tumors involving the lower pole are the ones most treated because this region is removed during most reduction mammoplasty. Other regions of tumor resection, can also be repaired using a combination of mammoplasty and glandular flaps to fill the breast defect. According to Hamdi's classification one of the relative contraindications for re-arrangement breast surgery (glandular flaps and reduction mammoplasty) is a large

tumor/breast ratio. Thus, smaller breasts require different methods of reconstruction and a large-volume tumor resection, the recruitment of local flaps is required. If these flaps become unavailable, the lateral breast defects can be repaired using a flap based on the thoracodorsal system.

In immediate reconstruction, Munhoz *et al.* identified trends in types of breast defects and to develop an algorithm for immediate BCS reconstruction according to the initial breast volume, the extent/location of glandular tissue resection and the remaining available breast tissue (14). To render possible a development of a BCS reconstructive algorithm, BCS defects were classified into one of three types;

Type I: Defects include tissue resection in smaller breasts without ptosis. Type IA defects involve minimal defects that do not cause volume alteration/distortion in the breast shape and the tissue resected is less than 10-15% of the total breast volume. Initial tumor exposure is achieved through a periareolar approach in cases where the tumor is located deeply. In patients where the tumor is located close to the skin, a separate incision is planned directly over the region to be resected. Type IB defects involve moderate defects that do originate moderate volume alteration/distortion in the breast shape or symmetry and the tissue resected is between 15 and 40% of the total volume. Usually, the skin above the tumor is resected with the tumor. Type IC defects involve large defects that do cause significant volume alteration/distortion in the breast shape and symmetry and the tissue resected is more than 40% of the total breast volume.

Type II: This group includes tissue resections in medium sized breasts with/without ptosis. Type IIA involve small defects that do not cause enough volume alteration/distortion in the breast shape. Type IIB defects involve moderate defects that cause minor/moderate volume alteration in the breast shape. Type IIC defects involve large defects that cause moderate/large volume variations in the breast shape and symmetry.

Type III: This group includes tissue resection in large-sized breasts with ptosis. Type IIIA involve small defects that do not cause enough aesthetic deformity. Type IIIB defects involve moderate defects that originate minor/moderate volume alterations in the breast shape or symmetry. Type IIIC defects involve large defects that cause significant volume alteration in the breast.

Conservative breast surgery techniques. BCS defects represent a variety that ranges from small defects that may repair with primary closure and to large defects that involve skin, NAC and a significant amount of glandular tissue. Currently, there are different groups of techniques in BCS reconstruction according to the volume of the excised breast tissue. One of which is the volume-displacement procedures that combine the resection with a variety of different breast-reshaping and breast-reduction techniques, and the other is

volume-replacement techniques that replace the volume of the excised breast tissue by using local and distant flaps (13, 19). Volume displacement procedures have positive aspects over volume replacement techniques. The operative time is shorter, it is less extensive, and there is no donor-site area and morbidity. However, in patients with small breast size or a higher tumor-to-breast volume ratio, there is a limitation on indication and aesthetic outcome. The volume replacement techniques retain the volume and shape of the breast and avoid contralateral breast surgery. However, these procedures can be more complex and require a donor site and increased recovery time following autologous tissue harvesting.

Thus, surgical planning should include the breast volume, tumor location, the extent of glandular tissue resected, and chiefly addressing individual reconstructive requirements, enabling each patient to receive an individual “custom-made” reconstruction. There are many variables in determining the best approach for the oncoplastic surgery in breast cancer patients (11). In addition, some classifications have been described to evaluate the extent of resection and indicate the appropriate surgical technique, which has consequently created a wide range of surgical options with different indications (3, 7, 8, 12, 14, 15-18).

Munhoz *et al.* observed that the majority of reconstruction techniques were performed with one of the six surgical options: breast tissue advancement flaps (BAF), lateral thoracodorsal flap (LTDF), bilateral mastopexy (BM), bilateral reduction mammoplasty (BRM), latissimus dorsi myocutaneous flap (LDMF) and abdominal flaps (14). Concerning the use of distant flaps (pedicled and free) in BCS reconstruction, there is no consensus regarding the indication and the more appropriate technique. In terms of benefits and morbidity, the abdominal wall area as donor site has some positive aspects. In fact, the abdominal area provides the ideal volume for a partial and total breast reconstruction, even in large-breasts patients (20). Thus, it is possible to utilize the mono-pedicled or bi-pedicled TRAM flap in BCS reconstruction. The establishment of microsurgery techniques led to the development of the free TRAM flap because of its increased vascularity and decreased rectus abdominis resection (3). Recently, the muscle-sparing free TRAM, DIEP, and SIEA flap techniques were followed in an effort to reduce donor site morbidity by decreasing damage to the rectus abdominis muscle and fascia. However, a significant number of patients with positive postoperative tumor margins after immediate BCS reconstruction underwent a completion mastectomy with immediate abdominal flap breast reconstruction. Similarly as pointed out by other authors (3, 8), this observation demonstrates the importance of not using the abdominal area (TRAM, DIEP or SIEA flaps) for immediate BCS reconstruction and the preservation of reconstructive options.

Surgical planning should include breast characteristics and the extent of breast tissue resected. The decision is determined by the surgeon's preferences and the size of the defect in relation to the size of the remaining breast. Thus, it is important to identify trends in types of breast defects on the basis of the initial breast volume, the extent/location of glandular tissue resection and the remaining available breast tissue. Based on the classification proposed by Munhoz *et al.*, the greater part of the BCS defects can be repaired with one of the following surgical options (14).

Types IA, IIA and IIIA: Defects are usually repaired with BAF in which the defect is usually spherical or rectangular. The breast tissue is advanced along the chest wall or beneath the breast skin flap to fill the tumor defect. In order to achieve a better aesthetic outcome without significant skin retraction, superficial undermining between the breast tissue and the skin flap can be performed, preserving the skin blood supply. In the situation of simultaneous superficial and deeper undermining of the breast tissue, the blood supply of the BAF can be decreased, especially in obese patients with fatty breasts. Thus, care must be taken in this group of patients in order to avoid late fat necrosis. Usually, in these patients no contralateral breast procedure is performed (Figure 1). Yang *et al.* advocated that in selected cases it is possible to minimize the depression around the defects and subsequently perform a simple primary closure (19). When additional defects are less than moderate and the remaining breast tissue is sufficient, broad dissection of the breast parenchyma around the defects from the skin and chest wall can be performed, and the defects are subsequently filled using a full-thickness segment of fibroglandular breast tissue advancement, rotation and transposition.

Type IB: In patients with lateral defects the LTDF is performed. Previously described elsewhere (21, 22), this local flap is planned as a wedge-shaped triangle placed on the lateral aspect of the thorax and then rotated to the lateral glandular and skin defect. Introduced as a fasciocutaneous flap, the LTDF is a well-described technique for delayed breast reconstruction following radical surgery (21). In CBS, Clough *et al.* (9) utilized the subaxillary area as a transposition flap with satisfactory results in lateral breast defects. According to the authors, if the defect is located in the superior pole of the breast, a superiorly-based flap can be applied with the same principles. Similarly, Kroll *et al.* (18) transferred the subaxillary skin and subcutaneous fat as a composite and rotation flap to reconstruct a lateral breast defect. Although additional scars are created, they will be placed in the lateral region and therefore will not interfere with the wearing of clothing. In fact, raising the LTDF provides a very wide access to the axilla which greatly facilitate lymph node dissection which was performed without

excessive traction or injury to the structures in the axilla. When indicated, the glandular tissue is dissected of the pectoral muscle in order to improve and re-shaping of the breast. The defect margins are sutured to the margins of the flap and the donor site is closed primarily in layers (Figure 2) (14, 21, 23). Some authors pointed-out that LTDF provides skin and subcutaneous tissue that match to the native skin breast with minimal donor site morbidity, and no sacrifice of muscle (23, 24). However, in patients who have previous surgery to the lateral chest wall, the posterolateral thoracotomy is contraindicated.

In patients with central and medial tumors, the LDMF can be utilized (8, 11, 14, 25, 26). The flap is designed into a horizontal position and the width of the paddle is measured according to the skin previously resected. The inferior and superior flap extension is subjectively estimated to match the volume of glandular tissue. Local flaps and specially the LTDF are useful techniques for upper-outer or lower-outer defects. Using tissue next to defect will provide matching color and texture to the breast. The technique provides wide access to the axilla when the flap incision is made in continuity with that of axillary incision.

The LDMF is used to replace the skin and glandular tissue resected during oncological surgery (17). It is frequently indicated for severe defects, where there is not enough breast tissue to perform reconstruction. In addition, the most common use for BCS reconstruction has been in patients who underwent extensive breast tissue resection because of large tumors or compromised breast margins (25). These included patients with small or medium-volume breasts without ptosis that precludes the use of mammoplasty techniques. Comparing the LTDF with LDMF, local flaps are easy to perform, less time-consuming, no special positioning, and no loss of muscle function (14). Additionally, LTDF when used as an alternative to LDMF will spare the muscle as a potential reserve for future use in case of local recurrence. Negative aspects of the LDMF are related to weakness in the back, shoulder or arm; donor-site morbidity, and a large scar on the back. In fact, Munhoz *et al.* in a series of 48 patients submitted to immediate BCS reconstruction with LDMF observed that flap complications occurred in seven and donor-site complications occurred in 25% of the patients (25). In their study, dorsal seroma (20.8 percent), dorsal dehiscence (6.2 percent), and partial flap loss (6.2 percent) were the most common complications and partial flap losses were limited and were treated by a conservative approach. A significant association ($p=0.035$) was detected between dorsal seroma and obesity (body-mass index 30 kg/m) and was associated with a 5.2-fold increase in the odds of developing this complication.

Type IC: Defects are converted to a skin-sparing mastectomy (SSM) and reconstructed with an appropriate technique. In patients with enough abdominal tissue, an

Table I. *Oncological and outcome of breast conservation surgery reconstruction using reduction mammaplasty techniques.*

Author (ref)	Year	Reduction mammaplasty technique	n	Tumor size	Follow-up (months)	Local recurrence (%)	Patient satisfaction (%)
Papp <i>et al.</i> (20)	1998	Superior pedicle	10	NR	52	5	95
Spear <i>et al.</i> (30)	2003	Superior pedicle	56	NR	46	6.9	91
Clough <i>et al.</i> (48)	2003	Superior pedicle	101	3.2	24	0	88
Goffman <i>et al.</i> (68)	2005	Superior pedicle	57	NR	18	13	82
Munhoz <i>et al.</i> (27)	2006	Superior Pedicle	74	2-4.0	22	0	93
Munhoz <i>et al.</i> (28)	2006	Superior-Medial Pedicle	39	2-4.0	20	0	90
Munhoz <i>et al.</i> (29)	2007	Inferior pedicle	26	2-4.0	21	0	89
Fitoussi <i>et al.</i> (16)	2010	Superior pedicle	540	2.9	49	6.8	90

NR:Not described.

abdominal flap (pedicled/free TRAM or DIEP) can be an option according to the surgeon's preference. In patients without an adequate abdomen, a LDMF associated with an implant can be performed (3,14).

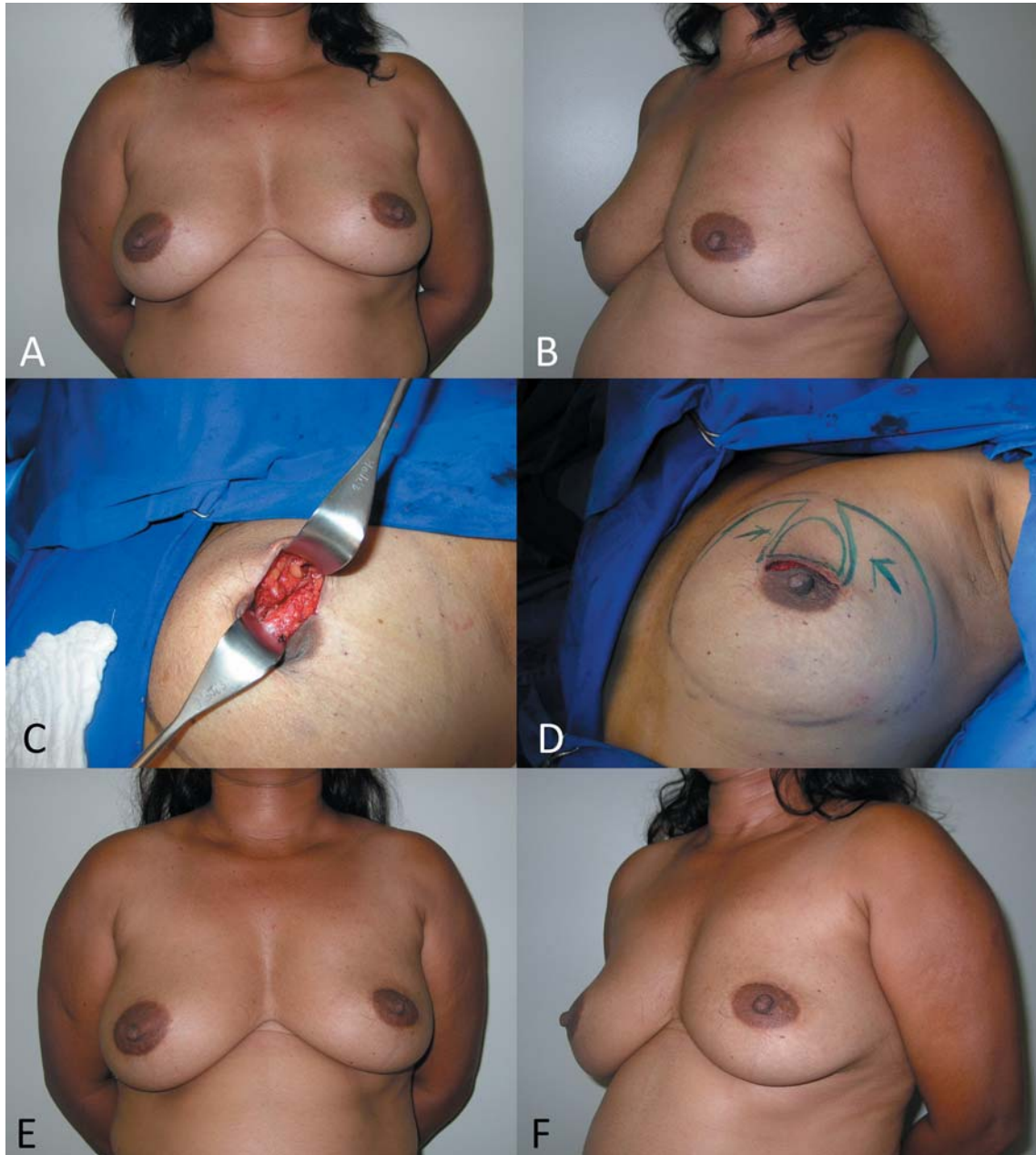
Type IIB: Defects are frequently reconstructed with BM techniques when there is sufficient breast tissue to perform the reconstruction. BM for BCS reconstruction have aesthetic, functional and oncological advantages (27-30). The preoperative appearance can be improved, having smaller and more proportional breasts. Patients can obtain potentially less back and shoulder pain and the bilateral procedure allows us to examine the contralateral breast tissue for occult breast lesions (27-29). In terms of local control and adjuvant therapy, the added removal of a substantial volume of breast tissue could add a significant amount of safety in terms of surgical margins (31-33). In addition, the technique reduces the difficulty of providing radiation therapy to the remaining breast tissues with acceptably low complication rates (34-36) (Table I).

In previous reports (27-29, 33), there is no consensus regarding the best BM technique for immediate BCS reconstruction. Possibly an ideal procedure does not exist and each case should be planned individually. The main advantages of the BM technique utilized should include reproducibility, safety and long-term results. As any surgical technique, all these goals are probably not met by any single procedure and this is supported by the large number of RM techniques available (27-33). Each technique presents particular advantages for their indications, tumor location limitations, vascular pedicle, additional skin and glandular resections due to compromised margins, and resultant scar. Because of rich breast tissue vascularization, the majority of techniques have based their planning on preserving the pedicle of the NAC after tumor removal. For tumors located in the lower region, the tumor resection can be incorporated into the sector of breast tissue removed as part of a superior

pedicle mammaplasty (27, 28). For upper-region tumors, the lower breast tissue may be moved into the defect as a glandular flap and an inferior pedicle mammaplasty can be utilized (27, 29). For inner- and outer-region tumors, the reduction pattern can be rotated and a superior-lateral or a superior-medial pedicle mammaplasty can be performed (27) (Figure 3). Following the NAC pedicle option, a Wise or vertical pattern incisions can be selected. In the case of small – moderate volume breasts, a vertical pattern can be an alternative based on breast size, degree of ptosis, and size of the tumor to be excised. For larger breasts, the Wise pattern can be the first option for BCS reconstruction (19, 27, 33).

The opposite breast surgery is usually performed to match the appropriate symmetry, particularly in breasts with severe ptosis. Under a well-trained surgical team, the procedure can be conducted on both sides at the same time, consequently reducing the operative time. When performing symmetrization, the surgeon can use this opportunity to resect any suspicious breast lesion that may have been revealed by preoperative exams (31, 33).

Type IIC: Defects are analyzed individually according to the size of the breast defect in relation to the remaining breast tissue available. For this purpose, the patient is positioned upright to assess the amount of the remaining glandular tissue. Thus, the type IIC can be subclassified into favorable and unfavorable defects. If there is enough tissue to perform an adequate breast mound shaping the defect is classified as favorable. For lateral defects, the extended LTDF is most commonly employed where the inferior and superior limits are designed more obliquely with curved borders to incorporate a large amount of subcutaneous tissue from the lateral and posterior region of the thorax. In patients with central and medial defects, the extended LDMF can be utilized (25). Conversely, if not enough breast tissue remains, the breast defect is classified as unfavorable and a SSM and total reconstruction is indicated.



Figures 1. A 51-years-old patient with invasive ductal carcinoma (2.9 cm) of the left breast (A-B, above left and right). The patient underwent a left superior lumpectomy and sentinel lymph node biopsy, immediately followed by a breast advancement glandular flaps (BAF) reconstruction; a total of 75 g was removed from the left breast (C-D, center left and right). One year postoperative appearance after the radiotherapy (E-F, below left and right).

Type IIIB: Defects are frequently reconstructed with BRM techniques when the patient presents large volume breasts and there is a sufficient amount of breast tissue. The most favorable tumor location is in the lower breast pole where a conventional superior pedicle or superior-medial technique can be utilized (27, 28). In patients with central tumors, an inferior pedicle is used to carry parenchyma and skin into the central defect (29).

Type IIIC: Breast defects are analyzed individually. When the defect is favorable the deficiency is most frequently reconstructed with BRM (Figure 4). A marked re-shaping of the breast with available tissue and a similar contralateral breast reduction is then performed. In patients in which the relation is not favorable a skin-sparing mastectomy and total breast reconstruction with an appropriate technique can be indicated.

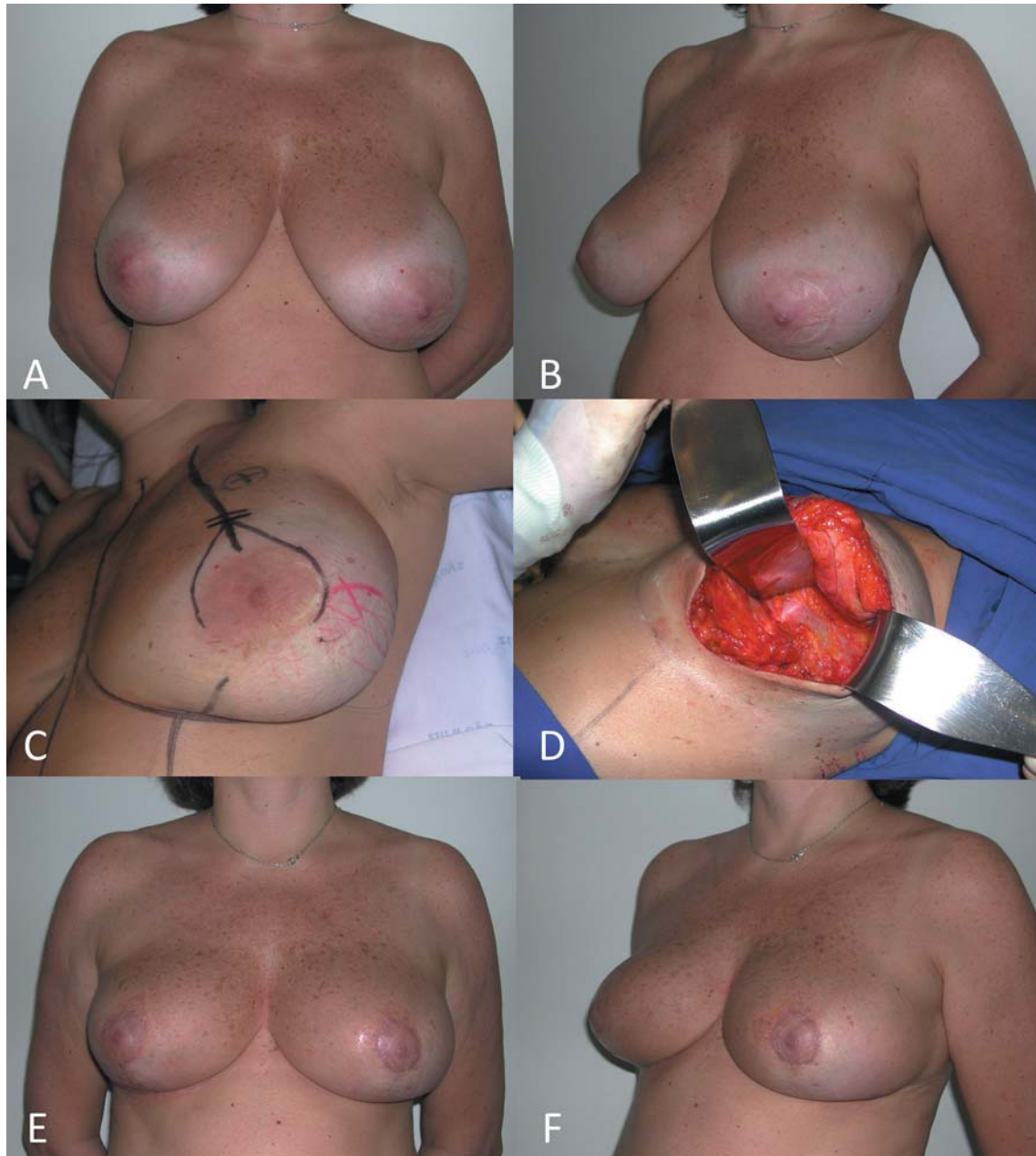


Figure 2. A 47-year-old patient with invasive ductal carcinoma (2.6 cm) of the right breast (A-B, above left and right). The patient underwent a right lateral lumpectomy and sentinel lymph node biopsy, immediately followed by a lateral thoracodorsal flap (LTDF) reconstruction; a total of 95 g were removed from the right breast (C-D, center left and right). One year postoperative appearance after the radiotherapy (E-F, below left and right).

Timing of conservative breast surgery reconstruction. With an immediate oncoplastic approach, the surgical process is smooth since oncological and reconstructive surgery can be associated in one operative setting. Additionally, because there is no fibrosis tissue, breast re-shaping is easier, and the aesthetic outcome is improved (3, 8, 11-14). In fact, Kronowitz *et al.* (11) observed that immediate repair is preferable to delayed

because of a decreased incidence of complications. Similarly, Papp *et al.* (20) observed that the aesthetic results showed a higher success rate in the immediate group when compared with delayed reconstruction patients. Munhoz *et al.* in a series of mammoplasty techniques for BCS reconstruction observed that post-radiation complication rate (delayed BCS reconstruction) was higher than that expected for mammoplasty

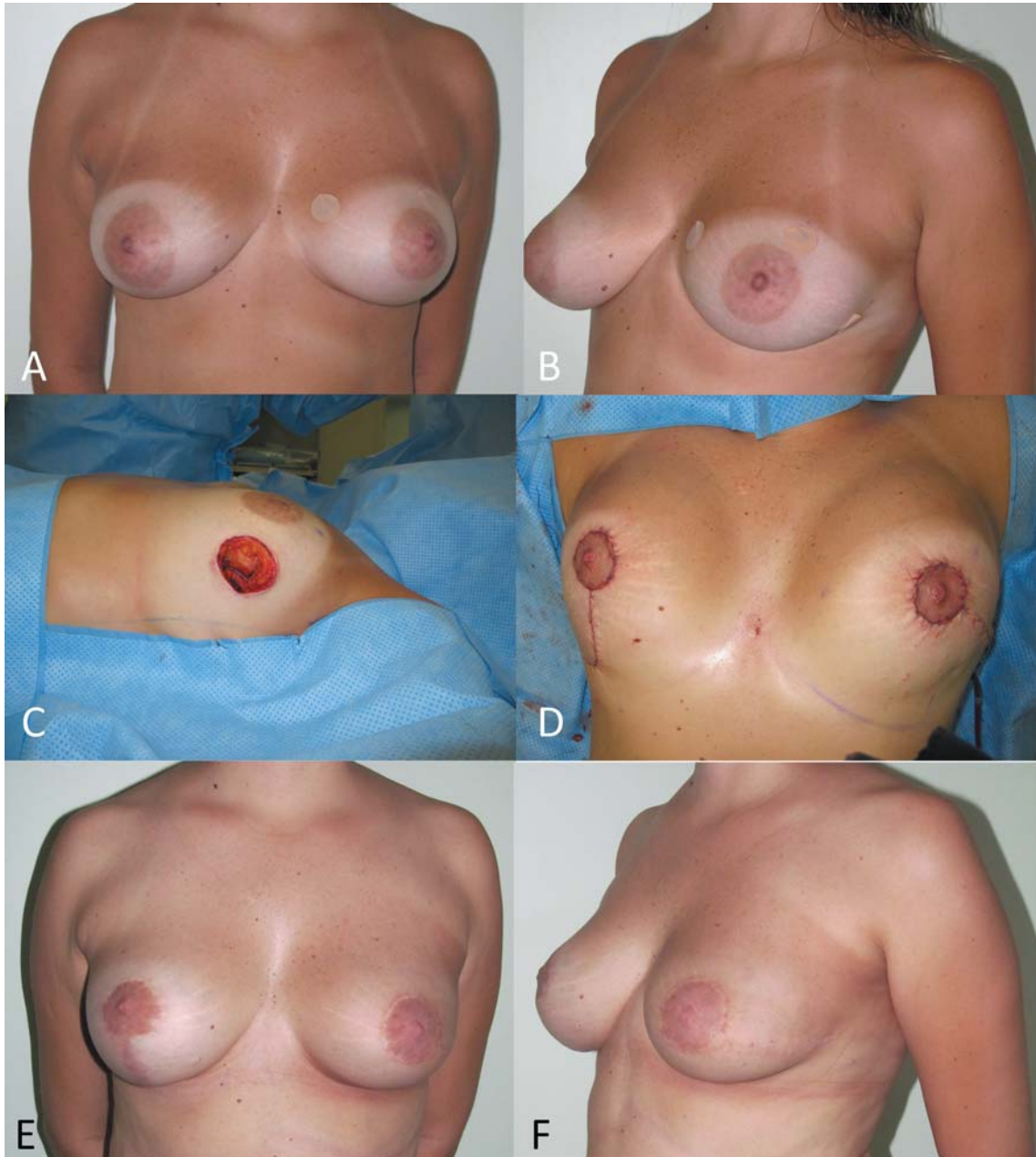


Figure 3. A 53-year-old patient with invasive ductal carcinoma (3.5 cm) of the lateral quadrant of the left breast (A-B, above left and right). The patient underwent a left lateral quadrantectomy and sentinel lymph node biopsy, immediately followed by a bilateral reduction mammoplasty reconstruction; a total of 215 g was removed from the left breast (C-D, center left and right). One year postoperative appearance after the radiotherapy with a very good outcome (E-F, below left and right).

without radiotherapy (37). After adjusting for other risk factors, the probability of complications tends to be higher for the delayed reconstruction group. This finding is similar to published reports which suggest that delayed BCS reconstruction has a significantly higher complication rate compared to immediate procedures (3, 8, 38).

In terms of oncological benefits and adjuvant treatment, immediate BCS reconstruction can be positive. Some clinical series have observed that patients with large-volume breasts present more local complications than patients with normal-volume breasts (34, 36). Additionally, some authors suggested that there is an increased fat

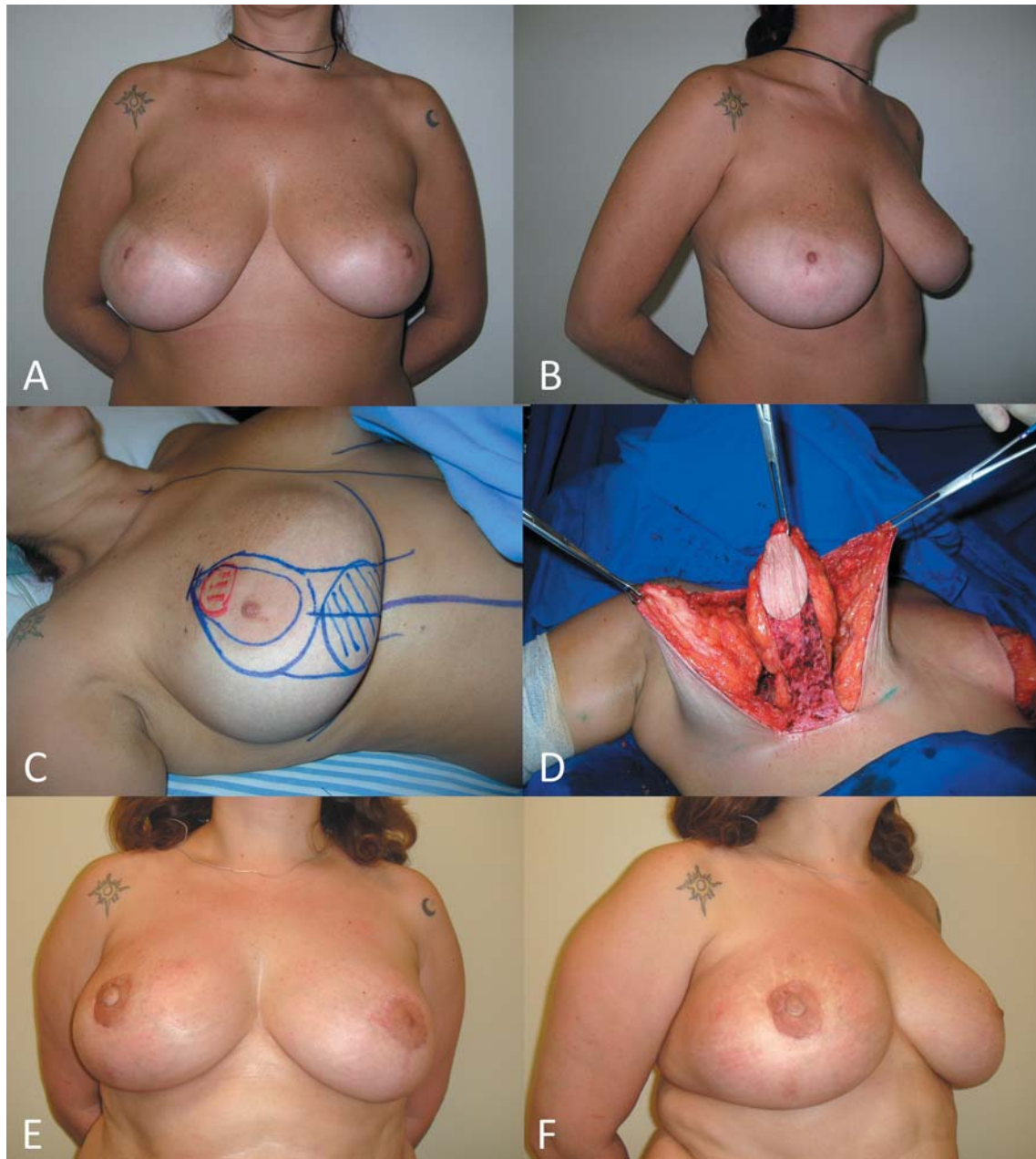


Figure 4. A 44-year-old patient with invasive ductal carcinoma (2.9 cm) of the central quadrant of the right breast (A-B, above left and right). The patient underwent a central right quadrantectomy and sentinel lymph node biopsy, immediately followed by a mastopexy reconstruction with inferior pedicle; a total of 165 g was removed from the right breast (C-D, center left and right). Two years postoperative appearance after the radiotherapy with a very good outcome (E-F, below left and right).

content in large breasts, and the fatty tissue results in more fibrosis, after radiotherapy, than glandular tissue. Gray *et al.* observed that there was more retraction and asymmetry in the large-breasted *versus* the small-breasted group (36). Thus, mammoplasty techniques can increase the eligibility of large-breasted (cup size C and D) patients for BCS since

it can reduce the difficulty of providing radiation therapy (14, 27, 33, 36, 38).

Another aspect is the possibility of accomplishing negative resection margin. In fact, the immediate reconstruction allows for wider local tumor excision, potentially reducing the incidence of margin involvement (27-29, 32, 33, 38). Kaur *et*

Table II. *Oncological and outcome evidence for delivery of adjuvant chemotherapy after immediate BCS reconstruction.*

Author (ref)	Year	n	Tumor size	Adjuvant chemotherapy n (%)	Delay in chemotherapy	Delayed Adjuvant chemotherapy n (%)
Losken <i>et al.</i> (33)	2002	20	Tis – n/d	n/d	–	0
Clough <i>et al.</i> (48)	2003	101	T1 – T4	0	+	4 (4)
Spear <i>et al.</i> (30)	2003	22	n/d	22 (100)	–	0
Munhoz <i>et al.</i> (27)	2006	74	T1 – T2	22 (29.7)	–	0
Thornton <i>et al.</i> (69)	2006	6	T1 – T2	0	–	0
Kronowitz <i>et al.</i> (17)	2007	41	Tis – T2	18 (44)	–	0
Losken <i>et al.</i> (60)	2007	63	Tis – n/d	n/d	–	0
Rietjens <i>et al.</i> (49)	2007	148	T1 – T3	89 (60)	–	0
Fitoussi <i>et al.</i> (16)	2010	540	T1 – T3	n/d	+	10 (1.9)
Song <i>et al.</i> (70)	2010	28	Tis	n/a	–	0
Romics Jr. <i>et al.</i> (71)	2012	31	T1 – T3	31 (100)	–	0
Kahn <i>et al.</i> (39)	2013	169	T1 – T3	n/d	–	0

n/d: Not disclosed; n/a: not applicable; (+): positive, (–): negative.

al. (32) observed that BCS reconstruction permitted larger resections, with a superior mean volume of the specimen and negative margins. Similarly, Down *et al.* compared tumor clearance and the need for further margin excision following standard wide local excision (N=121 patients), and oncoplastic breast-conserving surgery (N=37 patients) (38). These reconstructive techniques included BM, and local flaps. According to the authors, oncoplastic BCS results in higher mean specimen weights (58.1 g × 231.1g, $p < 0.0001$), higher specimen volumes (112.3 cm³ × 484.5 cm³, $p < 0.0001$), and wider clear margins (6.1 mm × 14.3 mm, $p < 0.0001$), resulting in lower rates of further surgery (28.9% × 5.4%, $p = 0.002$). In spite of the benefits, the immediate BCS reconstruction presents limitations. The surgical time can be lengthened and requires for specialist training to learn and properly apply these procedures (3, 4, 13, 14). In theory some complications of the immediate reconstructions can unfavorably alter the adjuvant therapy. In addition, the final contour of the breast cannot be predicted at the time of BCS (17, 33). Some authors observed that although the aesthetic outcome can be satisfactory, the appearance of the radiated breast is occasionally less pleasing than the non-radiated one (14, 27-30). Thus, in delayed reconstruction the plastic surgeon waits until the postoperative changes in the deformed breast stabilize.

With delayed BCS reconstruction, operative time is shortened and the surgical process is less extensive than in immediate BCS. However, some clinical series (14, 17, 27-29, 33, 39) have shown that immediate reconstruction does not compromise the start of radio and chemotherapy in the overall treatment of breast cancer. In fact, Kahn *et al.* in a series of 169 patients, evaluated the time required between multidisciplinary team decision to offer chemotherapy and

delivery of first cycle of chemotherapy in four groups of patients (29). According to the authors, time-to-chemotherapy of BCS reconstruction (n=31) was 29 (16-58) days, and a combined analysis involving all groups demonstrated no statistically significant difference ($p = 0.524$). The authors concluded that BCS reconstruction seems as safe as BCS without reconstruction in terms of adjuvant chemotherapy delivery, and, therefore, should not adversely-affect breast cancer outcome (Table II).

Clinical Results of Reconstruction Techniques

To date, there is limited evidence in the plastic and breast surgery literature on the safety and aesthetic clinical outcome of BCS reconstruction (7, 10, 13, 14, 16, 21, 25-33, 40). In fact, the greater part of clinical studies is retrospective in nature, and are based on a limited number of patients. In addition, there is limited number of data on its impact on local recurrences, distant metastasis and overall survival (13, 40, 41). Haloua *et al.* performed a systematic review on BCS reconstruction studies to evaluate the oncological and aesthetic outcomes (40). Using specific inclusion and exclusion criteria the authors included 88 articles for potential inclusion and reviewed them. In this study, no randomized controlled trials were identified. Eleven prospective observational or comparative studies fulfilled inclusion criteria and were selected and tumor-free resection margins were observed in 78% to 93%, resulting in a 3% to 16% mastectomy rate. Local recurrence was observed in 0% to 7% of the patients. The authors concluded that most studies showed significant weaknesses including lack of robust design and underpowered studies, negatively-influencing generalizability.

Table III. Immediate BCS reconstruction, surgical margins and outcome.

Author, year (ref)	Year	Patients (n)	Follow-up (months)	Tumor size (cm)	Positive margins (%)	Local recurrence (%)
Clough <i>et al.</i> (48)	2003	101	46	3.2 (0.1-7)	10.9	6.9
Clough <i>et al.</i> (9)	1999	20	54	†	0	5
Papp <i>et al.</i> (20)	1998	10	52	†	0	5
Masetti <i>et al.</i> (72)	2000	56	23	†	†	0
Spear <i>et al.</i> (30)	2003	11	24	†	0	0
Losken <i>et al.</i> (33)	2002	14	23	1.5 (0.6-3)	28.6	0
Munhoz <i>et al.</i> (27)	2006	74	22	1.9 (0.6-3.9)	9.5	0
Fitoussi <i>et al.</i> (16)	2010	540	49	2.9	5	6.8

†not specified.

A recent study review of 540 BCS reconstruction procedures revealed a local recurrence rate of 6.8%. In addition, the authors observed involved or close margins in 18.9% with 9.4% requiring further surgery as a mastectomy (16). Semprini *et al.* evaluated 489 submitted to BCS and immediate reconstruction with breast re-shaping and analyzed in terms of oncological safety and esthetic results (50). The authors observed early and late complications in 98 (20%) and 20 cases (4.08%) respectively. According to the authors, no case of cancer relapse after one year of follow-up was observed, while 3 cases (0.6%) after 5 years, were identified.

Chakravorty *et al.* evaluated one of the larger series related to BCS reconstruction comparing oncological outcomes between BCS without reconstruction from the same Center (51). The authors observed a re-excision rate of 2.7% and local recurrence rate of 2.7% and although the follow-up was limited to 28 months, a projected 6-year local recurrence rate was 4.3% in BCS reconstruction group. Despite a larger tumor size and higher grade in the reconstruction group, the local recurrence rates were similar in both groups, with and without reconstruction. These data are similar to local recurrence rates in the large randomized control trials of standard breast-conservation surgery (1, 2, 51).

Concerning the aesthetic outcome there is limited evidence of the BCS reconstruction procedures. In addition, the methods of aesthetic evaluation vary significantly (13, 40, 41). Factors influencing the aesthetic outcome are related to the excised breast volume, postoperative complications and radiotherapy. Some authors reported that the amount of glandular and skin tissue resection is directly associated to aesthetic outcome (42-45). Olivotto *et al.* (42) and Mills *et al.* (43) have documented that excision of a volume greater than 70 cm³ in medium-size breasts often leads to unsatisfactory aesthetic results. Rose *et al.* in a series of 593 patients submitted to BCS, evaluated the long-term aesthetic results by physician assessment (45). According to the authors, scores after 76 months have been rated good and

excellent in 90% of cases (25% and 65%, respectively). Contrarily as observed in other series, tumor size did influence cosmetic result. Similarly Pezner *et al.* utilized the breast retraction index and observed that tumor size and the employment of several radiation fields do not influence the aesthetic results (46). Gendy *et al.*, retrospectively compared the aesthetic outcomes of 106 patients (47). Although the panel scored the cosmetic outcome quite high, the cosmetic failure rate was 18% on breast retraction assessments. The authors demonstrated an advantage for the BCS reconstruction with regard to the incidence of complications (8% versus 14%), additional surgery (12% versus 79%), and restricted activities (54% versus 73%). Clough *et al.* (48) in a panel of three patients groups assessed cosmetic results at 2 and 5 years. At 2 years 88% and at 5 years 82% of patients had a fair-to-excellent outcome. A significantly worse aesthetic outcome was observed in the 13 patients that received pre-operative radiotherapy compared to the remainder which were given radiotherapy post-operatively (poor outcome 42.9% versus 12.7%, $p < 0.02$).

Haloua *et al.*, in a systematic review observed that aesthetic outcome of BCS reconstruction were adequately reported only in 4 studies, and although 3 of these described the method of cosmetic evaluation, no uniform or validated method was used (40). In all, only in 4 studies good aesthetic outcomes were observed in 84% to 89% of patients submitted to immediate BCS reconstruction. Nevertheless, there was a wide variation in both the manner of assessment of cosmetic outcome and the moment of cosmetic assessment.

Concerning the oncological outcome some authors evaluated the local recurrence following BCS reconstruction. Clough *et al.* (48) with a median follow-up of 46 months reported on 101 patients who underwent BCS and reconstruction. Local recurrence developed in 11 cases (5-year local recurrence rate was 9.4%). Thirteen patients developed metastases and eight died of their disease (5 year metastasis-free survival of 82.8% and an overall survival rate of 95.7%). Similarly, Kronowitz *et al.* in a review of 69

patients observed local recurrence in 2% of immediate oncoplastic reconstructions and in 16 percent of delayed cases ($p=0.06$) (11). The difference observed between the two groups can be explained by advanced tumor stage of the patients who had a delayed reconstruction. Recently, Rietjens *et al.* reported on the long-term oncological results of oncoplastic reconstruction in a series of 148 patients (49). With a median follow-up of 74 months, 3% developed an ipsilateral breast cancer recurrence 13% developed distant metastasis. According to the authors the rate of local recurrence after 5 years was low in their series when compared to the 14.3% of cumulative incidence in the NSABP trial, the 9.4% after 5 years in the Institut Curie study and the 0.5% after 5 years in the Milan I trial. Consequently, the immediate reconstruction associated with BCS can be considered as safe as mastectomy in tumors less than 2 cm and possibly safer than the BCS.

Recognizing that there is a small risk for local recurrence and based on clinical series, we believe that immediate application of reconstructive techniques could be a reasonable and safe option for early-breast cancer patients who desire BCS.

Complications, Outcome and Surveillance of Conservative Breast Surgery Reconstruction

Complication rates. There is no evidence that BCS reconstruction techniques result in a significantly higher complication rate than patients without reconstruction. In fact, Down *et al.* in a retrospective study observed no differences in terms of complications between the two groups of patients submitted to BCS with and without reconstruction ($2.4\% \times 5.4\%$, $p=0.32$) (38). Semprini *et al.* evaluated 489 patients submitted to BCS and immediate reconstruction with breast re-shaping and analyzed them in terms of oncological safety and aesthetic results (50). The authors observed early and late complications in 98 (20%) and 20 cases (4.08%) respectively.

In a recently published meta-analysis, the average complication rate in the BCS with reduction mammoplasty reconstruction was 16%, and in the flap-reconstruction group was 14% (41). However, there was no delay in the initiation of adjuvant therapy. According to the authors, it does not seem that complications in the BCS reconstruction group, although potentially higher, have any negative impact on patient care from an oncological point of view. In fact, adequate technique and patient selection is crucial in order to minimize morbidity when these oncoplastic techniques are selected (16, 41).

Concerning late complications, the most common event is related to fat necrosis. Munhoz *et al.* compared immediate and delayed BCS reconstruction with reduction mammoplasty techniques, and observed that this complication was significantly higher in the delayed group (37). In fact,

radiation therapy played a significant role and contributed to development of fat necrosis. One might surmise that in delayed reconstructions, a slower re-establishment of a local blood supply to re-arranged breast tissues from the underlying irradiated chest wall can be observed. In addition, previous breast tissue scarring and local effects of radiotherapy can also disrupt the local blood supply and the ability to create a safe parenchymal pedicle (8, 35-37). Thus, in these patients a careful surveillance is prudent since the risk of local recurrence is always possible. According to Losken *et al.* (33), postoperative surveillance is not impaired by simultaneous BM. In some cases, calcification and fat necrosis can simulate tumor recurrence; however, these aspects can be distinguished on mammogram or core biopsies (14, 27-29).

Radiation therapy. Frequently, the appearance of the radiated breast is less pleasing than the non-radiated one and total dose, the boost therapy and the number of radiation fields may be involved (14, 15, 27, 30, 33-36). Losken *et al.*, emphasized that when radiation is expected, the possibility of fibrosis/atrophy should be taken into account in an attempt to preserve symmetry (33). The authors suggested a less aggressive reduction on the ipsilateral breast to accommodate for any additional size distortion. Additionally, some authors advocated that oncoplastic reconstruction with radiation is best achieved using autologous, non-irradiated flaps (3, 8, 11, 12).

Another important issue is related to BCS reconstruction and boost radiotherapy. All immediate techniques that involve re-arrangement of glandular tissue may jeopardize the boost radiation dose delivery since the target area for the radiation is defined as the site of the tumor (14, 27-29, 52). To locate the original tumor area, it is recommend to orientate the tumor site by skin markings and also placing surgical clips at the tumor margins. Similarly as observed by a other authors (52-54) the identification of the original tumor bed based only on physical exam, without precise imaging information, can result in missing the primary tumor bed in a substantial percentage of patients. Munhoz *et al.* (27-29), observed that surgical clips have not interfered with mammography, and, actually, have helped recognize areas at-risk for recurrence. Additionally, clips have not been mentioned as interfering with physical examination or cosmesis or to have added to any morbidity related to the reconstructive procedure (54).

Surgical margins and reconstructive techniques. Intraoperative margin evaluation is usually assessed by pathological monitoring, which is based on radiological, macroscopic, and histological examination of frozen sections (55-59). Diverse techniques have been described, depending on the tumor type, size, the BCS technique, and whether or not the tumor is palpable (56, 57). Unfortunately, all techniques can present some limitations and as with any

other test, there is an inherent false-negative rate (56). BCS reconstructive techniques that involve re-arrangement of glandular tissue make re-excision difficult in cases where close or positive margins are observed (14, 27-29, 60). This fact could make it difficult to locate the residual tumor and to perform margin re-excision. Munhoz *et al.* observed that positive margins discovered on permanent pathology in a previously negative margin patient were observed in 5.5% (55). Previous studies have been investigating the risk factors to identify patients with a high probability of having positive margins following BCS (55, 57, 60, 62, 63). In these series, younger age (55, 60, 62, 63), histopathological characteristics (*in situ* carcinoma) (55, 60, 62, 63), and larger tumor size (55, 63) have all been associated with positive margins. Thus, the present data suggest that patients with those characteristics require for more meticulous intraoperative margin evaluation to avoid the need for re-operation. Concerning the re-operative rates, Weinberg *et al.* (64) observed that 6.2% had later re-excisions and Cendán *et al.* (65) reported that 19.6% of subjects required additional operations to clear surgical margins. Olson *et al.* (58) observed that 11.3% of patients submitted to BCS require for second operations to achieve negative margins.

Some authors believe that although microscopic evaluation can go a long way to reducing errors, this negative aspect cannot be totally eliminated, especially when dealing with large specimens for which freezing the entire lesion is not justified (56, 61). Some errors may result from artifacts of the freezing procedure and/or inexperience on the part of the pathologist interpreting the slide (56). Rietjens *et al.*, in a recent study observed 8% of positive or close margin involvement, which is less than the 10% observed in the NSABP B-06 trial (49). Conversely, Kronowitz *et al.* revealed that postoperative margins were positive in 15.7% of patients who underwent breast-conserving surgery (11).

Despite these aspects, the positive margins can be effectively managed with either re-excision with/without reconstruction or with skin-sparing mastectomy and total reconstruction, depending on the extent of tissue resection, preference, and pathology. The decision to re-operate depends on the extent of tumor involvement, whether the dissection had already been extended to the chest wall or skin, or whether the patient had opted to proceed with a total reconstruction. In addition, re-operation was not a disadvantage in these patients and the negative aspect of a more extensive surgery is negligible. However, it is important that the patient should be appropriately informed about the risk of further positive margins and the requirement of additional surgery (55, 60). Thus, intraoperative assessment of surgical margins require for multidisciplinary cooperation among oncological and plastic surgeons and pathologists (Table III).

BCS reconstruction surveillance. In spite of the fact that BCS reconstruction has recently increased, some restrictions about combining BCS with partial breast reconstruction alters the architecture and make postoperative cancer surveillance more difficult. Losken *et al.* retrospectively reviewed the charts and mammograms of 17 patients with an average follow-up of 6.3 years who underwent BCS reconstruction (66). These data were compared to those of a control group from the same time period who underwent BCS without reconstruction. According to the authors, typical mammographic findings, including architectural distortion, cysts, and calcifications, were similar between the two groups. There was no significant difference in breast density scores. In addition the reconstructed group had longer times to mammographic stabilization (21.2×25.6 months, $p=0.23$) and a trend toward a greater number of postoperative mammograms and ultrasounds in this group was observed. The rate of tissue sampling in the study group was significantly higher (53 percent) than that in the control group (18 percent). Thus, in terms of postoperative surveillance, BCS reconstruction remains safe and effective, without significantly affecting postoperative mammographic findings. These results corroborate with the findings of Roberts *et al.* concerning the incidence of abnormal mammograms after reduction mammoplasty (67). In fact, these authors observed that, despite the substantial mobilization of tissue, postoperative mammography did not lead to more diagnostic interventions than non-operative controls. Concerning late complications, the most common event is related to fat necrosis, and this aspect is well-defined in the conventional mammograms. Munhoz *et al.* in a study comparing immediate and delayed BCS reconstruction with reduction mammaplasty techniques, the complication rates and fat necrosis were significantly higher in the delayed group (37). It has been their impression that radiation therapy played a significant role and contributed to development of fat necrosis. One might surmise that in delayed reconstructions, a slower re-establishment of a local blood supply to re-arranged breast tissues from the underlying irradiated chest wall can be observed. In addition, previous breast tissue scarring and local effects of radiotherapy can also disrupt the local blood supply and the ability to create a safe parenchymal pedicle. Thus, in these patients a careful surveillance is prudent since the risk of local recurrence is always possible. According to Losken *et al.* (41, 60, 66), in some cases calcifications and fat necrosis can simulate tumor recurrence; however, these aspects can be distinguished on mammogram or core biopsy (27-29, 60).

Conclusion

The field of BCS reconstruction has greatly evolved over the last years. Partial breast defects represent an anatomic variety that ranges from small defects that may repair with primary closure, to large defects that involve skin, NAC and a significant amount of glandular tissue. Each defect has its

own special reconstructive necessities and varying expectations for aesthetic results. The incorporation of oncological and plastic surgery reconstructive techniques allows for the complete resection of local disease while achieving a satisfactory aesthetic outcome. The option of reconstructive technique depends on the patient's breast size, tumor location, the excised volume, and the volume of the remaining glandular tissue. A number of procedures have been described which involve primary closure, breast reshaping, local and distant flaps. In addition, some different classifications have been proposed to describe the extent of resection, which has consequently created a wide range of surgical options with different indications. In selected patients, this approach has allowed us to perform wide resections and obtain good oncological control with favorable aesthetic outcome. Although the combined approach requires for more preoperative planning and intraoperative care, the concept can reduce deformities, favor the oncological treatment and optimize the aesthetic outcome in most early-stage cancer patients.

References

- Veronesi U, Cascinelli N, Mariani L, Greco M, Saccozzi R, Luini A, Aguilar M and Marubini E: Twenty-year follow-up of a randomized study comparing breast-conserving surgery with radical mastectomy for early breast cancer. *N Engl J Med* 347: 1227-1235, 2002.
- Fisher B, Anderson S, Bryant J, Margolese RG, Deutsch M, Fisher ER, Jeong JH and Wolmark N: Twenty-year follow-up of a randomized trial comparing total mastectomy, lumpectomy, and lumpectomy plus irradiation for the treatment of invasive breast cancer. *N Engl J Med* 347: 1233-1241, 2002.
- Hamdi M, Wolfli J and Van Landuyt K: Partial mastectomy reconstruction. *Clin Plast Surg* 34: 51-62, 2007.
- Munhoz AM, Aldrighi C and Ferreira MC: Paradigms in oncoplastic breast surgery: A careful assessment of the oncological need and aesthetic objective. *Breast Journal* 13: 326-327, 2007.
- Petit JY, Rietjens M, Garusi M, Greuze M and Perry C: Integration of plastic surgery in the course of breast conserving surgery for cancer to improve cosmetic results and radicality of tumor excision. *Recent Results Cancer Res* 11: 78-84, 1998.
- Audretsch W, Rezai M, Kolotas C: Tumor-specific immediate reconstruction in breast cancer patients. *Perspec Plast Surg* 11: 71-79, 1998.
- Huemer GM, Schrenk P, Moser F, Wagner E and Wayand W: Oncoplastic techniques allow breast-conserving treatment in centrally located breast cancers. *Plast Reconstr Surg* 120: 390-398, 2007.
- Slavin SA and Halperin T: Reconstruction of the breast conservation deformity. *Sem Plast Surg* 18: 89-100, 2004.
- Clough K, Kroll S and Audretsch W: An approach to the repair of partial mastectomy defects. *Plast Reconstr Surg* 104: 409-420, 1999.
- Clough KB, Thomas SS, Fitoussi AD, Couturaud B, Reyat F and Falcou MC: Reconstruction after conservative treatment for breast cancer: cosmetic sequelae classification revisited. *Plast Reconstr Surg* 114: 1743-1750, 2004.
- Kronowitz SJ, Feledy JA, Hunt KK, Kuerer HM, Youssef A, Koutz CA and Robb GL: Determining the optimal approach to breast reconstruction after partial mastectomy. *Plast Reconstr Surg* 117: 1-11, 2006.
- Blondeel P, Hijjawi J, Depypere H, Roche N and Van Landuyt K: Shaping the breast in aesthetic and reconstructive breast surgery: an easy three step principle. Part III e reconstruction following breast conservative treatment. *Plast Reconstr Surg* 124: 28-38, 2009.
- Asgeirsson KS, Rasheed T, McCulley SJ and Macmillan RD: Oncological and cosmetic outcomes of oncoplastic breast conserving surgery. *Eur J Surg Oncol* 31: 817-827, 2005.
- Munhoz AM, Montag E, Arruda E, Pellarin L, Filassi JR, Piatto JR, de Barros AC, Prado LC, Fonseca A, Baracat E and Ferreira MC: Assessment of immediate conservative breast surgery reconstruction: a classification system of defects revisited and an algorithm for selecting the appropriate technique. *Plast Reconstr Surg* 121: 716-727, 2008.
- Berrino P, Campora E and Santi P: Postquadrantectomy breast deformities; classification and techniques of surgical correction. *Plast Reconstr Surg* 79: 567-72, 1987.
- Fitoussi AD, Berry MG, Fama F, Falcou MC, Curnier A, Couturaud B, Reyat F and Salmon RJ: Oncoplastic breast surgery for cancer: analysis of 540 consecutive cases. *Plast Reconstr Surg* 125: 454-462, 2010.
- Kronowitz SJ, Hunt K, Kuerer HM and Strom HM: Practical guidelines for repair of partial mastectomy defects using the breast reduction technique in patients undergoing breast conservation therapy. *Plast Reconstr Surg* 120: 1755-1779, 2007.
- Kroll SS and Singletary SE: Repair of partial mastectomy defects. *Clin Plast Surg* 25: 303-309, 1998.
- Yang JD, Lee JW, Cho YK, Kim WW, Hwang SO, Jung JH and Park HY: Surgical Techniques for Personalized Oncoplastic Surgery in Breast Cancer Patients with Small- to Moderate-Sized Breasts (Part 1): Volume Displacement. *J Breast Cancer* 15: 1-6, 2012.
- Papp C, Wechselberger G and Schoeller T: Autologous breast reconstruction after breast-conserving cancer surgery. *Plast Reconstr Surg* 102: 1932-1939, 1998.
- Munhoz AM, Montag E, Arruda E, Aldrighi C, Gemperli R, Aldrighi JM and Ferreira MC: The role of the lateral thoracodorsal fasciocutaneous flap in immediate conservative breast surgery reconstruction. *Plast Reconstr Surg* 117: 1699-1709, 2006.
- Holmstrom H and Lossing C: The lateral thoracodorsal flap in breast reconstruction. *Plast Reconstr Surg* 77: 933-938, 1986.
- Levine JL, Reddy PP and Allen RJ: Lateral thoracic flaps in breast reconstruction. In: Nahabedian M, editor. *Oncoplastic Surgery of the Breast*. Philadelphia:Saunders Elsevier 83-92, 2009.
- Yang JD, Lee JW, Cho YK, Kim WW, Hwang SO, Jung JH and Park HY: Surgical Techniques for Personalized Oncoplastic Surgery in Breast Cancer Patients with Small- to Moderate-Sized Breasts (Part 2): Volume Replacement. *J Breast Cancer* 15: 7-14, 2012.
- Munhoz AM, Montag E, Arruda E, Aldrighi C, Gemperli R, Aldrighi JM and Ferreira MC: Outcome analysis of breast-conservation surgery and immediate latissimus dorsi flap reconstruction in patients with T1 to T2 breast cancer. *Plast Reconstr Surg* 116: 741-750, 2005.

- 26 Chang DW, Youssef A, Cha S and Reece GP: Autologous breast reconstruction with the extended latissimus dorsi flap. *Plast Reconstr Surg* 110: 751-759, 2002.
- 27 Munhoz AM, Montag E, Arruda E, Aldrighi C, Gemperli R, Aldrighi JM and Ferreira MC: Critical analysis of reduction mammoplasty techniques in combination with conservative breast surgery for early breast cancer treatment. *Plast Reconstr Surg* 117: 1091-1103, 2006.
- 28 Munhoz AM, Montag E, Arruda E, Aldrighi C, Gemperli R, Aldrighi JM and Ferreira MC: Superior-medial dermoglandular pedicle reduction mammoplasty for immediate conservative breast surgery reconstruction. *Ann Plast Surg* 57: 502-511, 2006.
- 29 Munhoz AM, Montag E, Arruda E, Aldrighi C, Gemperli R, Aldrighi JM and Ferreira MC: Reliability of inferior dermoglandular pedicle reduction mammoplasty in reconstruction of partial mastectomy defects: surgical planning and outcome. *Breast* 16: 577-89, 2007.
- 30 Spear SL, Pelletiere CV, Wolfe AJ, Tsangaris TN and Pennanen MF: Experience with reduction mammoplasty combined with breast conservation therapy in breast cancer. *Plast Reconstr Surg* 111: 1102-1110, 2003.
- 31 Ricci MD, Munhoz AM, Geribela A, Geribela AH, Teixeira LC, Aldrighi C, Ferreira MC, Filassi JR and Pinotti JA: The influence of reduction mammoplasty techniques in synchronous breast cancer diagnosis and metachronous breast cancer prevention. *Ann Plast Surg* 57: 125-136, 2006.
- 32 Kaur N, Petit JY, Rietjens M, Maffini F, Luini A, Gatti G, Rey PC, Urban C and De Lorenzi F: Comparative study of surgical margins in oncoplastic surgery and quadrantectomy in breast cancer. *Ann Surg Oncol* 12: 539-549, 2005.
- 33 Losken A, Elwood ET, Styblo TM and Bostwick J 3rd: The role of reduction mammoplasty in reconstructing partial mastectomy defects. *Plast Reconstr Surg* 109: 968-976, 2002.
- 34 Chang E, Johnson N, Webber B, Booth J, Rahhal D, Gannett D, Johnson W, Franzini D and Zegzula H: Bilateral reduction mammoplasty in combination with lumpectomy for treatment of breast cancer in patients. *Am J Surg* 187: 647-655, 2004.
- 35 Brierley JD, Paterson IC, Lallemand RC and Rostom AY: The influence of breast size on late radiation reaction following excision and radiotherapy for early breast cancer. *Clin Oncol* 3: 6-12, 1991.
- 36 Gray JR, McCormick B, Cox L and Yahalom J: Primary breast irradiation in large-breasted or heavy women: analysis of cosmetic outcome. *Int J Radiat Oncol Biol Phys* 21: 347-356, 1991.
- 37 Munhoz AM, Aldrighi CM, Montag E, Arruda E, Brasil JA, Filassi JR, Aldrighi JM, Gemperli R and Ferreira MC: Outcome analysis of immediate and delayed conservative breast surgery reconstruction with mastopexy and reduction mammoplasty techniques. *Ann Plast Surg* 67: 220-225, 2011.
- 38 Down SK, Jha PK, Burger A and Hussien MI: Oncological advantages of oncoplastic breast-conserving surgery in treatment of early breast cancer. *Breast J* 19: 56-63, 2013.
- 39 Kahn J, Barrett S, Forte C, Stallard S, Weiler-Mithoff E, Doughty JC and Romics L Jr: Oncoplastic breast conservation does not lead to a delay in the commencement of adjuvant chemotherapy in breast cancer patients. *Eur J Surg Oncol* 39: 887-891, 2013.
- 40 Haloua MH, Krekel NM, Winters HA, Rietveld DH, Meijer S, Bloemers FW and van den Tol MP: A systematic review of oncoplastic breast-conserving surgery: current weaknesses and future prospects. *Ann Surg* 257: 609-620, 2013.
- 41 Losken A, Dugal CS, Styblo TM and Carlson GW: A Meta-Analysis Comparing Breast Conservation Therapy Alone to the Oncoplastic Technique. *Ann Plast Surg* Mar 13. [Epub ahead of print] 2013.
- 42 Olivotto IA, Rose MA, Osteen RT, Love S, Cady B, Silver B, Recht A and Harris JR: Late cosmetic outcome after conservative surgery and radiotherapy: analysis of causes of cosmetic failure. *Int J Radiat Oncol Biol Phys* 17: 747-753, 1989.
- 43 Mills JM, Schultz DJ and Solin LJ: Preservation of cosmesis with low complication risk after conservative surgery and radiotherapy for ductal carcinoma *in situ* of the breast. *Int J Radiat Oncol Biol Phys* 39: 637-641, 1997.
- 44 Cochrane R, Valasiadou P, Wilson A, Al-Ghazal SK and Macmillan RD: Cosmesis and satisfaction after breast-conserving surgery correlates with the percentage of breast volume excised. *Br J Surg* 90: 1505-1509, 2003.
- 45 Rose MA, Olivotto I, Cady B, Koufman C, Osteen R, Silver B, Recht A and Harris JR: Conservative surgery and radiation therapy for early breast cancer. Long-term cosmetic results. *Arch Surg* 124: 153-157, 1989.
- 46 Pezner RD, Patterson MP, Hill LR, Vora NL, Desai KR and Lipsett JA: Breast retraction assessment. An objective evaluation of cosmetic results of patients treated conservatively for breast cancer. *Int J Radiat Oncol Biol Phys* 11: 575-578, 1985.
- 47 Gendy RK, Able JA and Rainsbury RM: Impact of skin-sparing mastectomy with immediate reconstruction and breast-sparing reconstruction with miniflaps on the outcomes of oncoplastic breast surgery. *Br J Surg* 90: 433-439, 2003.
- 48 Clough KB, Lewis JS, Couturaud B, Fitoussi A, Nos C and Falcou MC: Oncoplastic techniques allow extensive resection for breast-conserving therapy of breast carcinomas. *Ann Surg* 237: 26-34, 2003.
- 49 Rietjens M, Urban CA, Rey PC, Mazzarol G, Maisonneuve P, Garusi C, Intra M, Yamaguchi S, Kaur N, De Lorenzi F, Matthes AG, Zurrida S and Petit JY: Long-term oncological results of breast conservative treatment with oncoplastic surgery. *Breast* 16: 387-395, 2007.
- 50 Semprini G, Cattin F, Vaienti L, Brizzolari M, Cedolini C and Parodi PC: Oncoplastic surgery and cancer relapses: cosmetic and oncological results in 489 patients. *Breast* 22: 946-951, 2013.
- 51 Chakravorty A, Shrestha AK, Sanmugalingam N, Rapisarda F, Roche N, Querci Della Rovere G and Macneill FA: How safe is oncoplastic breast conservation? Comparative analysis with standard breast conserving surgery. *Eur J Surg Oncol* 38: 395-398, 2012.
- 52 Solin L, Danoff B, Schwartz G, Galvin JM and Goodman RL: A practical technique for the localization of the tumor volume in definitive irradiation of the breast. *Int J Radiat Oncol Biol Phys* 11: 1215-1220, 1985.
- 53 Solin L, Chu J, Larsen R, Fowble B, Galvin JM and Goodman RL: Determination of depth for electron breast boosts. *Int J Radiat Oncol Biol Phys* 13: 1915-1919, 1987.
- 54 Regine W, Ayyangar K, Komarnickv L, Bhandare N and Mansfield CM: Computer-CT planning of the electron boost in definitive breast irradiation. *Int J Radiat Oncol Biol Phys* 20: 121-125, 1991.
- 55 Munhoz AM, Montag E, Arruda E, Aldrighi CM, Filassi JR, Piatto JR, Prado LC, Aldrighi JM, Gemperli R and Ferreira MC: Immediate reconstruction following breast-conserving surgery: Management of the positive surgical margins and influence on secondary reconstruction. *Breast* 18: 47-54, 2009.

- 56 Laucirica, R: Intraoperative assessment of the breast: Guidelines and potential pitfalls. *Arch Pathol Lab Med* 129: 1565-1583, 2005.
- 57 Cabioglu N, Hunt KK, Sahin AA, Kuerer HM, Babiera GV, Singletary SE, Whitman GJ, Ross MI, Ames FC, Feig BW, Buchholz TA and Meric-Bernstam F: Role for intraoperative margin assessment in patients undergoing breast-conserving surgery. *Ann Surg Oncol* 14: 1458-1467, 2007.
- 58 Olson TP, Harter J, Muñoz A, Mahvi DM and Breslin T: Frozen section analysis for intraoperative margin assessment during breast-conserving surgery results in low rates of re-excision and local recurrence. *Ann Surg Oncol* 14: 2953-2960, 2007.
- 59 Balch GC, Mithani SK, Simpson JF and Kelley MC: Accuracy of intraoperative examination of surgical margin status in women undergoing partial mastectomy for breast malignancy. *Am Surg* 71: 22-31, 2005.
- 60 Losken A, Styblo TM, Carlson GW, Jones GE and Amerson BJ: Management algorithm and outcome evaluation of partial mastectomy defects using reduction or mastopexy techniques. *Ann Plast Surg* 59: 235-242, 2007.
- 61 Singletary SE: Surgical margins in patients with early-stage breast cancer treated with breast conservation therapy. *Am J Surg* 184: 383-390, 2002.
- 62 Obedian E and Haffty BG: Negative margin status improves local control in conservatively managed breast cancer patients. *Cancer J Sci Am* 6: 28-37, 2000.
- 63 Tartter PI, Kaplan J and Bleiweiss I: Lumpectomy margins, re-excision, and local recurrence of breast cancer. *Am J Surg* 179: 81-90, 2000.
- 64 Weinberg E, Cox C, Dupont E, White L, Ebert M, Greenberg H, Diaz N, Vercel V, Centeno B, Cantor A and Nicosia S: Local recurrence in lumpectomy patients after imprint cytology margin evaluation. *Am J Surg* 188: 349-357, 2004.
- 65 Cendán JC, Coco D and Copeland EM: Accuracy of intraoperative frozen-section analysis of breast cancer lumpectomy margins. *J Am Coll Surg* 201: 194-203, 2005.
- 66 Losken A, Schaefer TG, Newell M and Styblo TM: The impact of partial breast reconstruction using reduction techniques on postoperative cancer surveillance. *Plast Reconstr Surg* 124: 9-17, 2009.
- 67 Roberts JM, Clark CJ, Campbell MJ and Paige KT: Incidence of abnormal mammograms after reduction mammoplasty: implications for oncoplastic closure. *Am J Surg* 201: 611-614, 2011.
- 68 Goffman TE, Schneider H, Hay K, Elkins DE, Schnarrs RA and Carman C: Cosmesis with bilateral mammoreduction for conservative breast cancer treatment. *Breast J* 11: 195-198, 2005.
- 69 Thornton BP, Stewart DH, McGrath PC and Pu LL: Breast reduction as an alternative treatment option for early breast cancer in women with macromastia. *Ann Plast Surg* 56: 26-30, 2006.
- 70 Song HM, Styblo TM, Carlson GW and Losken A: The use of oncoplastic reduction techniques to reconstruct partial mastectomy defects in women with ductal carcinoma *in situ*. *Breast J* 16: 141-146, 2010.
- 71 Romics Jr L, Chew BK, Weiler-Mithoff E, Doughty JC, Brown IM, Stallard S, Wilson CR, Mallon EA and George WD: Ten-year follow-up of skin-sparing mastectomy followed by immediate breast reconstruction. *Br J Surg* 99: 799-806, 2012.
- 72 Masetti R, Di Leone A, Franceschini G, Magno S, Terribile D, Fabbri MC and Chiesa F: Oncoplastic techniques in the conservative surgical treatment of breast cancer: an overview. *Breast J* 12: 174-180, 2006.

Received December 18, 2013

Revised January 10, 2014

Accepted January 14, 2014