

Distinct Expression and Localization of TNF System in Ovarian Carcinoma Tissues: Possible Involvement of TNF- α in Morphological Changes of Ovarian Cancerous Cells

BENJAMIN PIURA^{1,4}, LIAT MEDINA^{2,4}, ALEX RABINOVICH^{1,4},
VICTOR DYOMIN^{3,4}, RUTHY SHACO LEVY^{3,4} and MAHMOUD HULEIHEL^{2,4}

¹Unit of Gynecologic Oncology, Division of Obstetrics and Gynecology, and

³Institute of Pathology, Soroka University Medical Center, Beer-Sheva, Israel;

²The Shruga Segal Department of Microbiology, Immunology and Genetics,

⁴Faculty of Health Sciences, Ben-Gurion University of the Negev, Beer-Sheva, Israel

Abstract. *Background/Aim: It has been previously shown that epithelial ovarian carcinoma tissues express high levels of tumor necrosis alpha (TNF- α), interleukin (IL)-6, IL-1 α and IL-1 β . The aim of the present study was to evaluate the localization of TNF- α and its receptors (TNFR1 and TNFR2) in different types of ovarian carcinoma tissues and the possible role of TNF in the pathogenesis of epithelial ovarian carcinoma. Materials and Methods: Total RNA was extracted from normal and cancerous ovarian tissues and mRNA was analyzed with semi-quantitative reverse transcriptase-polymerase chain reaction (RT-PCR). Immunohistochemical staining was performed with use of antibodies against human (ah)TNFR1 and TNF2. Results: TNF- α mRNA and TNFR2 mRNA levels were significantly higher in ovarian carcinoma tissues than in normal ovarian tissues, whereas TNFR1 mRNA levels were similar. TNFR1 and TNFR2 were mainly localized in the epithelial neoplastic cells of the tumor. Knocking-down TNF- α activity with ahTNF- α altered ovarian carcinoma cell morphology (with more branches) in vitro. Conclusion: Our study indicates a possible role of TNF- α in epithelial ovarian carcinoma pathogenesis through TNFR2, which affects morphological changes, which may be involved ovarian cancer pathogenesis.*

Correspondence to: Mahmoud Huleihel, Ph.D., The Shruga Segal Department of Microbiology, Immunology and Genetics, Faculty of Health Sciences, Ben-Gurion University of the Negev, Beer-Sheva, Israel. Tel: +972 86479959, e-mail: huleihel@bgu.ac.il and Benjamin Piura, MD, F.R.C.O.G., Unit of Gynecologic Oncology, Division of Obstetrics and Gynecology, Soroka University Medical Center, P.O.B. 151, Beer-Sheva 84101, Israel. Tel: +972 542365959, e-mail: piura@bgu.ac.il

Key Words: Ovarian carcinoma, TNF- α , TNFR, cell morphology.

Epithelial ovarian carcinoma (EOC) is diagnosed in 22,000 women yearly and causes approximately 15,000 deaths each year in the USA (1), with a worldwide annual incidence and mortality of 225,000 and 140,000, respectively (2, 3). It is the leading cause of death from gynecological malignancies in the USA and is the second leading cause of death, after uterine cervix cancer, due to gynecological malignancies in the world (1-3).

Cytokines are autocrine/paracrine immunoregulatory polypeptide factors that participate in the process of various biological conditions, including inflammation and tumorigenesis (4, 5). In the past, the prevailing opinion was that tumor-infiltrating lymphocytes (TIL) and tumor-associated macrophages (TAM), not the epithelial cancerous cells, are the source of tumor necrosis-alpha (TNF- α), interleukin (IL)-6, IL-1 and other cytokines expressed in EOC. In recent years, however, it has been established that the ovarian epithelial cancerous cells are the main source of these cytokines (4-7). We have previously shown that (6, 7) i) TNF- α activity is detected only in supernatants of EOC cell cultures; ii) EOC tissues express high levels of TNF- α and IL-6 localized predominantly in the cancerous epithelial cells, whereas normal ovarian tissues express low levels of both cytokines localized mainly in the stroma; iii) IL-1 is detected only in supernatants of EOC cell cultures; iv) Both IL-1 α and IL-1 β are more strongly expressed in EOC tissues than in normal ovarian tissues and are localized mainly in cancerous epithelial cells.

TNF- α is produced primarily as a type-II transmembrane form (26 kDa) arranged in stable homotrimers. A mature, soluble homotrimeric 17-kDa TNF is released from transmembrane TNF through proteolytic cleavage by the metalloprotease TNF-converting enzyme (8-11). TNF- α has been implicated in the pathophysiology of infections and autoimmune diseases and there is growing evidence showing

that TNF- α and its receptors modulate the expression of other cytokines and are involved in the process of tumorigenesis and angiogenesis (10, 12-16). Three main arms of the TNF- α signaling network are recognized (10, 17, 18): i) Recruitment of caspase-8 by Fas-associated death domain that leads to apoptosis; ii) Recruitment of cellular inhibitors of apoptosis by TNFR-associated factor 2 that leads to activation of c-Jun terminal kinase and protection against apoptosis; iii) Activation of the transcription factor nuclear factor-kappa B (NF- κ B) by protein kinase receptor-interacting protein that leads to the translocation of NF- κ B from the cytoplasm to the nucleus. The ability of NF- κ B in the nucleus to bind DNA results in the expression of NF- κ B-dependent genes, such as vascular endothelial growth factor, basic fibroblast growth factor, IL-8, and matrix metalloproteinases, that are factors necessary for angiogenesis and tumorigenesis (10, 14, 16, 17, 19, 20). With use of immunohistochemical staining, we have demonstrated in a previous study that TNF α is more strongly expressed in ovarian carcinoma tissues compared to normal ovarian tissues and is mainly localized in the epithelial neoplastic cells (7).

TNF- α interacts with two receptors, TNFR1 (p55, CD120a, 50-60 kDa) and TNFR2 (p75, CD120b, 70-80 kDa) (21). TNFR1 is constitutively expressed by most cell types, while constitutive expression of TNFR2 is mostly limited to cells of the immune system (22, 23). TNFR1 signaling can result in the activation of several pathways, including mitogen-activated protein kinases and NF- κ B, leading to proliferation and survival, and can result in the activation of caspases, leading to apoptosis (24). TNFR2 does not activate the apoptotic pathways but otherwise may enhance TNFR1-induced cell death or promote cell activation, migration, or proliferation through the mitogen-activated protein kinases and NF κ B (10, 11, 22, 23). It has been shown that the production of TNF- α by EOC cells stimulates a constitutive network of other cytokines, angiogenic factors, and chemokines that may act in an autocrine/paracrine manner to promote tumorigenesis (13, 25).

The aim of our study was to evaluate the expression levels and cellular origin of TNF- α , TNFR1 and TNFR2 in normal and cancerous ovarian tissues, and to assess the possible involvement of TNF- α in ovarian carcinoma cell-cell interaction, such as cell morphology.

Materials and Methods

Origin and handling of ovarian tissues. Fresh normal and cancerous ovarian tissues were collected under sterile conditions from the operating room of the Department of Obstetrics and Gynecology, Soroka University Medical Center, Beer-Sheva, Israel. The Institutional Review Board (IRB) approved the study (No. 1492) and informed consent to participate in the study was obtained from all women. Normal ovarian tissues were obtained from 22 women who underwent surgery for benign gynecological conditions and cancerous ovarian tissue was obtained from 15 women who had surgery for

EOC. The histopathological diagnosis was confirmed by examining the formalin-fixed, paraffin-embedded tissues. Fresh tissue samples were immediately washed with cold phosphate-buffered saline (PBS) to eliminate residual blood cells. Approximately 1-2 g of each fresh ovarian tissue was used for the establishment of primary cell culture. The remaining tissue was stored at -70°C and was later used for the evaluation of protein and mRNA levels.

Preparation of homogenates from ovarian tissues. Normal and cancerous ovarian tissues were separately homogenized (100 mg wet weight/ml) in PBS (10 mM sodium phosphate and 150 mM sodium chloride, pH=7.8) containing 0.2% Triton X-100 with a Teflon glass tissue grinder on ice (15 strokes). Homogenates were centrifuged (3,000 \times g at 4°C for 15 min), and the supernatant fractions were collected, stored at -70°C , and later used for enzyme-linked immunosorbent assay (ELISA).

Extraction of total RNA and semi-quantitative reverse transcriptase – polymerase chain reaction (RT-PCR) analysis for mRNA. Total RNA was extracted from normal and cancerous ovarian tissues using the EZ-RNA Reagent protocol (Biological Industries, Beit HaE'mek, Israel). First-strand complementary DNAs (cDNAs) were synthesized from 2.5 μg total RNA with $5\times$ RT buffer, 2 μM oligo (dT) primers (Sigma St. Louis, MO, USA), 0.5 mM dNTP mix (ORNAT, Rehovot, Israel), 10 U Rnase Out (Invitrogen, Carlsbad, CA, USA) and 200 U M-MLV (Invitrogen) in a final volume of 20 μl . The reverse transcription (RT) reaction was performed for 1 h at 37°C and stopped for 10 min at 65°C . The volume of 20 μl was subsequently made up to 60 μl with diethyl pyocarbonate (DEPC) (Sigma)-treated water. Negative controls for the RT reaction contained DEPC-treated water instead of RNA. The semi-quantitative RT-PCR was performed by calculating the ratio between the intensity of each band (obtained by densitometry, using TINA 2.0 software) and the intensity of the β -actin band of the same cDNA sample. In brief, 2.5 μl of cDNA were amplified by PCR in a final volume of 25 μl containing $10\times$ PCR buffer, 0.2 mM dNTP mix, 2 mM Mg^{++} , 0.25 U DNA polymerase (BIOLINE, London, UK) and 0.5 μM of the following primers: forward: 5'-gacgagccagagcaagag-3', reverse: 5'-ggcgggactctgctactactc-3' for human β -actin (935 bp); forward: 5'-tctgggcaggtctacttgg-3', reverse: 5'-gaggaaggcctaaggccac-3' for TNF- α (411 bp); forward: 5'-ccccatccttgccagacg-3', reverse: 5'-aagcctctctgatgctct-3' for TNFR1 (358 bp); forward: 5'-aaaagcaccgcctcaaatg-3', reverse: 5'-tgtacaaagtggcaggcca-3' for TNFR2 (468 bp). Negative controls for the PCR contained DEPC-treated water instead of cDNA (cDNA-). The PCR reactions were carried out on a T personal Thermal Cycler (Biometra, Goettingen, Germany). All of the tested factors (cytokines and β -actin) were calibrated using several cDNA concentrations to determine the number of cycles needed for an appropriate amplification. The β -actin cDNA was amplified at 63°C for 30 cycles, the TNF- α was amplified at 59°C for 35 cycles, the TNFR1 was amplified at 64°C for 30 cycles and the TNFR2 was amplified at 64°C for 35 cycles. Twenty microliters of each PCR product were run on 2% agarose gel, containing ethidium bromide, and photographed under UV light. The ratio between the intensity of the transcription band of TNF- α , TNFR1 and TNFR2, respectively, and the intensity of β -actin band of the same cDNA sample was calculated and presented as percentage of β -actin.

Immunohistochemical staining. Immunohistochemical staining of the ovarian tissues was performed as previously described by Rabinovich *et al.* (5). In brief, immunoperoxidase assay was carried

Table I. Expression of tumor necrosis alpha (TNF- α) and its receptors in normal and cancerous ovarian cells and tissues. TNF- α protein levels (pg/ml) were examined in supernatants of cell cultures by ELISA; the range from minimum (mean \pm SD) to maximum (mean \pm SD) is shown. mRNA of TNF- α , TNFR1 and TNFR2, respectively, were examined by semi-quantitative RT-PCR and presented as percentage of β -actin mRNA expression. Immunohistochemical staining for TNFR1 and TNFR2 was performed in normal and cancerous ovarian tissues and localization of the staining is indicated.

	Cell cultures	Homogenates		Tissues
	Protein	mRNA		IHC
	Levels from minimum (mean \pm SD) to maximum (mean \pm SD) (pg/ml)	Ratio between number of positive samples and total number of samples (%)	mRNA expression as percentage of β -actin mRNA expression (mean \pm SD)	Cell origin
TNF-α				
Normal	6.16 \pm 3.2 – 9.95 \pm 5.3	21/22 (95.5)	39.3 \pm 33.1%	ND
Carcinoma	9 \pm 6.6 – 15.9 \pm 4.8	13/15 (86.7)	106.9 \pm 66% (<i>p</i> =0.003)	ND
TNFR1				
Normal	ND	18/22 (81.8)	81.6 \pm 51.6%	EP
Carcinoma	ND	9/15 (60)	85.4 \pm 55.3% (<i>p</i> >0.05)	EP
TNFR2				
Normal	ND	21/22 (95.5)	60 \pm 30.8%	EP+S
Carcinoma	ND	15/15 (100)	103.8 \pm 46.4% (<i>p</i> =0.004)	EP

ELISA, Enzyme-linked immunosorbent assay; EP, epithelium; IHC, immunohistochemistry; ND, not done; RT-PCR, reverse transcription polymerase chain reaction; S, stroma; SD, standard deviation.

out on paraffin-embedded normal or cancerous ovarian sections from archival material of the Department of Pathology, Soroka University Medical Center, using the Vectastain Elite ABC kit (Vector Laboratories, Burlingame, CA, USA). Four micron-thick sections from formalin-fixed, paraffin-embedded tissue blocks were mounted on Super Frost Plus slides, dried at 37°C for 48 h and stored at room temperature. Before the primary antibodies were applied, the slides were deparaffinized in xylene, rehydrated in graded alcohol and warmed twice in 6 M urea for 5 min. Blocking of the non-specific background staining was achieved with PBS containing 2.5% of either goat or rabbit serum. This solution was also used to dilute the primary antibodies. Blocking of the endogenous peroxidase was done with 0.01% H₂O₂ in 80% methanol for 25 min before applying biotinylated antibody and the streptavidin-peroxidase conjugate (Avidin-Biotin Complex) according to the supplier's instructions (Vector Laboratories). Development was carried out with 3,3' diaminobenzidine (DAB) and Mayer's hematoxylin was used for counter-staining. For negative control, we used the blocking solution instead of primary antibodies.

SKOV-3 cell culture. Ovarian carcinoma SKOV-3 cells (ATCC® HTB77™) were cultured in minimum essential medium- α (MEM- α) containing 5% fetal calf serum (FCS), L-glutamine (2 mM) and an antibiotic combination of streptomycin 0.1 mg/ml and penicillin G 100 U/ml (Biological Industries, Beit-Haemek, Israel). The cells were incubated at 37°C in a humidified air atmosphere containing 5% CO₂. The number of cells used in the experiments was optimized to achieve confluent growth at the end of the experimental system.

Primary normal and cancerous ovarian cell culture. All procedures and cell manipulations were carried out under sterile conditions. Primary normal and cancerous ovarian cell lines (cultures) were established as described by Huleihel *et al.* (6). Briefly, ovarian tissue was minced with a scalpel into small pieces and dissociated by stirring with collagenase (0.05% w/v) and hyaluronidase (0.01% w/v) for 2-3 h at 37°C with stirring until complete dissociation. The cell suspension was filtered through sterile gauze and centrifuged at 300 $\times g$ for 10 min. The cells were suspended in growth medium Dulbecco's modified Eagle's medium (DMEM) containing 10% FCS, L-glutamine (2 mM) and antibiotic combination of streptomycin (0.1 mg/ml) and penicillin G (100 U/ml) (Biological Industries) and cultured in 25 cm² flasks at 37°C in a humidified air atmosphere containing 5% CO₂. After 7-10 days, monolayers were formed and the cultures were trypsinized and passed to fresh flasks (first passage). At each passage, cells were cultured in fresh bottles to remove contaminated macrophages. Assays were performed after up to six passages.

Examination of the effect of antibodies ahTNF- α on cell morphology. SKOV-3 cells (10⁵ cells/100 μ l/well) were cultured in MEM- α and primary ovarian carcinoma cells (10⁴ cells/100 μ l/well) were cultured in DMEM in the absence or presence of 5 μ g/ml rabbit ahTNF- α for 24 h of incubation. Morphology of the cells in the microwells was examined by light microscopy at magnification \times 100.

Statistical analysis. Samples were examined in triplicate for each experiment. Each experiment was repeated at least three times unless otherwise stated. Results are expressed as the mean \pm SEM. Student's *t*-test was performed to evaluate the statistical significance of the results. A *p*-value <0.05 was considered significant.

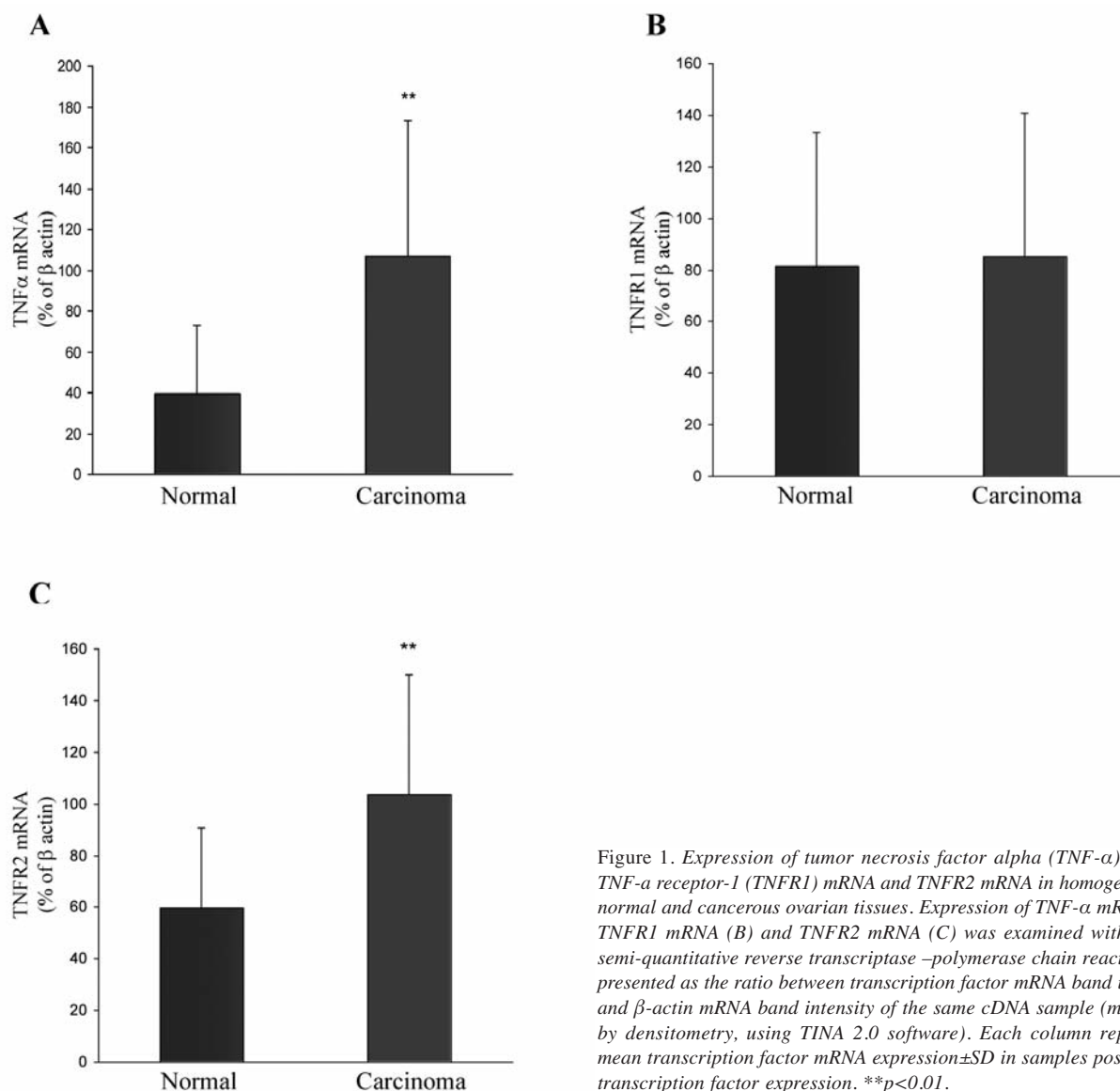


Figure 1. Expression of tumor necrosis factor alpha (*TNF-α*) mRNA, *TNF-α* receptor-1 (*TNFR1*) mRNA and *TNFR2* mRNA in homogenates of normal and cancerous ovarian tissues. Expression of *TNF-α* mRNA (A), *TNFR1* mRNA (B) and *TNFR2* mRNA (C) was examined with use of semi-quantitative reverse transcriptase –polymerase chain reaction and presented as the ratio between transcription factor mRNA band intensity and β -actin mRNA band intensity of the same cDNA sample (measured by densitometry, using TINA 2.0 software). Each column represents mean transcription factor mRNA expression \pm SD in samples positive for transcription factor expression. ** $p < 0.01$.

Results

TNF-α mRNA, *TNFR1* mRNA and *TNFR2* mRNA expression in homogenates of normal and cancerous ovarian tissues. Expression of *TNF-α* mRNA, *TNFR1* mRNA and *TNFR2* mRNA was found in 86.7%, 60% and 100%, respectively, of cancerous ovarian tissues and in 95.5%, 81.8% and 95.5%, respectively, of normal ovarian tissues (Table I).

The ratio between *TNF-α* mRNA expression and β -actin mRNA expression was significantly higher in cancerous ovarian tissues (mean=92.6% \pm 71.7%; range=0%-225.3%) compared to normal ovarian tissues (mean=37.5% \pm 33.6%; range=0%-116.3%) ($p=0.012$). When only samples positive

for *TNF-α* mRNA expression were examined, the ratio between *TNF-α* mRNA expression and β -actin mRNA expression was similarly significantly higher in cancerous ovarian tissues (mean=106.9% \pm 65.9%) compared to normal ovarian tissues (mean=39.3% \pm 33.4%) ($p=0.003$) (Table I and Figure 1A).

The ratio between *TNFR1* mRNA expression and β -actin mRNA expression in cancerous ovarian tissues was similar to that in normal ovarian tissues. When only samples positive for *TNFR1* mRNA were examined, the ratio between *TNFR1* mRNA expression and β -actin mRNA expression in cancerous ovarian tissues (mean=85.4% \pm 55.3%) was still similar to that found in normal ovarian tissues (mean=81.6% \pm 51.6%) (Table I and Figure 1B).

The ratio between *TNFR2* mRNA expression and β -actin mRNA expression was significantly higher in cancerous ovarian tissues (mean=103.8% \pm 46.4%) compared to normal ovarian tissues (mean=57.1% \pm 32.7%) ($p=0.003$). When only samples positive for *TNFR2* mRNA expression were examined, the ratio between *TNFR2* mRNA expression and β -actin mRNA expression was significantly higher in cancerous ovarian tissues (mean=103.8% \pm 46.4%) compared to normal ovarian tissues (mean=59.9% \pm 30.8%) ($p=0.004$) (Table I and Figure 1C).

Immunohistochemical localization of TNFR1 and TNFR2 in normal and cancerous ovarian tissues. Immunohistochemical staining with use of goat anti-human TNFR1 antibody demonstrated that TNFR1 was strongly expressed in the epithelial cell component, and weakly in the stroma, of both normal and cancerous ovarian tissues (Figure 2). Immunohistochemical staining with use of goat anti-human TNFR2 demonstrated that TNFR2 was expressed strongly and equally in the epithelial cell component and in the stroma of normal ovarian tissue, expressed strongly in the epithelial cell component and weakly in the stroma of papillary serous and mucinous carcinomas, and expressed sporadically in the epithelial cell component and weakly in the stroma of endometrioid carcinoma (Figure 2).

Effect of ahTNF- α on SKOV-3 and primary ovarian carcinoma cell morphology. The addition of rabbit ahTNF- α to SKOV-3 and primary ovarian carcinoma cell cultures for 24-96 h of incubation affected cell morphology. The greatest effect of ahTNF- α on ovarian carcinoma cell morphology was achieved, however, after 24 h of incubation (Figure 3). The cancerous cells that were round and arranged in aggregates in cultures without ahTNF- α , became flat, elongated and adherent to the microwell wall in cultures with ahTNF- α (Figure 3). On the other hand, addition of rabbit ahIL-1 β or ahIL-6 to SKOV-3 and primary ovarian carcinoma cell cultures for 24-96 h of incubation did not affect cell morphology (data not presented).

Discussion

In contrast to the vasculotoxic tumor-regressing effect of TNF- α administered therapeutically at extremely high doses, the endogenous chronic autocrine/paracrine secretion of TNF- α acts to promote angiogenesis, tumorigenesis and growth (19, 26, 27). We have shown that normal ovarian cells, EOC cells and SKOV-3 cells secrete basal amounts (pg) of TNF- α protein into culture supernatants. This finding corroborates other studies that demonstrated that many cancer cell lines secrete basal amounts of TNF- α *in vitro*, along with other cytokines and chemokines such as IL-1, IL-6, IL-8, macrophage-colony stimulating factor, monocyte Chemoattractant Protein-1 and the chemokine (C-X-C motif) ligand 12 (10, 25).

In colorectal and breast carcinoma, tumor-infiltrating immune cells were found to be the main source of secreted TNF- α and no TNF- α expression was observed in neoplastic epithelial cells (28-30). In contrast, in a previous study we demonstrated that the neoplastic epithelial cells of EOC, not the tumor-infiltrating immune cells, are the main source of TNF- α and IL-6 (7). In the current study, we observed that *TNF- α* mRNA expression was significantly higher in ovarian carcinoma tissues compared to normal ovarian tissues ($p=0.003$), there was no difference in *TNFR1* mRNA expression between ovarian carcinoma tissues and normal ovarian tissues, and *TNFR2* mRNA expression was significantly higher in cancerous ovarian tissues compared to normal ovarian tissues ($p=0.004$). By immunohistochemical staining, we demonstrated that TNFR1 was mainly localized in the epithelial cells of both normal and cancerous ovarian tissues, whereas TNFR2 was localized in both epithelial cells and stroma of normal ovarian tissues, and confined mainly to the epithelial cells in cancerous ovarian tissues. These results are in agreement with other studies that demonstrated that *TNF- α* mRNA is expressed by EOC cells (15, 31, 32). Szlosarek *et al.* showed that cultured EOC cells expressed up to 1,000 times more *TNF- α* mRNA than cultured normal ovarian surface epithelial cells (15). It has been assumed that TNF- α activity is mainly mediated through TNFR1, while TNFR2 is expressed in the infiltrating immune cells and endothelial cells, and its functions are still unclear, but most probably TNFR2 is involved in promotion of cell proliferation (16, 20, 22). Our failure to demonstrate increased *TNFR1* mRNA expression in cancerous ovarian tissues compared to normal ovarian tissues is in disagreement with Szlosarek *et al.*, who demonstrated TNFR1 expression, but not TNFR2 expression, in EOC cell lines and normal ovarian surface epithelial cells, indicating that TNF- α signals through TNFR1 (15). Our observation that *TNFR2* mRNA expression was significantly higher in ovarian carcinoma tissues compared to normal ovarian tissues and that TNFR2 was localized in the epithelial neoplastic cells rather than in stroma may suggest that autocrine TNF- α regulates ovarian carcinoma tumorigenesis through TNFR2.

Naylor *et al.* found *TNF- α* mRNA expression in the epithelial component of 8 out of 14 (57%) ovarian carcinomas studied (33). Immunohistochemical studies led the authors to the conclusion that the neoplastic epithelial cells of ovarian carcinoma transcribe the *TNF- α* gene (31). In a subsequent study, Naylor *et al.* reported that *TNF- α* gene expression was found in 45 out of 63 (71.4%) ovarian carcinomas studied (34). *TNF- α* mRNA was found in the neoplastic epithelial cells of the tumor and infiltrating macrophages, whereas TNF- α protein localized primarily to a sub-population of macrophages within and in close vicinity to tumor areas. mRNA and TNFR1 protein (p55) were localized to the tumor epithelium, but not to stromal

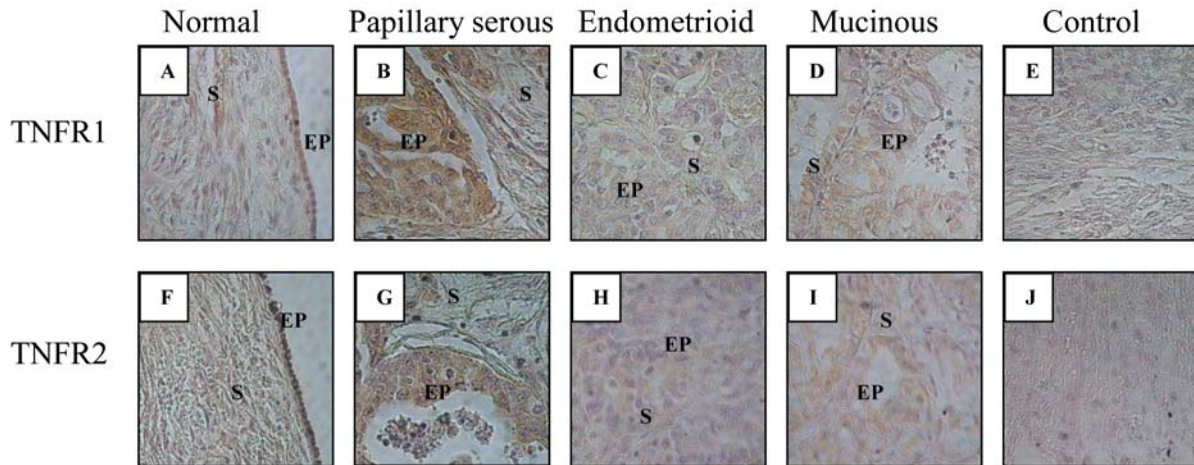


Figure 2. Immunohistochemical staining of normal and cancerous ovarian tissues for tumor necrosis factor alpha receptor-1 (TNFR1) and TNFR2. Formalin-fixed paraffin-embedded normal (A, F) and cancerous (B, C, D, G, H, I) ovarian tissues were immunohistochemically-stained for TNFR1 and TNFR2 with use of goat anti-human TNFR1 and TNFR2 antibody, respectively. A formalin-fixed paraffin-embedded normal ovarian tissue that was not immunohistochemically stained served as control (E, J). TNFR1 was strongly expressed in the epithelial cell component (EP), and weakly in the stroma (S), of both normal (A) and cancerous (B, C, D) ovarian tissues. TNFR2 was strongly expressed in the epithelial cell component (EP) and in the stroma (S) of normal ovarian tissue (F), expressed strongly in the epithelial cell component (EP) and weakly in the stroma (S) of papillary serous (G) and mucinous (I) carcinoma, and expressed sporadically in the epithelial cell component (EP) and weakly in the stroma (S) of edometrioid carcinoma (H). Magnification $\times 400$.

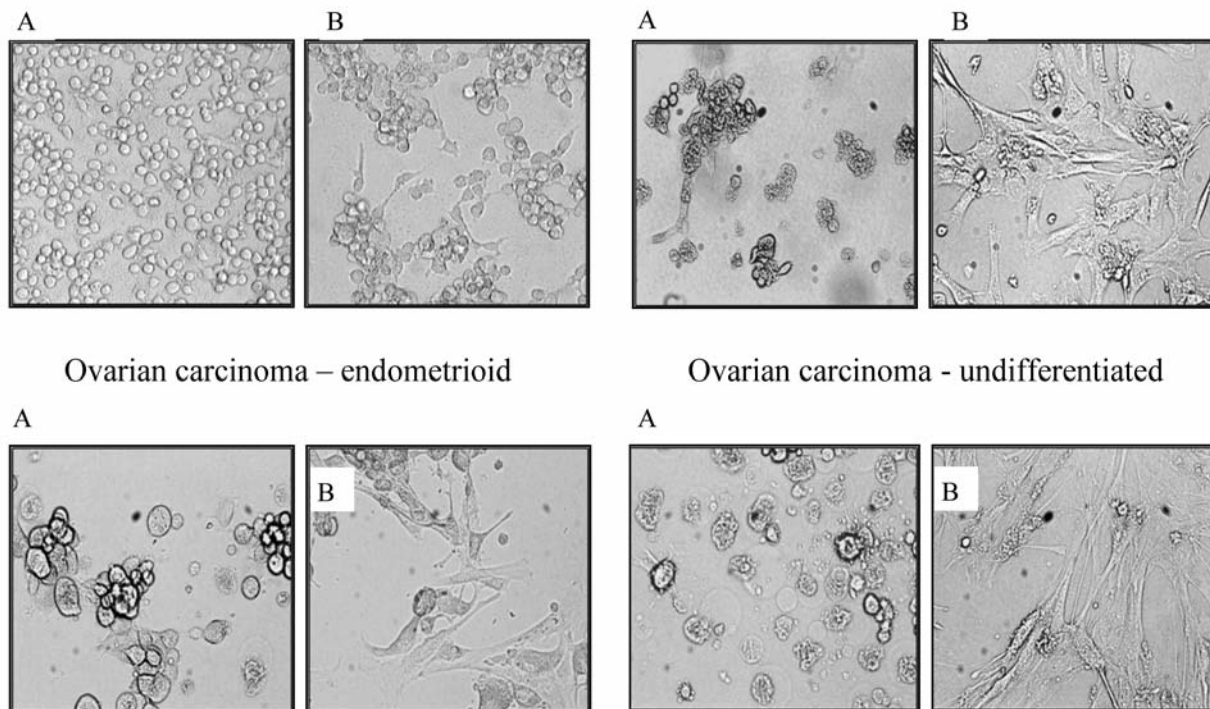


Figure 3. Effect of ahTNF- α on SKOV-3 and primary ovarian carcinoma cell morphology. SKOV-3 cells (10^5 cells/100 μ l/well) were cultured in minimum essential medium-alpha and primary ovarian carcinoma cells (10^4 cells/100 μ l/well) were cultured in Dulbecco's modified Eagle's medium in the absence (control) (A) or presence (B) of rabbit ahTNF- α (5 μ g/ml) for 24 h of incubation. In the control cultures (absence of ahTNF- α), the cells were round and arranged in aggregates (A). In cultures with ahTNF- α , the cells became flat, elongated and adherent to the microwell wall (B). Light microscope; magnification $\times 100$.

macrophages. TNFR2 protein (p75) was confined to infiltrating cells. Cells expressing mRNA were also found in ovarian carcinoma ascites and TNF- α protein was detected in some ascitic fluids. It has been concluded that the co-expression of TNF- α and its receptors in ovarian carcinoma suggests the capacity for autocrine/paracrine action and that TNF- α antagonists may have therapeutic potential in ovarian carcinoma (34).

We observed that neutralization of TNF- α by either thalidomide or ahTNF- α did not affect cell proliferation rate in SKOV-3 cell and primary ovarian carcinoma cell cultures (35). It is suggested that the proliferation rate of ovarian carcinoma cells is influenced by various factors (*e.g.* cytokines TNF- α , IL-6, IL-1, and other growth factors) and neutralization of one of these cytokines is compensated by the action of other cytokines and growth factors present. In the present study, we have demonstrated that knocking down TNF- α with ahTNF- α in SKOV-3 cell and primary ovarian carcinoma cell cultures caused considerable changes in cell morphology. The neoplastic epithelial cells that originally were round and arranged in aggregates became flat, elongated and adherent to the microwell wall. This effect was specific for TNF- α but not to other cytokines (IL-1 β and IL-6) (data not presented). It is thus suggested that TNF- α has a decisive role in developing and maintaining cancer cell morphology that enables the cells to disengage, mobilize, spread and form metastatic implants. This effect should not be related to apoptosis since we did not find any effect of ahTNF- α on ovarian carcinoma cell proliferation rate.

We also observed that thalidomide selectively inhibits TNF- α and MMP secretion, but not IL-6 secretion, in SKOV-3 and primary ovarian carcinoma cells and that neutralization of TNF- α by ahTNF- α reduces the capacity of the cells to secrete MMPs and tends to increase the capacity of the cells to secrete IL-6 (35). It is suggested that the autocrine/paracrine secretion of TNF- α by ovarian carcinoma cells stimulates a constitutive network of other cytokines (mainly IL-6), angiogenic factors, MMPs, and chemokines that may act in an autocrine/paracrine manner to promote ovarian carcinoma tumorigenesis. The production of IL-6 and MMPs does not depend solely on TNF- α , and other cytokines may compensate for the decrease in TNF- α level.

In conclusion, we have demonstrated that *TNF- α* mRNA and *TNFR2* mRNA levels were significantly higher in ovarian carcinoma tissues than in normal ovarian tissues, whereas *TNFR1* mRNA levels did not differ between these tissues. TNFR1 and TNFR2 were localized mainly in the epithelial neoplastic cells of the tumor. Knocking down TNF- α activity with ahTNF- α altered ovarian carcinoma cell morphology. Based on our previous studies (4-7) and on this study, we suggest that TNF- α and its receptors (mainly TNFR2) may be implicated in ovarian carcinoma tumorigenesis through three main mechanisms of action by: i) Affecting the

activity/behavior of ovarian carcinoma cells mainly through TNFR2; ii) Affecting cell morphology. This may enable the neoplastic cells to disengage, mobilize and spread; iii) Regulation of a constitutive network of other cytokines (IL-6), angiogenic factors and MMPs that may act in an autocrine/paracrine manner to promote ovarian carcinoma tumorigenesis. Our results indicate that TNFR2 may have a major role in the pathogenesis of ovarian carcinoma. This study, which suggests a different mechanism for the possible involvement of TNF- α in the regulation of ovarian carcinoma pathogenesis, may have important implications for the design and use of new therapeutic strategies.

Acknowledgements

This study was supported by the Israel Cancer Association.

References

- 1 Siegel R, Naishadham D and Jemal A: Cancer statistics, 2012. *CA Cancer J Clin* 62: 10-29, 2012.
- 2 Jemal A, Bray F, Center MM, Ferlay J, Ward E and Forman D: Global cancer statistics. *CA Cancer J Clin* 61: 69-90, 2011.
- 3 Lowe KA, Chia VM, Taylor A, O'Malley C, Kelsh M, Mohamed M, Mowat FS and Goff B: An international assessment of ovarian cancer incidence and mortality. *Gynecol Oncol* 130: 107-114, 2013.
- 4 Rabinovich A, Medina L, Piura B, Segal S and Huleihel M: Regulation of ovarian carcinoma SKOV-3 cell proliferation and secretion of MMPs by autocrine IL-6. *Anticancer Res* 27: 267-272, 2007.
- 5 Rabinovich A, Medina L, Piura B and Huleihel M: Expression of IL-10 in human normal and cancerous ovarian tissues and cells. *Eur Cytokine Netw* 21: 122-128, 2010.
- 6 Huleihel M, Maymon E, Piura B, Prinsloo I, Benharroch D, Yanai-Inbar I and Glezerman M: Distinct patterns of expression of interleukin-1 alpha and beta by normal and cancerous human ovarian tissues. *Eur Cytokine Netw* 8: 179-187, 1997.
- 7 Glezerman M, Mazot M, Maymon E, Piura B, Prinsloo I, Benharroch D, Yanai-Inbar I and Huleihel M: Tumor necrosis factor-alpha and interleukin-6 are differentially expressed by fresh human cancerous ovarian tissue and primary cell lines. *Eur Cytokine Netw* 9: 171-179, 1998.
- 8 Anderson GM, Nakada MT and DeWitte M: Tumor necrosis factor-alpha in the pathogenesis and treatment of cancer. *Curr Opin Pharmacol* 4: 314-320, 2004.
- 9 Balkwill F: Tumour necrosis factor and cancer. *Nat Rev Cancer* 9: 361-371, 2009.
- 10 Balkwill F: TNF-alpha in promotion and progression of cancer. *Cancer Metastasis Rev* 25: 409-416, 2006.
- 11 Idriss HT and Naismith JH: TNF alpha and the TNF receptor superfamily: structure-function relationship(s). *Microsc Res Tech* 50: 184-195, 2000.
- 12 Charles KA, Kulbe H, Soper R, Escorcio-Correia M, Lawrence T, Schultheis A, Chakravarty P, Thompson RG, Kollias G, Smyth JF, Balkwill FR and Hagemann T: The tumor-promoting actions of TNF-alpha involve TNFR1 and IL-17 in ovarian cancer in mice and humans. *J Clin Invest* 119: 3011-3023, 2009.

- 13 Kulbe H, Thompson R, Wilson JL, Robinson S, Hagemann T, Fatah R, Gould D, Ayhan A and Balkwill F: The inflammatory cytokine tumor necrosis factor- α generates an autocrine tumor-promoting network in epithelial ovarian cancer cells. *Cancer Res* 67: 585-592, 2007.
- 14 Szlosarek P, Charles KA and Balkwill FR: Tumour necrosis factor- α as a tumour promoter. *Eur J Cancer* 42: 745-750, 2006.
- 15 Szlosarek PW, Grimshaw MJ, Kulbe H, Wilson JL, Wilbanks GD, Burke F and Balkwill FR: Expression and regulation of tumor necrosis factor α in normal and malignant ovarian epithelium. *Mol Cancer Ther* 5: 382-390, 2006.
- 16 Szlosarek PW and Balkwill FR: Tumour necrosis factor α : A potential target for the therapy of solid tumours. *Lancet Oncol* 4: 565-573, 2003.
- 17 Chen G and Goeddel DV: TNF-R1 signaling: A beautiful pathway. *Science* 296: 1634-1635, 2002.
- 18 Gaur U and Aggarwal BB: Regulation of proliferation, survival and apoptosis by members of the TNF superfamily. *Biochem Pharmacol* 66: 1403-1408, 2003.
- 19 Balkwill F: Tumor necrosis factor or tumor-promoting factor? *Cytokine Growth Factor Rev* 13: 135-141, 2002.
- 20 Mocellin S, Rossi CR, Pilati P and Nitti D: Tumor necrosis factor, cancer and anticancer therapy. *Cytokine Growth Factor Rev* 16: 35-53, 2005.
- 21 Shibata H, Abe Y, Yoshioka Y, Nomura T, Sato M, Kayamuro H, Kawara T, Arita S, Furuya T, Nagano K, Yoshikawa T, Kamada H, Tsunoda SI and Tsutsumi Y: Generation of mouse macrophages expressing membrane-bound TNF variants with selectivity for TNFR1 or TNFR2. *Cytokine* 50: 75-83, 2010.
- 22 Al-Lamki RS, Wang J, Vandenabeele P, Bradley JA, Thiru S, Luo D, Min W, Pober JS and Bradley JR: TNFR1- and TNFR2-mediated signaling pathways in human kidney are cell type-specific and differentially contribute to renal injury. *FASEB J* 19: 1637-1645, 2005.
- 23 Mukai Y, Shibata H, Nakamura T, Yoshioka Y, Abe Y, Nomura T, Taniai M, Ohta T, Ikemizu S, Nakagawa S, Tsunoda S, Kamada H, Yamagata Y and Tsutsumi Y: Structure-function relationship of tumor necrosis factor (TNF) and its receptor interaction based on 3D structural analysis of a fully active TNFR1-selective TNF mutant. *J Mol Biol* 385: 1221-1229, 2009.
- 24 Micheau O and Tschopp J: Induction of TNF receptor I-mediated apoptosis *via* two sequential signaling complexes. *Cell* 114: 181-190, 2003.
- 25 Kulbe H, Chakravarty P, Leinster DA, Charles KA, Kwong J, Thompson RG, Coward JI, Schioppa T, Robinson SC, Gallagher WM, Galletta L; Australian Ovarian Cancer Study Group, Salako MA, Smyth JF, Hagemann T, Brennan DJ, Bowtell DD and Balkwill FR: A dynamic inflammatory cytokine network in the human ovarian cancer microenvironment. *Cancer Res* 72: 66-75, 2012.
- 26 Fiers W: Tumor necrosis factor: characterisation at the molecular, cellular and *in vivo* level. *FEBS Lett* 285: 199-212, 1991.
- 27 Balkwill F and Joffroy C: TNF: A tumor-suppressing factor or a tumor-promoting factor? *Future Oncol* 6: 1833-1836, 2010.
- 28 Naylor MS, Stamp GWH and Balkwill FR: Investigation of cytokine gene expression in human colorectal cancer. *Cancer Res* 50: 4436-4440, 1990.
- 29 Beissert S, Bergholz M, Waase I, Lepsien G, Schauer A, Pfizenmaier K and Krönke M: Regulation of tumor necrosis factor gene expression in colorectal adenocarcinoma: *in vivo* analysis by *in situ* hybridization. *Proc Natl Acad Sci USA* 86: 5064-5068, 1989.
- 30 Miles DW, Happerfield LC, Naylor MS, Bobrow LG, Rubens RD and Balkwill FR: Expression of tumour necrosis factor (TNF α) and its receptors in benign and malignant breast tissue. *Int J Cancer* 56: 777-782, 1994.
- 31 Takeyama H, Wakamiya N, O'Hara C, Arthur K, Niloff J, Kufe D, Sakurai K and Spriggs D: Tumor necrosis factor expression by human ovarian carcinoma *in vivo*. *Cancer Res* 51: 4476-4480, 1991.
- 32 Wu S, Boyer CM, Whitaker RS, Berchuck A, Wiener JR, Weinberg JB and Bast RC Jr: Tumor necrosis factor α as an autocrine and paracrine growth factor for ovarian cancer: Monokine induction of tumor cell proliferation and tumor necrosis factor α expression. *Cancer Res* 53: 1939-1944, 1993.
- 33 Naylor MS, Malik ST, Stamp GW, Jobling T and Balkwill FR: *In situ* detection of tumour necrosis factor in human ovarian cancer specimens. *Eur J Cancer* 26: 1027-1030, 1990.
- 34 Naylor MS, Stamp GW, Foulkes WD, Eccles D and Balkwill FR: Tumor necrosis factor and its receptors in human ovarian cancer. Potential role in disease progression. *J Clin Invest* 91: 2194-2206, 1993.
- 35 Piura B, Medina L, Rabinovich A, Dyomin V and Huleihel M: Thalidomide distinctly affected TNF- α , IL-6 and MMP secretion by ovarian cancer cell line (SKOV-3) and primary ovarian cancer cells. *Eur Cytokine Netw* 24: 122-129, 2013.

Received November 27, 2013

Revised December 30, 2013

Accepted January 3, 2014