

Survival of a Patient with Anaplastic Thyroid Cancer Following Intensity-modulated Radiotherapy and Sunitinib - A Case Report

JONATHAN D. SCHOENFELD^{1,2}, OROFE O. ODEJIDE^{3,4}, LORI J. WIRTH⁴ and ANNIE W. CHAN²

¹Harvard Radiation Oncology Program, Boston, MA, U.S.A.;
Departments of ²Radiation Oncology and ⁴Medical Oncology, Massachusetts
General Hospital, Harvard Medical School, Boston, MA, U.S.A.;

³Dana-Farber/Partners CancerCare Hematology/Oncology Fellowship Program, Boston, MA, U.S.A.

Abstract. *Background: Anaplastic thyroid cancer has a very poor prognosis, especially in patients who have gross residual disease following resection. Case Report: We present the case of a patient with anaplastic thyroid cancer and a significant gross residual disease treated with intensity-modulated radiotherapy with concurrent chemotherapy and sunitinib who had a complete response and remains without evidence of disease more than 18 months after diagnosis. Conclusion: Chemoradiotherapy has an important role in the adjuvant treatment of anaplastic thyroid cancer in selected patients and should be considered when gross residual disease is present following resection. The combined use of radiotherapy and targeted biological agents such as sunitinib may warrant further investigation.*

Anaplastic thyroid cancer has a very poor prognosis, with a median survival ranging from weeks to months and few long-term survivors (1-3). Prognostic factors previously reported include age, performance status, metastasis, tumor size, leukocytosis and extrathyroid extension (1, 4, 5). However, even patients with more favorable prognostic factors, such as localized disease, generally succumb to their disease within a year of diagnosis (6). The subset of patients with gross residual disease following resection do even worse, with a median survival of less than 6 months (5) and almost no long-term survivors (4). Unfortunately, this characterizes the majority of patients with localized disease (3).

Correspondence to: Jonathan D. Schoenfeld, MD, M.Phil., Department of Radiation Oncology, Massachusetts General Hospital, Cox Building, 3rd Floor, 100 Blossom St., Boston, Massachusetts 02114, U.S.A. Tel: +1 6177267559, Fax: +1 6177263603, e-mail: jdschoenfeld@partners.org

Key Words: Anaplastic thyroid carcinoma, chemoradiation, intensity-modulated radiation therapy (IMRT), sunitinib, case report.

Adjuvant therapies employed in the treatment of anaplastic thyroid malignancies have provided only limited benefit. Retrospective analyses suggest a small survival improvement associated with adjuvant radiation in selected patients (6-8). Taxanes, including paclitaxel and docetaxel, have shown modest activity in several trials (9, 10). A randomized trial of doxorubicin *versus* doxorubicin plus cisplatin achieved three complete and three partial responses in (18) patients with anaplastic thyroid cancer who received combination therapy (11). Combination therapy offered no statistically significant overall survival benefit, although two patients who achieved complete response remained disease free for more than two years. Although adjuvant therapy may have a limited impact on survival, treatment is also frequently considered to prevent progressive locoregional disease and its consequential impact on swallowing and the upper airway.

Given the limited benefit of chemotherapy, there is an emerging focus on the role of targeted biological agents in anaplastic thyroid cancer management. Anti-angiogenic and vascular-disrupting agents have shown some promise in pre-clinical models (1, 3), although clinical trials have produced mixed results (3). Preliminary results of a study evaluating the anti-angiogenic tyrosine kinase inhibitor sorafenib in patients who progressed on cytotoxic chemotherapy produced a median survival of 3.5 months (12), and a phase II multi-center French study exploring the use of sunitinib in patients with locally advanced or metastatic anaplastic, differentiated or medullary thyroid cancer is on-going (13). Another phase II study evaluating fosbretabulin, a vascular-disrupting agent, demonstrated a median survival of 4.7 months, although fosbretabulin failed to produce evidence of an objective disease response (14).

Combined modality therapy and chemoradiation have also been utilized with mixed results (3). De Crovoisier *et al.* reported a median survival of 10 months for patients treated with hyperfractionated accelerated radiotherapy intermixed between six cycles of chemotherapy with

doxorubicin and cisplatin (15). A retrospective analysis of 75 patients treated in the Netherlands with weekly doxorubicin concurrent with 50.6 Gy of hyperfractionated radiation followed by prophylactic lung radiation and adjuvant doxorubicin revealed a median survival of only 2.9 months, although 40% of patients had metastatic disease (16). In contrast, various retrospective series reported improved outcomes in patients treated with a multimodality approach (4, 7, 17), although it is difficult to exclude the effect of selection bias in these studies.

Although previous studies investigated a variety of treatments for anaplastic thyroid cancer patients, the use of adjuvant chemoradiotherapy along with biological therapies remains relatively unexplored. In this report, we describe a complete response followed by a prolonged disease-free survival, achieved in a patient with anaplastic thyroid cancer, treated with an aggressive multimodal treatment regimen consisting of chemoradiotherapy and sunitinib following limited surgical resection.

Case Report

An otherwise healthy 49-year-old woman with a history of recurrent papillary thyroid carcinoma presented with progressive bilateral neck pain and fullness. She had been initially diagnosed with papillary thyroid cancer 10 years prior, for which she underwent total thyroidectomy followed by treatment with 150 mCi of radioiodine. Seven years later, a lymph node recurrence in the right neck had been treated with a selective neck dissection followed by 106 mCi of radioiodine. One year after that treatment, a second lymph node recurrence of papillary cancer in the left neck had been removed using an ultrasound-directed limited neck dissection.

At the time of the current presentation, ultrasound of the neck revealed bilateral lymphadenopathy, with multiple enlarged, cystic-appearing lymph nodes. Fine-needle aspiration was consistent with anaplastic transformation. Computed tomography (CT) of the neck and chest did not reveal any evidence of distant metastatic disease; however, multiple mass lesions with central hypoattenuation extended down the jugular chain and into the superior mediastinum (Figure 1A). Lesions in the paratracheal region were noted to exert significant mass effect upon the trachea, although the patient did not report any respiratory symptoms.

A bilateral neck dissection was attempted, revealing a large conglomerate mass posterolateral to the internal jugular vein on the left that was incompletely excised. In the right neck, a mass involving the vertebral artery and the roots of the brachial plexus was also incompletely excised. The pathology of both lesions was consistent with poorly differentiated anaplastic carcinoma with extranodal extension with no residual well-differentiated component.

Following surgery, positron-emission tomography (PET)-CT demonstrated a significant volume of residual disease bilaterally (Figure 1B). After extensive discussion with the patient and her family about treatment options ranging from palliative approaches to multimodal therapy, the patient decided to pursue an aggressive, albeit unproven, regimen including chemotherapy, radiation and sunitinib. The potential risks of this treatment approach were explained to the patient in detail.

Chemotherapy with paclitaxel and sunitinib (37.5 mg daily) was started approximately three weeks following surgery; however, an allergic reaction to paclitaxel led to its substitution with docetaxel (20 mg/m² weekly). A radiation planning CT was performed in the supine position using an S-frame and thermoplastic mask to secure the shoulders in addition to the head and neck, using high-resolution (2.5 mm) slices. The residual gross tumor volume (GTV) was defined with the aid of the postoperative PET-CT and a clinical target volume (CTV) was designed to encompass the lymph node regions at risk in the neck and superior mediastinum. An expansion of 3 mm was used for both the GTV and CTV to arrive at final planning treatment volumes (PTV).

Intensity-modulated radiotherapy (IMRT) planning was performed with the CORVUS software (Best nomos, Pittsburgh, PA, USA). Two treatment plans were designed to initially treat the areas of GTV and CTV to 60 Gy and then deliver a 10 Gy boost to the GTV for a final cumulative dose of 70 Gy to all GTVs (Figure 1C). All treatments were administered in 200 cGy daily fractions with a 6-MV photon beam.

The patient began concurrent radiotherapy approximately five weeks following surgery. She completed the treatment as planned, with a one-day break towards the end of treatment for nausea and dehydration. A percutaneous gastrostomy tube was placed during treatment for worsening dysphagia and in order to address concerns regarding poor oral intake. The patient also experienced expected grade 3 skin toxicity with moist desquamation within the treated field.

After radiotherapy, the patient continued on maintenance sunitinib (37.5 mg daily for four weeks, followed by two weeks off). CT performed approximately six weeks after radiotherapy revealed a decrease in the size of the patient's neck masses and subsequent scans revealed a continued response. PET-CT performed approximately one year following the completion of chemoradiation revealed no evidence of abnormal (FDG) uptake and only minimal residual soft tissue along the right tracheoesophageal angle, consistent with post-treatment change (Figure 1D). Scattered non-FDG-avid subcentimeter pulmonary and hepatic nodules were stable, with no clear evidence of metastatic disease. The patient also has not had any clinical evidence of disease recurrence, now, more than 18 months after her diagnosis, although she continues to experience the

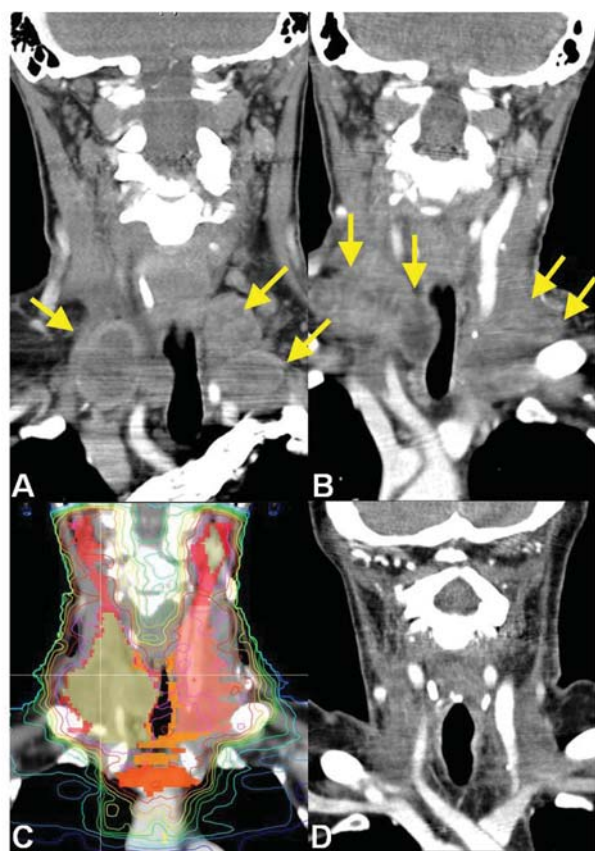


Figure 1. A: Coronal reconstruction of computed tomography (CT) performed before treatment demonstrated multiple lesions (arrows) extending from the neck to the superior mediastinum. B: Significant residual disease remained after surgical resection (arrows), exerting a mass effect upon the trachea. C: Representative coronal view of the patient's composite radiation treatment plan. Gross tumor volume (GTV) is shaded dark yellow and the clinical target volume (CTV) is shown in red/pink/orange. Representative isodose lines are also shown (pink, 100% of prescription to GTV; red, 90%; orange, 80%; yellow, 70%; green, 60-40%; blue, 30-10%). D: Approximately one year following chemoradiation, there was no evidence of residual disease on CT.

expected long-term sequelae of combined modality therapy, including fatigue, hand-foot syndrome, and neck fibrosis. She is able to tolerate an oral diet, supplemented by gastrostomy tube feeding. She has not required a tracheotomy.

Discussion

Because of the extremely poor outcomes associated with anaplastic thyroid cancer, the specific type of cancer accounts for more than a quarter of all thyroid-related cancer deaths despite only accounting for 2% of thyroid malignancies (2). Anaplastic transformation of the well-differentiated thyroid malignancy is potentially an important part of the development of this type of cancer in many cases (18), as it appeared to be

in our patient; however, she had no residual well-differentiated disease identified at the time of surgical resection. The lack of well-differentiated foci within anaplastic disease has been reported to portend a worse outcome (19). In addition to these unfavorable histological findings, our patient had a number of other adverse prognostic features, the most notable of which was a substantial amount of residual disease remaining after surgical resection.

Therefore, we elected to offer the possibility of adding a targeted biological agent, sunitinib, to a treatment regimen including chemoradiation, and administered this agent both during and after radiotherapy. Although evidence supporting the use of sunitinib for anaplastic thyroid cancer is sparse, it has been explored for a variety of thyroid cancers (13, 20). The possibility of combining this agent concurrently with radiation has also been explored in the setting of hypofractionated radiotherapy for metastatic renal cell carcinoma (21, 22). Administering anti-angiogenic therapy such as sunitinib concurrently with IMRT could potentially normalize the tumor vasculature and enhance the efficacy of radiotherapy (23, 24).

The poor prognosis associated with anaplastic thyroid cancer can make adjuvant treatment decisions difficult, especially those regarding the use of multimodal therapy. This case is illustrative of the potential benefits of a combined approach. In addition to offering symptomatic relief, comprehensive chemoradiation eventually eradicated bulky residual disease and provided a substantial disease-free interval that is ongoing.

Conclusion

We report on prolonged survival in a patient with significant residual anaplastic thyroid carcinoma in the neck following surgery who was treated with chemoradiation with docetaxel along with concurrent and maintenance sunitinib. This outcome is in stark contrast to the poor outcomes expected for patients with anaplastic thyroid cancer, which highlights the need for innovative approaches in the treatment of this disease. In particular, the role of concurrent IMRT and sunitinib in the treatment of non-metastatic anaplastic thyroid cancer warrants further investigation.

Conflict of Interest

None.

References

- 1 Are C and Shaha A: Anaplastic thyroid carcinoma: biology, pathogenesis, prognostic factors, and treatment approaches. *Ann Surg Oncol* 13(4): 453-464, 2006.
- 2 Green LD, Mack L and Pasiaka JL: Anaplastic thyroid cancer and primary thyroid lymphoma: a review of these rare thyroid malignancies. *J Surg Oncol* 94(8): 725-736, 2006.

- 3 Smallridge RC and Copland JA: Anaplastic Thyroid Carcinoma: Pathogenesis and Emerging Therapies. *Clin Oncol* 22(6): 486-497, 2010.
- 4 Akaishi J, Sugino K, Kitagawa W, Nagahama M, Kameyama K, Shimizu K, Ito K and Ito K: Prognostic Factors and Treatment Outcomes of 100 Cases of Anaplastic Thyroid Carcinoma. *Thyroid* 21(11): 1183-1189, 2011.
- 5 Basic N, Hocevar M, Zgajnar J, Pogacnik A, Grazio-Frkovic S and Auersperg M: Prognostic factors in anaplastic carcinoma of the thyroid—a multivariate survival analysis of 188 patients. *Langenbecks Arch Surg* 390(3): 203-208, 2005.
- 6 Chen J, Tward JD, Shrieve DC and Hitchcock YJ: Surgery and radiotherapy improves survival in patients with anaplastic thyroid carcinoma: analysis of the surveillance, epidemiology, and end results 1983-2002. *Am J Clin Oncol* 31(5): 460-464, 2008.
- 7 Kebebew E, Greenspan FS, Clark OH, Woerber KA and McMillan A: Anaplastic thyroid carcinoma. Treatment outcome and prognostic factors. *Cancer* 103(7): 1330-1335, 2005.
- 8 Yau T, Lo CY, Epstein RJ, Lam AKY, Wan KY and Lang BH: Treatment outcomes in anaplastic thyroid carcinoma: survival improvement in young patients with localized disease treated by combination of surgery and radiotherapy. *Ann Surg Oncol* 15(9): 2500-2505, 2008.
- 9 Ain KB, Egorin MJ and DeSimone PA: Treatment of anaplastic thyroid carcinoma with paclitaxel: phase 2 trial using 96-hour infusion. Collaborative Anaplastic Thyroid Cancer Health Intervention Trials (CATCHIT) Group. *Thyroid* 10(7): 587-594, 2000.
- 10 Troch M, Koperek O, Scheuba C, Dieckmann K, Hoffmann M, Niederle B and Raderer M: High efficacy of concomitant treatment of undifferentiated (anaplastic) thyroid cancer with radiation and docetaxel. *J Clin Endocrinol Metab* 95(9): E54-57, 2010.
- 11 Shimaoka K, Schoenfeld DA, DeWys WD, Creech RH and DeConti R: A randomized trial of doxorubicin *versus* doxorubicin plus cisplatin in patients with advanced thyroid carcinoma. *Cancer* 56(9): 2155-2160, 1985.
- 12 Nagaiah G, Fu P and Wasman JK: Phase II trial of sorafenib (bay 43-9006) in patients with advanced anaplastic carcinoma of the thyroid (ATC). *J Clin Oncol* 27(15S): 605 suppl., 2009.
- 13 Ravaud A, de la Fouchardiere C and Courbon F: Sunitinib in patients with refractory advanced thyroid cancer: The THYSU Phase II trial. *J Clin Oncol* 26: 6058 suppl., 2008.
- 14 Mooney CJ, Nagaiah G, Fu P, Wasman JK, Cooney MM, Savvides PS, Bokar JA, Dowlati A, Wang D, Agarwala SS, Flick SM, Hartman PH, Ortiz JD, Lavertu PN and Remick SC: A phase II trial of fosbretabulin in advanced anaplastic thyroid carcinoma and correlation of baseline serum-soluble intracellular adhesion molecule-1 with outcome. *Thyroid* 19(3): 233-240, 2009.
- 15 De Crevoisier R, Baudin E, Bachelot A, Leboulleux S, Travagli JP, Caillou B and Schlumberger M: Combined treatment of anaplastic thyroid carcinoma with surgery, chemotherapy, and hyperfractionated accelerated external radiotherapy. *Int J Radiat Oncol Biol Phys* 60(4): 1137-1143, 2004.
- 16 Swaak-Kragten AT, de Wilt JHW, Schmitz PIM, Bontenbal M and Levendag PC: Multimodality treatment for anaplastic thyroid carcinoma – treatment outcome in 75 patients. *Radiother Oncol* 92(1): 100-104, 2009.
- 17 Foote RL, Molina JR, Kasperbauer JL, Lloyd RV, McIver B, Morris JC, Grant CS, Thompson GB, Richards ML, Hay ID, Smallridge RC and Bible KC: Enhanced survival in locoregionally confined anaplastic thyroid carcinoma: a single-institution experience using aggressive multimodal therapy. *Thyroid* 21(1): 25-30, 2011.
- 18 Wiseman SM, Loree TR, Wesley L, Hicks EL, Rigual NR, Winston JS, Tan D, Anderson GR and Stoler DL: Anaplastic thyroid cancer evolved from papillary carcinoma. *Arch Otolaryngol Head Neck Surg* 129(1): 96-100, 2003.
- 19 Patel KN and Shaha AR: Poorly differentiated and anaplastic thyroid cancer. *Cancer Control* 13(2): 119-128, 2006.
- 20 Carr LL, Mankoff DA, Goulart BH, Eaton KD, Capell PT, Kell EM, Bauman JE and Martins RG: Phase II study of daily sunitinib in FDG-PET-positive, iodine refractory, differentiated thyroid cancer and metastatic medullary carcinoma of thyroid with functional imaging correlation. *Clin Cancer Res* 16(21): 5260-5268, 2010.
- 21 Staehler M, Haseke N, Nuhn P, Tullmann C, Karl A, Siebels M, Stief CG, Wowra B and Muacevic A: Simultaneous anti-angiogenic therapy and single-fraction radiosurgery in clinically relevant metastases from renal cell carcinoma. *BJU Int* 108(5): 673-678, 2010.
- 22 Staehler M, Haseke N, Stadler T, Nuhn P, Roosen A, Stief CG and Wilkowski R: Feasibility and effects of high-dose hypofractionated radiation therapy and simultaneous multi-kinase inhibition with sunitinib in progressive metastatic renal cell cancer. *Urol Oncol* published online, 2010.
- 23 Lin MI and Sessa WC: Antiangiogenic therapy: creating a unique window of opportunity. *Cancer Cell* 6(6): 529-531, 2004.
- 24 Winkler F, Kozin SV, Tong RT, Chae SS, Booth MF, Garkavtsev I, Xu L, Hicklin DJ, Fukumura D, di Tomaso E, Munn LL and Jain RK: Kinetics of vascular normalization by VEGFR2 blockade governs brain tumor response to radiation: role of oxygenation, angiopoietin-1, and matrix metalloproteinases. *Cancer Cell* 6(6): 553-563, 2004.

Received February 28, 2012

Revised April 2, 2012

Accepted April 3, 2012