

Treatment Evaluation of Metastatic Lymph Nodes after Concurrent Chemoradiotherapy in Patients with Head and Neck Squamous Cell Carcinoma

GOSHI NISHIMURA, HIDEKI MATSUDA, TAKAHIDE TAGUCHI, MASAHIRO TAKAHASHI, MASANORI KOMATSU, DAISUKE SANO, NAOKO SAKUMA, YASUHIRO ARAI and HIDEAKI TAKAHASHI

*Department of Otorhinolaryngology, Head and Neck Surgery,
Yokohama City University School of Medicine, Yokohama, Japan*

Abstract. *Background:* Concurrent chemoradiotherapy (CCRT) is used to treat advanced head and neck cancer. The accuracy of evaluating lymph nodes metastases following CCRT is important for subsequent therapy. *Patients and Methods:* Patients were divided into two groups, the complete response (CR) and the non-CR groups, as determined by imaging and fine-needle aspiration cytology (FNAC) performed 4-8 weeks after the CCRT, and the findings were compared with the clinical characteristics. *Results:* The sensitivity and the specificity of each evaluation method were as follows: 52.9% and 74.2%, respectively, for computer tomography (CT) and magnetic resonance imaging (MRI); 88.2% and 66.1% for ultrasonography (US); 35.3% and 96.0% for fluorodeoxyglucose-positron emission tomography (FDG-PET) or PET-CT; and 71.4% and 95.6% for FNAC. *Conclusion:* To evaluate the response of lymph node(s) treated by CCRT, US is useful as a positive screening tool and FDG-PET and PET-CT as negative screening tools. FNAC is useful in evaluating suspicious lymph nodes in both positive and negative cases.

Histopathologically, most head and neck carcinomas are of the squamous cell type. The definitive treatment method for locoregionally advanced head and neck squamous cell carcinoma (HNSCC) is radiotherapy with/without surgical resection. Because of the anatomical structures in the head and neck, organ preservation is important to maintain function and to minimize aesthetic changes. Recently, concurrent chemoradiotherapy (CCRT) and neo-adjuvant (induction)

chemotherapy followed by definitive radiotherapy for patients with advanced HNSCC have been shown to be effective in preserving function (1-11). The HNSCC stage classification is based on the tumor, node, metastasis (TNM) system. Patients categorized as having disease of advanced T, as well as those termed early T but with positive lymph node(s), are defined as having advanced stage disease. A planned neck dissection (PND) after CCRT is a treatment strategy for advanced HNSCC. However, with improved chemotherapy regimens and radiotherapy accuracy, such as with the use of intensity-modulated radiation therapy (IMRT), as well as advanced diagnostic imaging systems, such as fluorodeoxyglucose-positron emission computer tomography (PET-CT), the treatment outcome and the evaluation accuracy of metastatic lymph nodes has improved. Therefore, the use of early period salvage neck dissection vs. PND has increased. In order to help predict the potential value of neck dissection following CCRT, we compared the precision of the evaluation methods, including computer tomography (CT) and/or magnetic resonance imaging (MRI), ultrasonography (US), fluorodeoxyglucose-positron emission tomography (FDG-PET) or PET-CT, and fine-needle aspiration cytology (FNAC), with clinical and pathological findings.

Patients and Methods

Study design. This was a retrospective study. The Institutional Review Board's approval was obtained prior to data collection.

Patients. Since January 2002, FDG-PET or PET-CT has been performed for head and neck carcinoma patients at our institute. Eligibility criteria included the following: written informed consent of the patient; presence of untreated lymph node-positive HNSCC, N classification as determined by the 2009 staging system of the Union for International Cancer Control (UICC) 7th edition; contrast-enhanced CT or Gd-enhanced MRI, US, and FDG-PET or PET-CT performed before and 4-8 weeks after the end of CCRT; and a minimum follow-up period of 6 months after the end of CCRT, or confirmed death within 6 months post therapy (to enable clinical determination of treatment response).

Correspondence to: G. Nishimura, Department of Otorhinolaryngology, Head and Neck Surgery, Yokohama City University School of Medicine, 3-9 Fukuura, Kanazawa-ku, Yokohama, 236-0004, Japan. Tel: +81 457872687, e-mail: gnishimu@yokohama-cu.ac.jp

Key Words: Head and neck squamous cell carcinoma, metastatic lymph node, chemoradiotherapy.

Table I. Patient characteristics (n=149).

Age (years)	Average	63.1
	Range	28-91
Gender (n)	Male	129
	Female	20
Primary site (n)	Nasopharynx (NPC)	15
	Oropharynx (OPC)	43*
	Hypopharynx (HPC)	58*
	Larynx	17*
	Oral cavity	8*
	Nasal/para-nasal	3
	Unknown primary	8
	(*)Oral cavity + larynx	1
	(*)OPC +HPC	2
N Classification (n)	N1	31
	N2**	104
	N3	14
	(**)N2 (NPC)	8
	(**)N2a	3
	(**)N2b	61
	(**)N2c	32

*Synchronous double cancer cases. **Subclassification in N2 cases.

Treatment. Radiotherapy was performed five days a week with a single daily fraction of 1.8 Gy using 6 MV X-ray linear accelerators for a total dose of 66.6-70.2 Gy. The CCRT regimens were determined by age and/or the comorbidity, as previously reported (4-11). The chemotherapy regimens were as follows: The PFML regimen (7, 8, 11) consisted of cisplatin (60 mg/m², day 4), 5-fluorouracil (600 mg/m², days 1-5), methotrexate (30 mg/m², day 1), and leucovorin (20 mg/m², days 1-5). The TPF regimen (5, 11) consisted of docetaxel (50 mg/m², day 1), cisplatin (60 mg/m², day 4), and 5-fluorouracil (600 mg/m², days 1-5). The S-1 regimen (10) comprised of oral administration of S-1, 1 M tegafur-0.4 M 5-chloro-2,4-dihydroxypyridine-1 M potassium oxonate, with the dose adjusted according to the body surface area. The CBDCA plus UFT regimen (4, 9) consisted of carboplatin (5 AUC, once per week) and uracil-tegafur (300 mg/day, every day). The TXT regimen (6) consisted of an intravenous infusion of docetaxel (10 mg/m², once per week).

Evaluation. At 4-8 weeks after the end of CCRT, the responses at the primary and the metastatic lymph node sites were assessed using CT and/or MRI, US, and FDG-PET or PET-CT. The pathological response of the primary site was confirmed by biopsy for all patients except those with an unknown primary site showing positive neck lymph node(s). For the cytological evaluation of the lymph nodes, FNAC was performed for patients whose imaging examinations were suspected not to be of complete response (CR). In cases where remnant lymph node metastasis was revealed by cytological evaluation or strongly suspected by imaging, neck dissection was performed as definitive surgery of the metastatic lymph nodes, with or without primary site resection. The response assessment of CT and MRI was as per the RECIST guidelines (version 1.1) (12), and the response groups were divided into CR and non-CR [partial response (PR), no change (NC), and progressive disease (PD)]. The response assessment of US was performed by size, morphology, and

Table II. Treatment responses according to the evaluation methods.

	CR (n)	non-CR (n)
CT and MRI (n=141)	100	41
US (n=141)	84	57
FDG-PET or PET-CT (n=141)	130	11
FNAC (n=82)	67	15
Clinical evaluation (n=141)	124	17
Clinical evaluation in FNAC cases (n=82)	68	14

CT: Computer tomography; MRI: magnetic resonance imaging; US: ultrasonography; FDG-PET: fluorodeoxyglucose-positron emission tomography; FNAC: fine-needle aspiration cytology; CR: complete response.

blood flow (13), and the patients were divided into CR and the non-CR groups. The response assessment of FDG-PET or PET-CT was carried out by the standardised uptake value (SUV), with the cutoff value defined at 3.7, as previously reported (14); CR was classified as <3.7 and non-CR as ≥3.7. The FNAC specimens were evaluated by pathologists and classified as class 0 to V. In cases of class 0 and class III, the cytological sample was re-extracted and re-evaluated. A classification of 0, I, II, III, or IIIa was termed as CR, and IIIb, IV, or V as non-CR.

Follow-up. The patients with a CR in both the primary site and neck lymph node(s) were followed up at the outpatient clinic every two to four weeks by manual and visual examinations. Follow-up imaging was performed every two to three months, with a shorter follow-up duration in patients at a high risk for remnant tumors or recurrence. In cases in which remnant tumor or recurrence at the primary site was suspected, pathological diagnosis by biopsy was performed, and in those with remnants or a recurrence at the neck lymph node(s), cytological evaluation by FNAC was conducted. Distant metastasis was diagnosed by imaging.

Remnant tumor and recurrence. The recurrence of lymph node metastasis was defined as growth in size by visual examination, manual examination, CT, MRI, and/or US, the elevation of the SUV by FDG-PET or PET-CT, and/or positive FNAC results after ≥6 months from the end of the CCRT. Cases showing regrowth of the lymph nodes within 6 months after the end of CCRT were considered to have remnant tumor (non-CR), and those in whom regrowth was evident at ≥6 months were classified as recurrence. Thus, patients with clinical CR were defined as no recurrence, and pathological CR patients in neck-dissected patients; patients with clinical non-CR were defined as remnant, and pathological NC patients in neck-dissected patients.

Statistical analysis. Pearson's chi-square test was performed for the sensitivity and the specificity between each examination, a *p*-value less than 0.05 was considered to indicate statistical significance.

Results

Patients. Between January 2002 and January 2010, 149 patients were enrolled. Characteristics of these patients are

Table III. Evaluation of accuracy of each examination compared to the clinical response.

	Sensitivity (%)	Specificity (%)	False-positive rate (%)	False-negative rate (%)
CT and/or MRI (n=141)	52.9	74.2	25.8	47.1
US (n=141)	88.2	66.1	33.9	11.8
FDG-PET or PET-CT (n=141)	35.3	96.0	4.0	64.7
FNAC (n=82)	71.4	95.6	4.4	28.6

CT: Computer tomography; MRI: magnetic resonance imaging; US: ultrasonography; FDG-PET: fluorodeoxyglucose-positron emission tomography; FNAC: fine-needle aspiration cytology.

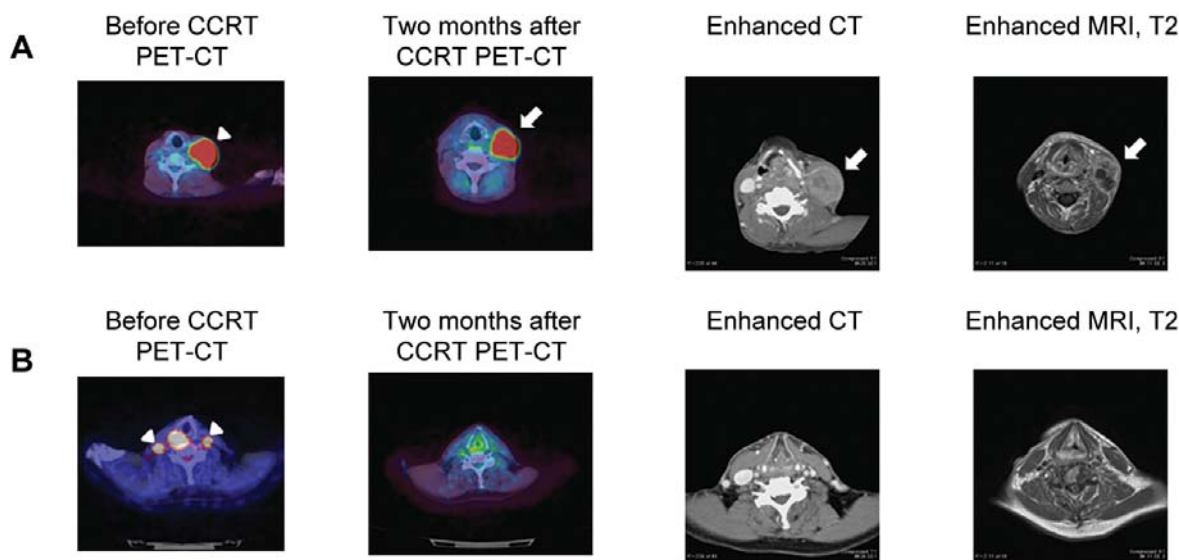


Figure 1. A: A case (56-years-old male) in which all imaging examinations and fine-needle aspiration cytology (FNAC) showed non- complete response (CR) after concurrent chemoradiotherapy (CCRT). The primary disease was hypopharyngeal carcinoma, T4bN3M0. The arrow head indicates the lymph node metastasis before CCRT. The arrows indicate the remnant lymph node after CCRT. B: A case (61-years-old male) in which all imaging examinations and FNAC showed CR after CCRT. However, cancer cells were detected 5 months after the CCRT. The primary disease was hypopharyngeal carcinoma, T4bN2cM0. The arrow heads indicate the lymph node metastasis before CCRT.

summarized in Table I. Chemotherapy regimens including PFML (n=45), TPF (n=43), S-1 (n=30), CBDCA plus UFT (n=27), and TXT (n=4) were selected as previously described (4-11). Five patients with confirmed remnant at the primary site refused definitive surgery, two patients dropped out, and one patient died from ileus four months after the CCRT. Thus, 141 patients were analyzed in this study.

CT and MRI. Enhanced CT and Gd-enhanced MRI were performed on all patients. One hundred patients had a CR and 41 a non-CR. The sensitivity rate of the CT and MRI was 52.9% and the specificity rate was 74.2%. The false-positive rate was 25.8% and the false-negative rate was 47.1% (Tables II and III). US was performed on all patients. Eighty-four cases (59.6%) showed CR and 57 cases (40.4%) non-CR. The sensitivity rate of the US was 88.2% and the specificity rate was 66.1%. The false-positive rate was 33.9% and the false-negative rate was 11.8% (Tables II and III).

FDG-PET and PET-CT. FDG-PET or PET-CT was performed on all patients. There were 130 cases (92.3%) which showed CR and 11 (7.7%), non-CR. The sensitivity rate of the FDG-PET or PET-CT was 35.3% and the specificity rate was 96.0%. The false-positive rate was 4.0% and the false-negative rate was 64.7% (Tables II and III).

FNAC. FNAC was performed on 82 patients, including 67 (81.7%) CR and 15 (18.3%) non-CR cases. The sensitivity rate of the FNAC was 71.4% and the specificity rate was 95.6%. The false-positive rate was 4.4% and the false-negative rate was 28.6% (Tables II and III).

Clinical evaluation. Clinical CR was obtained in 124 (87.9%) and non-CR in 17 (12.1%) cases. Clinical and imaging findings were consistent in 77 patients, including 72 cases of CR and 5 of non-CR (Figure 1A). There was one case in which all imaging examinations and FNAC indicated

CR; however, a metastatic lymph node appeared five months after the CCRT, and thus the case was clinically considered as non-CR (Figure 1B).

Statistical analysis. The sensitivity of CT and MRI are significantly less compared to PET and PET-CT ($p=0.034$), FNA ($p<0.0001$). There were no significant differences for the specificity between the examinations.

In the clinical CR cases, the follow-up period ranged from 6 to 120 months (average, 38.7 months). In this group, 30 patients had locoregional recurrence and/or distant metastases. The types of relapse included primary site recurrence ($n=12$); neck lymph node(s) recurrence ($n=7$); distant metastasis ($n=7$); neck lymph node(s) and distant recurrence ($n=2$); recurrence in the primary site and the neck lymph node(s), as well as distant metastasis ($n=1$); and recurrence in the primary site and neck lymph node(s) ($n=1$). Out of these patients, seven underwent definitive surgery (neck dissection [$n=4$]; both primary resection and neck dissection, [$n=2$]; and primary resection, [$n=1$]), and three (nasopharyngeal carcinoma patients with recurrence confirmed only in the primary site) received additional radiotherapy. Four out of the ten patients who received additional radiotherapy or surgery were alive with tumor-free status and one with tumor-dormant status. Of the remaining 20 patients, 10 had distant metastases which were inoperable: 3 cases were considered inoperable due to local invasion, 3 were considered inoperable for reconstruction surgery because of their age (78, 81, and 89 years), 2 refused definitive surgery, 1 had poor performance status, and 1 patient dropped out. Of the 30 cases locoregional recurrence and/or distant metastasis, 25 patients died of disease-specific reasons. Of the 124 CR cases, 11 patients died of non-specific causes.

In the clinical non-CR cases, the follow-up period ranged from 3 to 69 months (average, 19.4 months). In this group, 8 patients underwent neck dissection with or without primary site resection, 8 refused additional treatment and received terminal care, and 1 patient dropped out. Of the 8 operated cases, 5 died of disease-specific causes, 2 were alive with a tumor-free status, and 1 died of other causes (unspecified) 66 months after treatment.

Discussion

The definitive treatment methods for locoregionally advanced HNSCC are radiotherapy with or without surgical resection. However, recent studies have described the efficacy of CCRT and neo-adjuvant (induction) chemotherapy followed by definitive radiotherapy for advanced HNSCC in terms of organ preservation (1-11, 15, 16). The treatment of lymph node metastases improves the prognosis of advanced HNSCC. However, the treatment response to CCRT of lymph node metastases in patients with advanced HNSCC patients is poor, and it is not unusual for these patients to have a CR

on the primary site but a remnant of the neck lymph node metastasis. This could be attributable to the following factors: The radiation dose distribution tends to be unequal due to irregularities of the regional lymph node area in the head and neck and the maximum radiation dose is limited, especially in cases with advanced N classification (N2c and N3), due to the presence of critical organs, such as the carotid artery and the spine. The radiotherapy CR rates in the lymph node vary between 59% and 83% and are related to the size of the lymph node metastasis, the radiation dose, and the time point when the response is determined (17). With the progress of CCRT, *i.e.* chemotherapy regimens, radiotherapy techniques, and effective means of dealing with adverse events, the treatment outcome of neck lymph node metastases have improved. In cases with obvious remnant lymph node metastases after CCRT, neck dissection is performed as definitive therapy. However, the application of neck dissection following CCRT in CR cases is under debate. Because the possibility of remnant tumor is high in the neck lymph nodes, despite the clinical evaluation being CR (18, 19), PND is performed after definitive radiotherapy in patients with suspected remnant tumors, especially in N2 and N3 cases. In contrast, Argiris *et al.* (20) reported that PND did not improve the survival rate and was unnecessary in patients treated by definitive radiotherapy. Recent articles have reported the rate of isolated neck failure, *i.e.* recurrence only in the neck lymph nodes but not in the primary site that were evaluated as CRs in both sites after CCRT, to be 0-5% (21-23) and have shown that recurrence can be detected in the early period of neck lymph node relapse by FDG-PET or PET-CT (24). For the treatment of metastatic neck lymph node metastases by CCRT with or without PND, evaluation methods with high specificity in order to detect a true CR are required.

Prior to initiating treatments of advanced HNSCC patients, CT and MRI are necessary to evaluate the disease stage and are indispensable in evaluating the T classification, *i.e.* the extent of local invasion, extension to the surrounding organs, and tumor diameters. On the other hand, the common criteria used to determine N classification are the longest diameter of the lymph nodes before the treatment, the morphologic changes in the lymph nodes (25), and the extra-capsular invasion after the definitive treatment (26). The treatment response evaluation for lymph node metastases by CCRT is difficult according to these criteria. In terms of the N classification, the RECIST guideline, *i.e.* the size and the number of tumors, is usually applied. CT and MRI are morphologic imaging diagnostic techniques and cannot diagnose microscopic or molecular level metastases. Thus, in order to determine the necessity for neck dissection after CCRT, performing FDG-PET/PET-CT, US, and/or FNAC may provide superior data.

Cancer cells either metastasize to a part of the lymph node while a normal lymph node structure is maintained, or the

whole lymph node is replaced by cancer cells. The shrinkage of the lymph node metastases which respond to CCRT is of two types, according to the metastasis pattern. According to the first pattern, the lymph node becomes normal, with the cancer cells disappearing as a result of the CCRT. According to the second pattern, the shape of the lymph node is maintained, but there is presence of necrotic and degenerative tissue. Dissection of the lymph node at this time reveals that the inner part has been replaced with necrotic tissue, with no remaining cancer cells. Subsequently, the lymph node metastasis disappears with no necessity for dissection. In contrast, the lymph node metastases that do not respond to CCRT do not show these denaturation patterns, which can be detected by US (13). Thus, we have applied US to evaluate lymph node metastases after CCRT, as a positive screening tool, and obtained sensitivity of 88.2%.

The use of FDG-PET and PET-CT for evaluating remaining lymph node(s) after CCRT has shown varying results. Ong *et al.* (24) reported the PET examination to be useful, whereas Gourin *et al.* (27) did not conclude to benefit. This was possibly due to different evaluation time points used in the two studies. In order to reduce the false-positive rate of FDG-PET and PET-CT after CCRT, it is preferable to perform the evaluation after the radiation-induced inflammation has subsided, whereas to reduce the false-negative rate, it is advisable to wait until the remnant cancer cells can be detected by the minimum accumulation FDG level. To obtain a more accurate N re-classification, it may be beneficial to perform the FDG-PET or PET-CT at a later time point after CCRT. However, a late PET may cause a delay in salvage surgery, resulting in a poorer prognosis. In the early period in our institute, FDG-PET or PET-CT was performed approximately four weeks after CCRT to avoid delays in salvage surgery in non-responding patients. However, as per our previous report (14), we currently perform this evaluation at 6-8 weeks after the CCRT, to circumvent the radiation-induced inflammation, and use an SUV cutoff value of 3.7. With this, we obtained a good specificity rate, but the sensitivity was poor. FDG-PET or PET-CT showed false-negative results in 11 cases. However, 6 out of these 11 patients demonstrated lymph node regrowth at 3 to 5 months after the CCRT. At 4 to 8 weeks after the CCRT, these patients were evaluated as CR by FDG-PET or PET-CT, whereas the clinical CR was defined at least 6 months after the CCRT. The remaining five patients were considered to be essentially false-negative cases. Although the adjusted sensitivity of FDG-PET and PET-CT at 4 to 8 weeks after CCRT was 54.5% and the adjusted specificity was 96.2%, we expect an increase in the sensitivity rate if the evaluation time point is delayed, although doing so may be controversial due to a resultant delay in salvage surgery.

FNAC directly evaluates the intra-lymph node cells. It is useful in cases diagnosed by imaging to be non-CR as per

morphological findings but in which the lymph node is filled with necrotic tissue. In cases in which remnant cancer cells are detected by FNAC, the treatment response is considered as NC, regardless other imaging diagnosis, and neck dissection with or without primary resection should be considered as a subsequent therapy. There were four cases of false-negative results by FNAC, out of which three resulted in lymph node regrowth, five months after the CCRT. However, these patients were evaluated as CR by FNAC, 4 to 8 weeks after the CCRT. One patient was essentially considered to be false-negative, and the adjusted sensitivity of FNAC, 4 to 8 weeks after CCRT, was found to be 90.9% and the adjusted specificity was 95.8%. We suggest that in cases of discrepancy between imaging and clinical evaluations, FNAC should be performed to confirm the intra-lymph node status, despite the accompanying pain and risk of dissemination. The reliability of FNAC is high and satisfactory for the treatment evaluation of lymph node metastases following CCRT.

Conclusion

To evaluate the treatment response to CCRT in patients with advanced HNSCC, CT or MRI, US, and FDG-PET or PET-CT, with or without FNAC, at 6-8 weeks after the end of CCRT were performed. CT and MRI are indispensable in evaluating the response of the primary site to CCRT. However, these techniques are not adequate in evaluating lymph node metastases. US was found to be useful as a positive screening tool, and FDG-PET, PET-CT as a negative screening tool, for evaluating the response of the lymph node metastases. FNAC is useful in both positive and negative cases, particularly in those where there is a discrepancy between clinical and imaging results.

References

- 1 Urba SG, Moon J, Giri PG, Adelstein DJ, Hanna E, Yoo GH, Leblanc M, Ensley JF and Schuller DE: Organ preservation for advanced resectable cancer of the base of tongue and hypopharynx: a Southwest Oncology Group Trial. *J Clin Oncol* 23: 88-95, 2005.
- 2 Fountzilas G, Ciuleanu E, Dafni U, Plataniotis G, Kalogera-Fountzila A, Samantas E, Athanassiou E, Tzitzikas J, Ciuleanu T, Nikolaou A, Pantelakos P, Zaraboukas T, Zamboglou N, Daniilidis J and Ghilezan N: Concomitant radiochemotherapy vs. radiotherapy alone in patients with head and neck cancer: a Hellenic Cooperative Oncology Group Phase III Study. *Med Oncol* 21: 95-107, 2004.
- 3 Seiwert TY and Cohen EEW: State-of-the-art management of locally advanced head and neck cancer. *Br J Cancer* 92: 1341-1348, 2005.
- 4 Taguchi T, Ikeda Y, Mikami Y, Kawai S, Arai Y, Mochimatsu I and Tsukuda M: Combined radiotherapy and chemotherapy with carboplatin and UFT for head and neck squamous cell carcinoma. *Anticancer Res* 23: 713-718, 2003.

- 5 Katori H, Tsukuda M, Mochimatsu I, Ishitoya J, Kawai S, Mikami Y, Matsuda H, Tanigaki Y, Horiuchi C, Ikeda Y, Taguchi T, Ono M, Yoshida T, Hirose S, Sakuma Y and Yamamoto K: Phase I trial of concurrent chemoradiotherapy with docetaxel, cisplatin and 5-fluorouracil (TPF) in patients with locally advanced squamous cell carcinoma of head and neck (SCCHN). *Br J Cancer* 90: 348-352, 2004.
- 6 Fujii M, Tsukuda M, Satake B, Kubota A, Kida A, Kohno N, Okami K and Inuyama Y; Japan Cooperative Head and Neck Oncology Group (JCHNOG): Phase I/II trial of weekly docetaxel and concomitant radiotherapy for squamous cell carcinoma of the head and neck. *Int J Clin Oncol* 9: 107-112, 2004.
- 7 Taguchi T, Tsukuda M, Mikami M, Matsuda H, Horiuchi C, Yoshida T, Nishimura G, Ishitoya J and Katori H: Concurrent chemoradiotherapy with cisplatin, 5-fluorouracil, methotrexate, and leucovorin in patients with advanced resectable squamous cell carcinoma of the larynx and hypopharynx. *Acta Oto-Laryngol* 126: 408-413, 2006.
- 8 Katori H, Tsukuda M and Taguchi T: Analysis of efficacy and toxicity of chemotherapy with cisplatin, 5-fluorouracil, methotrexate and leucovorin (PFML) and radiotherapy in the treatment of locally advanced squamous cell carcinoma of the head and neck. *Cancer Chemother Pharmacol* 59: 789-794, 2007.
- 9 Katori H, Tsukuda M and Taguchi T: Concurrent chemoradiotherapy with carboplatin and uracil-tegafur (UFT) for patients with poor performance status with locally advanced squamous cell carcinoma of the head and neck (SCCHN). *Acta Oto-Laryngol* 127: 1099-1104, 2007.
- 10 Tsukuda M, Ishitoya J, Mikami Y, Matsuda H, Horiuchi C, Taguchi T, Satake K, Kawano T, Takahashi M, Nishimura G, Kawakami M, Sakuma Y, Watanabe M, Shiono O, Komatsu M and Yamashita Y: Analysis of feasibility and toxicity of concurrent chemoradiotherapy with S-1 for locally advanced squamous cell carcinoma of the head and neck in elderly cases and/or cases with comorbidity. *Cancer Chemother Pharmacol* 64: 945-952, 2009.
- 11 Tsukuda M, Ishitoya J, Matsuda H, Horiuchi C, Taguchi T, Takahashi M, Nishimura G, Kawakami M, Watanabe M, Niho T, Kawano T, Ikeda Y, Sakuma Y, Shiono O and Komatsu M: Randomized controlled phase II comparison study of concurrent chemoradiotherapy with docetaxel, cisplatin, and 5-fluorouracil *versus* CCRT with cisplatin, 5-fluorouracil, methotrexate and leucovorin in patients with locally advanced squamous cell carcinoma of the head and neck. *Cancer Chemother Pharmacol* 66: 729-736, 2010.
- 12 Eisenhauer EA, Therasse P, Bogaerts J, Schwartz LH, Sargent D, Ford R, Dancey J, Arbuck S, Gwyther S, Mooney M, Rubinstein L, Shankar L, Dodd L, Kaplan R, Lacombe D and Verweij J: New response evaluation criteria in solid tumours: revised RECIST guideline (version 1.1). *Eur J Cancer* 45: 228-247, 2009.
- 13 Furukawa MK and Furukawa M: Diagnosis of lymph node metastases of head and neck cancer and evaluation of effect of chemoradiotherapy using ultrasonography. *Int J Clin Oncol* 15: 23-32, 2010.
- 14 Horiuchi C, Taguchi T, Yoshida T, Nishimura G, Kawakami M, Tanigaki Y, Matsuda H, Mikami Y, Oka T, Inoue T and Tsukuda M: Early assessment of clinical response to concurrent chemoradiotherapy in head and neck carcinoma using fluoro-2-deoxy-D-glucose positron emission tomography. *Auris Nasus Larynx* 35: 103-108, 2008.
- 15 Pignon JP, Bourhis J, Domenge C and Designé L: Chemotherapy added to locoregional treatment for head and neck squamous-cell carcinoma: three meta-analyses of updated individual data; MACH-NC Collaborative Group; Meta-Analysis of Chemotherapy on Head and Neck Cancer. *Lancet* 355: 949-955, 2000.
- 16 Adelstein DJ, Li Y, Adams GL, Wagner H Jr., Kish JA, Ensley JF, Schuller DE and Forastiere AA: An intergroup phase III comparison of standard radiation therapy and two schedules of concurrent chemoradiotherapy in patients with unresectable squamous cell head and neck cancer. *J Clin Oncol* 21: 92-98, 2003.
- 17 Schoder H, Fury M, Lee N and Kraus D: PET monitoring of therapy response in head and neck squamous cell carcinoma. *J Nucl Med* 50: 74S-88S, 2009.
- 18 Parsons JT, Mendenhall WM, Stringer SP, Amdur RJ, Hinerman RW, Villaret DB, Moore-Higgs GJ, Greene BD, Speer TW, Cassisi NJ and Million RR: Squamous cell carcinoma of the oropharynx; surgery, radiation therapy, or both. *Cancer* 84: 2967-2980, 2002.
- 19 Brizel DM, Prosnitz RG, Hunter S, Fisher SR, Clough RL, Downey MA and Scher RL: Necessity for adjuvant neck dissection in setting of concurrent chemoradiation for advanced head-and-neck cancer. *Int J Radiat Oncol Biol Phys* 58: 1418-1423, 2004.
- 20 Argiris A, Stenson KM, Brockstein BE, Mittal BB, Pelzer H, Kies MS, Jayaram P, Portugal L, Wenig BL, Rosen FR, Haraf DJ and Vokes EE: Neck dissection in the combined-modality therapy of patients with locoregionally advanced head and neck cancer. *Head Neck* 26: 447-455, 2004.
- 21 Lavertu P, Adelstein DJ, Saxton JP, Secic M, Wanamaker JR, Eliachar I, Wood BG and Strome M: Management of the neck in a randomized trial comparing concurrent chemotherapy and radiotherapy with radiotherapy alone in resectable stage III and IV squamous cell head and neck cancer. *Head Neck* 19: 559-566, 1997.
- 22 Corry J, Peters L, Fisher R, Macann A, Jackson M, McClure B and Rischin D: N2-N3 neck nodal control without planned neck dissection for clinical/radiologic complete responders – results of Trans Tasman Radiation Oncology Group Study 98.02. *Head Neck* 30: 737-742, 2008.
- 23 Peters LJ, Weber RS, Morrison WH, Byers RM, Garden AS and Goepfert H: Neck surgery in patients with primary oropharyngeal cancer treated by radiotherapy. *Head Neck* 18: 552-559, 1996.
- 24 Ong SC, Schoder H, Lee NY, Patel SG, Carlson D, Fury M, Pfister DG, Shah JP, Larson SM and Kraus DH: Clinical utility of 18F-FDG PET/CT in assessing the neck after concurrent chemoradiotherapy for locoregional advanced head and neck cancer. *J Nuc Med* 49: 532-540, 2008.
- 25 Som PM: Detection of metastasis in cervical lymph node; CT and MR criteria and differential diagnosis. *Am J Roentgenol* 158: 961-969, 1992.
- 26 Yousem DM, Som PM, Hackney DB, Schwaibold F and Hendrix RA: Central nodal necrosis and extracapsular neoplastic spread in cervical lymph nodes; MR imaging *versus* CT. *Radiology* 182: 753-759, 1992.
- 27 Gourin CG, Williams HT, Seabolt WN, Herdman AV, Howington JW and Terris DJ: Utility of positron-emission tomography-computed tomography in identification of residual nodal disease after chemoradiation for advanced head and neck cancer. *Laryngoscope* 116: 705-710, 2006.

Received December 1, 2011

Revised December 21, 2011

Accepted December 23, 2011