

Vitamin D Receptor Expression in Patients with Vulvar Cancer

DARIUS SALEHIN¹, CHRISTINA HAUGK¹, MARC THILL², TIM CORDES²,
MARINA WILLIAM³, BERNHARD HEMMERLEIN³ and MICHAEL FRIEDRICH¹

¹Department of Gynecology and Obstetrics and ³Institute of Pathology, Helios Hospital Krefeld, Krefeld, Germany

²Department of Obstetrics and Gynecology, University of Lübeck, Lübeck, Germany

Abstract. *The anticarcinogenic potential of vitamin D is attributed to antiproliferative and prodifferentiative effects on cells for a wide variety of carcinomas. The biological effects of 1,25(OH)₂D (calcitriol) are mediated through a soluble receptor protein termed vitamin D receptor (VDR). However, thus far there have been no studies evaluating the association between VDR expression and vulvar cancer. Using immunohistochemical analysis, VDR expression was evaluated separately in the nucleus, cytoplasm and membrane, in vulvar cancer samples and adjacent non-pathological vulvar tissue from 48 squamous cell carcinoma patients with no prior therapy, and the association between VDR and overall survival was investigated. Overall, among the 48 vulvar cancer cases, nuclear and cytoplasmic VDR expression was present in 47 (97.9%) and 23 (47.9%) cases respectively. The median nuclear VDR expression was significantly higher as compared to the cytoplasmic VDR in the vulvar cancer tissue. No significant correlation between VDR values and the age of the patients was detected. Nuclear and cytoplasmic VDR in the vulvar cancer tissue were also compared according to the tumor size, and no significant association between mean tumor VDR and tumor size was detected. There was no association between cytoplasmic VDR expression and OS, but better OS was observed in patients with reduced nuclear VDR expression as compared to those with high VDR expression. VDR may be considered as a useful pathological marker.*

Vitamin D is a liposoluble vitamin, like A, E and K. It is obtained from food such as fish, liver, milk and eggs or it is endogenically synthesized from cholesterol (1-3). Synthesis starts in the liver, where cholesterol is dehydrogenated to 7-dehydrocholesterol (7-DHC) (4), which is binds to

vitamin-D-binding-protein (DBP) and transported via the blood circulation to the skin. Here cholecalciferol is synthesized by light in the 290-315 nm UV-B range (5), and then it is bonded to DBP and circulates back to liver. The active metabolite is hydroxylated in the kidney to 1,25-dihydroxycholecalciferol (1,25(OH)₂D, calcitriol) (6-9).

Although the conversion of 25(OH)D primarily takes place in the kidney, several studies have shown that, 1 α -hydroxylase is also present in other tissues such as prostate (10), colon (11, 12), pancreas (13), parathyroid (14) and breast (15). Several studies have demonstrated the ability of vitamin D to perform autocrine and paracrine functions in carcinomas such as breast, colon and prostate cancer (10, 12, 15-20). Deficiency of vitamin D correlates with these carcinomas (21-24).

The anticarcinogenic potential of vitamin D is attributed to the strong antiproliferative and prodifferentiative effects shown in melanoma, osteosarcoma and breast cancer cells from the above mentioned carcinomas (25-28). The biological effects of 1,25(OH)₂D are mediated through a soluble receptor protein termed vitamin D receptor (VDR). VDR binds 1,25(OH)₂D with high affinity and high selectivity (29). In the target cell, the interaction of 1,25(OH)₂D with the VDR initiates a complex cascade of molecular events culminating in alterations in the rate of transcription of specific genes or gene networks (29-31).

Squamous cell carcinoma of the vulvar is a rare disease with an annual incidence of 1.5-4 per 100,000 women in Germany (32). Vulvar cancer accounts for 3% to 5% of all genital carcinomas affecting women following endometrial, ovarian and cervical cancer (33). Eightyfive-90% of vulvar carcinomas are squamous cell carcinomas (34), the remainder are melanomas, adenocarcinomas and sarcomas (35). Vulvar intraepithelial neoplasia (VIN) is the most common premalignant affliction of the vulvar, emanating from a HPV-Infection (36).

Since 1970 the incidence of carcinoma *in situ*, attributed to VIN III, has nearly doubled (37, 38), while invasive carcinoma tends to increase in the last few years (39, 40).

VDR expression has been studied in carcinomas of the breast (41), lung (42) and the colon (43). However, there has

Correspondence to: Dr. med. Darius Salehin, Department of Gynecology and Obstetrics, Helios Hospital Krefeld, Lutherplatz 40, 47805 Krefeld, Germany. Tel: +49 2151322201, Fax: +40 2151322220, e-mail: darius.salehin@helios-kliniken.de

Key Words: Vitamin D, VDR, vulvar cancer, calcitriol, SCC.

Table I. VDR-score.

Intensity levels		Reactive cells	
0	None	0	no pos. cells
1	Weak	1	<10% pos. cells
2	Moderate	2	10-50% pos. cells
3	Strong	3	51-80% pos. cells
		4	>80% pos. cells

Pos. cells: positive cells.

been no study evaluating the VDR expression in vulvar cancer, 48 samples of squamous cell carcinoma of the vulvar were evaluated for the presence of VDR.

Patients and Methods

Study participants and setting. The pathological samples consisted of a consecutive series of 48 patients who had received primary surgical treatment between 1995 and 2009 at the Helios Hospital Krefeld, Germany. The study population consisted of patients with histologically proven squamous cell carcinoma of the vulvar of different stages and adjacent non-pathological vulvar tissue. The patients were aged between 25 and 87 years. It is reasonable to assume that disruption of the vitamin D signaling and metabolic pathways may occur during tumor development. Women with a history of liver and kidney diseases, osteoporosis, diabetes mellitus, endometriosis or pregnancy were excluded from the study. None of the patients were receiving vitamin D supplements.

Immunohistochemistry. Immunohistochemistry was performed with a VDR-specific polyclonal antibody, C-20: sc-1008 (Santa Cruz Biotechnology, Heidelberg, Germany). Sections of five micrometer thickness on slides were deparaffinized and rehydrated (Figure 1). The slides were incubated with the VDR-specific antibody by a fully automated slide preparation system.

Scoring and cut-off selection. Immunohistochemical expression of VDR was assessed semi-quantitatively with regards to the intensity and proportion of positively stained tumor cells. The proportion of tumor cells and healthy vulvar tissue expressing VDR, in the nucleus, cytoplasm and membrane was recorded separately, at four intensity levels: none (0), weak (1), moderate (2) or strong (3) and was assigned an immunohistochemical score for each type of VDR expression (Table I) (Figures 2a-d, 3). This is an established technique of scoring, used in clinical practice in our institute of pathology within the context of scoring steroid hormone receptors (estrogen receptor, progesterone receptor) in breast cancer (44). No consistent scoring methods have previously been used to study VDR in vulvar cancer.

Statistical analysis. Statistical analysis was performed using the statistical package SPSS Version 18.0 (Statistical Package for Social Sciences, SPSS GmbH, München, Germany). Mann-Whitney, Fisher's Exact and Chi-square tests were used to compare the categorical variables. A *p*-value of less than 0.05 was considered statistically significant.

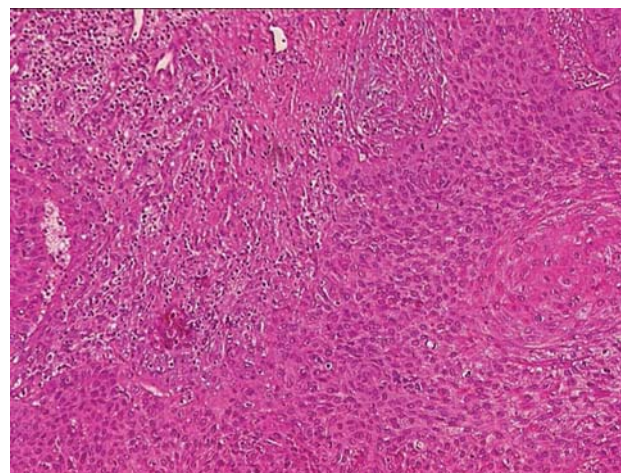


Figure 1. Squamous cell carcinoma of the vulvar (hematoxylin staining, magnification $\times 20$).

Survival analysis was performed according to the Kaplan-Meier method and survival differences were tested by log-rank test.

Results

VDR expression. Overall, among the 48 vulvar cancer cases studied, nuclear and cytoplasmic VDR expression was present in 47 (97.9%) and 23 (47.9%) cases respectively. The median nuclear VDR expression was significantly ($p=0.001$) higher in the vulvar cancer tissue (4.7 ± 3.0) as compared to the cytoplasmic VDR in the vulvar cancer tissue (1.7 ± 2.4) (Figure 4).

In four cases a high expression of membrane VDR was demonstrated in vulvar cancer tissues. The percentage of immunoreactive cases for the nuclear VDR in the non-pathological vulvar tissue was very high (91.7%, corresponding to 44 cases out of 48). Regarding the expression of cytoplasmic VDR in the non-pathological vulvar tissue, only 4.2% of positive cases, corresponding to 2 out of 48 were observed (Table II).

Within the vulvar cancer tissue and non-pathological vulvar tissue, the nuclear VDR expression was characterized by strong immunoreactivity (4.7 ± 3.0), whereas the non-pathological vulvar tissues expressed nuclear VDR immunoreactivity of 3.8 ± 2.1 . The difference between nuclear VDR expression in the vulvar cancer and non-pathological vulvar tissue was significant ($p=0.030$) (Figure 5).

Correlation between VDR and age or histological characterization. No significant correlation between the VDR values and the age of the patients was detected.

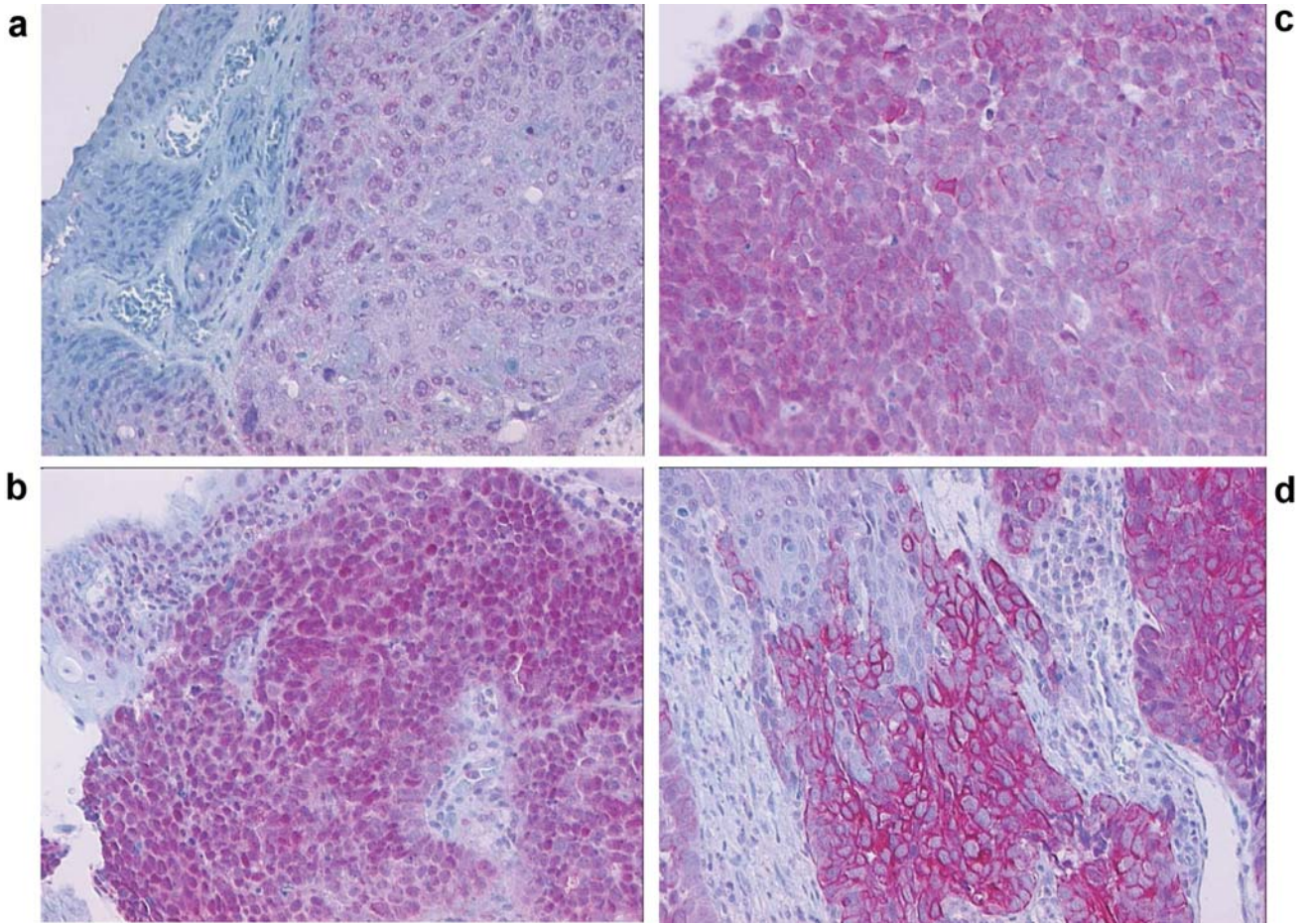


Figure 2. Immunohistochemical staining of paraffin-embedded sections of vulvar cancer tissue (magnification $\times 20$). a) Weak staining of nuclear VDR. b) Strong staining of nuclear VDR. c) Staining of cytoplasmic VDR. d) Staining of membranous VDR.

Table II. VDR expression in vulvar cancer and healthy vulvar tissue.

Score	Vitamin D receptor			
	Nucleus/ tumor	Cytoplasm/ tumor	Nucleus/ healthy tissue	Cytoplasm/ healthy tissue
0	1 (2.1%)	25 (52.1%)	4 (8.3%)	46 (95.8%)
1	5 (10.4%)	4 (8.3%)	-	-
2	5 (10.4%)	6 (12.4%)	8 (16.7%)	1 (2.1%)
3	11 (22.9%)	3 (6.3%)	13 (27.1%)	1 (2.1%)
4	7 (14.6%)	3 (6.3%)	9 (18.8%)	-
6	8 (16.7%)	6 (12.5%)	11 (22.9%)	-
8	7 (14.6%)	-	2 (4.2%)	-
9	1 (2.1%)	1 (2.1%)	1 (2.1%)	-
12	3 (6.3%)	-	-	-
n	n=48	n=48	n=48	n=48
mean \pm SD	4.7 \pm 3.0	1.7 \pm 2.4	3.8 \pm 2.1	0.1 \pm 0.5

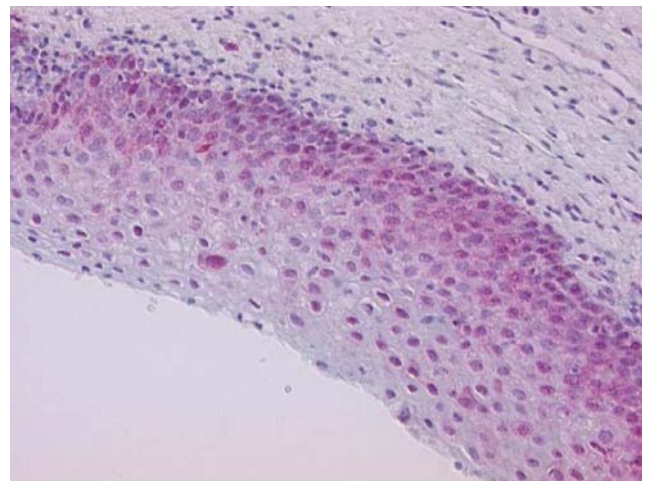


Figure 3. Immunohistochemical staining of paraffin-embedded sections of vulvar healthy tissue (magnification $\times 20$).

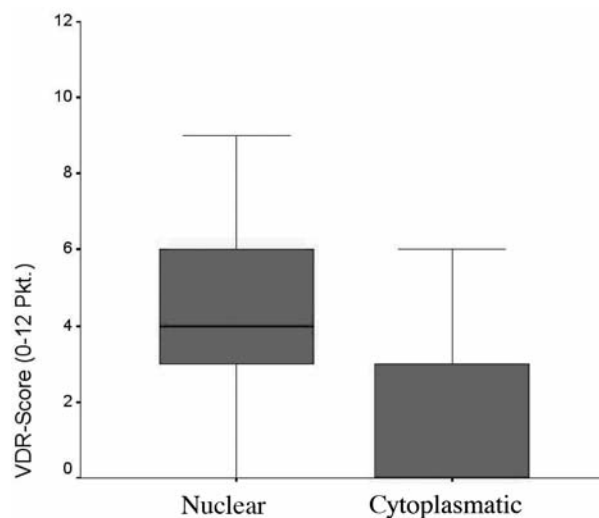


Figure 4. Nuclear and cytoplasmic VDR in vulvar cancer tissue.

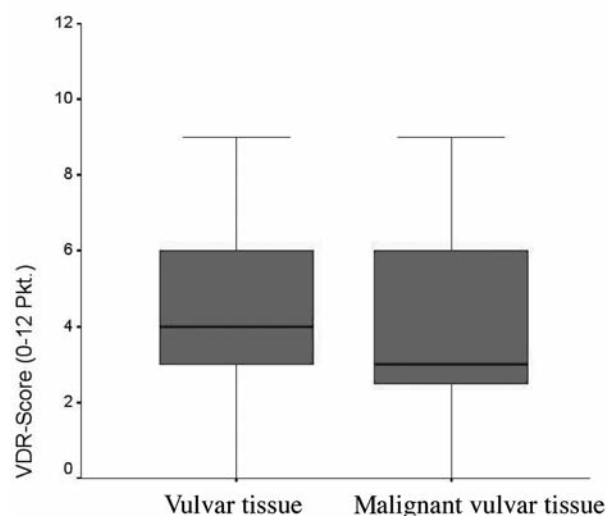


Figure 5. Expression of the nuclear VDR in non-pathological and malignant vulvar tissue.

The expression of nuclear VDR in well-differentiated vulvar cancer was 4.8 ± 3.2 while in poorly-differentiated vulvar cancer it was 4.5 ± 3.0 . This difference was statistically not significant. There was also a trend towards an increased expression of cytoplasmic VDR in the well-differentiated *versus* poorly-differentiated vulvar cancer. However, the difference was not statistically significant. Nuclear and cytoplasmic VDR in vulvar cancer tissue were also compared according to the tumor size, and no significant association between mean tumor VDR and tumor size was detected (Table III).

VDR expression and overall survival. Patients with low nuclear VDR expression (4.3 ± 3.0) exhibited better OS compared to those with high VDR expression (5.0 ± 2.7), although this difference was again not statistically significant.

Discussion

The VDR assay allowed reliable quantification of the protein and rend it possible to detect reasonable differences among the groups.

The expression of nuclear VDR in the pathological tissue revealed a significantly higher expression of the VDR than in non-pathologic vulvar tissue. Similar results were previously demonstrated for breast cancer (15, 45). However conflicting results have been published with lower VDR expression in malignant breast tissues (46) and of nuclear VDR in non-small cell lung cancer (NSCLC) patients on which an even distribution of high and low cytoplasmic VDR expression was observed (42).

In concordance with other cancer studies, VDR was found to be present in the cytoplasm of the studied vulvar cancer

Table III. Comparison of nuclear and cytoplasmic VDR and tumor grading.

Grading	Nuclear VDR	Cytoplasmic VDR
G 1	n=1	n=1
Mean	3	3
G 2	n=23	n=23
Mean±SD	4.8 ± 3.2	1.8 ± 2.4
Median	4	1
Min-max	0-12	0-9
G 3	n=14	n=14
Mean±SD	4.5 ± 3.0	2.4 ± 2.8
Median	4	1
Min-max	1-12	0-6
p-value	0.775	0.581

patients, but significantly less expression of the cytoplasmic VDR was found in the non-pathological vulvar tissue compared to vulvar cancer. The nuclear VDR expression in the non-pathological vulvar tissue and the vulvar cancer was higher than the cytoplasmic VDR expression. Similar observations of VDR in patients with ovarian cancer and expression of cytoplasmic VDR were reported by Silvagno *et al.* (47), who also found that high VDR expression was associated with better overall survival (OS).

In our study VDR expression showed no significant correlation to the OS. There was a trend for the OS of the vulvar cancer patients. The patients who died of vulvar cancer had a lower VDR expression in comparison to those

who died of a different cause. Patients with high nuclear VDR expression have been shown to have a higher survival rate in NSCLC while the level of cytoplasmic VDR expression had no influence on OS (42). Due to the limitations of the present small retrospective study, definite conclusions concerning the OS could not be drawn.

Although nuclear VDR expression showed no statistically significant differences in relation to tumor size and grading; a trend for higher expression of cytoplasmic VDR in well differentiated vulvar cancer compared to cases with poor differentiation was found.

In colon cancer cells, Shabahang *et al.* demonstrated an inhibiting effect of 1.25(OH)₂D with well-differentiated carcinomas showing inhibition of cell proliferation as compared to poorly-differentiated carcinomas (48). Holick *et al.* showed that 1.25(OH)₂D may inhibit cell proliferation in healthy and malignant prostate-, breast- and colon tissue and may induce cell differentiation (49). Some of the studies suggested a protective effect of locally produced 1.25(OH)₂D in the pathogenesis of various malignancies. Vitamin D up-regulation of VDR expression in malignant melanoma cells has been reported (50). A higher number of patients in our study may perhaps have demonstrated a correlation between the differentiation of vulvar cancer and the expression of VDR. However, due to the very small number of patients with well-differentiated vulvar cancer in the present study (n=1), no definite conclusions could be drawn.

Membrane-bound VDR (mVDR) first described in literature 1981 (51) was also detected in four of the present cases of vulvar cancer.

The mVDR transmits signals *via* changes in the intracellular calcium levels (52, 53) and represents a secondary mode of molecular signalling in addition to the nuclear VDR (30). Calcitriol regulates transcription by a nuclear VDR and can also interact with a membrane VDR by a rapid cellular reaction (54). To our knowledge, expression of mVDR in vulvar cancer has not been previously reported.

The expression of VDR in breast cancer is correlated with the anti-proliferative effects of calcitriol, so that the intensity of VDR expression in tumor cells may be considered a prognostic marker for the response to therapy with calcitriol or vitamin D analogues (55).

Further studies should be conducted to evaluate vitamin D supplementation and its effect on the pathogenesis of gynecological tumors. *In vivo* studies showed that active vitamin D analogues may block proliferation and tumor progression of epithelial tumor cells (56). This approach may also be useful in the prevention of vulvar cancer. For example, in the near future vitamin D analogues may be used for the treatment of vulvar intraepithelial neoplasia to prevent progression to invasive carcinoma. This promising hypothesis, however, will require further evaluation through clinical trials.

References

- Giovanucci E: The epidemiology of vitamin D and cancer incidence and mortality: a review (United States). *Cancer causes control* 16: 83-95, 2005.
- Haddad JG and Hahn TJ: Natural and synthetic sources of circulating 25-hydroxyvit-D in man. *Nature* 244: 515-517, 1973.
- Slovik DM, Adams JS, Neer RM, Holick MF and Potts JT: Deficient production of 1,25-dihydroxyvitamin D in elderly osteoporotic patients. *N Engl J Med* 305(7): 372-374, 1981.
- Holick MF: Sunlight and vitamin D for bone health and prevention of autoimmune diseases, cancers, and cardiovascular disease. *Am J Clin Nutr* 80: 1678-1688S, 2004.
- Kimlin MG: Understanding vitamin D ultraviolet radiation. *Proceedings of the 13th vitamin D workshop*. Victoria, BC, Canada, 2006.
- Hollis BW and Wagner CL: Normal serum vitamin D levels. *N Engl J Med* 352(5): 515-516, 2005.
- Reichrath J: Vitamin D and the skin: an ancient friend, revisited. *Experimental Dermatology* 16(7): 618-625, 2007.
- Jakob F: 1,25(OH)₂-vitamin D₃. The vitamin D hormone. *Internist* 40(4): 414-430, 1999.
- Holick MF: Vitamin D deficiency. *N Engl J Med* 357: 266-281, 2007.
- Barreto AM, Schwartz GG, Woodruff R and Cramer SD: 25-Hydroxyvitamin D₃, the prohormone of 1,25-dihydroxyvitamin D₃, inhibits the proliferation of primary prostatic epithelial cells. *Cancer Epidemiol Biomarkers Prev* 9: 265-270, 2000.
- Ogunkolade BW, Boucher BJ, Fairclough PD, Hitman GA, Dorudi S, Jenkins PJ and Bustin SA: Expression of 25-hydroxyvitamin D-1- α -hydroxylase mRNA in individuals with colorectal cancer. *Lancet* 359: 1831-1832, 2002.
- Tangpricha V, Flanagan JN, Whitlach LW, Tseng C, Chen TC, Holt PR, Lipkin MS and Holick MF: 25-Hydroxyvitamin D-1 α -hydroxylase in normal and malignant colon tissue. *Lancet* 357: 1673-1674, 2001.
- Hewison M, Kantorovich V, Liker HR, van Herle AJ, Cohan P, Zehnder D and Adams JS: Vitamin D-mediated hypercalcemia in lymphoma: evidence of hormone production by tumoradjacent macrophages. *J Bone Miner Res* 18: 579-582, 2003.
- Hewison M, Zehnder D, Chakraverty R and Adams JS: Vitamin D and barrier function: a novel role for extra renal 1 α -hydroxylase. *Mol Cell Endocrinol* 215: 31-38, 2004.
- Friedrich M, Diesing D, Cordes T, Fischer D, Becker S, Chen TC, Flanagan JN, Tangpricha V, Gherson I, Holick MF and Reichrath J: Analysis of 25-hydroxyvitamin D₃-1 α -hydroxylase in normal and malignant breast tissue. *Anticancer Res* 26(4A): 2615-2620, 2006.
- Cordes T, Fischer D, Thill M, Becker S, Friedrich M and Salehin D: Vitamin D-1 α -hydroxylase and vitamin D-24-Hydroxylase in benign and malign breast tissue. *Eur J Gynaecol Oncol* 31(2): 151-155, 2010.
- Fischer D, Seifert M, Becker S, Ludders D, Cordes T, Reichrath J and Friedrich M: 25-Hydroxyvitamin D₃ 1 α -hydroxylase splice variants in breast cell lines MCF-7 and MCF-10. *Cancer Genomics Proteomics* 4(4): 295-300, 2007.
- Ogunkolade WB, Boucher BJ, Bustin SA, Burrin JM, Noonan K, Mannan N and Hitman GA: Vitamin D metabolism in peripheral blood mononuclear cells is influenced by chewing "betel nut" (*Areca catechu*) and Vitamin D status. *J Clin Endocrinol Metab* 91(7): 2612-2617, 2006.

- 19 Garland CF, Garland FC, Shaw EK, Comstock GW, Helsing KJ and Gorham ED: Plasma 25-hydroxyvitamin D and colon cancer: eight-year prospective study. *Lancet* 2(8673): 1176-1178, 1989.
- 20 Schwartz GG and Hulka BS: Is vitamin D deficiency a risk factor for prostate cancer? *Anticancer Res* 10(5A): 1307-1311, 1990.
- 21 Holt PR, Arber N, Halmos B, Forde K, Kissilef H, McGlynn KA, Moss SF, Kurihara N, Fan K, Yang K and Lipkin M: Colonic epithelial cell proliferation decreases with increasing levels of serum 25-hydroxy vitamin D. *Cancer Epimeiol Biomarkers Prev* 11(1): 113-119, 2002.
- 22 Lowe LC, Guy M, Mansi JL, Peckitt C, Bliss J, Wilson RG and Colston KW: Plasma 25-hydroxy vitamin D concentrations, vitamin D genotype and breast cancer risk in a UK Caucasian population. *Eur J Cancer* 41(8): 1164-1169, 2005.
- 23 Rossi M, McLaughlin JK, Lagiou P, Bosetti C, Talamini R, Lipworth L, Giacosa A, Montella M, Franceschi S, Negri E and La Vecchia C: Vitamin D intake and breast cancer risk: a case-control study in Italy. *Ann Oncol* 20(2): 374-378, 2009.
- 24 Zitterman A: Vitamin D in preventive medicine: are we ignoring the evidence? *Br J Nutr* 89: 552-572, 2003.
- 25 Eisman JA, Martin TJ and MacIntyre I: 1,25-dihydroxyvitamin D₃ receptors in cancer. *Lancet* 31(1): 1188, 1980.
- 26 Hansen CM, Hansen D, Holm PK and Binderup L: Vitamin D compounds exert anti-apoptotic effects in human osteosarcoma cells *in vitro*. *J Steroid Biochem Mol Biol* 77(1): 1-11, 2001.
- 27 Saez S, Falette N, Guillot C, Meggouh F, Lefebvre MF and Crepin M: William L. McGuire Symposium. 1,25(OH)₂D₃ modulation of mammary tumor cell growth *in vitro* and *in vivo*. *Breast Cancer Res Treat* 27(1-2): 69-81, 1993.
- 28 Trump DL, Hershberger PA, Bernhardt RJ, Ahmed S, Muindi J, Fakih M, Yu WD and Johnson CS: Anti-tumor activity of Calcitriol: pre-clinical and clinical studies. *J Steroid Biochem Mol Biol* 89-90(1-5): 519-526, 2004.
- 29 Li YC: Vitamin D regulation of the renin-angiotensin system. *J Cell Biochem* 88(2): 327-331, 2003.
- 30 Marcinkowska E and Wiedlocha A: Steroid signal transduction activated at the cell membrane: from plants to animal. *Acta Biochim Pol* 49: 735-745, 2002.
- 31 Sone T, Kerner S and Pike JW: Vitamin D receptor interaction with specific DNA. Association as a 1,25-dihydroxyvitamin D₃-modulated heterodimer. *J Biol Chem* 266(34): 23296-23305, 1991.
- 32 Krebs in Deutschland. Häufigkeiten und Trends. Arbeitsgemeinschaft Bevölkerungsbezogener Krebsregister in Deutschland, in Zusammenarbeit mit dem Robert-Koch-Institut, 4. überarbeitete, aktualisierte Ausgabe. Saarbrücken, 2004.
- 33 Reinhaller A and Leodolter S: Chirurgische Onkologie. Vulvakarzinom. Part 2: 441-447, 2008.
- 34 Kimmig R and Kürzl R (Eds): Manual Vulvakarzinom. Empfehlungen zur Diagnostik, Therapie und Nachsorge. W. Zuckerschwerdt ; München Bern Wien New York, 2001.
- 35 Schnürch HG and Meerpohl HG: Kompendium internistische Onkologie. Vulvakarzinom 8: 4765-4788, 2006.
- 36 Toki T, Kurman RJ, Park JS, Kessis T, Daniel RW and Shah KV: Probable nonpapillomavirus etiology of suamous cell carcinoma of the vulva in older women: a clinicopathologic study using *in situ* hybridization and polymerase chain reaction. *Int J Gynecol Pathol* 10: 107-125, 1991.
- 37 WHO. International histological classification of tumours. *In*: Histological typing of female genital tract tumours. Scully RE, Bonfiglio TA, Kurman RJ, Silverberg SG, Wilkinson EJ (eds.) Berlin Heidelberg New York: Springer, 1984.
- 38 Wilkinson EJ and Teixeira MR: Epithelial tumours, squamous tumours: *In*: World Health Organization Classification of Tumours: Pathology and Genetics: Tumours of the Breast and Female Genital Organs. Tavassoli M, Devilee P (Eds.) Lyon: IARC Press, 230-320, 2003.
- 39 Landis S, Murray T, Bolden S and Wingo PA: Cancer Statistics. *CA-Cancer J Clin* 48: 6-29, 1998.
- 40 Sturgeon SR, Briton LA, Devesa SS and Kurman RJ: *In situ* and invasive vulvar cancer incidence trends (1973 to 1987). *Am J Obstet Gynecol* 166: 1482-1485, 1992.
- 41 Colston KW, Berger U and Coombes RC: Possible role for vitamin D in controlling breast cancer cell proliferation. *Lancet* 1: 188-191: 1989.
- 42 Srinivasan M, Parwani AV, Hershberger PA, Lenzner DE and Weissfeld JL: Nuclear vitamin D receptor expression is associated with improved survival in non-small cell lung cancer. *J Steroid Biochem Mol Biol* 123(1-2): 30-36, 2011.
- 43 Murillo G, Peng X, Benya RV and Mehta RG: Human colon cancer cells express CYP27B1 and their proliferation is inhibited by 25-hydroxyvitamin D₃. *Proceedings of the 13th vitamin D workshop*, Victoria, BC, Canada, 2006.
- 44 Remmele W and Stegner HE: Recommendation for uniform definition of an immunoreactive score (IRS) for immunohistochemical estrogen receptor detection (ER-ICA) in breast cancer tissue. *Pathologe* 8(3): 138-140, 1987.
- 45 Townsend K, Evans KN, Campbell MJ, Colston KW, Adams JS and Hewison M: Biological actions of extra-renal 25-hydroxyvitamin D-1alpha-hydroxylase and implications for chemoprevention and treatment. *J Steroid Biochem Mol Biol* 97(1-2): 103-109, 2005.
- 46 Thill M, Fischer D, Hoellen F, Kelling K, Dittmer C, Landt S, Salehin D, Diedrich K, Friedrich M and Becker S: Prostaglandin metabolizing enzymes and PGE2 are inversely correlated with vitamin D receptor and 25(OH)₂D₃ in breast cancer. *Anticancer Res* 30(5): 1673-1679, 2010.
- 47 Silvagno F, Poma CB, Realmuto C, Ravarino N, Ramella A, Santoro N, D'Amelio P, Fuso L, Pescarmona G and Zola P: Analysis of vitamin D receptor expression and clinical correlations in patients with ovarian cancer. *Gynecol Oncol* 119: 121-124, 2010.
- 48 Shabahang M, Buras RR, Davoodi F, Schumaker LM, Nauta RJ and Evans SR: 1,25-Dihydroxyvitamin D₃ receptor as a marker of human colon carcinoma cell line differentiation and growth inhibition. *Cancer Res* 53(16): 3712-3718, 1993.
- 49 Holick MF: Vitamin D: evolutionary, physiological and health perspectives. *Curr Drug Targets* 12(1): 4-18, 2011.
- 50 Ainsleigh HG: Beneficial effects of sun exposure on cancer mortality. *Prev Med* 22(1): 132-140, 1993.
- 51 Nemere I and Szego CM: Early actions of parathyroid hormone and 1,25-dihydroxycholecalciferol on isolated epithelial cells from rat intestine. *Endocrinology* 108: 1450-1462, 1981.
- 52 Boland R, De Boland AR, Buitrago C, Morelli S, Santillán G, Vazquez G, Capiati D and Baldi C: Non-genomic Stimulation of tyrosine phosphorylation cascades by 1,25(OH)₂D₃ by VDR-dependent and -independent mechanisms in muscle cells. *Steroids* 67: 477-482, 2002.

- 53 Marcinkowska E: A run for a membrane vitamin D receptor. *Biol Signals Recept* 10(6): 341-349, 2001.
- 54 Zanatta L, Zamoner A, Zanatta AP, Bouraima-Lelong H, Delalande C, Bois C, Carreau S and Silva FR: Nongenomic and genomic effects of 1 α ,25(OH)(2) vitamin D(3) in rat testis. *Life Sci* 89(15-16): 515-523, 2011.
- 55 Jensen SS, Madsen MW, Lukas J, Bartek J and Binderup L: Sensitivity to growth suppression by 1 α ,25.dihydroxyvitamin D(3) among MCF-7 clones correlates with Vitamin D receptor protein induction. *J Steroid Biochem Mol Biol* 81: 123-133, 2002.
- 56 Trémezaygues L and Reichrath J: From the bench to emerging new clinical concepts: Our present understanding of the importance of the vitamin D endocrine system (VDES) for skin cancer. *Dermatoendocrinol* 3(1): 11-17, 2011.

Received September 19, 2011

Revised November 8, 2011

Accepted November 9, 2011